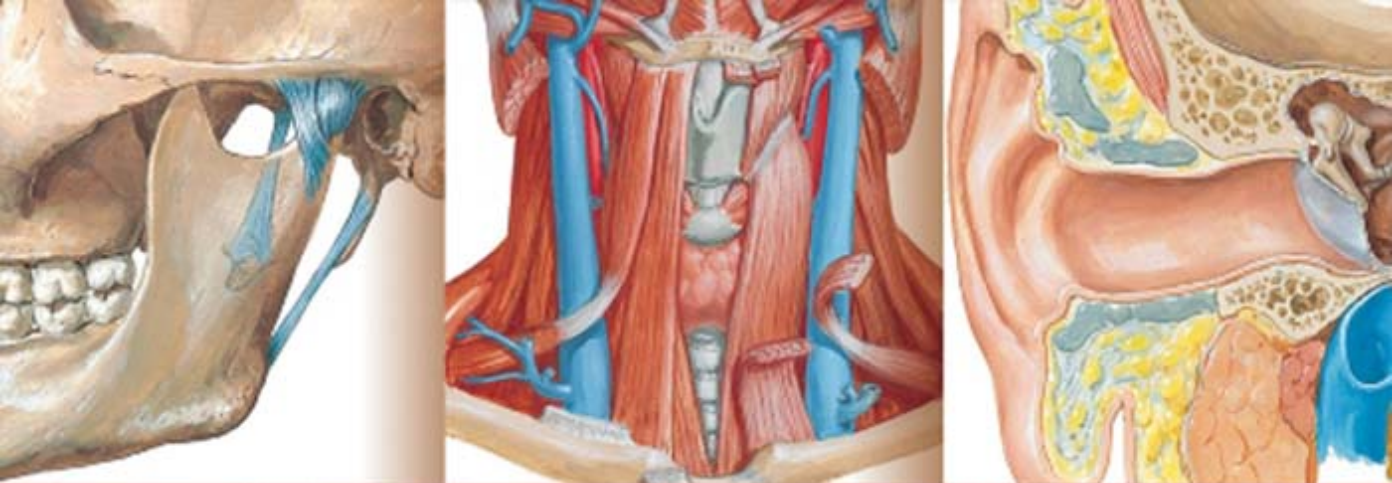

NETTER'S

*Atlas of* ANATOMY  
*for* SPEECH,  
SWALLOWING,  
*and* HEARING

*Second Edition*

*F. Netter  
M.D.*

David H. McFarland

ELSEVIER

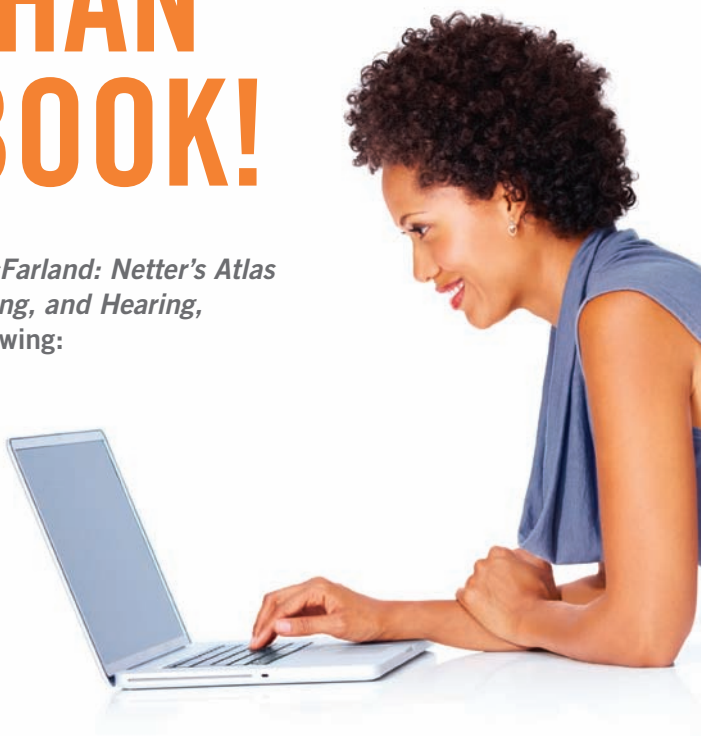


EVOLVE STUDY RESOURCES FREE WITH NEW TEXTBOOK PURCHASE  
[EVOLVE.ELSEVIER.COM](http://EVOLVE.ELSEVIER.COM)

# YOU'VE JUST PURCHASED MORE THAN A TEXTBOOK!

Evolve Student Resources for *McFarland: Netter's Atlas of Anatomy for Speech, Swallowing, and Hearing, Second Edition*, include the following:

- **Self-Test Questions:** Approximately 150 objective-style questions—multiple-choice, true/false, fill-in-the-blank, and matching—are available for examination preparation and accompanied by instant feedback and remediation assistance.
- **Labeling Exercises:** Many of the book's illustrations have been turned into interactive drag-and-drop exercises as a practice tool to help students master the relevant anatomy.



Activate the complete learning experience that comes with each textbook purchase by registering with your scratch-off access code at

<http://evolve.elsevier.com/McFarland/Netter/>

## REGISTER TODAY!

You can now purchase Elsevier products on Evolve!

Go to [evolve.elsevier.com/html/shop-promo.html](http://evolve.elsevier.com/html/shop-promo.html) to search and browse for products.

NETTER'S

---

*Atlas of* ANATOMY  
*for* SPEECH,  
SWALLOWING,  
*and* HEARING

---

*Second Edition*

This page intentionally left blank



NETTER'S

---

*Atlas of* ANATOMY  
*for* SPEECH,  
SWALLOWING,  
*and* HEARING

---

*Second Edition*

David H. McFarland

ASHA Fellow

Professor

School of Speech-Language Pathology and Audiology

Faculty of Medicine

University of Montreal;

Adjunct Professor

School of Communication Sciences and Disorders

Faculty of Medicine

McGill University

Montreal, Quebec, Canada

ELSEVIER

ELSEVIER  
MOSBY

3251 Riverport Lane  
St. Louis, Missouri 63043

*Netter's Atlas of Anatomy for Speech, Swallowing, and Hearing*, ed 2

978-0-323-23982-0

**Second Edition: Copyright © 2015 by Mosby, an imprint of Elsevier Inc. All rights reserved.**

**First Edition: Copyright © 2009 by Mosby, Inc., an affiliate of Elsevier Inc. All rights reserved.**

No part of this publication may be reproduced or transmitted in any form or by any means, electronic or mechanical, including photocopying, recording, or any information storage and retrieval system, without permission in writing from the Publisher. Details on how to seek permission, further information about the Publisher's permissions policies and our arrangements with organizations such as the Copyright Clearance Center and the Copyright Licensing Agency, can be found at our website: [www.elsevier.com/permissions](http://www.elsevier.com/permissions).

This book and the individual contributions contained in it are protected under copyright by the Publisher (other than as may be noted herein).

#### Notices

Knowledge and best practice in this field are constantly changing. As new research and experience broaden our understanding, changes in research methods, professional practices, or medical treatment may become necessary.

Practitioners and researchers must always rely on their own experience and knowledge in evaluating and using any information, methods, compounds, or experiments described herein. In using such information or methods they should be mindful of their own safety and the safety of others, including parties for whom they have a professional responsibility.

With respect to any drug or pharmaceutical products identified, readers are advised to check the most current information provided (i) on procedures featured or (ii) by the manufacturer of each product to be administered, to verify the recommended dose or formula, the method and duration of administration, and contraindications. It is the responsibility of practitioners, relying on their own experience and knowledge of their patients, to make diagnoses, to determine dosages and the best treatment for each individual patient, and to take all appropriate safety precautions.

To the fullest extent of the law, neither the Publisher nor the authors, contributors, or editors, assume any liability for any injury and/or damage to persons or property as a matter of products liability, negligence or otherwise, or from any use or operation of any methods, products, instructions, or ideas contained in the material herein.

Previous edition copyrighted 2009

#### Library of Congress Cataloging-in-Publication Data or Control Number

*Content Strategy Director:* Penny Rudolph  
*Professional Content Development Manager:* Jolynn Gower  
*Senior Content Development Specialist:* Courtney Sprehe  
*Publishing Services Manager:* Jeff Patterson  
*Senior Project Manager:* Jeanne Genz  
*Designer:* Ashley Miner  
*Copy Editor:* Beth Welch

Printed in China

Last digit is the print number: 9 8 7 6 5 4 3 2 1



Working together  
to grow libraries in  
developing countries

[www.elsevier.com](http://www.elsevier.com) • [www.bookaid.org](http://www.bookaid.org)

# PREFACE

Speech, swallowing, and hearing are human behaviors that are vital to everyday life. And diagnosing and treating their disordered function requires a thorough understanding of the many body systems involved.

The purpose of this atlas is to provide readers with a comprehensive reference for the essential aspects of speech, swallowing, and hearing anatomy. Key physiological and nervous system processes, which cannot be dissociated from anatomy, have also been summarized to deliver a more complete picture of these functions. This second edition was an opportunity to include more anatomical illustrations and provide additional physiological details.

## ■ AUDIENCE

This atlas is for anyone interested in the body systems involved in speech, swallowing, and hearing, either for understanding normal processes or as a basis for clinical practice. It is specifically tailored for instructors and students in both undergraduate and graduate programs, as well as for researchers and clinicians in the fields of speech-language pathology, audiology, and related medical disciplines. My sincere ambition for this book is that it will serve as a useful learning tool for students and be a faithful reference for practitioners and researchers. I also hope that it will become a functional guide for clinicians who work with disorders of speech, swallowing, and hearing, and used to educate patients suffering from these problems. Perhaps one day it may even become a platform for shared communication among the diverse professionals encountering the challenges of these complex disorders.

## ■ CONCEPT AND IMPORTANCE TO THE PROFESSION

The inaugural edition of this atlas was the first time that the medical illustrations of Frank Netter had been gathered into a volume dedicated to speech, swallowing, and hearing. These seminal illustrations were chosen in part because they are used extensively in other disciplines and thereby represent a common base of study and clinical reference for students, instructors, and professionals in these fields. The images also have garnered the favor of scholars and clinicians because they provide just the right level of detail and clearly convey the relationship among key anatomical structures. We have been fortunate in this second edition to be able to supplement the Netter illustrations with those from other illustrators to highlight key aspects of structure and function.

## ■ ORGANIZATION

For the physiological component of the book, I adopted a targeted approach to provide essential information that is useful and appropriate for clinical practice. Clear parallels are made between the structure being referenced on the left page and the accompanying Netter illustration on the right. Each section concludes with summary tables featuring key muscles. Core physiological concepts were reviewed and greatly expanded upon in this second edition.

Ease of use was one of my main organizational objectives. Because education is one of the primary purposes of this work, the content reflects the way the anatomy and physiology of speech and swallowing are traditionally taught. It begins with a basic introduction to anatomy

and moves on to a more detailed discussion of the three key systems involved in speech, voice, and swallowing—the respiratory, laryngeal-phonatory, and oropharyngeal-articulatory systems. It concludes by covering fundamental hearing and neurological systems.

## ■ DISTINCTIVE FEATURES

---

- *Full-Color Presentation:* This is the first and only atlas of anatomy specific to speech, swallowing, and hearing to include full-color images, providing maximum detail and accuracy for students and clinicians.
- *Stellar Art Program:* The remarkable, time-honored, and detailed images of renowned illustrator Dr. Frank Netter take center stage in this atlas. Dr. Netter's artwork has been used for years to teach leading healthcare professionals and researchers. Images are presented from various orientations and levels of detail to ensure that readers gain the foundation they need to work with patients who have disorders of speech, swallowing, and hearing.
- *Atlas Format:* Information on targeted anatomical and related physiological mechanisms is found on the left page, with a corresponding image detailing the related anatomy on the right page. This “read-it, see-it” approach appeals to a wide variety of learning styles and makes it ideal for clinical reference.
- *Instruction-Based Organization:* The organization of the sections follows a logical order that is consistent with the way this content is taught in educational programs—an overview of anatomy followed by successive sections detailing the anatomy and related physiology of the respiratory, laryngeal-phonatory, oropharyngeal-articulatory, auditory, and nervous systems—making it an ideal complement to any related courses.
- *Appropriate Depth of Coverage:* The text—often presented in a bulleted-list style for easy reference and comprehension—presents readers with the essential, need-to-know information relevant to speech, swallowing, and hearing mechanisms. This unique and targeted approach provides just the right level of depth and detail to give the artwork proper context.
- *Summary Muscular Tables:* Each section concludes with the relevant musculature of that body system, detailing the origin, insertion, innervation, and action of each. These tables present vital information in a quick, easy, and consistent format ideal for study or quick reference.

## ■ ANCILLARIES

---

A companion Evolve website (<http://evolve.elsevier.com/McFarland/Netter>) has been developed to accompany this book with tools to enhance teaching for instructors and learning for students.

## ■ INSTRUCTOR RESOURCES

---

- *Test Bank:* Approximately 275 objective-style questions—multiple-choice, true/false, fill-in-the-blank, and matching—with accompanying rationales for correct answers and page-number or page-range references for remediation.

## ■ STUDENT RESOURCES

---

- *Self-Test Questions:* Approximately 150 objective-style questions—multiple-choice, true/false, fill-in-the-blank, and matching—are available for examination preparation and accompanied by instant feedback and remediation assistance.
- *Labeling Exercises:* Many of the book's illustrations have been turned into interactive drag-and-drop exercises as a practice tool to help students master the relevant anatomy.

**David H. McFarland**

# ACKNOWLEDGMENTS

I would first like to thank all of the students and professionals worldwide who have shown interest in the first edition of *Anatomy for Speech, Swallowing, and Hearing*. Their enthusiasm led to the publication of this book in several languages, including French (the original language in which it was written), Spanish, Portuguese, Greek, and Chinese.

In this second edition, you will find many new figures illustrating fundamental anatomical and functional concepts. Key physiological processes were extensively reviewed, brought up to date, and greatly expanded. These improvements make this book an even more valuable tool for clinicians, researchers, and students seeking to understand the anatomy and physiology of speech, voice, swallowing, and hearing.

In addition to the numerous collaborators who participated in the first edition of this book, I would like to acknowledge Jolynn Gower, Penny Rudolph, Courtney Sprehe, and Jeanne Genz of Elsevier (USA) for their exceptional editorial and production support. I would also like to thank Professors Jeremy Donai and Patricia Stewart for their reviews of the hearing anatomy and cranial nerve sections of the first edition of the book, respectively. Special thanks go to Professor William G. Pearson for his diligent and expert review of neuroanatomy and muscle structure and function.

Finally, I would like to extend my gratitude to Annie-Joëlle Fortin for her rigorous assistance in the elaboration of this second edition.

I sincerely hope that *Anatomy for Speech, Swallowing, and Hearing* will offer a solid and practical reference for students and professionals in our field for years to come.

**David H. McFarland**

# REVIEWERS

---

## **Jeremy Donai, PhD**

Visiting Assistant Professor  
Communication Sciences and Disorders  
College of Education and Human Services  
West Virginia University  
Morgantown, WV

## **William G. Pearson, PhD**

Assistant Professor  
Department of Cellular Biology and Anatomy  
Department of Otolaryngology  
Medical College of Georgia  
Georgia Regents University  
Augusta, GA

## **Patricia Stewart, PhD**

Professor Emerita  
Faculty of Medicine  
University of Toronto  
Toronto, Canada



# TABLE OF CONTENTS

---

## INTRODUCTION, 1

---

### **ANATOMY, 2**

- Systemic Anatomy, 2
- Regional Anatomy, 2
- Developmental Anatomy, 2
- Functional Anatomy, 2
- Clinical Anatomy, 2

### **NOMENCLATURE, 3**

- Anatomical Position, 3

### **PLANES AND SECTIONS, 4**

- Sagittal, 4
- Frontal or Coronal, 4
- Transverse or Horizontal, 4
- Anatomical Terms, 6
- Superior and Inferior, 6
- Anterior and Posterior, 6
- Medial, Lateral, and Median, 6
- Proximal and Distal, 10
- External, Internal, and Intermediate, 10
- Parietal and Visceral, 10
- Prone and Supine, 10
- Ipsilateral, Contralateral, and Bilateral, 10

### **VIEWS AND ASPECTS, 10**

### **ANATOMICAL MOVEMENT, 12**

- Flexion and Extension, 12
- Abduction and Adduction, 12
- Elevation and Depression, 12
- Protrusion and Retrusion, 12
- Supination and Pronation, 12

### **VOCABULARY SPECIFIC TO**

#### **ANATOMY, 13**

### **PRIMARY TISSUES, 14**

- Epithelial Tissue (Epithelium, Epithelia), 14
- Connective Tissue, 14
- Muscular Tissue, 16
- Nervous Tissue, 16

### **TERMS RELATIVE TO BONES, 17**

- Depressions, 17
- Elevations, 20

## **PART 1: The Respiratory System, 25**

---

### **OVERVIEW, 25**

### **SKELETAL SUPPORT FOR**

#### **RESPIRATION, 26**

- Vertebral Column, 26
- Rib Cage (Ribs, Cartilages, Sternum), 30

Pectoral, Scapular, or Shoulder Girdle, 30

Pelvic Girdle or Bony Pelvis, 32

### **RESPIRATORY TRACT, 34**

- Nasal Cavities, 34
- Oral Cavity, 34
- Pharynx, 34
- Larynx, 34
- Trachea, 38
- Bronchi, 38
- Lungs, 42
- Pleura, 46

### **RESPIRATORY MUSCLES, 48**

- Principal Muscles of Inspiration, 49
- Accessory Muscles of Inspiration, 58
- Muscles of Expiration, 58

### **RESPIRATORY VOLUMES AND**

#### **CAPACITIES, 72**

- Volumes, 72
- Capacities, 72
- Other Functional Measures, 72

## **PART 2: Laryngeal-Phonatory System, 75**

---

### **OVERVIEW, 77**

### **LARYNX, 78**

### **CARTILAGES OF THE LARYNX, 80**

- Thyroid Cartilage, 80
- Cricoid Cartilage, 80
- Arytenoid Cartilages, 80
- Corniculate, or Santorini's, Cartilages, 82
- Cuneiform Cartilages, 82
- Tricteal (Tritiate) Cartilages, 82
- Epiglottis, 82

### **HYOID BONE, 83**

### **TYPES OF JOINTS, 83**

### **LIGAMENTS AND MEMBRANES, 84**

- Extrinsic Ligaments and Membranes, 84
- Intrinsic Ligaments and Membranes, 84

### **VOCAL FOLDS, 86**

- Tissue Layers of the Vocal Folds, 86
- Visual Representation of the Classifications of Vocal Fold Layers, 91

### **MUSCLES OF THE LARYNX, 92**

- Intrinsic Muscles of the Larynx, 92
- Extrinsic Muscles of the Larynx, 96

## **PART 3: Oropharyngeal – Articulatory System, 107**

---

### **OVERVIEW, 109**

### **CRANIAL ANATOMY, 110**

Cranium, 110

Facial Skeleton, 114

Sinuses, 118

### **VOCAL TRACT, 119**

Pharyngeal Cavity, 119

Nasal Cavities, 122

Oral Cavity, 124

Tonsils, 126

Palate, 126

Tongue, 126

Salivary Glands, 128

Lips, 128

Teeth, 130

### **MUSCLES OF THE LIPS AND FACIAL EXPRESSION, 134**

Orbicularis Oris Muscle, 134

Two Transverse Muscles, 134

Five Angular Muscles, 136

Three Vertical Muscles, 138

### **ONE MUSCLE OF THE NECK, 139**

Platysma Muscle, 139

### **MUSCLES OF THE TONGUE, 140**

Intrinsic Muscles of the Tongue, 140

Extrinsic Muscles of the Tongue, 142

### **MUSCLES OF MASTICATION, 144**

Temporomandibular Joint, 144

Three Jaw-Closing Muscles (Jaw Elevators), 146

Four Jaw-Opening Muscles (Jaw Depressors),  
148

### **MUSCLES OF THE SOFT PALATE, 152**

Levator Veli Palatini Muscle, 152

Tensor Veli Palatini Muscle, 152

Palatoglossus (Glossopalatine) Muscle, 154

Palatopharyngeus Muscle, 154

Uvular Muscle (Musculus Uvulae), 154

### **MUSCLES OF THE PHARYNX, 155**

Superior Pharyngeal Constrictor Muscle, 155

Middle Pharyngeal Constrictor Muscle, 155

Inferior Pharyngeal Constrictor Muscle, 155

Salpingopharyngeus Muscle, 157

Stylopharyngeus Muscle, 157

Velopharyngeal Mechanism, 157

### **ESOPHAGUS, 160**

Upper Esophageal, or Inferior Pharyngeal,  
Sphincter, 160

Primary Esophageal Peristalsis, 160

Lower Esophageal Sphincter, 160

## **PART 4: Auditory System, 171**

---

### **OVERVIEW, 173**

### **ANATOMICAL DIVISIONS OF**

#### **THE EAR, 174**

Outer Ear, 176

Middle Ear, 180

Inner Ear: Cochlea and Vestibular System, 186

Scala Media, or Cochlear Duct, 192

### **COCHLEAR AFFERENT AND**

#### **EFFERENT INNERVATION, 196**

Afferent Innervation, 196

Afferent Central Auditory Pathway, 197

Efferent Central Auditory Pathway (Auditory  
Centrifugal Pathway), 200

## **PART 5: Nervous System, 201**

---

### **OVERVIEW, 203**

### **NEUROANATOMICAL TERMS OF**

#### **DIRECTION, 204**

### **TELENCEPHALON (CEREBRAL**

#### **HEMISPHERES OR CEREBRUM**

#### **AND BASAL GANGLIA), 205**

Surface Structures, 205

Internal Structures of the Cerebral

Hemispheres, 212

Basal Ganglia, 212

### **DIENCEPHALON (THALAMUS,**

#### **HYPOTHALAMUS, EPITHALAMUS,**

#### **AND SUBTHALAMUS), 214**

Characteristic Features, 214

Importance for Speech and Swallowing, 214

### **MESENCEPHALON (MIDBRAIN), 215**

Characteristic Features, 215

Importance for Speech and Swallowing, 215

### **METENCEPHALON (PONS AND**

#### **CEREBELLUM), 216**

Characteristic Features, 216

Importance for Speech and Swallowing, 216

### **MYELENCEPHALON (MEDULLA**

#### **OBLONGATA), 216**

Characteristic Features, 216

Importance for Speech and Swallowing, 216

Brainstem Pattern-Generating Circuitry, 216

### **SPINAL CORD, 218**

Characteristic Features, 218

Internal Structures, 218

### **CEREBELLUM, 220**

Characteristic Features, 220

**MENINGES, 224**

Dura Mater, 224

Arachnoid Mater, 224

Pia Mater, 224

**CEREBROSPINAL FLUID, 226****CEREBRAL VASCULATURE, 229****CRANIAL NERVES, 234**

Types of Cranial Nerve Fibers, 236

I Olfactory (Sensory), 238

II Optic (Sensory), 238

III Oculomotor (Motor), 239

IV Trochlear (Motor), 239

V Trigeminal (Motor and Sensory), 240

VI Abducens (Motor), 242

VII Facial (Motor and Sensory), 242

VIII Vestibulocochlear (Sensory), 244

IX Glossopharyngeal (Motor and Sensory),  
246X Vagus, or Pneumogastric, Nerve (Motor  
and Sensory), 248

XI Accessory (Motor), 250

XII Hypoglossal (Motor), 252

This page intentionally left blank

# INTRODUCTION

Speech differs from many other skilled human movements in that the goal is not to move the body or interact with an object but to communicate. It has been estimated that we may produce up to 15 speech sounds per second, which may require the activity of approximately 100 muscles distributed across the different physiological systems involved in speech production, including the respiratory, laryngeal, and oral-articulatory systems. The use of these different systems makes speech production one of the most complex of all human skilled movements. The underlying neural control processes are similarly complex and involve several hierarchically organized cortical and subcortical structures interacting with sensory feedback from peripheral speech structures. Swallowing uses many of these same complex anatomical and neural control processes involved in speech production.

The goal of this book is to summarize our current understanding of the anatomical basis of normal speech and swallowing function and to provide a platform for the diagnosis and treatment of disorders of these vital behaviors. Physiology is briefly summarized because structure and function are intimately related and are only artificially separated in this book to simplify learning.

This book is organized around the pioneering medical illustrations of Frank M. Netter. Anatomical descriptions are presented with specific reference to these classic illustrations, and the relevant structures are highlighted. Understanding anatomy requires a visual representation of structure from various orientations, and Netter's figures provide this thorough perspective. Summary tables of muscle origin, insertion, innervation, and function are provided throughout. In this second edition, figures from other talented illustrators have been added to highlight key structure and function.

We begin with an overview of anatomical classification systems, a summary of anatomical nomenclature, a list of the terms used to describe direction and movement, and a description of the different types of anatomical tissues. We continue with descriptions of the respiratory, laryngeal, and oropharyngeal structures and end with hearing anatomy and key neurological systems involved in the control and coordination of speech and swallowing movements.

The study of anatomy is one of the oldest medical sciences, and its origins can be traced back to at least the early Greeks. You are embarking on this grand and noble tradition in the study of human anatomical principles.

## ■ ANATOMY

---

There are many ways of classifying and consequently studying anatomy. Some of these are described in the next sections. This book uses many of these methods to cover the following aspects of anatomy in relation to speech, swallowing, and hearing:

- The normal structure of organs and systems
- The topographical or anatomical relationships between structures
- The function of anatomical structures
- The development of anatomical structures and systems
- The neurological aspects of a structure's normal function
- Certain clinical aspects of disordered function

### **Systemic Anatomy**

Systemic anatomy classifies the body by biological systems and sub-systems. The major systems include the integumentary system, the musculoskeletal system, the nervous system, the circulatory system, the respiratory system, the digestive system, the urinary system, the reproductive system and the endocrine system.

### **Regional Anatomy**

Regional anatomy emphasizes the different regions or divisions of the body and the relationship between the anatomical structures of those divisions. The typical regions are as follows:

- Head and neck
- Back and extremities
- Thorax
- Abdomen
- Pelvis

### **Developmental Anatomy**

Developmental anatomy concerns the prenatal and postnatal development of anatomical structures.

### **Functional Anatomy**

Functional anatomy classifies the relationship between a structure and its function, combining anatomy and physiology.

### **Clinical Anatomy**

Clinical anatomy emphasizes the relationship between anatomy and medical or other clinical practice.



## ■ NOMENCLATURE

---

Before beginning to discuss the human body, it is important to know the terms most frequently used by anatomists to describe a structure and its location. These terms greatly facilitate the understanding and study of anatomy.

### **Anatomical Position** (see [Figure 1](#) [p. 5])

All structures are described in relationship to a standard position, which is called the *anatomical position*. In *humans*,\* the anatomical position is standing, facing the observer, arms along the body, palms turned forward, legs together or slightly separated, and feet straight ahead.

---

\*Because most nonhuman animals are on all fours, their anatomical position and terms of direction are different from those for humans. This should be kept in mind when comparing nonhuman with human anatomy.

## ■ PLANES AND SECTIONS

---

The body is described relative to different planes of orientation, and these can give rise to different sections or imaginary points of dissection. The three standard anatomical reference planes are as follows (Figure 1):

### **Sagittal**

The sagittal plane is a longitudinal plane or section that is parallel to the sagittal suture of the skull. To visualize this plane, imagine a sheet of paper aligned vertically between your eyes. All sagittal sections are parallel to this sheet. The *median* or *midsagittal* plane or section is the sagittal plane or section that divides the body into two equal left and right halves. All other sagittal planes or sections are termed *parasagittal*, or just *sagittal*.

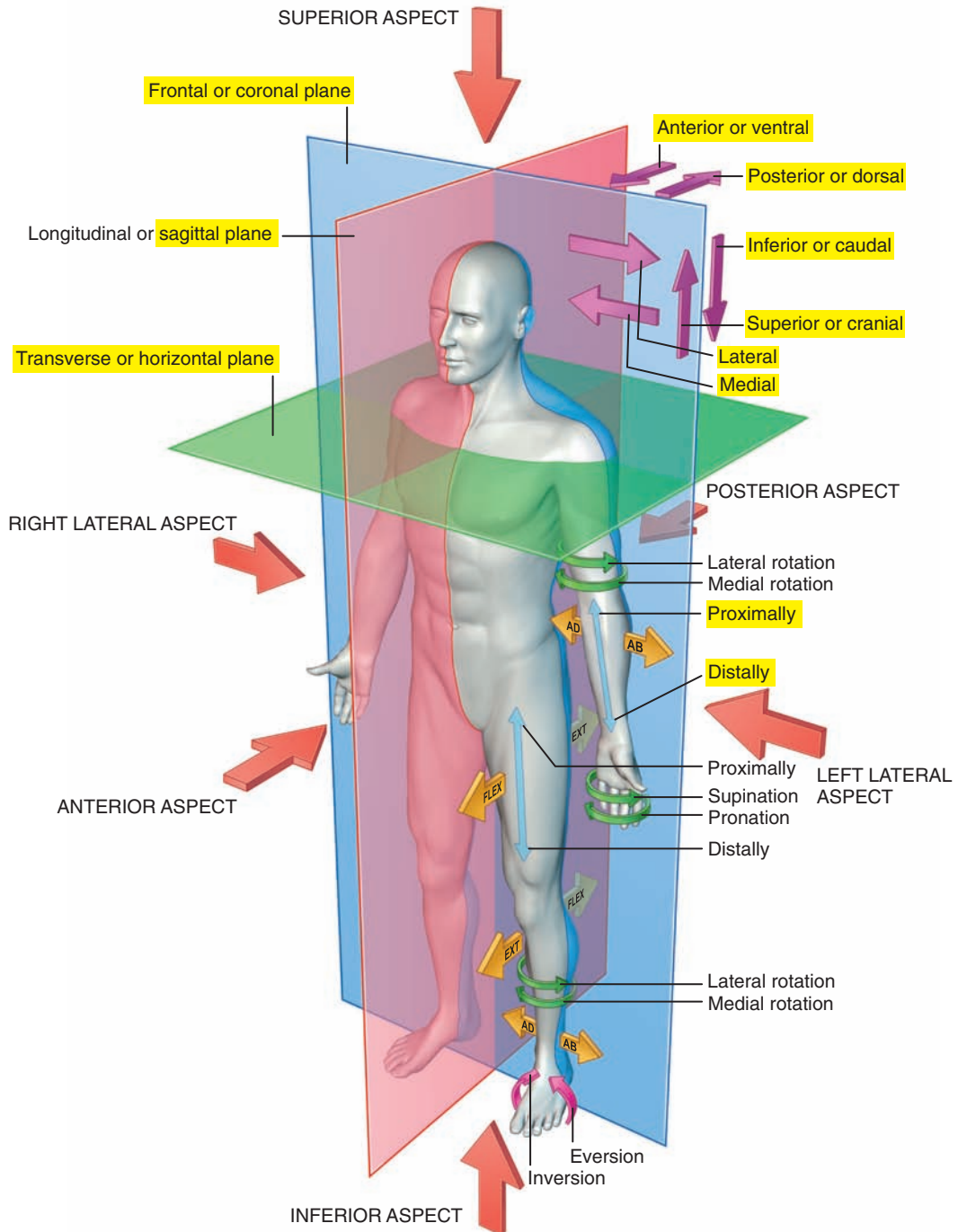
### **Frontal or Coronal**

The frontal, or coronal, plane is a longitudinal plane or section that crosses the sagittal plane at a right angle. To visualize this plane, imagine holding a piece of paper directly in front of you and parallel to the coronal or frontal suture of the cranium. All frontal sections will be parallel to this sheet. Coronal planes or sections divide the body front to back (anteriorly to posteriorly). The terms *midfrontal* or *midcoronal* are sometimes used to designate planes or sections that divide the body into equal anterior and posterior halves.

### **Transverse or Horizontal**

The transverse, or horizontal, plane divides the body or structure into superior/inferior portions or sections. To visualize this plane, imagine a sheet of paper placed horizontally in front of your face that divides your head into upper and lower halves. All transverse sections are parallel to this sheet. The term *midtransverse* is used to designate the plane dividing the body into two equal superior and inferior halves.

NOTE: An oblique plane or section is oriented obliquely between one of the planes described here.



**Figure 1.** Anatomical position, terms of relationships, and body planes. (From Standing S: *Gray's anatomy: the anatomical basis of clinical practice*, ed 39, Edinburgh, 2005, Churchill Livingstone.)

NOTE: Labels of certain figures are highlighted in yellow to emphasize the related elements in the corresponding text.

## ■ ANATOMICAL TERMS

---

Directional terms are used to locate anatomical structures and to explain the spatial relationship between structures relative to the anatomical position. They are presented in contrasting pairs (see [Figure 1](#) [p. 5]).

### **Superior and Inferior** ([Figure 2](#))

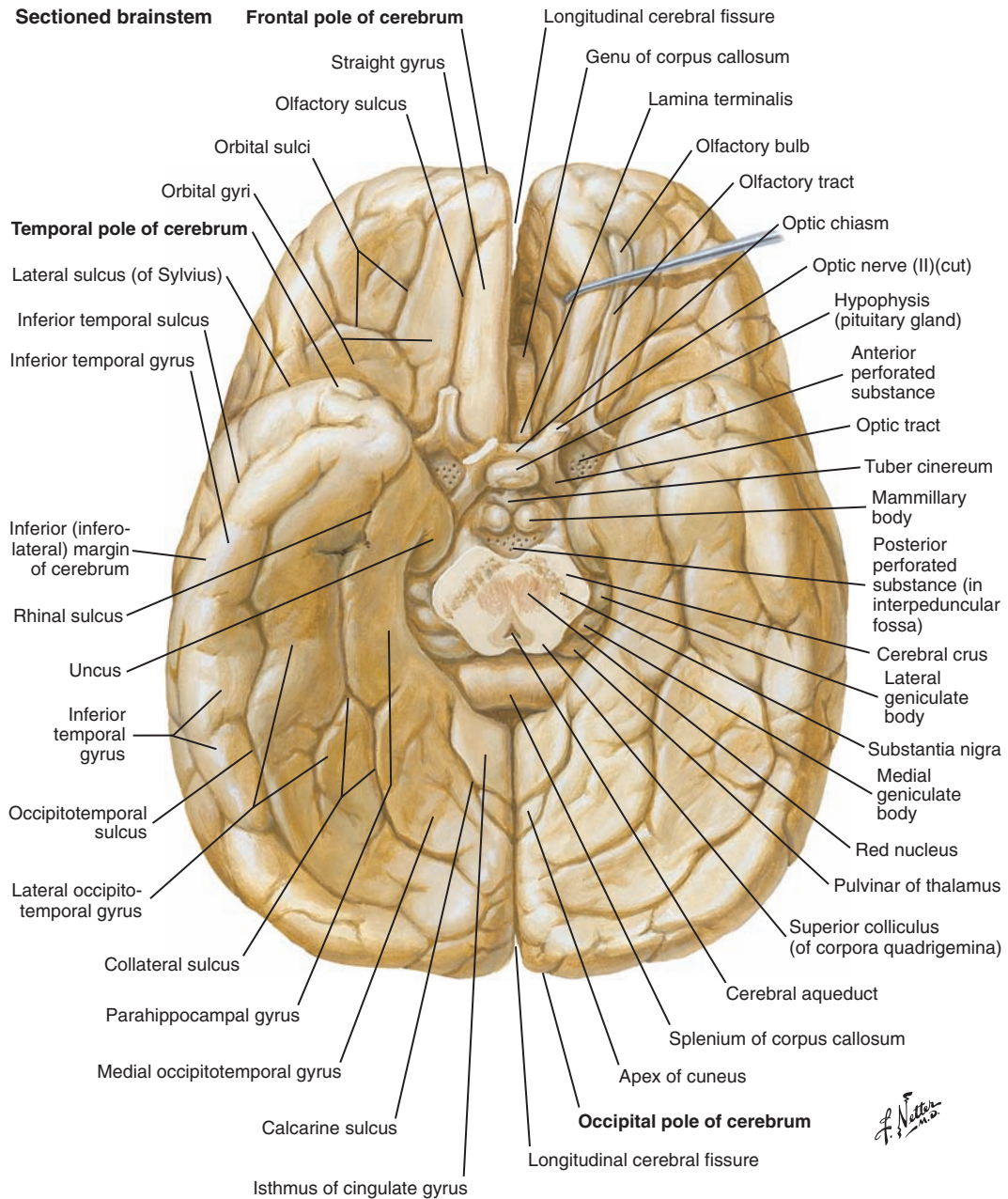
- Superior (rostral, cranial) is toward the upper portion or located above a structure of the body.
- Inferior (caudal) is toward the lower portion or below a structure of the body.

### **Anterior and Posterior** ([Figure 3](#) [p. 8])

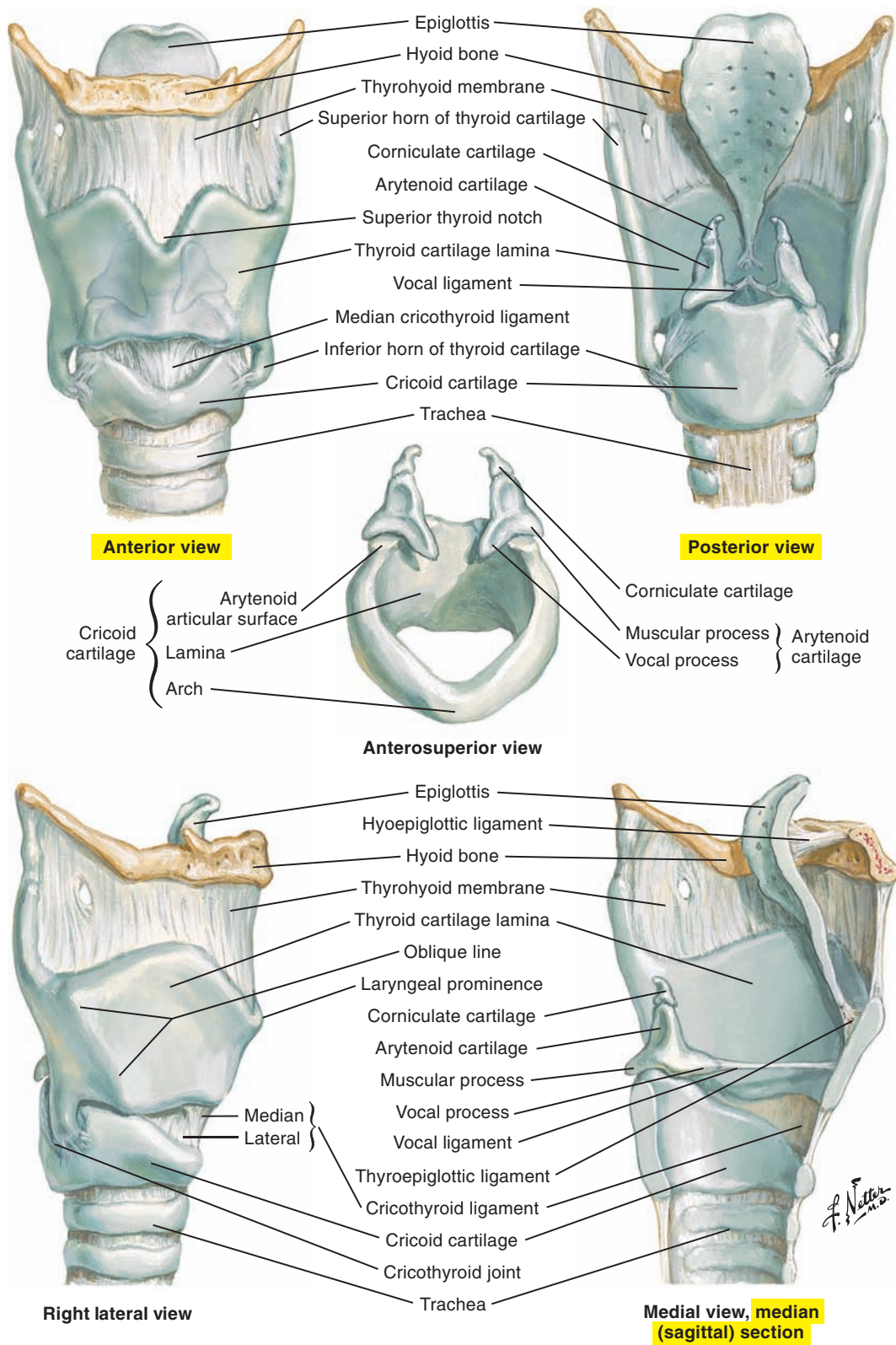
- Anterior (ventral) is toward the front or in front of a structure of the body.
- Posterior (dorsal) is toward the back or behind a structure of the body.

### **Medial, Lateral, and Median** ([Figure 4](#) [p. 9])

- Medial is toward the midline, or central axis, of the body.
- Lateral is away from the central axis, or midline, of the body.
- Median is on the central sagittal plane.

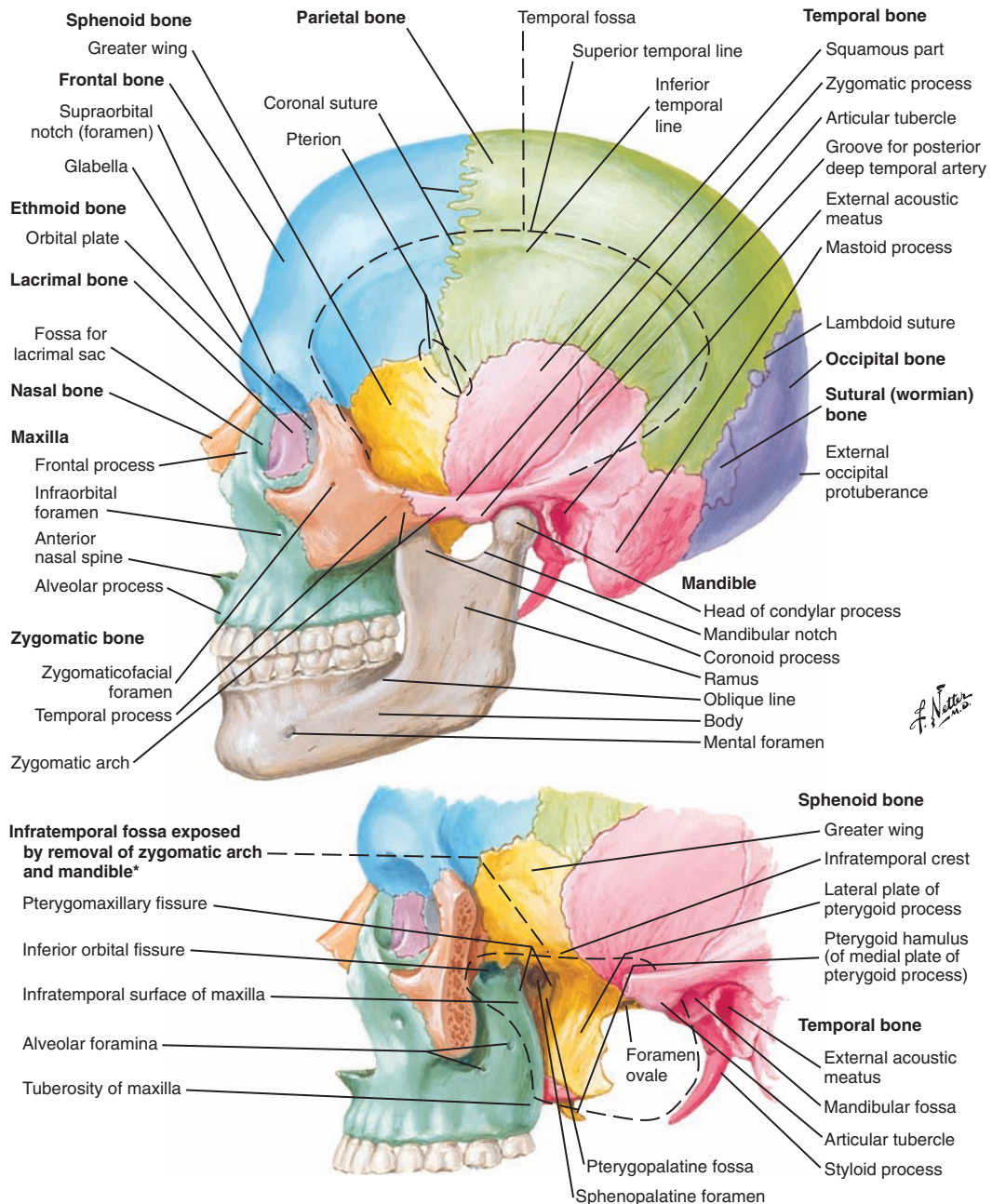


**Figure 2.** Inferior view of the cerebrum.



**Figure 3.** Anterior and posterior views of the cartilages of the larynx.





\*Superficially, mastoid process forms posterior boundary.

**Figure 4.** Lateral view of the skull.

**Proximal and Distal**

- Proximal is toward the origin of a structure of the body.
- Distal is away from the origin of a structure of the body. Proximal and distal are often used to describe the limbs.

**External, Internal, and Intermediate**

- External (superficial) is toward the surface of a structure of the body.
- Internal (deep) is away from the surface of a structure of the body.
- Intermediate (middle) is between internal and external.

These terms are often used to describe anatomical relationships between structures, such as one structure being deep to or superficial to another.

**Parietal and Visceral (Figure 5)**

- Parietal is the outer layer or covering of a body cavity.
- Visceral is the inner layer of a cavity wrapped around body organs.

**Prone and Supine**

- Prone is the anatomical position of the body with the face and ventral surface of the body facing down.
- Supine is the anatomical position of the body with the face and ventral surface of the body facing up.

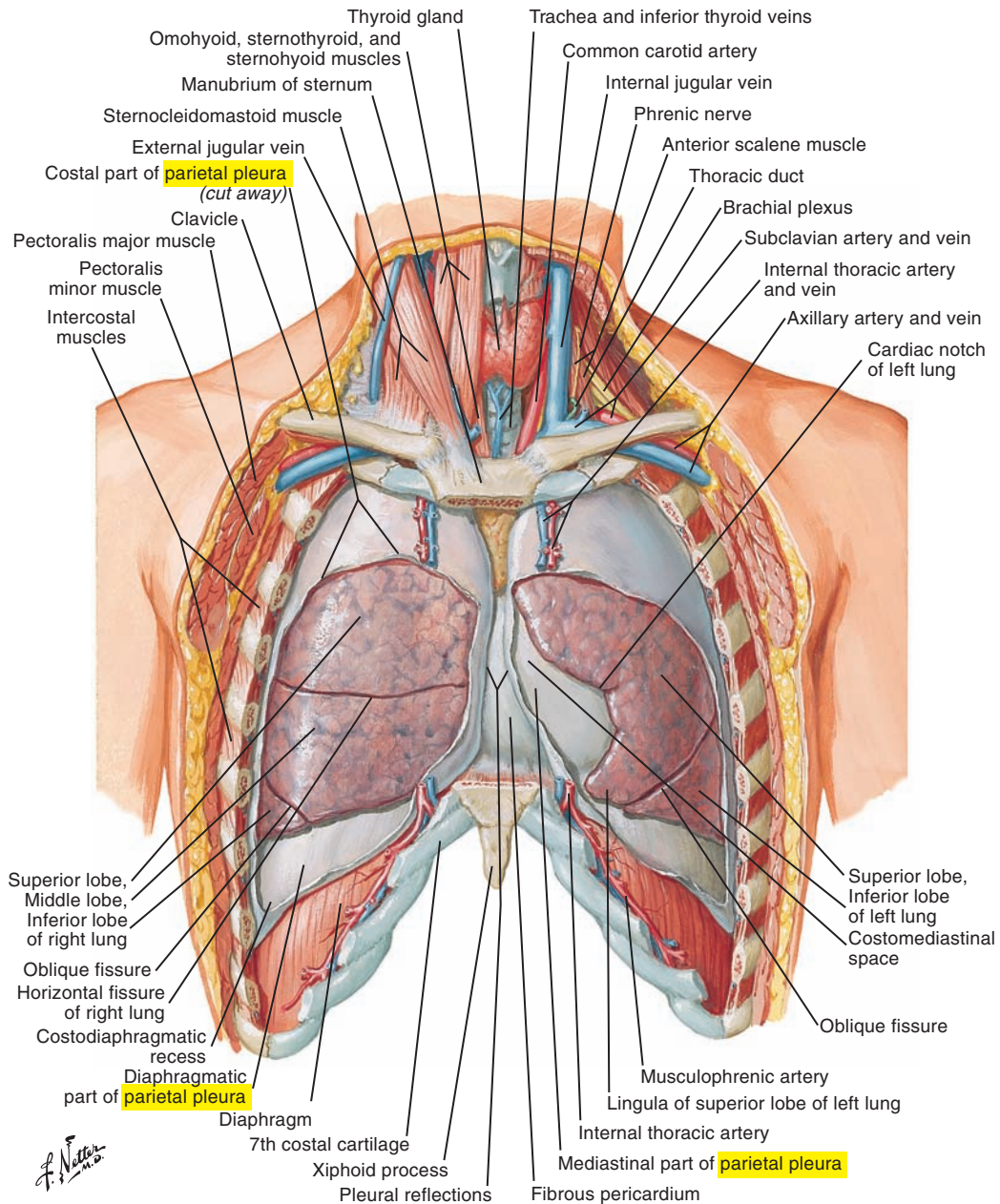
**Ipsilateral, Contralateral, and Bilateral**

- Ipsilateral refers to the same side of the body.
- Contralateral refers to the opposite side of the body.
- Bilateral refers to both sides of the body.

**■ VIEWS AND ASPECTS**

---

Anatomy requires the visualization of structures from different perspectives. The terms view, aspect, and surface are used to describe these orientations. For example, an anterior view is when the observer is positioned anteriorly and looking posteriorly at a structure. An anterior aspect or surface of the structure would be in view (see [Figures 1 \[p. 5\] and 5](#)).



**Figure 5.** Anterior view of the lungs in situ. Note the parietal pleura.

## ■ ANATOMICAL MOVEMENT

---

As with terms of direction, anatomical movements are usually described in contrasting pairs. Each pair is detailed in the following sections (see also [Figure 1](#) [p. 5]).

### **Flexion and Extension**

- Flexion is the movement around a joint that brings two adjacent bones or body segments closer together, reducing the angle of articulation.
- Extension is the movement around a joint that brings two adjacent bones or body segments farther apart, increasing the angle of articulation.

### **Abduction and Adduction**

- Abduction is the movement of a structure away from the midline.
- Adduction is the movement of a structure toward the midline.

### **Elevation and Depression**

- Elevation is the upward movement of a structure.
- Depression is the downward movement of a structure.

### **Protrusion and Retrusion**

- Protrusion (protraction) is the forward movement of a structure.
- Retrusion (retraction) is the backward movement of a structure.

### **Supination and Pronation**

Supination and pronation refer to rotational movements of certain structures such as the arm and hand:

- Supination refers to the rotation of the arm and hand so that the palm is facing anteriorly (with arm straight) or upward (with arm bent).
- Pronation refers to the rotation of the arm and hand so that the palm is facing posteriorly (with arm straight) or downward (with arm bent).

## ■ VOCABULARY SPECIFIC TO ANATOMY

---

Many structures are named according to either their anatomical location on the body (e.g., external intercostal muscles, supra glottic, and so on) or their function (e.g., levator scapulae muscle, depressor anguli oris muscle, and so on). In addition to their anatomical name, other structures have names originating from mythology (e.g., Achilles tendon) or from the first person who associated the structure to a disease or a malformation or the first person who described the structure (e.g., circle of Willis).

Names of muscles and ligaments may also correspond to their points of attachment, as follows:

- Origin corresponds to the point of attachment of a muscle that remains relatively fixed during muscular contraction.
- Insertion corresponds to the more mobile point of attachment.

In general, the origin is named first and the insertion second. Sometimes, origin and insertion can be interchanged (insertion first and origin second) if both are considered of equal mobility. Muscle names may also provide information about the form of the muscle such as the number of bellies or portions of the muscle (e.g., *digastric*, or two bellies), its overall shape or location (e.g., *external* intercostals), or its action (e.g., *tensor* veli palatini).

## ■ PRIMARY TISSUES

---

Tissues are groups of cells with similar structure that perform a common function. The four primary tissue groups are as follows:

1. Epithelial
2. Connective
3. Muscular
4. Nervous

### **Epithelial Tissue (Epithelium, Epithelia)**

Epithelia cover surfaces of the body and the body cavities of different systems (respiratory, digestive, cardiac, and vascular systems). This group of tissue performs the following functions:

- Protection
- Absorption and filtration
- Excretion and secretion
- Sensation

### **Connective Tissue**

Connective tissue is a key component (with muscles and the skeleton) of the musculoskeletal system. It is widespread in the human body, and its principal functions are as follows:

- Fixation and support
- Protection
- Energy reserve
- Transportation of fluids and other substances

Connective tissue can be solid, liquid, or gelatinous and can be classified in several different ways. The following four categories and respective subdivisions are used throughout the atlas: (1) connective tissue proper, (2) specialized connective tissues, (3) osseous tissue, and (4) blood.



**Connective Tissue Proper**

- **Loose (areolar)** connective tissue is a supple and gelatinous tissue formed of collagen and elastin fibers that surrounds and forms a cushion for organs and other body structures.
- **Adipose** connective tissue is composed of adipose cells and stores fat, protects and supports certain organs, and acts as an insulator.
- **Dense** connective tissue. Although the following classification system is often used, dense connective tissue types (together with elastic tissues) are more of a continuum than discrete entities.
  - **Dense regular** connective tissue is composed primarily of collagen fibers and some elastic fibers that follow a parallel orientation. It interconnects and supports body structures. Collagen fibers are quite stiff relative to elastic fibers and take longer to recover from deformation (like stretch). Tendons, ligaments, fascia, and aponeuroses are composed of dense regular connective tissue.
  - **Dense irregular** connective tissue is principally composed of collagen fibers with no specific orientation. Its function is to reinforce and protect. Dense irregular connective tissue is found in the deep fascia of the body and the dermis (skin).
- **Elastic** connective tissue has a high concentration of elastic fibers (elastin and others), and this tissue recovers from deformation (stretch) very quickly, like an elastic band. Such tissues are found in the bronchial tree and larynx including the vocal ligament of the vocal folds.

**Specialized Connective Tissues****Cartilage (see [Figure 3](#) [p. 8])**

- **Hyaline** cartilage is the most common cartilage. It contains collagen fibers and provides strength and flexibility. Some examples are costal, nasal, tracheal, and most laryngeal cartilages.
- **Elastic** cartilage is similar to hyaline cartilage but contains more elastic fibers and is thus more flexible. Some examples are the external ear, eustachian tube, epiglottis, and cuneiform and corniculate cartilages.
- **Fibrocartilage** is composed of dense collagen fibers and provides strength and shock absorption. Examples are the intervertebral discs.

More detail is provided on the following types of connective tissues that appear frequently in the atlas:

- **Membranes** are layers of epithelial and/or connective tissue that cover and protect body cavities and other surfaces. There are four types of membranes: mucous, serous, synovial, and cutaneous.
- **Tendons** are strong bands of dense regular connective tissue that connect skeletal muscle to bone. Tendons are flexible but resist extension (stretch). They are supplied with important sensory nerve endings, the Golgi tendon organs.
- **Aponeuroses** are broad tendinous-like sheets that cover muscle or are the points of origin or insertion of skeletal muscle.
- **Ligaments** are strong bands of dense regular connective tissue that connect bone to bone, cartilage to cartilage, and cartilage to bone. Ligaments are slightly elastic (“stretchy”) and lengthen under tension.
- **Fascia** is connective tissue that covers and groups anatomical structures (muscles and organs) and also serves as a point of attachment of some muscles.

#### Osseous Tissue

Osseous tissue is hard and rigid tissue that is composed of collagen fibers and minerals. Bones produce red and white blood cells, store minerals, support the body, protect vital organs, and provide skeletal support for movement. They also serve a sound transmission role in bone-conducted hearing.

#### Blood

Although a fluid, blood is classified as a specialized connective tissue. It is composed of red blood cells, white blood cells, and platelets suspended in plasma. It transports respiratory gases, nutrients, and other substances crucial for normal body functions.

#### Muscular Tissue

- **Skeletal** muscles are composed of striated muscle fibers and are involved in the production of movements.
- **Cardiac** muscles are composed of striated cells and have involuntary control of the heart.
- **Smooth** muscles are composed of nonstriated cells and are involved in the involuntary control of body organs.

#### Nervous Tissue

The nervous system is composed of the following types of nervous tissue:

- Neurons are specialized cells that conduct nerve impulses.
- Glial cells are nonconducting cells that support, insulate, and protect neurons.

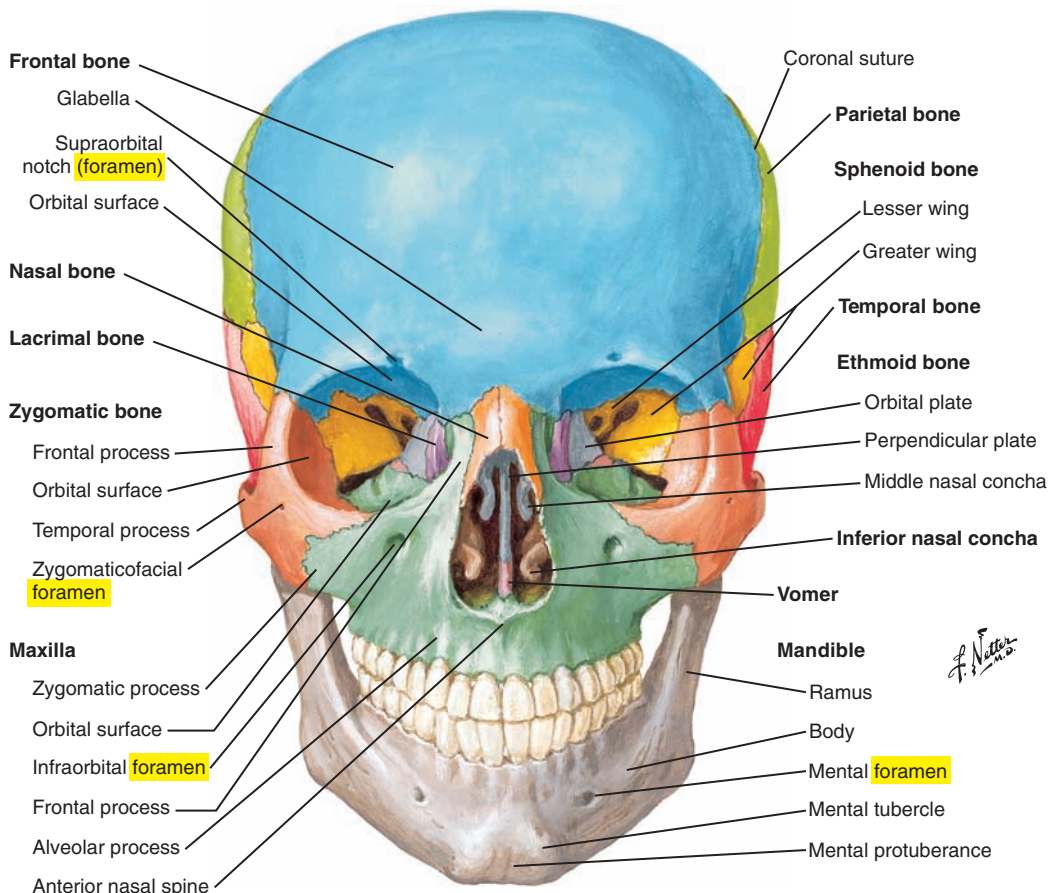
## ■ TERMS RELATIVE TO BONES

Terms relative to bones are classified into the following categories:

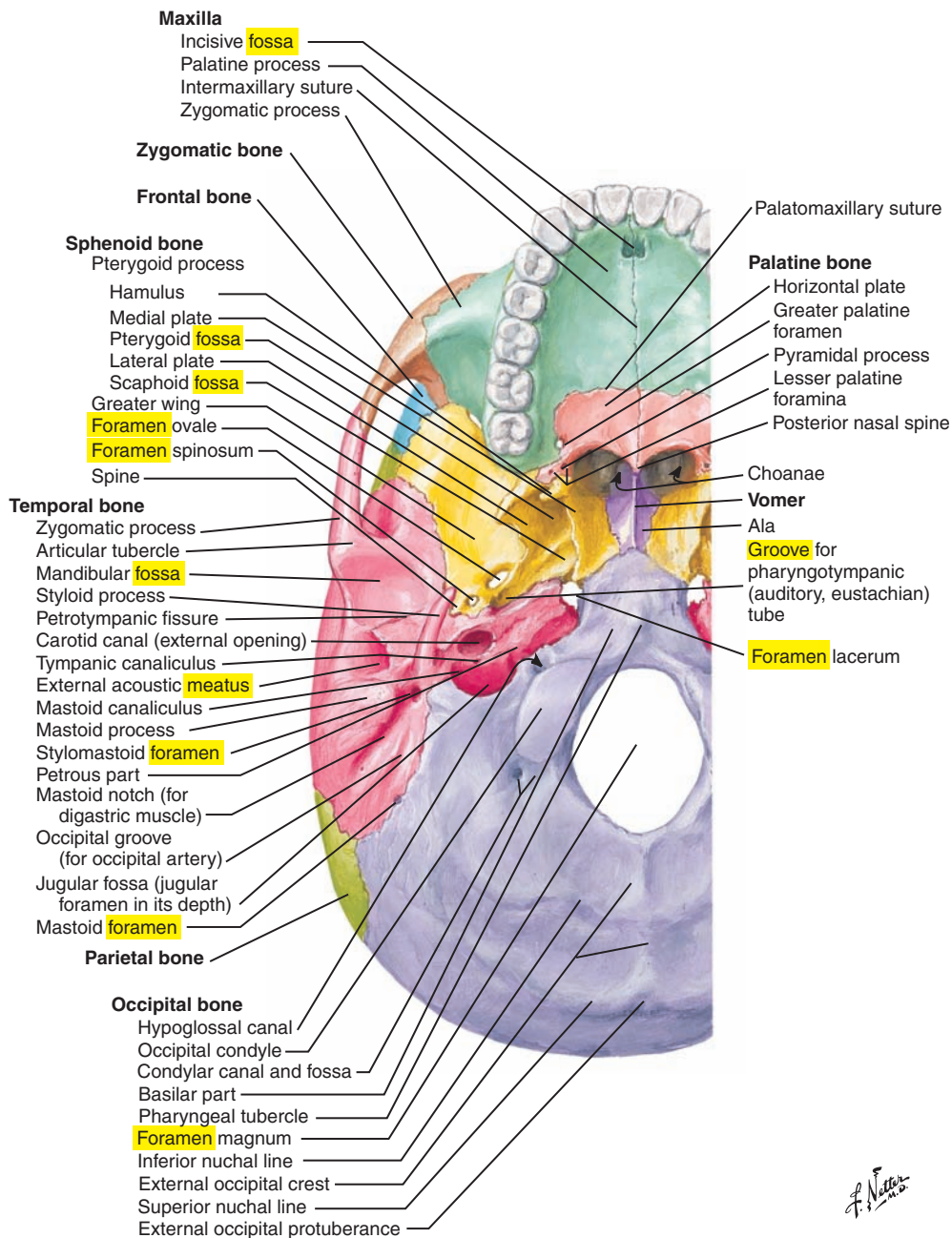
1. Depressions
2. Elevations

### Depressions

- A fissure is a cleft.
- A foramen is a natural opening (Figure 6; see also Figure 7 [p. 18]).
- A fossa is a depression (Figure 7 [p. 18]).
- A groove is a furrow (Figure 7 [p. 18]).
- A meatus is a passageway (see Figures 7 [p. 18] and 8 [p. 19]).
- A sinus is a cavity (Figure 8 [p. 19]).

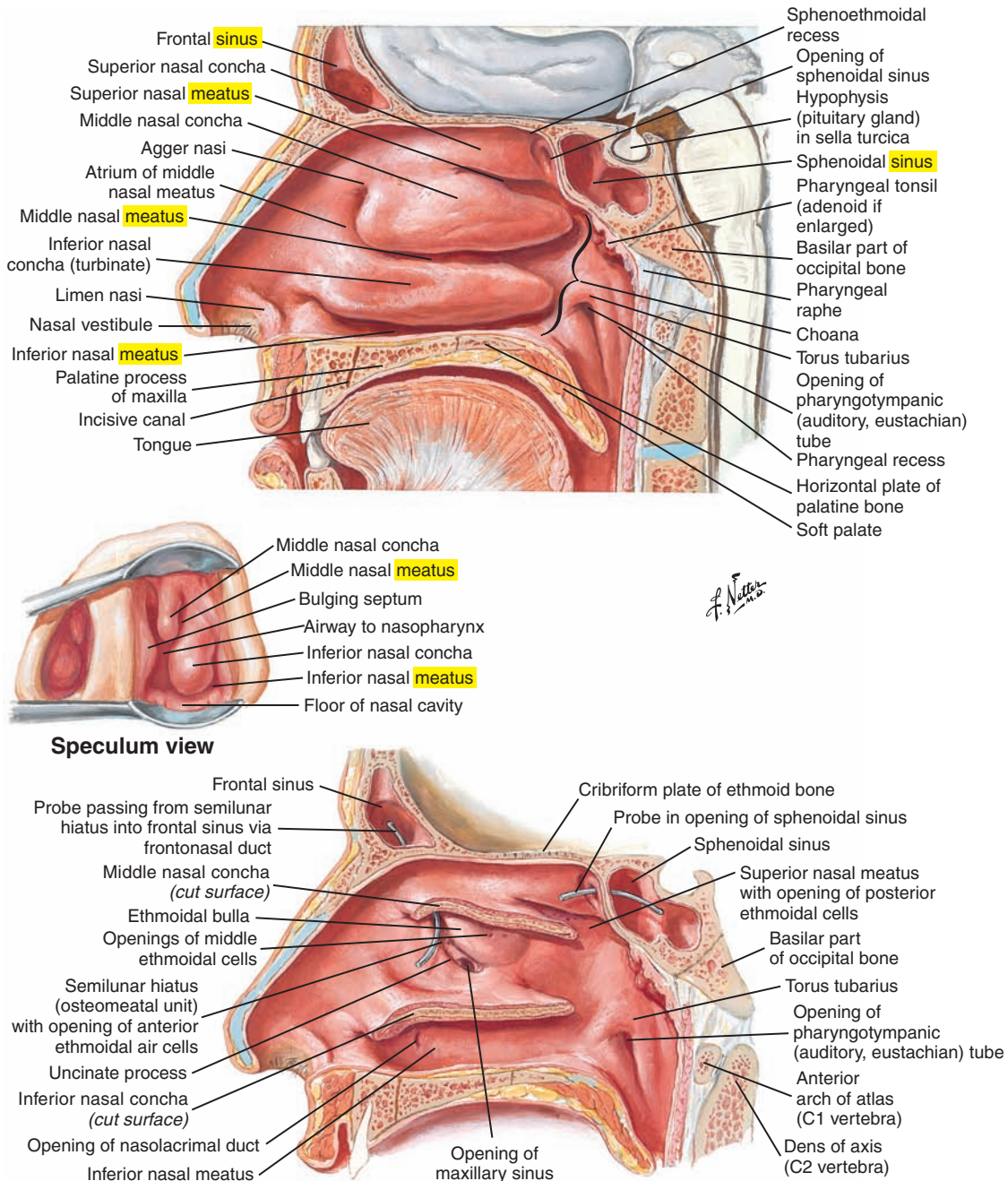


**Figure 6.** Anterior view of the skull, showing examples of the foramen, tubercle, and protuberance.



**Figure 7.** Inferior view of the cranial base. Note the fossa, foramen, meatus, and groove.

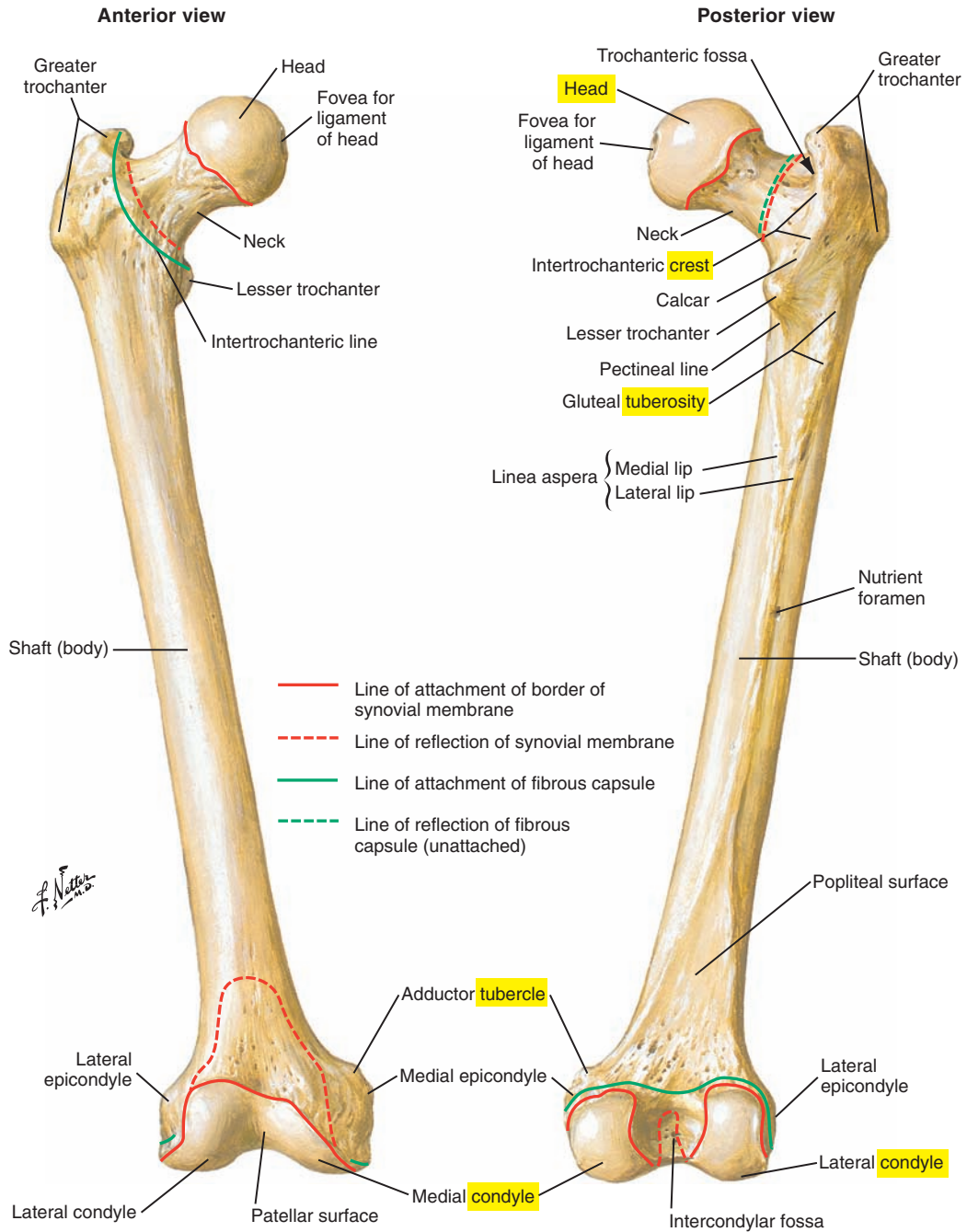




**Figure 8.** Lateral wall of the nasal cavity showing examples of a sinus and meatus.

**Elevations**

- A condyle is a rounded point of articulation ([Figure 9](#)).
- A crest is a ridge (see [Figure 9](#)).
- A head is an enlargement of the extremity of a bone (see [Figure 9](#)).
- A process is a prominence or extension (see also [Figure 7](#) [p. 18]).
- A protuberance is a projection beyond the surface.
- A spine is a spike-shaped projection.
- A tubercle is a small, rounded protuberance (see [Figure 9](#); see also [Figure 6](#) [p. 17]).
- A tuberosity is a larger, rounded protuberance (see [Figure 9](#)).



**Figure 9.** Anterior and posterior views of the femur. Note the condyle, crest, head, tubercle, and tuberosity.



This page intentionally left blank

# RESPIRATORY SYSTEM

**Overview, 25****Skeletal Support for Respiration, 26**

Vertebral Column, 26

Rib Cage (Ribs, Cartilages, Sternum), 30

Pectoral, Scapular, or Shoulder Girdle, 30

**Pelvic Girdle or Bony Pelvis, 32**

**Respiratory Tract, 34**

Nasal Cavities, 34

Oral Cavity, 34

Pharynx, 34

Larynx, 34

Trachea, 38

Bronchi, 38

Lungs, 42

**Pleura, 46**

**Respiratory Muscles, 48**

Principal Muscles of Inspiration, 49

Accessory Muscles of Inspiration, 58

**Principal Muscles of Expiration, 58**

**Respiratory Volumes and Capacities, 72**

Volumes, 72

Capacities, 72

Other Functional Measures, 72

This page intentionally left blank

## ■ OVERVIEW

---

The respiratory system is vital for the elimination of carbon dioxide and the absorption of oxygen. Superimposed on this primary biological function is the use of the respiratory system for speech production. The respiratory system is the source of energy for vocal fold vibration and consonant production by the oral articulators.

For speech production, the pressure beneath the closed vocal folds (subglottal pressure) is maintained within a relatively narrow range. The maintenance of a relatively constant subglottal pressure requires a complex interaction between the forces generated by the passive mechanical properties of the lungs and thorax and those generated by active muscular contraction. Even though subglottal pressure is maintained relatively constant for vocal fold vibration, it is possible to modulate this pressure up or down for changes in loudness (intensity) or pitch (fundamental frequency).

Inspirations during speech are rapid to avoid interruptions to the flow of speech and terminate at slightly higher lung volumes than those associated with quiet breathing. Expirations are prolonged, and because we speak during the expiratory phase, their duration is influenced by communication demands.

For swallowing, the precise coordination of respiratory and swallowing processes ensures adequate airway protection. The airway is protected during swallowing because the food or liquid bolus and air share a common passageway and aspiration must be prevented. Airway protective mechanisms during swallowing include respiratory inhibition, vocal fold closure, laryngeal elevation, and velopharyngeal closure.

The respiratory system is the topic of Part 1, beginning with a brief overview of the skeletal support for respiration and then addressing the lungs and associated respiratory structures. Finally, respiratory muscles and their functions are reviewed.

## ■ SKELETAL SUPPORT FOR RESPIRATION

---

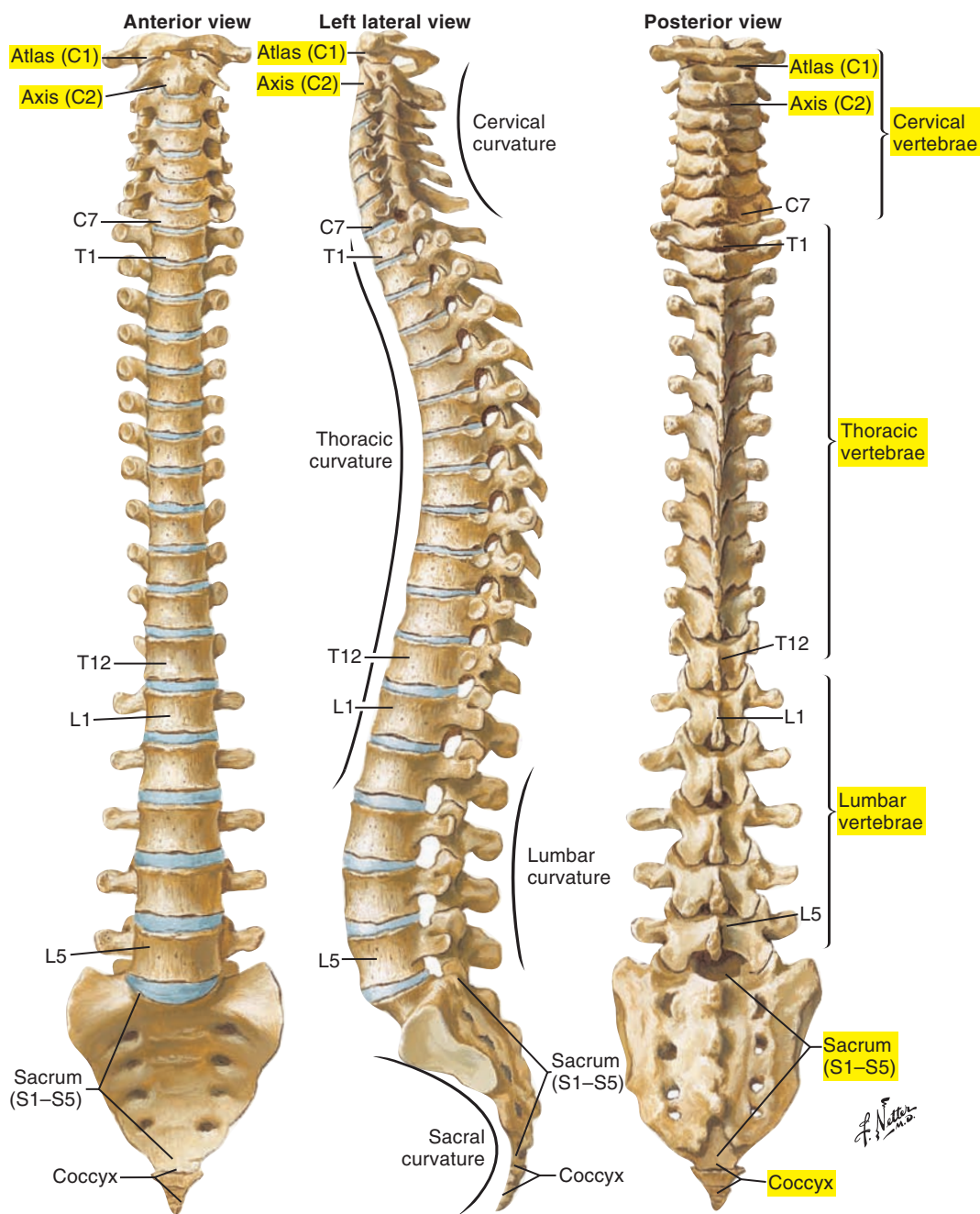
Skeletal support for respiration is composed of the following elements (see [Figures 1-3](#) [p. 31] and [1-4](#) [p. 33]):

- Posteriorly by the vertebral column
- Anteriorly by the sternum and cartilages
- Laterally by the ribs
- Superiorly by the scapular girdle
- Inferiorly by the pelvic girdle

### **Vertebral Column** ([Figure 1-1](#))

The vertebral column contains 32 to 33 vertebrae that are numbered superiorly to inferiorly in 5 regions, as follows:

- 7 cervical vertebrae
- 12 thoracic vertebrae (that articulate with 12 ribs)
- 5 lumbar vertebrae
- 5 sacral vertebrae
- 3 to 4 coccygeal vertebrae



**Figure 1-1.** The vertebral column.

NOTE: Labels of certain figures are highlighted in yellow to emphasize the related elements in the corresponding text.

A typical thoracic vertebra contains the following elements ([Figure 1-2](#)):

- Vertebral body
  - Vertebral foramen (canal for the spinal cord)
  - Four articular processes where adjacent vertebrae connect (to *articulate* means to “come closer and form a junction”)
  - Superior, inferior, and transverse costal facets, which are points of attachment of the ribs
  - Transverse processes, which are points of attachment of muscles and ligaments
  - A spinous process, which is the site of attachment of muscles and ligaments
- Refer to [Figure 1-1](#) (p. 27) to see the following:
- Note the change in the form of the vertebrae. Inferior vertebrae are more massive to support more weight.
  - The vertebral column contains four curves (cervical, thoracic, lumbar, and sacral). These curves give a double **S** shape to the vertebral column and increase its strength and flexibility to support body weight and movement.
  - Two cervical vertebrae have anatomical and functional characteristics that are different from the other vertebrae. The first cervical vertebra (C1), or atlas (after Greek mythology), has no body or spinous process, supports the head, and allows for head rotation and other movements. The second cervical vertebra (C2), or axis, has an odontoid (meaning toothlike) process that serves as a pivot point for head rotation.
  - The seventh cervical vertebra (C7) has a long spinous process that is often easy to locate and palpate on the skin’s surface.
  - Sacral vertebrae are normally fused in the adult. They reinforce and stabilize the pelvis and form the sacrum.
  - Coccygeal vertebrae are also fused and form a small triangular bone, the coccyx.
  - Intervertebral discs of fibrocartilage lie between adjacent vertebrae except for between the atlas and axis and between adjacent sacral and coccygeal vertebrae (which are fused). There is a large intervertebral disc between the last lumbar (L5) and first sacral (S1) vertebrae (the lumbosacral joint) and a small atypical disc between the last sacral (S5) and first coccygeal (Co1) vertebrae (the sacrococcygeal joint). Discs provide for movement and shock absorption.



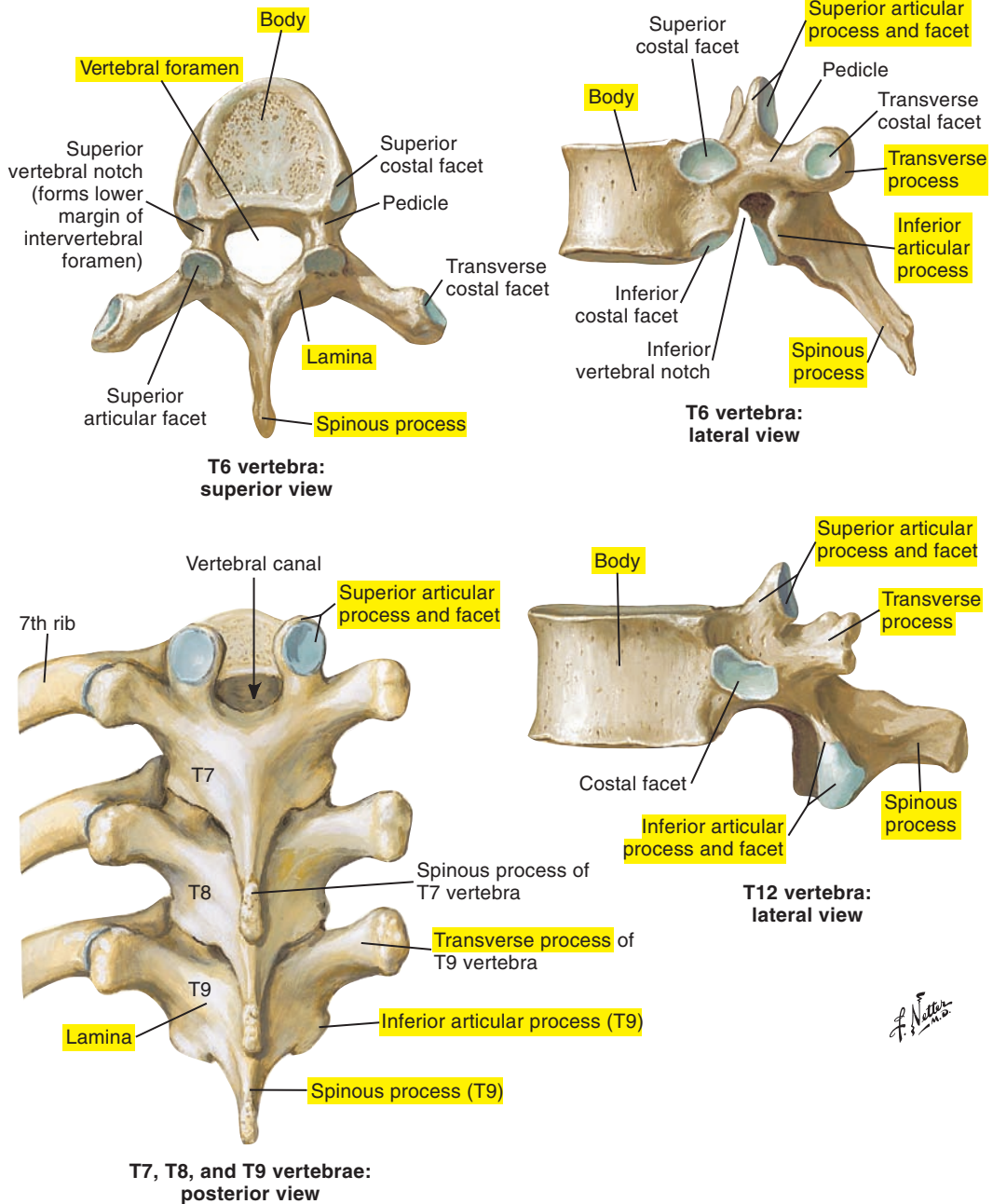


Figure 1-2. The thoracic vertebrae.

**Rib Cage (Ribs, Cartilages, Sternum) (Figure 1-3)**

The human body contains the following 12 pairs of ribs:

- Ribs 1 through 7 are “true” ribs (or vertebrosteral ribs) and connect directly to the sternum via costal cartilages (for mobility).
- Ribs 8, 9, and 10 are “false” ribs and connect to the sternum via a common cartilage that joins the seventh costal cartilage.
- Ribs 11 and 12 are “floating” ribs; their anterior extremity is free (not connected to the sternum).

The posterior extremity of each rib is connected to the vertebral column. The sternum is connected to the ribs and clavicles and is composed of the following three parts:

1. The manubrium
2. The body or corpus
3. The xiphoid process

The articulation of the manubrium with the corpus forms the sternal angle, or angle of Louis, and marks the approximate location of the second costal cartilages and the level of tracheal bifurcation.

**Pectoral, Scapular, or Shoulder Girdle (see Figure 1-3)**

- The pectoral, scapular, or shoulder girdle is formed anteriorly by the clavicle (long thin bone) and posteriorly by the scapula (triangular flat bone).
- The clavicle allows for the projection of the scapula away from the thoracic cage.
- The humerus is attached to the glenoid cavity of the scapula.
- The pectoral girdle is the point of attachment for many accessory muscles of respiration such as the pectoralis major and sternocleidomastoid muscles. Fixation or stabilization of the pectoral girdle is needed for forced inspiration and expiration, as well as for heavy lifting and other strenuous activities.

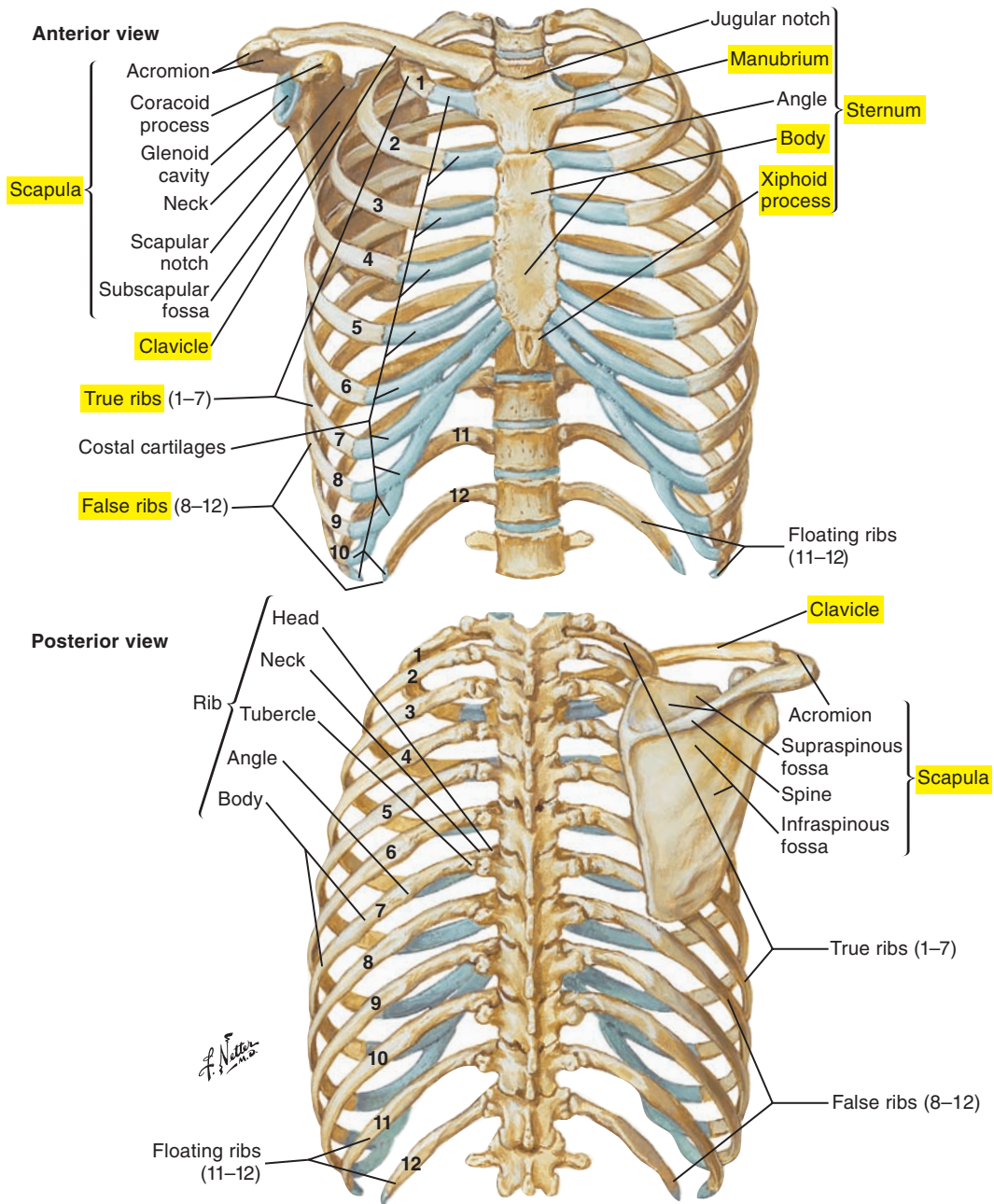
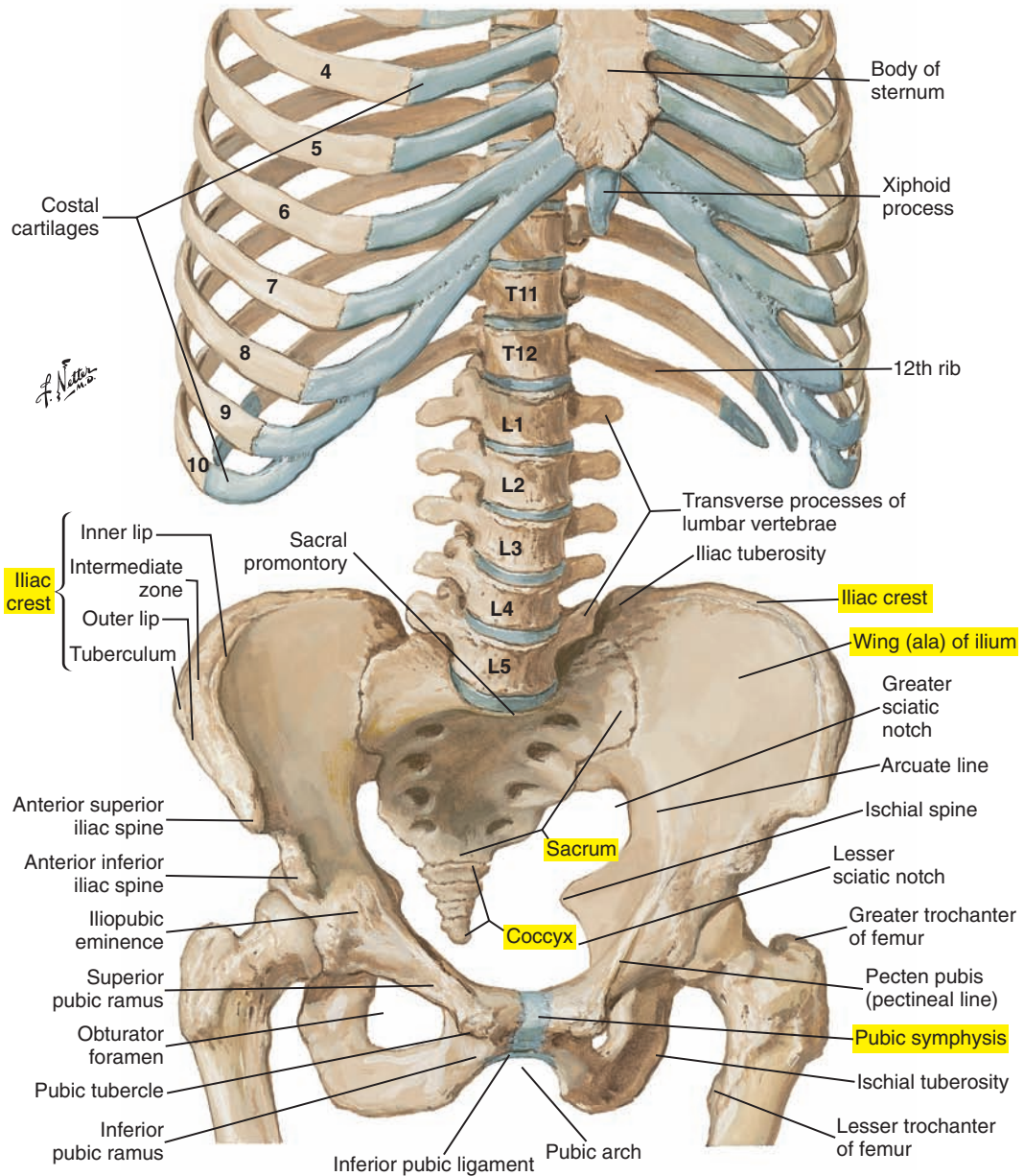


Figure 1-3. The bony framework of the thorax.

**Pelvic Girdle or Bony Pelvis** (Figure 1-4)

The pelvic girdle is formed by the following:

- A pair of symmetrical coxal, or hip, bones that are joined together anteriorly at the pubic symphysis and posteriorly by the sacrum. Each hip bone is composed of three distinct bones that fuse during development. The following individual structures retain their names despite the fact that they are fused and no suture lines may be visible:
  - Ilium
  - Ischium
  - Pubis
- The sacrum is attached to the ilium at the sacroiliac joint, an extremely strong and stable joint that supports the weight of the upper body.
- The coccyx is the final segment of the vertebral column and is often referred to as the “tailbone.”



**Figure 1-4.** The bony framework of the abdomen.



## ■ RESPIRATORY TRACT

---

Air circulates in the following respiratory areas:

- Nasal cavities
- Oral cavity
- Pharynx
- Larynx
- Trachea
- Bronchi
- Lungs

### **Nasal Cavities** (Figure 1-5)

The nasal cavities are the first segment of the upper respiratory tract and participate in olfaction (see Part 3: Oropharyngeal-Articulatory System, pp. 107-169).

### **Oral Cavity**

The oral cavity is delimited anteriorly and laterally by the teeth, posteriorly by the palatoglossal arch (anterior faucial pillar), superiorly by the hard palate and soft palate, and inferiorly by the tongue. It is located behind and medial to the buccal cavity, which is the space between the lips and gums and the teeth, and anterior to the pharynx (see Part 3: Oropharyngeal-Articulatory System, pp. 107-169).

### **Pharynx** (Figure 1-6 [p. 36])

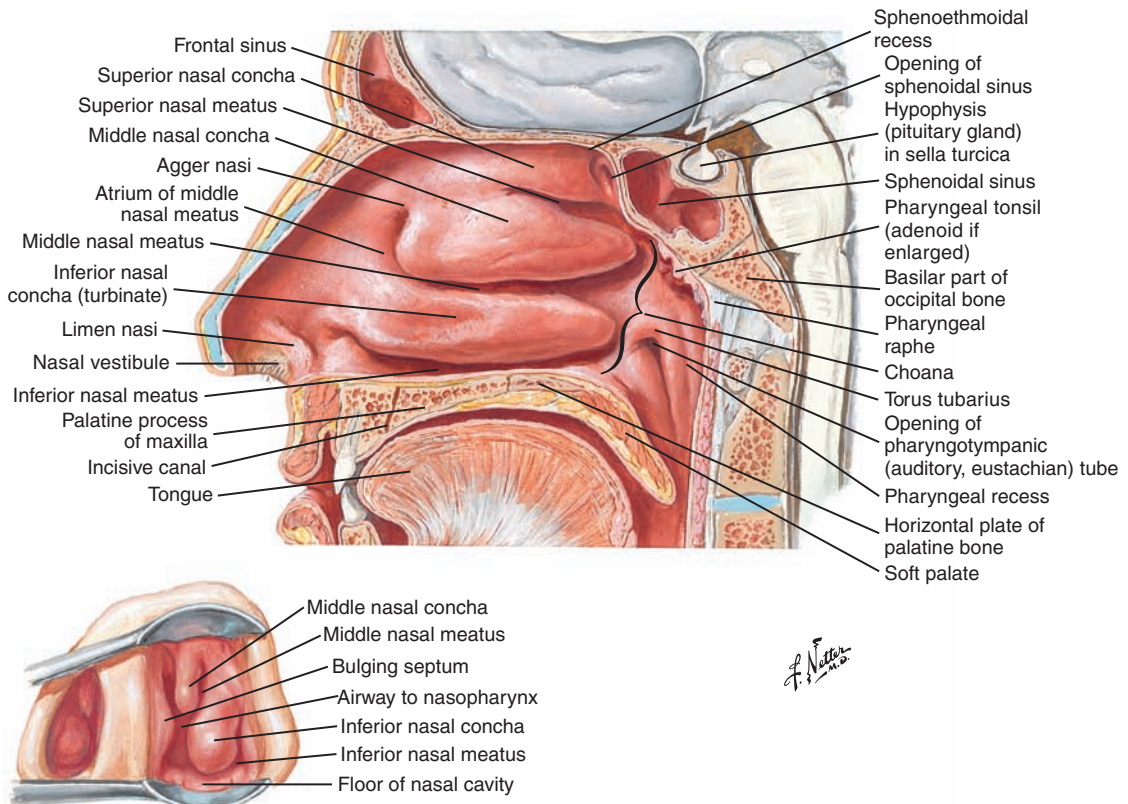
The pharynx is a vertically oriented muscular passageway that provides communication between the buccal/oral cavities and the esophagus and between the nasal cavities and the larynx (see Part 3: Oropharyngeal-Articulatory System, pp. 107-169).

The pharynx is composed of the following:

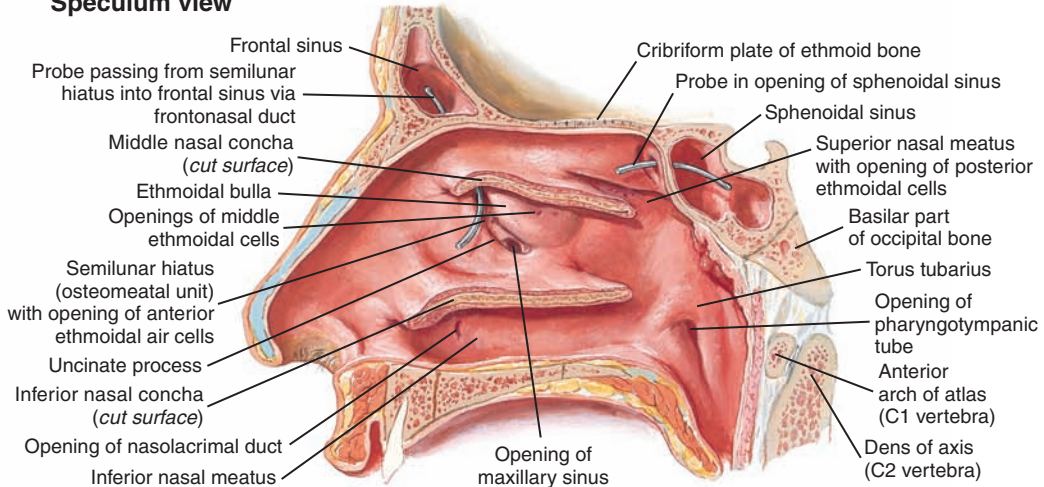
- Nasal portion (nasopharynx)
- Buccal portion (oropharynx)
- Laryngeal portion (laryngopharynx)

### **Larynx** (Figure 1-7 [p. 37])

The larynx is located directly above the trachea and in front of the pharynx. The principal biological function of the larynx is to protect the lower respiratory tract (see Part 2: Laryngeal-Phonatory System, pp. 75-106).

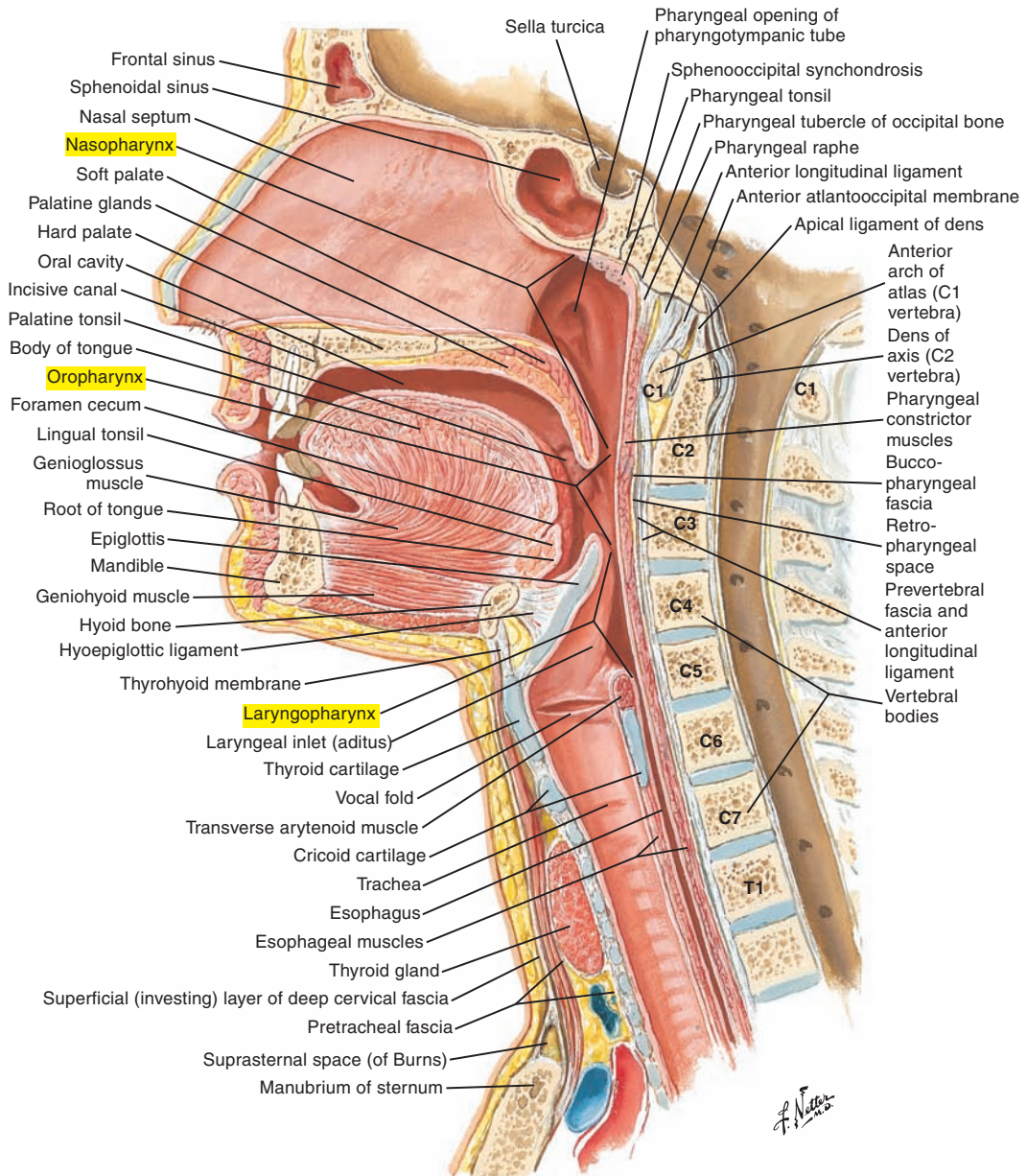


### Speculum view

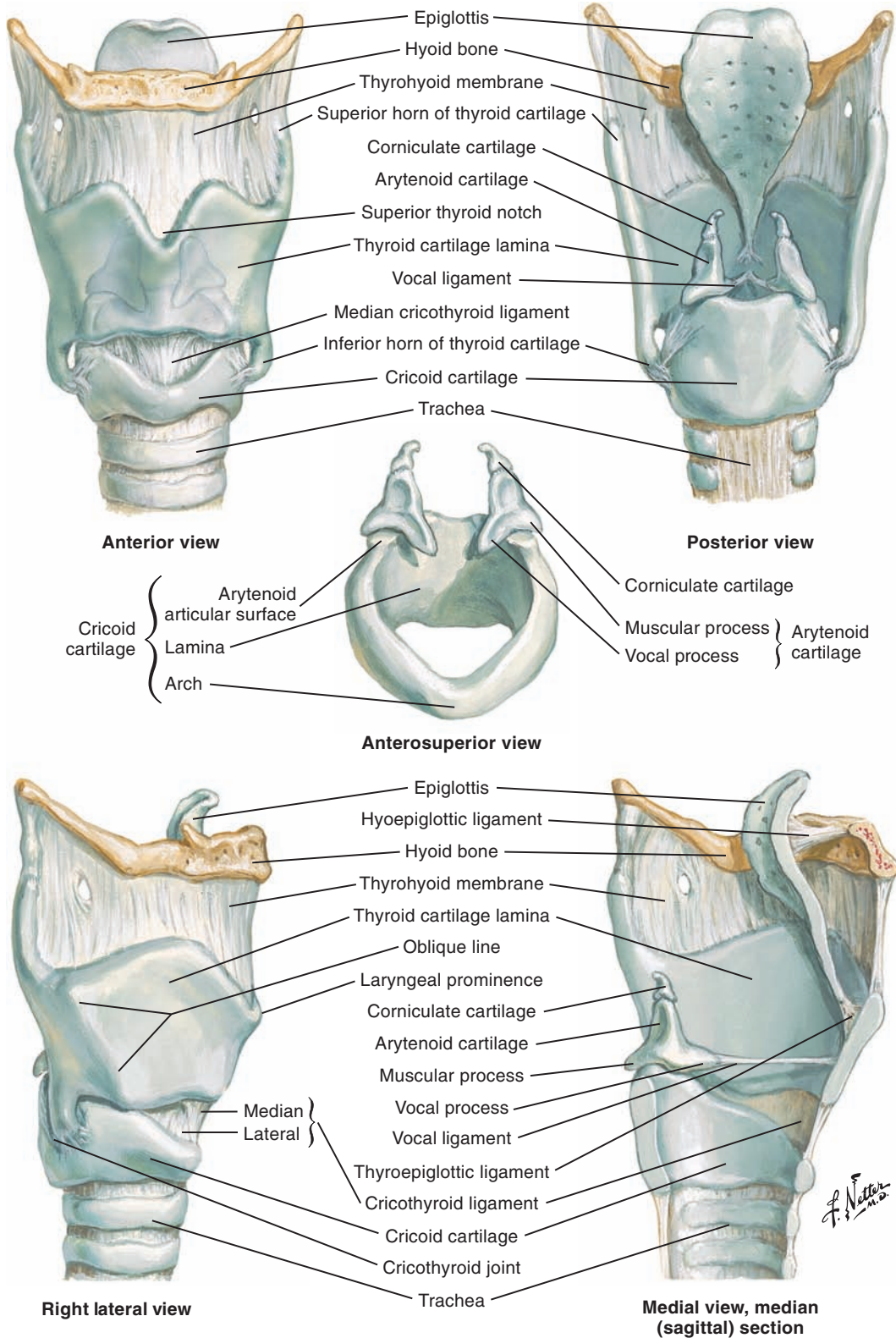


**Figure 1-5.** The lateral wall of the nasal cavity.





**Figure 1-6.** A median section of the pharynx.



**Figure 1-7.** The cartilages of the larynx.

**Trachea** (Figure 1-8)

The trachea extends from the larynx to the bronchi. It contains 16 to 20 incomplete cartilaginous horseshoe-shaped rings connected by ligaments. The rings are deficient posteriorly to accommodate the attachment to the esophagus. The trachea has two portions: (1) cervical and (2) thoracic.

**Bronchi** (Figures 1-8 and 1-9 [p. 40])

The trachea divides, or bifurcates, at the level of the sternal angle (T4 to T5) to form the main, or primary, bronchi (right and left), as follows:

- The main bronchi divide into lobar or secondary bronchi, one for each lung lobe: three for the right (superior, middle, and inferior) and two for the left (superior and inferior).
- The lobar bronchi further divide to form segmental or tertiary bronchi (third-order bronchi), each supplying a specific bronchopulmonary segment: 10 for the right and 9 for the left.
- The segmental bronchi continue to divide many times (20 to 25 generations) to eventually become terminal bronchioles (“little tubes”) with diameters of less than 0.5 mm. The terminal bronchioles are the end of the conducting respiratory passageways.

The respiratory portion of the pathway in which gas exchange occurs begins with the respiratory bronchioles, then the alveolar ducts, the alveolar sacs, and the alveoli, in which the main part of pulmonary gas exchange occurs (Figure 1-10 [p. 41]).

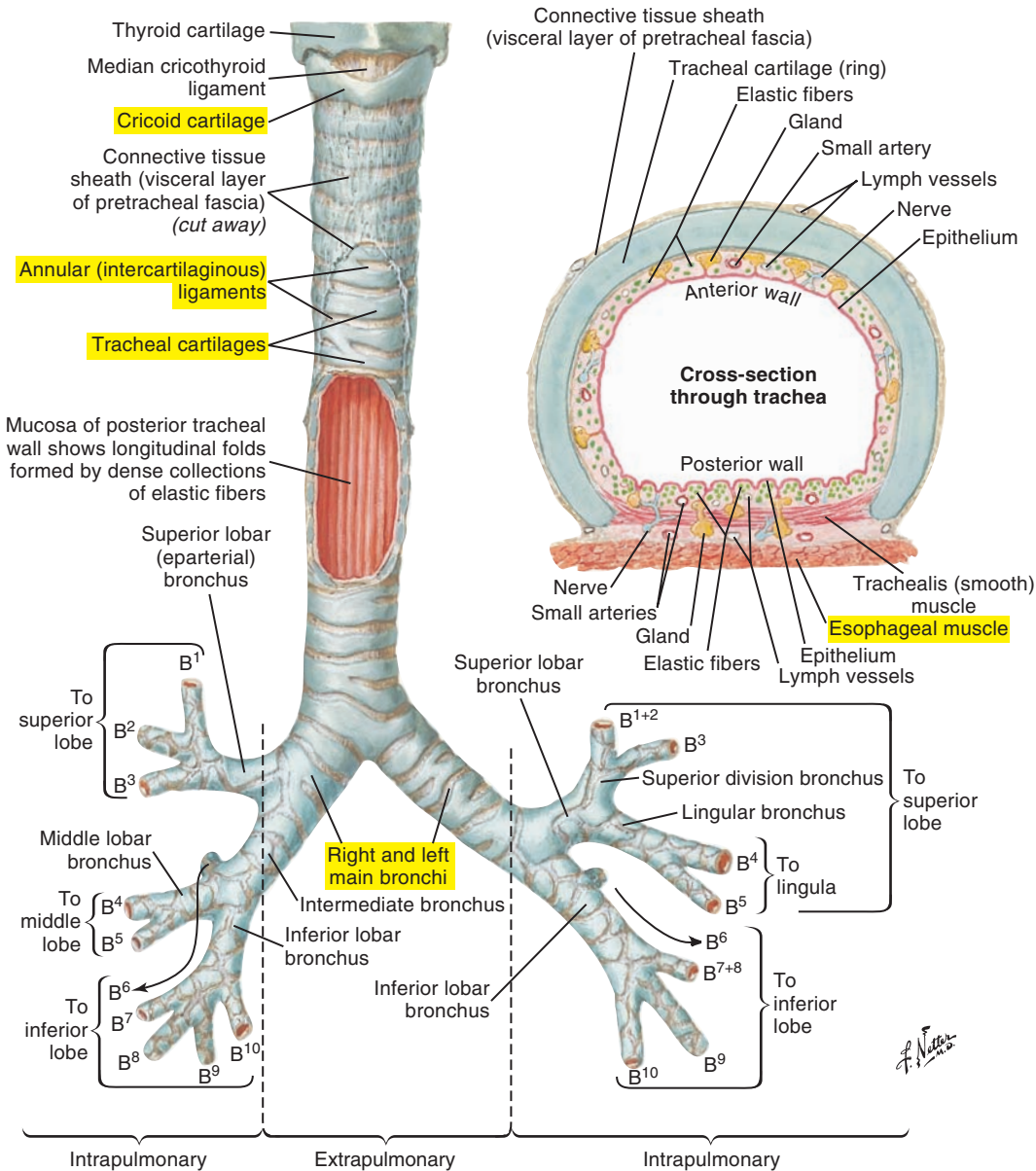
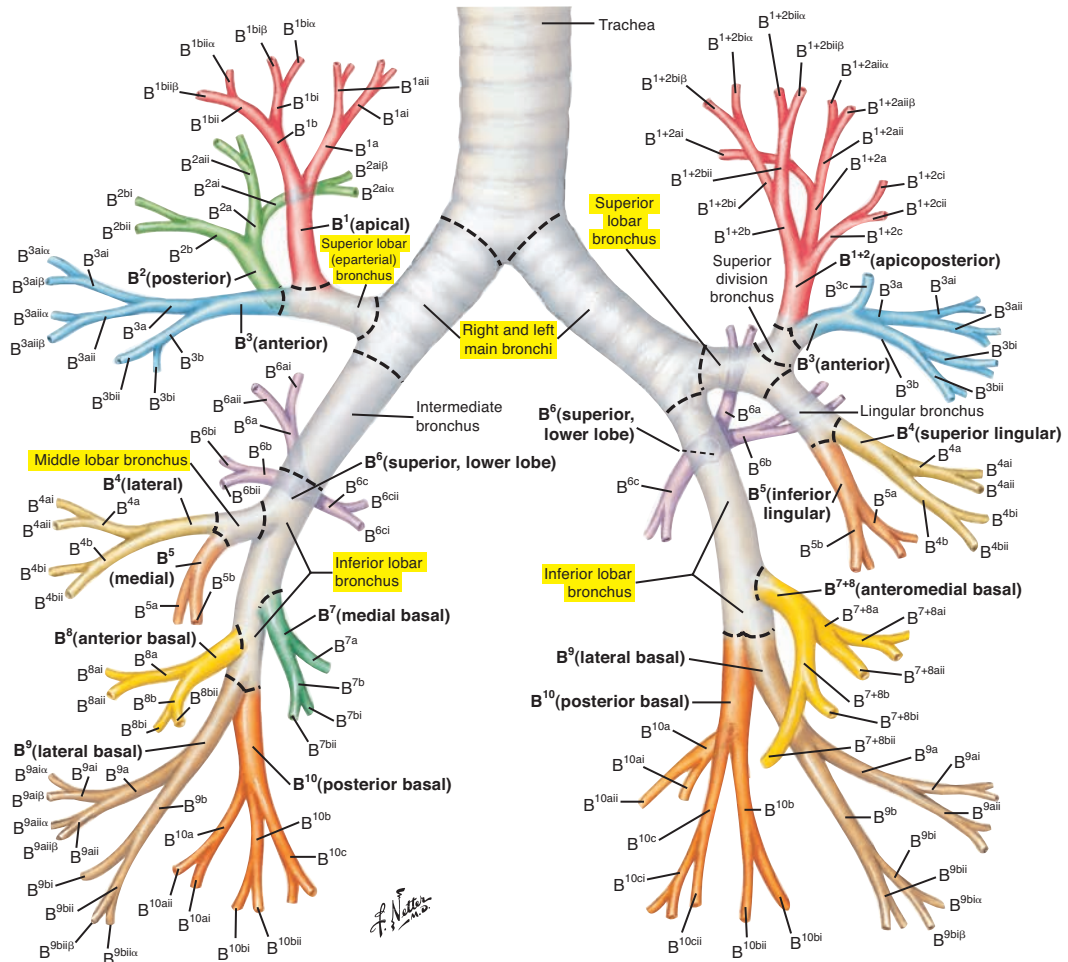


Figure 1-8. The trachea and major bronchi.



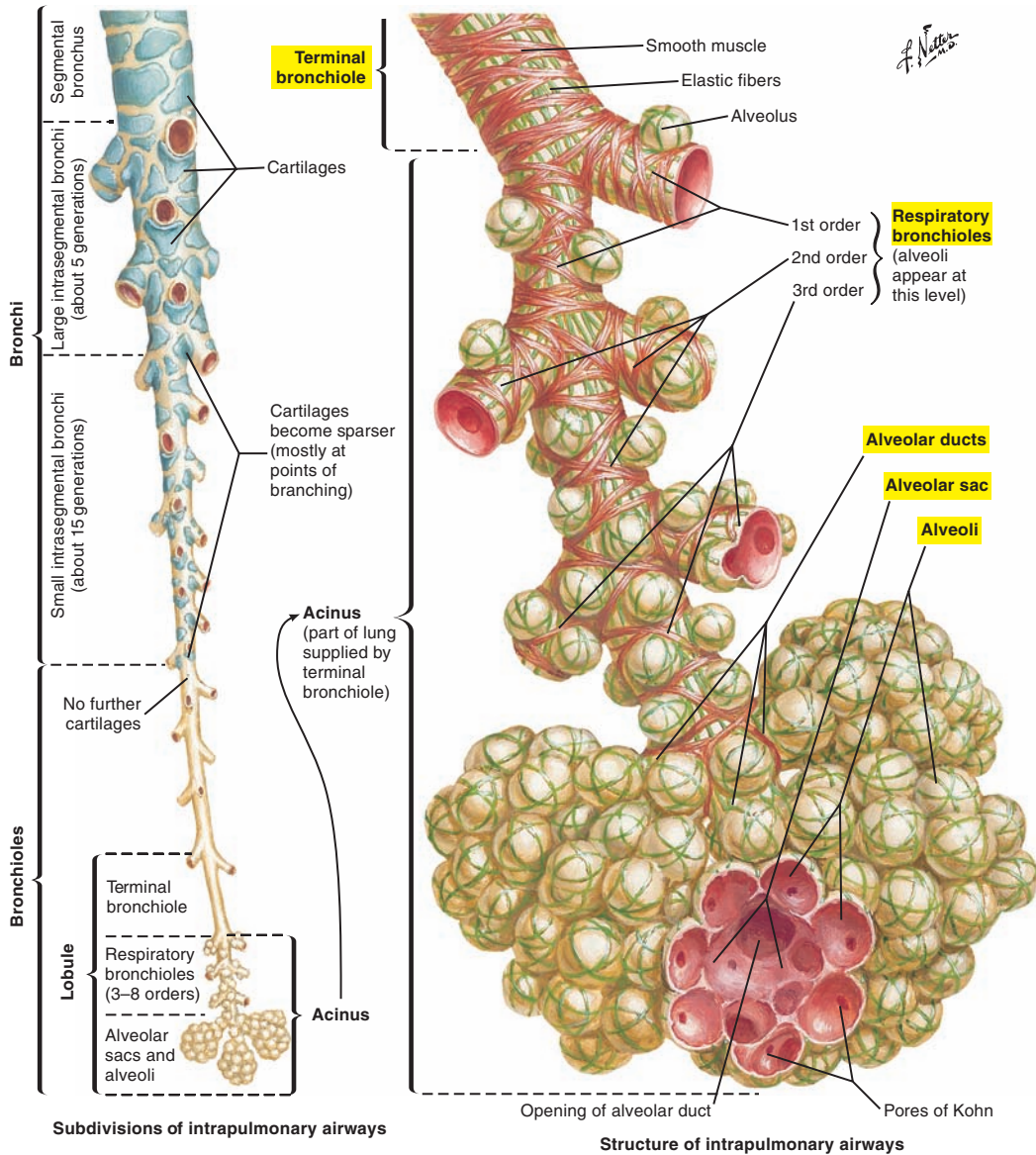


Nomenclature in common usage for bronchopulmonary segments is that of Jackson and Huber, and segmental bronchi are named accordingly. Ikeda proposed nomenclature (as demonstrated here) for bronchial subdivisions as far as 6th generation. For simplification on this illustration, only some bronchial subdivisions are labeled as far as 5th or 6th generation. Segmental bronchi (B) are numbered from 1 to 10 in each lung, corresponding to pulmonary segments. In left lung, B<sup>1</sup> and B<sup>2</sup> are combined,

as are B<sup>7</sup> and B<sup>8</sup>. Subsegmental, or 4th order, bronchi are indicated by addition of lower-case letters a, b, or c when an additional branch is present. Fifth order bronchi are designated by Roman numerals i (anterior) or ii (posterior) and 6th order bronchi by Greek letters α or β. Several texts use alternate numbers (as proposed by Boyden) for segmental bronchi.

Variations of standard bronchial pattern shown here are common, especially in peripheral airways.

**Figure 1-9.** The nomenclature of the bronchi.



**Figure 1-10.** The intrapulmonary airways. Gas exchange begins at the level of the respiratory bronchioles.

## Lungs (Figure 1-11)

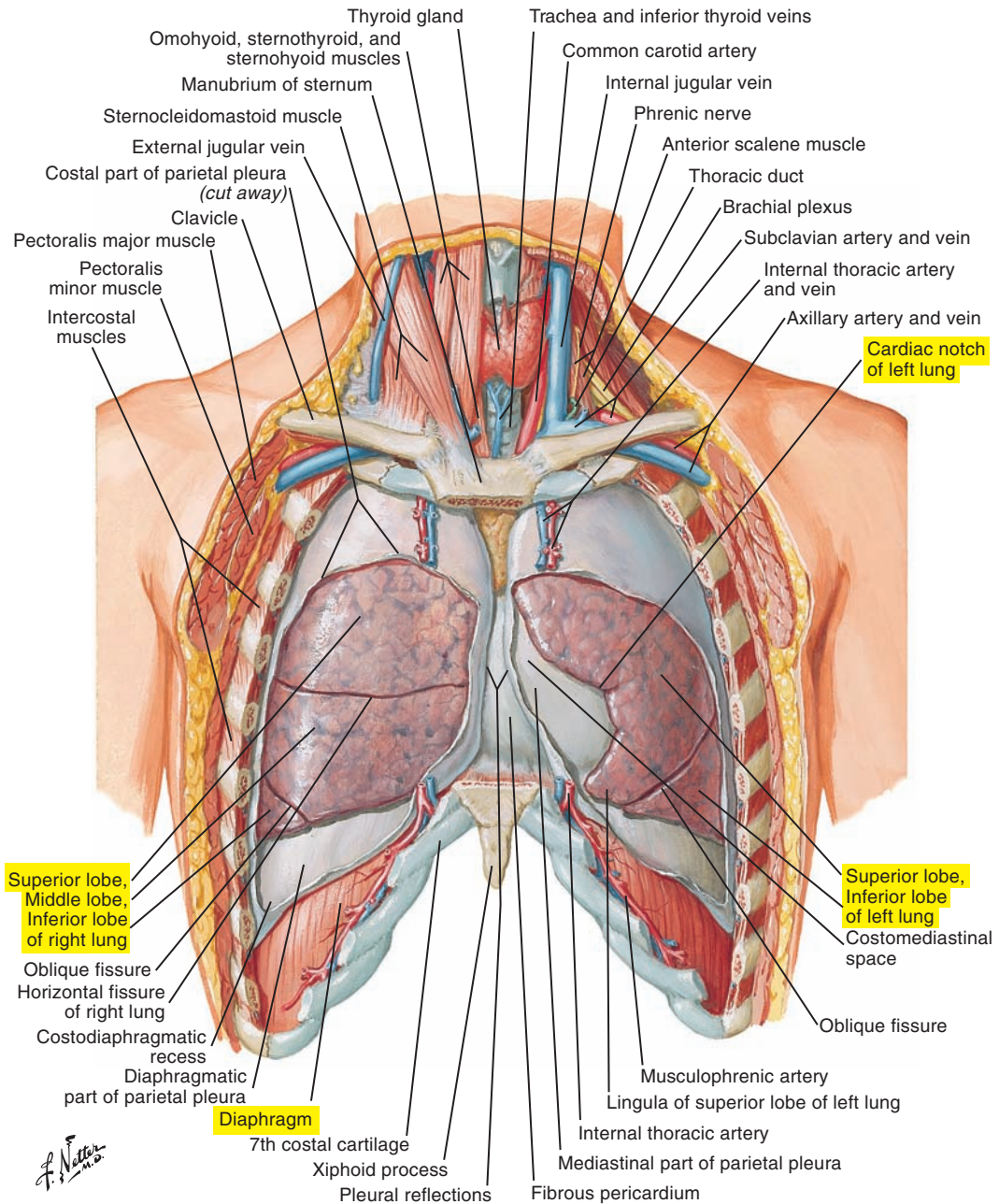
The trunk, or torso, contains the thorax (or thoracic cavity) and the abdomen, which are divided by the diaphragm. The lungs are located in the thorax. They are two masses of nonmuscular tissue that occupy a major portion of the thoracic cavity. Between the right and left lungs is a space called the *mediastinum* that contains the heart and other anatomical structures (Figure 1-12 [p. 44]).

The lungs are spongy, porous, and highly elastic. Because they are elastic, they seek to return to their relaxed or resting position when stretched or compressed and can generate relaxation pressures because of their elastic recoil. Imagine stretching an elastic band between your two fingers and “feeling” the tension acting to return the band to its nonstretched position. Elastic recoil forces of the lungs (and thorax) and the pulmonary pressures they create are key aspects of quiet breathing and speech breathing.

Although similar in appearance and function, the following differences in shape of the two lungs are a result of the presence of adjacent organs (Figure 1-13 [p. 45]):

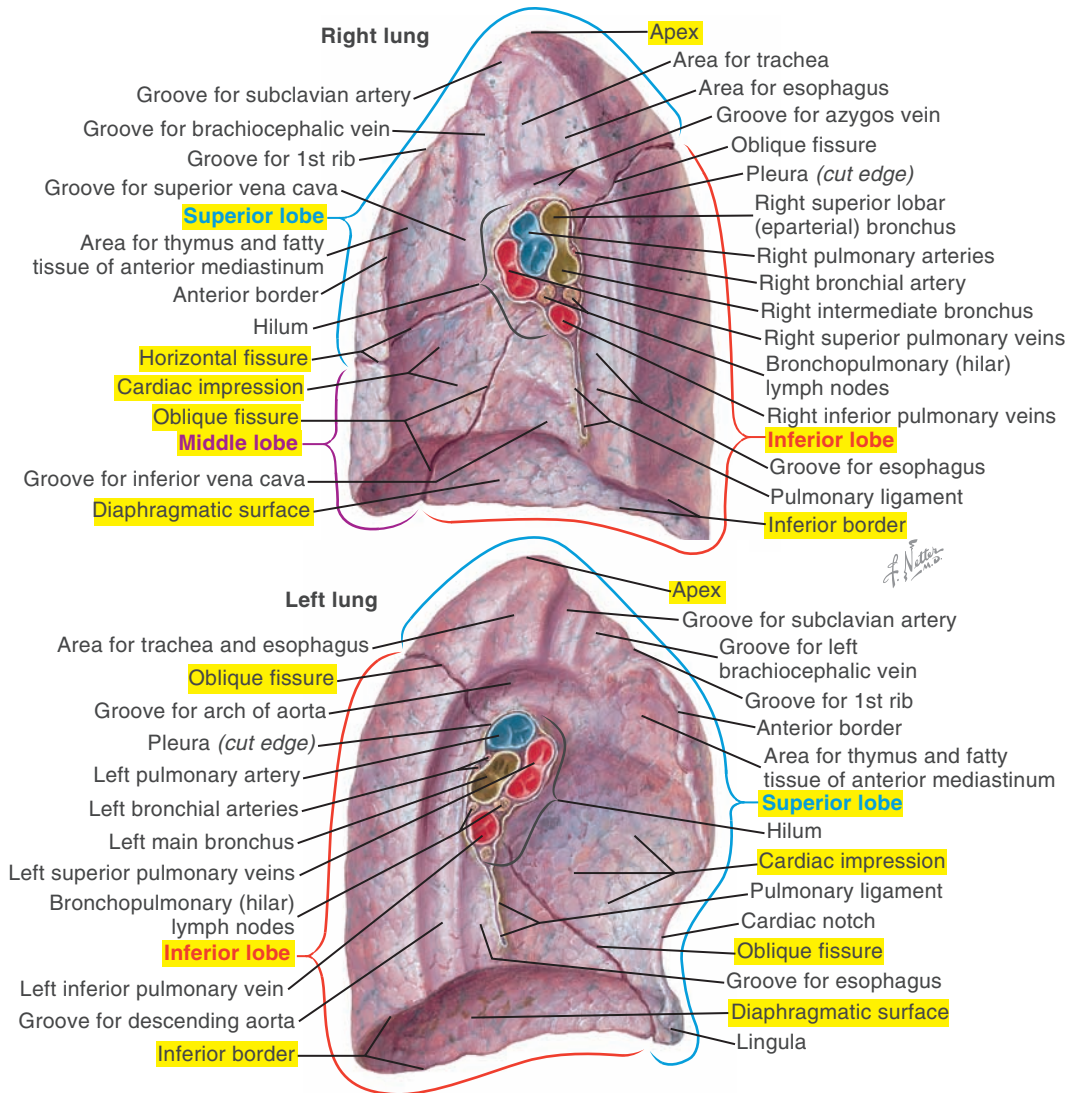
- The right lung is larger and broader than the left but shorter because of the presence of the liver and the elevation of the diaphragm on the right side. The overall capacity and weight of the right lung are greater than those of the left.
- The left lung is smaller and narrower than the right lung, with a distinct cardiac notch to accommodate the pericardium (membrane covering the heart and great blood vessels).
- The right lung is divided into three lobes by the horizontal and oblique fissures.
- The left lung is divided into two lobes by an oblique fissure.
- Each lung is anatomically divided into functional segments called *bronchopulmonary segments* (10 for the right and 9 for the left).
- The superior aspect of each lung is called the *apex*, and the inferior aspect is called the *base*.
- Each lung has an inferior concave diaphragmatic surface, an external convex costal surface, and an internal concave surface that is caused by the presence of the mediastinum.
- The lung apex can exceed the limits of the thorax and protrude above the level of the middle third of the clavicle by several centimeters.





**Figure 1-11.** An anterior view of the lungs in situ.





**Figure 1-13.** Medial views of the right and left lungs.

**Pleura** (Figure 1-14)

The pleurae are intrathoracic serous membranes that envelop and protect the lungs:

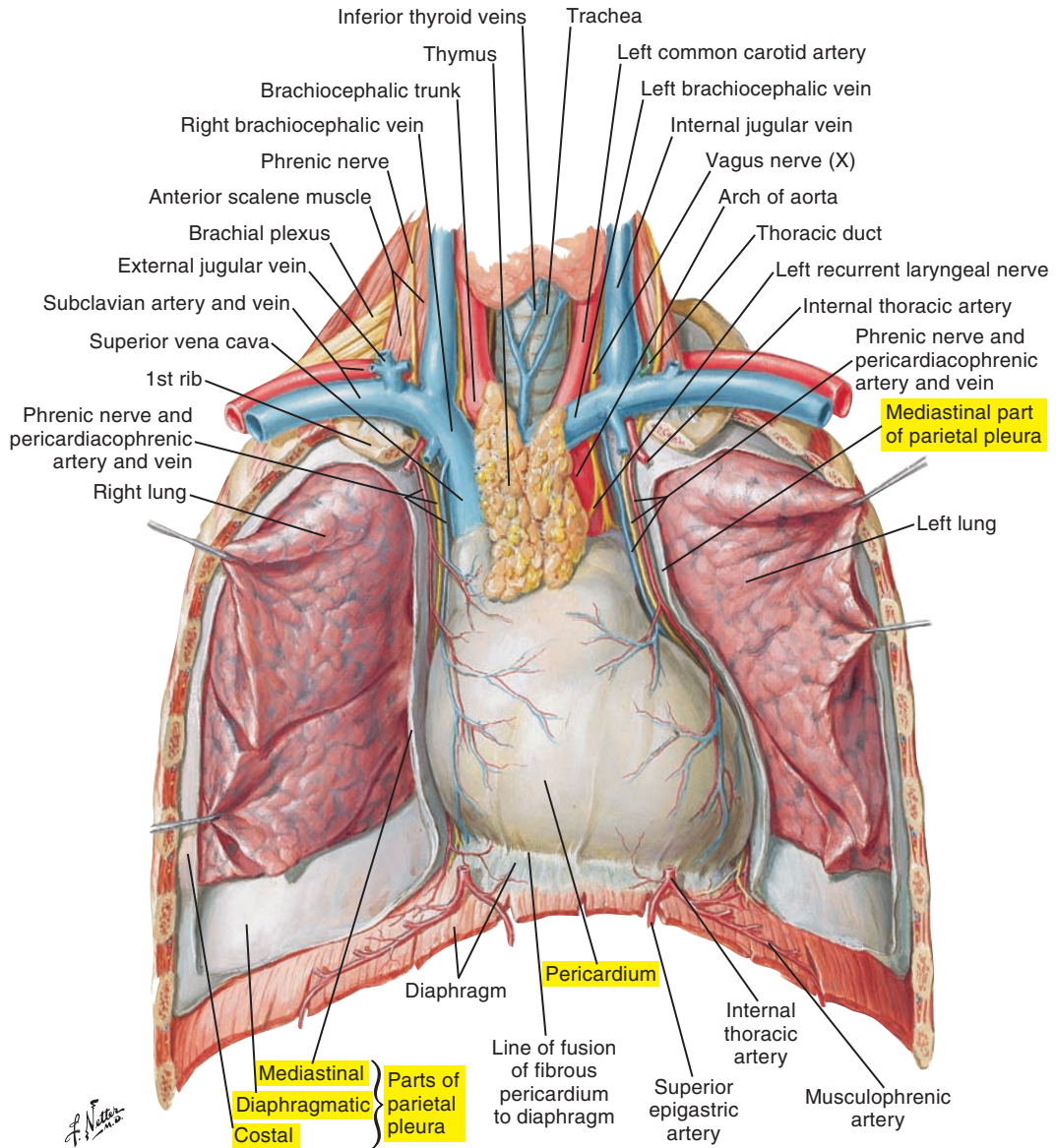
- The parietal pleurae line the inner surface of the thoracic cavity.
- The visceral pleurae cover each lung independently.

Parietal and visceral pleurae are attached (linked) through a very thin, fluid-filled space called the *pleural space*. Fluid in the space allows for friction-free movement between the two membranes and creates surface tension and negative pressure that link the two pleurae. With pleural linkage, when respiratory muscles change the dimensions of the thorax, lung volume also changes. Consequently, the lungs and thorax normally act as a unit and are often referred to as the *lungs-thorax unit*.

**Selected Pulmonary Disorders Affecting Lung Function**

- **Pleurisy** is an inflammation of the pleura caused by an undersecretion or oversecretion of fluid in the pleural space. Respiration may be very painful.
- **Pneumothorax** is the presence of air in the pleural space (the result of trauma such as a penetrating chest wound or disease). This condition may interrupt pleural linkage and cause a collapse of one or both of the lungs, depending on whether the pneumothorax is unilateral or bilateral.
- **Pneumonia** is an infection of the lungs resulting from many possible causes, including the presence of bacteria, viruses, and fungi. Pneumonia is a possible consequence of disordered swallowing and the aspiration (breathing in) of food and liquids. This is referred to as *aspiration pneumonia*.





**Figure 1-14.** The heart in situ. Note the parts of the parietal pleura.

## ■ RESPIRATORY MUSCLES

---

A very large number of muscles are potentially involved in respiration. Our focus here is on the principal muscles of respiration, which are classified as either inspiratory or expiratory (see the tables on pp. 65, 66, and 69). This historical classification is based on the isolated action of each muscle. Inspiratory muscles are those muscles whose mechanical advantage or action is to increase lung volume, and expiratory muscles are those whose mechanical advantage or action is to decrease lung volume. However, it is important to note that inspiratory muscles are not solely active during inspiration and expiratory muscles are not solely active during expiration. For example, during normal spontaneous breathing, the diaphragm (a major muscle of inspiration) continues to contract during the early expiratory phase to slow passive relaxation forces acting to decrease lung volume.

Therefore the muscles grouped in the category “inspiratory muscles” are those whose isolated action is to increase lung volume, and “expiratory muscles” are those whose isolated action is to decrease lung volume.

## Principal Muscles of Inspiration

The function of the principal muscles of inspiration is to increase pulmonary volume.

### **Diaphragm** (Figures 1-15 [p. 50] and 1-16 [p. 51])

The diaphragm is an unpaired muscle. It is a thin, dome-shaped muscle with a strong central tendon (aponeurosis). It separates the thorax from the abdomen. Several important structures pass through the diaphragm including the esophagus, aorta, and major veins through the following:

- Aortic hiatus. The aorta passes behind the medial arcuate ligament and through an osseoaponeurotic opening, and thus technically does not pierce the diaphragm. This ensures that muscular contractions of the diaphragm do not impact blood flow.
- Esophageal hiatus
- Vena cava foramen (caval opening)

The three main groups of muscle fibers, named according to their principal points of origin, are as follows:

1. The **costal part** originates from the inferior and inner surfaces of the costal cartilages and adjacent portions of the last six ribs and courses directly upward to insert into the central tendon. Costal diaphragm muscle fibers are directly apposed to the inner surface of the rib cage for approximately 6 to 9 cm through the “zone of apposition.”
2. The **sternal part** originates from the inner inferior surface of the xiphoid process of the sternum and courses upward to insert into the central tendon.
3. The **lumbar (vertebral) part** originates from the upper lumbar vertebrae through two groups of fibers called *crura* and from the medial and lateral arcuate ligaments. Fibers course upward to insert into the central tendon.

The orientation of the fibers of the diaphragm can be visualized by imagining the fibers forming the inner walls of a bowl.

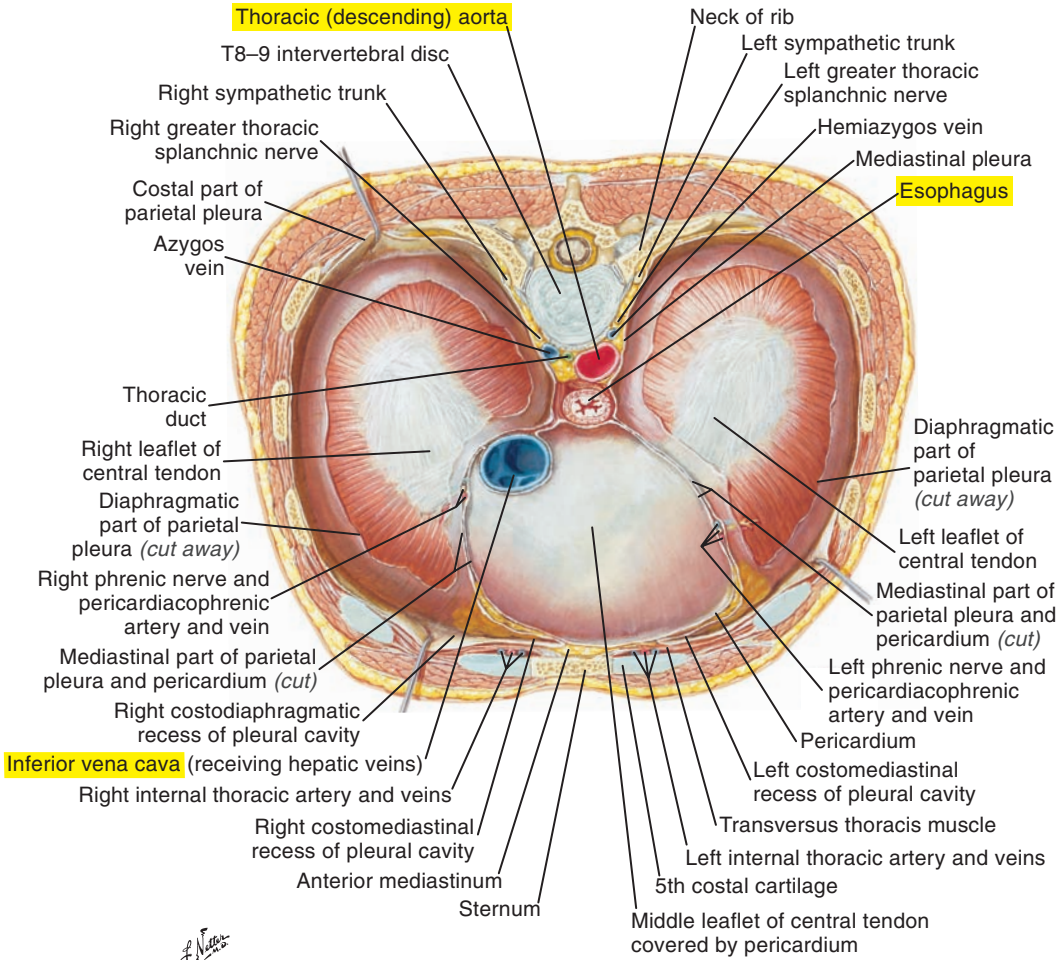
Diaphragm contraction (and shortening of its muscle fibers) pulls down on the central tendon, which increases the vertical dimensions of the lungs-thorax unit. At the level of the rib cage, diaphragm contraction (against the resistance of the abdominal contents) lifts the ribs and rotates them outward, which increases the anterolateral dimensions of the rib cage. Lung volume increases, thus creating negative (inspiratory) alveolar (lung) pressure. The contraction of the diaphragm compresses the viscera and increases abdominal pressure.

When the diaphragm relaxes, it returns to its resting form, thus decreasing the vertical dimensions of the lungs-thorax unit. The ribs also rotate downward and inward, decreasing circumferential dimensions.

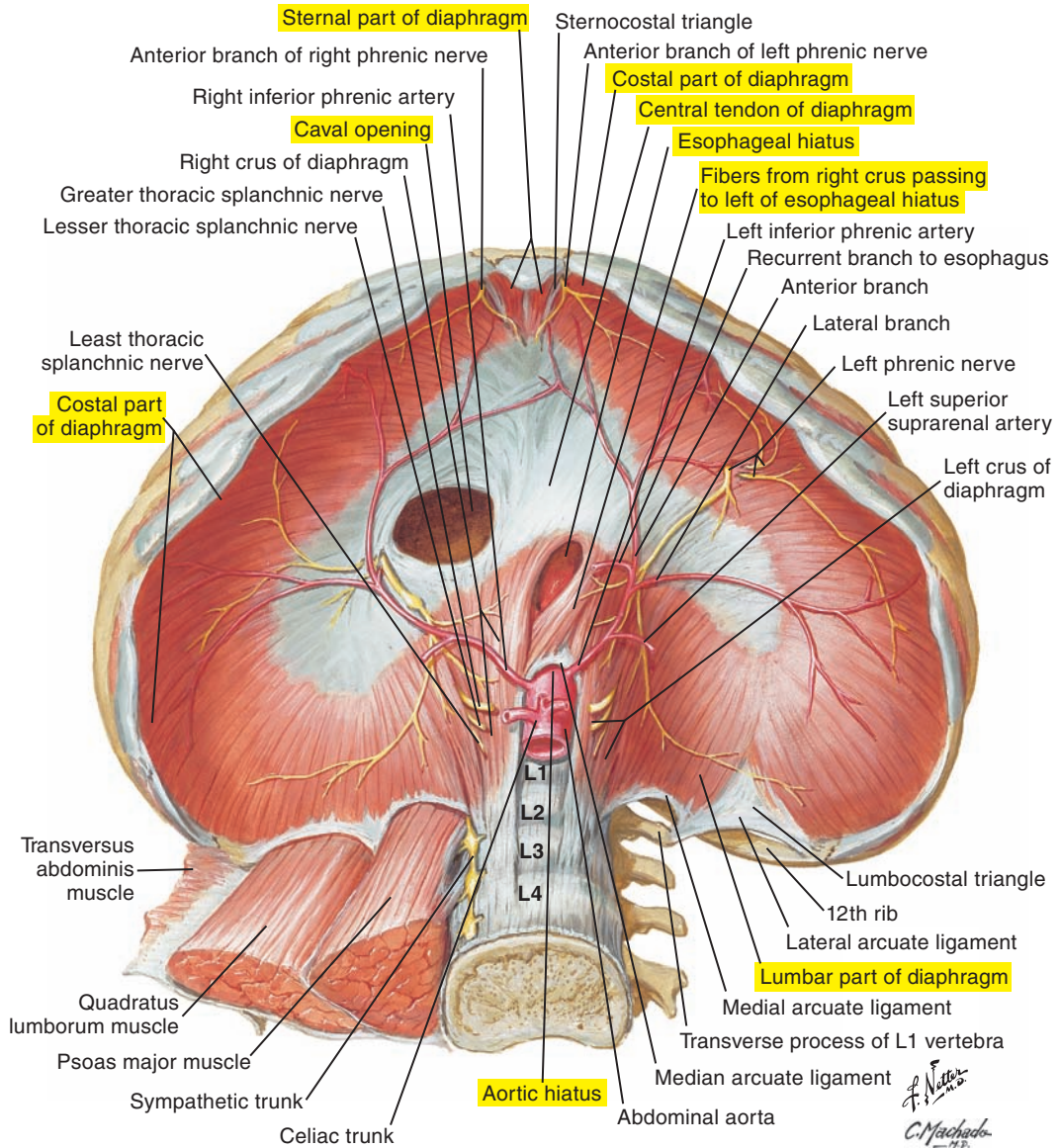
The diaphragm is innervated by the phrenic nerve, which arises from cervical spinal nerves C3 to C5.

A primary function of the intercostal (internal and external) muscles is to stiffen the rib intercostal spaces and thus the chest wall. This function prevents chest wall collapse (being “sucked” in or out) when, for example during inspiration, diaphragmatic contraction generates negative intrathoracic pressures.





**Figure 1-15.** The thoracic surface of the diaphragm.



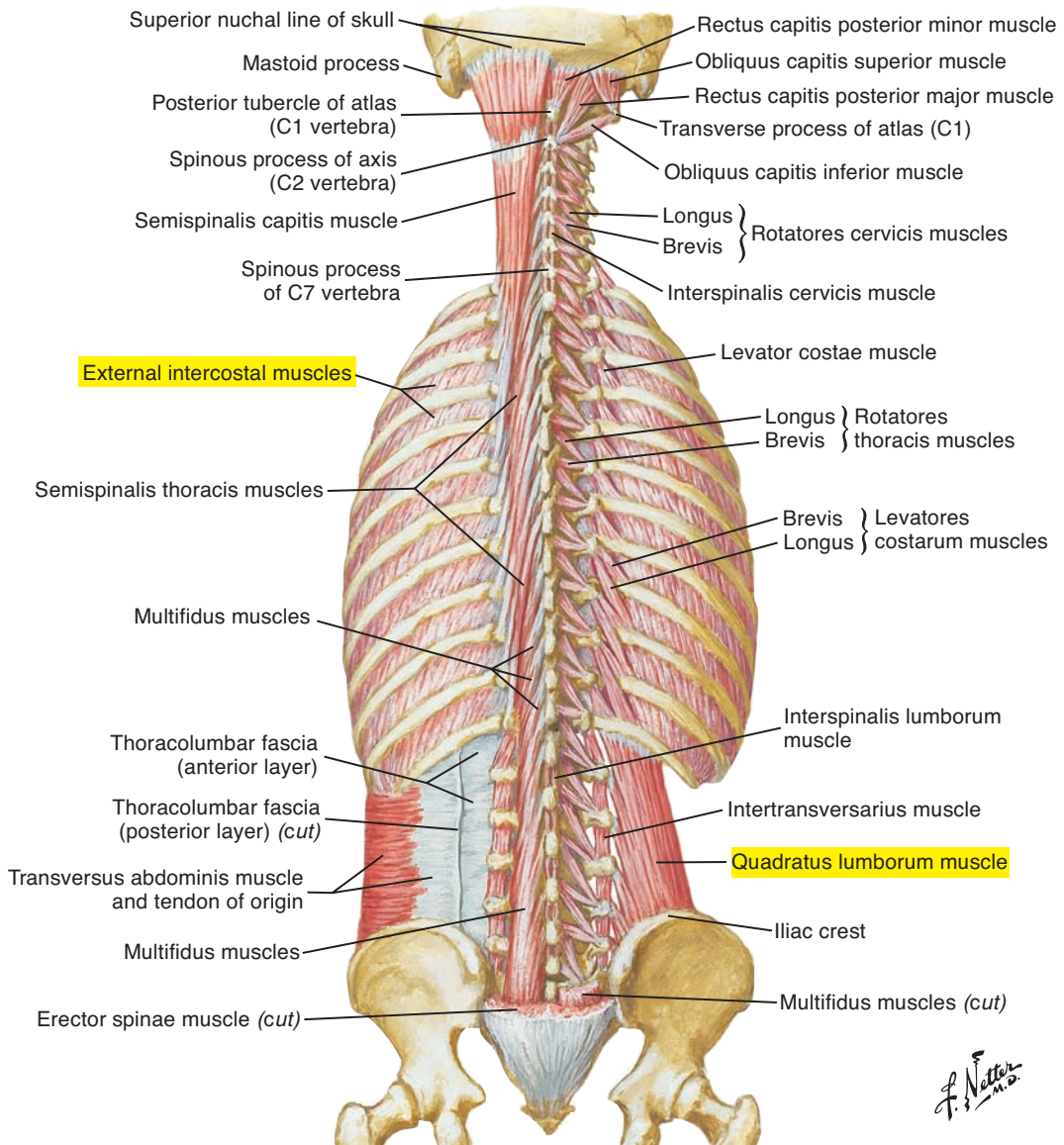
**Figure 1-16.** The abdominal surface of the diaphragm.

**External Intercostal Muscles** (Figures 1-17, 1-18 [p. 54], and 1-19 [p. 55])

Fibers extend from the tubercles of the ribs to the junctions of the costal cartilages and the bony ribs (the costochondral junctions). From there, they are replaced by external intercostal membranes. A posterior view of the external intercostals reveals that the muscle fibers are oriented inferiorly and laterally (see Figure 1-17). Anteriorly, the muscle fibers are oriented inferiorly and medially (see Figure 1-18 [p. 54]).

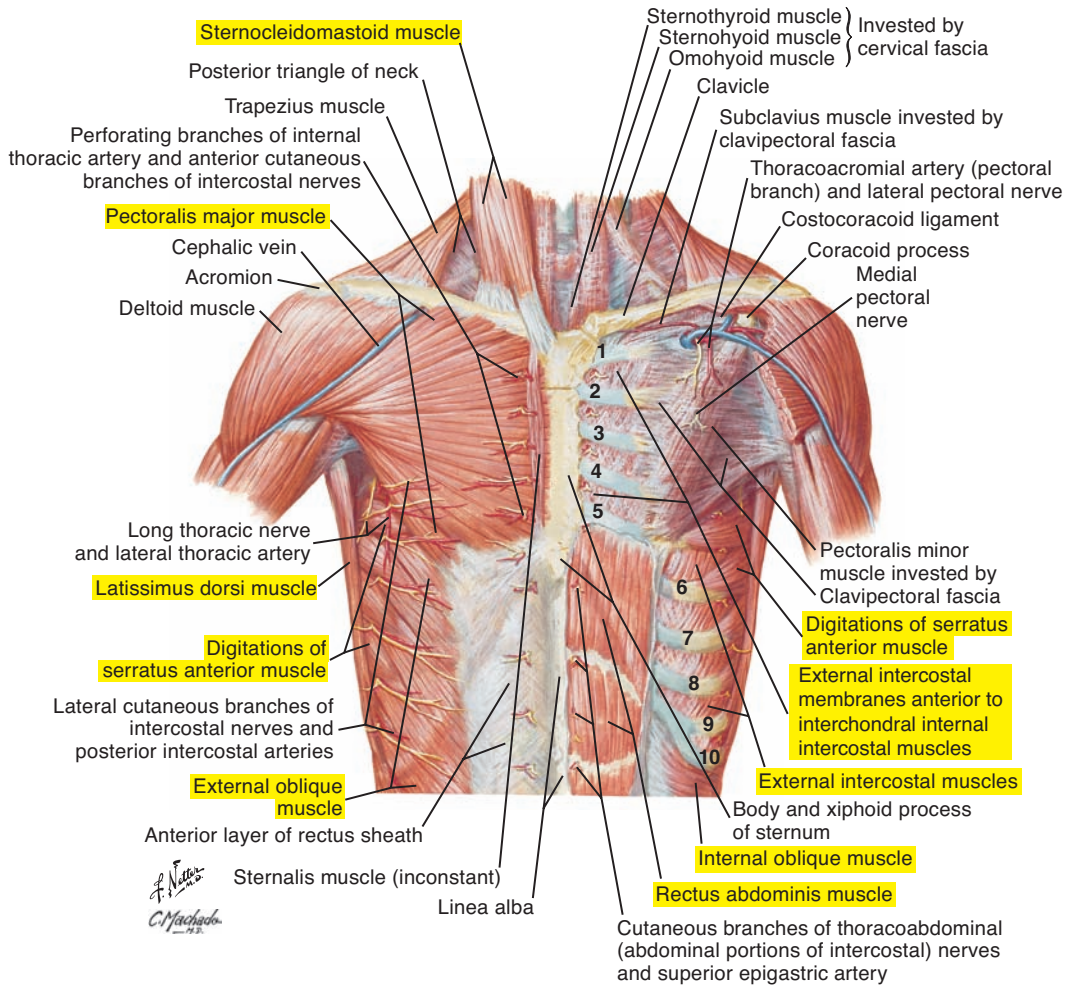
There appears to be some regional distribution of the respiratory function of the external and internal intercostals (see next section). The muscle fibers located in more rostral interspaces are inspiratory, and the muscle fibers located in ventral caudal interspaces are expiratory. Inspiratory action raises the rib below; expiratory action lowers the rib above.

The external intercostal muscles are innervated by the intercostal nerves (anterior ramifications of spinal nerves T1 to T11).



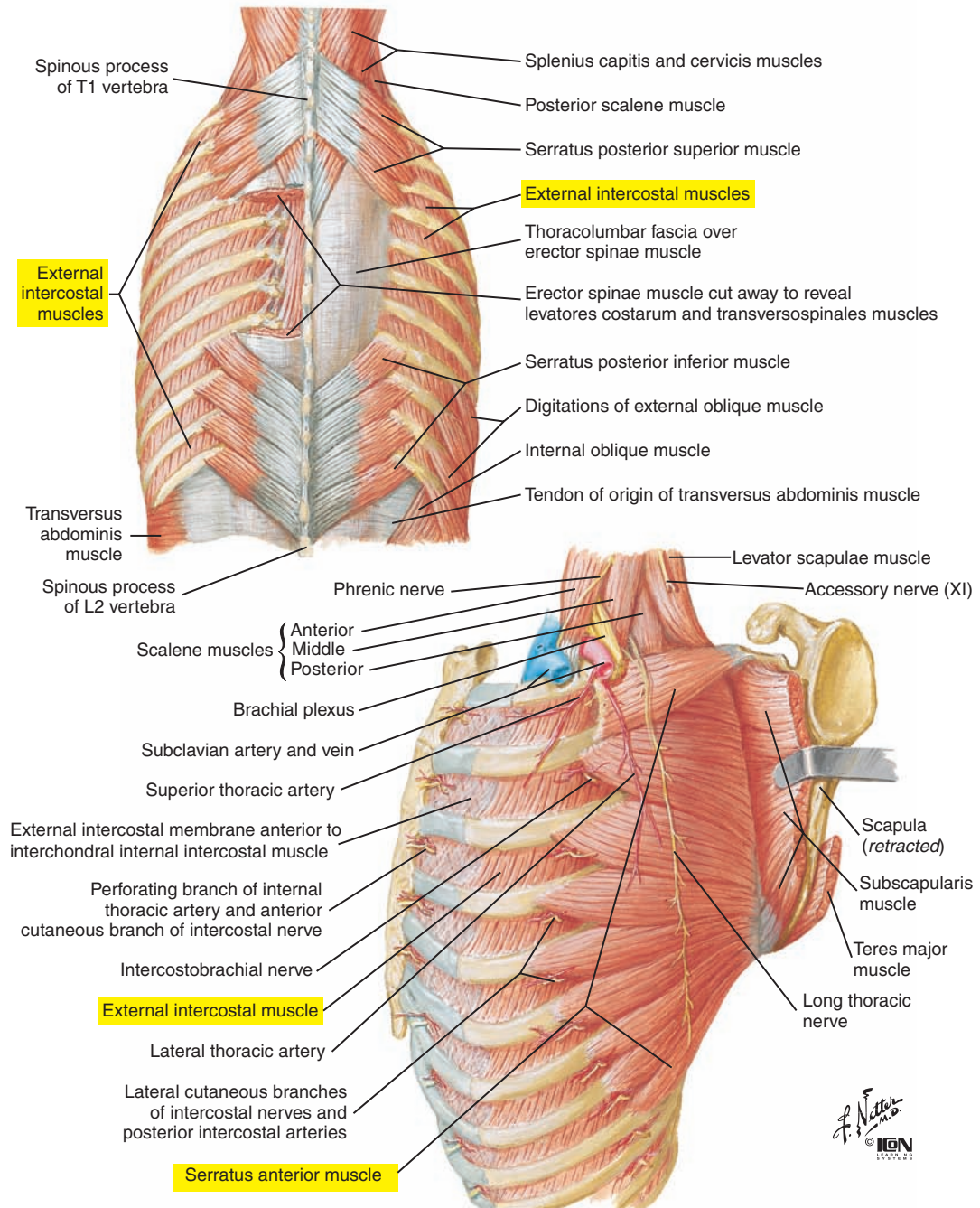
**Figure 1-17.** The deep layers of the muscles of the back. Note that posteriorly the muscle fibers of the external intercostals are oriented inferiorly and laterally.





**Figure 1-18.** The anterior thoracic wall. Note that anteriorly the muscle fibers of the external intercostals are oriented inferiorly and medially.

### Posterior and Lateral Thoracic Walls



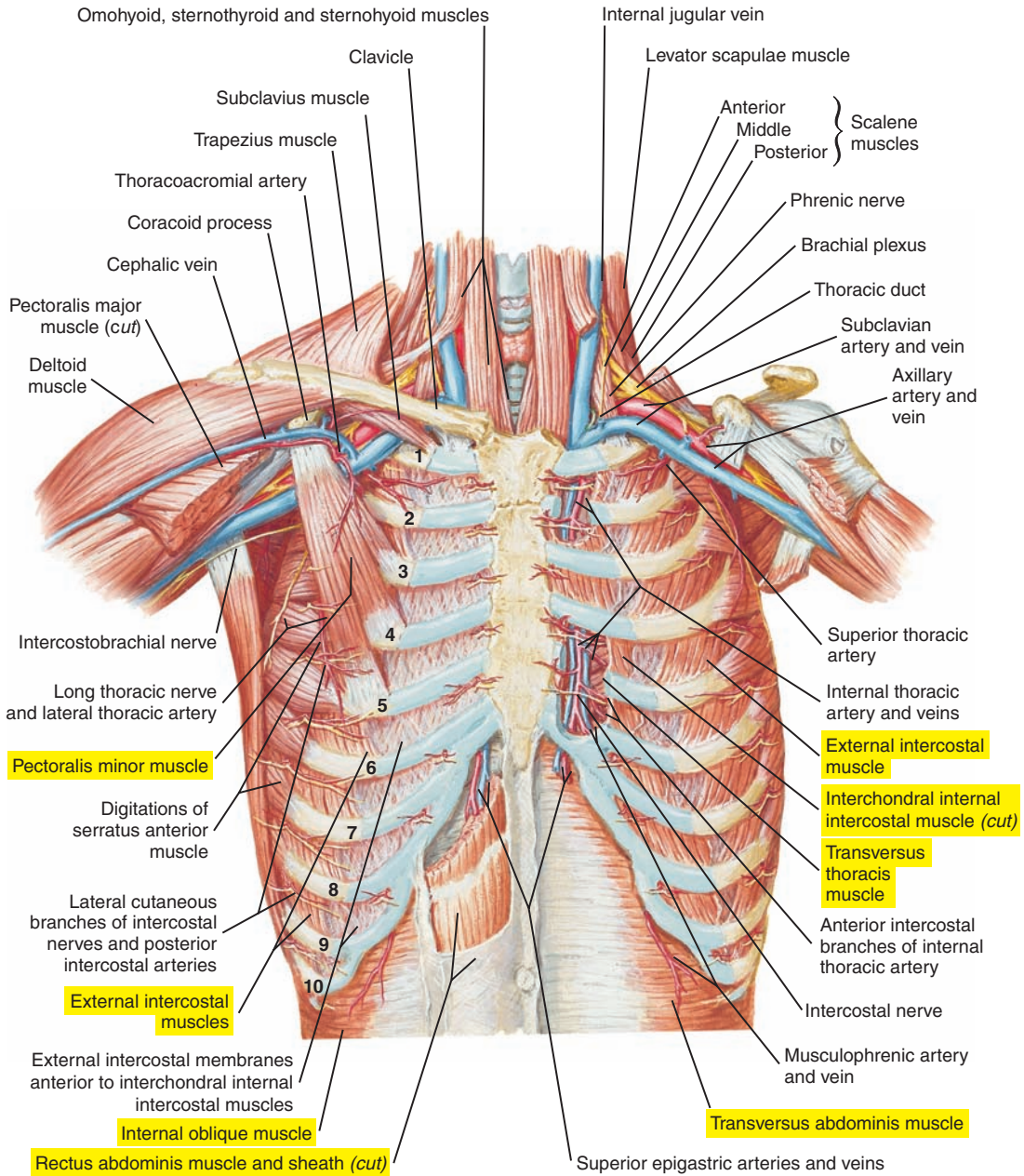
**Figure 1-19.** The posterior and lateral thoracic walls. Note the external intercostal muscles.

***Interchondral (Parasternal) Portion of Internal Intercostal Muscles*** (Figures 1-20 and 1-21 [p. 59])

Fibers extend from the costochondral junction and at approximately right angles to the fibers of the external intercostals (which are absent here) to the sternum; their action is to raise the rib below.

The interchondral internal intercostals are innervated by the intercostal nerves (anterior ramifications of spinal nerves T1 to T11).





**Figure 1-20.** The anterior thoracic wall. Note the interchondral portion of internal intercostal muscles.

**Accessory Muscles of Inspiration** (Figure 1-21; see also Figures 1-17 [p. 53], 1-18 [p. 54], 1-19 [p. 55], and 1-20 [p. 57])

Accessory muscles of inspiration include a potentially large number of muscles that could have an inspiratory effect on the thorax and lungs. The exact respiratory function, however, of these muscles is not completely understood. For example, serratus posterior superior and levatores costarum could, via their mechanical advantage, act to elevate the ribs, but conclusive evidence of their activity during respiratory efforts is lacking.

### **Principal Muscles of Expiration**

The function of the muscles of expiration is to decrease lung volume.

#### ***Interosseous Portion of Internal Intercostal Muscles*** (Figures 1-21 and 1-23 [p. 61])

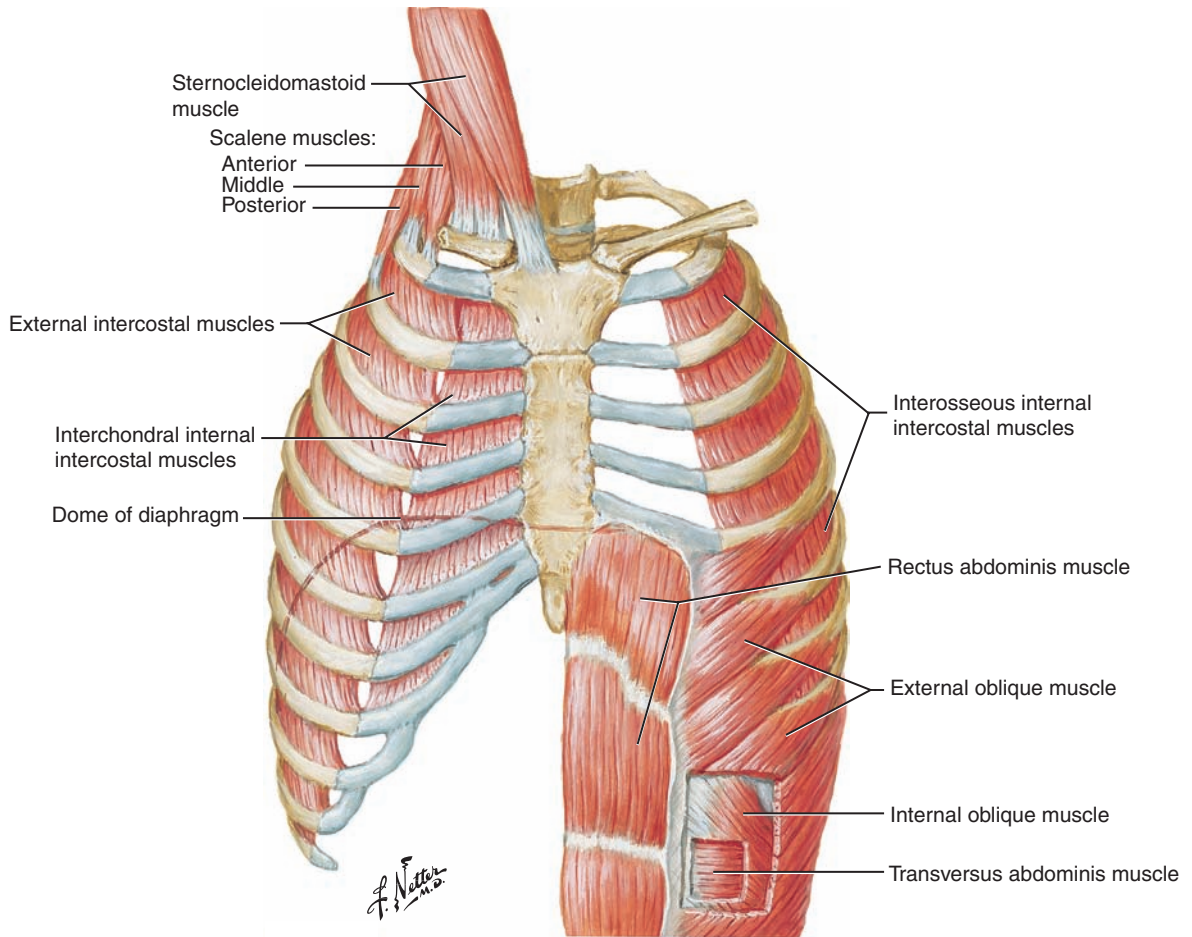
Fibers extend anteriorly (ventrally) from the costochondral junction to near the angle of the ribs posteriorly (dorsally). From there, they are replaced by the internal intercostal membrane. Located deep to the external intercostals on the inner surface of the ribs, they travel obliquely and form approximately a right angle with the external intercostals. Interosseous (nonparasternal) interosseous internal intercostals have an expiratory function to lower the rib above.

The interosseous internal intercostals are innervated by the intercostal nerves (anterior ramifications of spinal nerves T1 to T11).

#### ***Rectus Abdominis Muscle*** (Figures 1-21 and 1-22 [p. 60]; see also Figure 1-18 [p. 54])

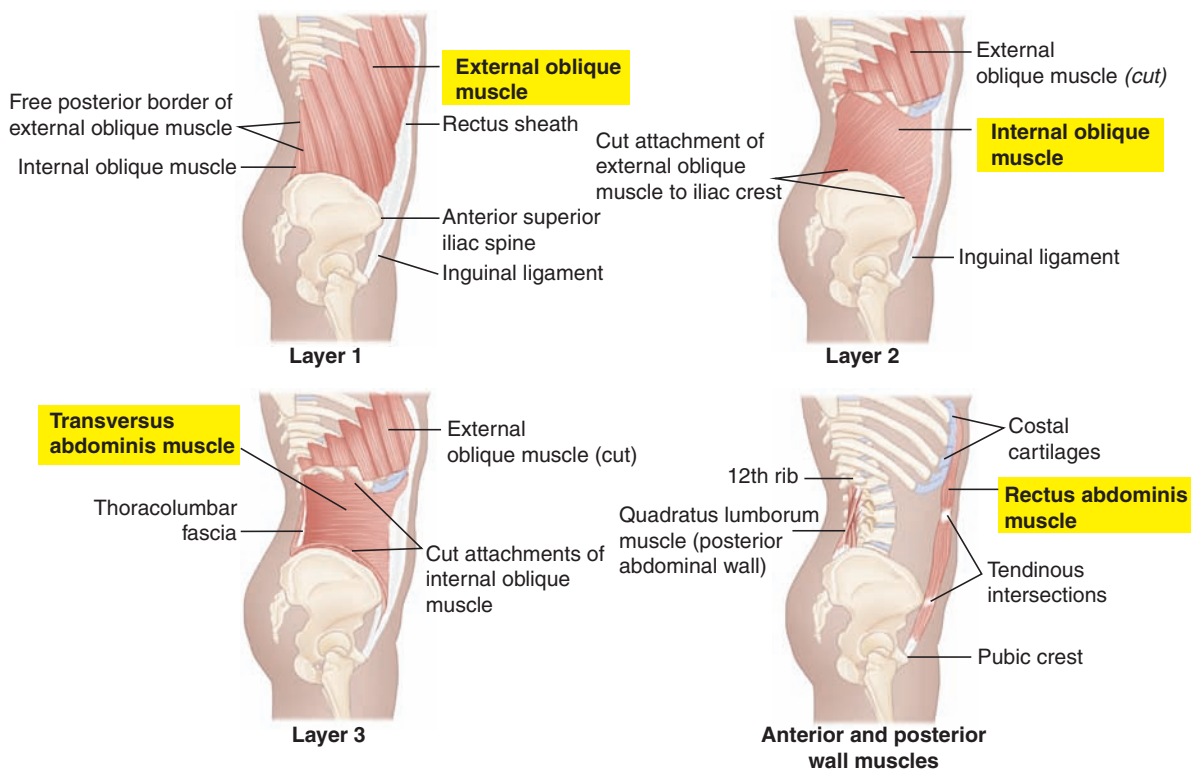
The rectus abdominis muscle is formed by large vertical, paired muscles that extend from the pubis to the sternum and the costal cartilages of ribs 5 through 7. These parallel muscles are enclosed in the rectus sheath, which is a continuation of the abdominal aponeurosis of the more laterally located abdominal muscles. The linea alba (“white line”) of this sheath separates the right and left muscles. Muscular contraction compresses the abdomen.

The rectus abdominis muscle is innervated by intercostal nerves T7 to T11 and the subcostal nerve of T12.



**Figure 1-21.** Muscles of respiration.

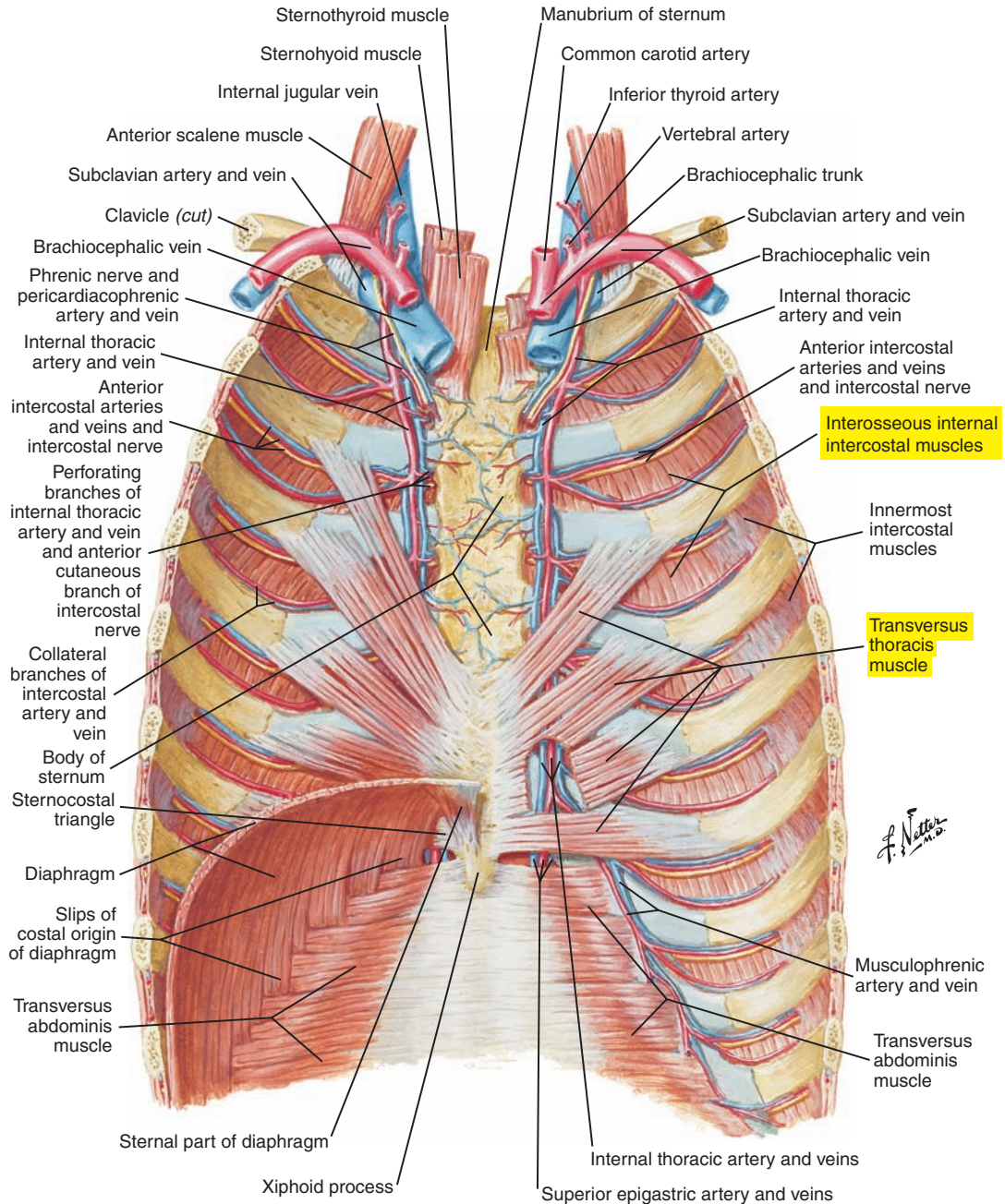
## Lateral Views



Layers 1 - 3: Superficial to deep muscles of anterolateral abdominal wall

Figure 1-22. Lateral view of abdominal muscles.





**Figure 1-23.** An internal view of the anterior thoracic wall. Note the interosseous portion of internal intercostal muscles.

**External Oblique Muscle** (Figures 1-24 and 1-25 [p. 64]; see also Figures 1-18 [p. 54], 1-21 [p. 59] and 1-22 [p. 60])

The external oblique muscle is a large sheetlike muscle that extends from the external surfaces of ribs 5 through 12. It travels obliquely medially and inferiorly to insert on the iliac crest, the inguinal ligament, and the aponeurosis of the external oblique muscle.

The external oblique muscle is innervated by intercostal nerves T7 to T11 and the subcostal nerve of T12.

**Internal Oblique Muscle** (Figure 1-25 [p. 64]; see also Figures 1-18 [p. 54], 1-21 [p. 59], and 1-22 [p. 60])

The internal oblique muscle is another sheetlike muscle that lies deep and almost perpendicular to the external oblique muscle. Fibers originate from the iliac crest, the inguinal ligament, and the thoracolumbar fascia (lumbodorsal fascia) and insert on the inferior borders of ribs 10 to 12 and the abdominal aponeurosis of the internal oblique muscle.

The internal oblique muscle is innervated by intercostal nerves T7 to T11, the subcostal nerve of T12, and the iliohypogastric and ilioinguinal branches of the first lumbar nerve.

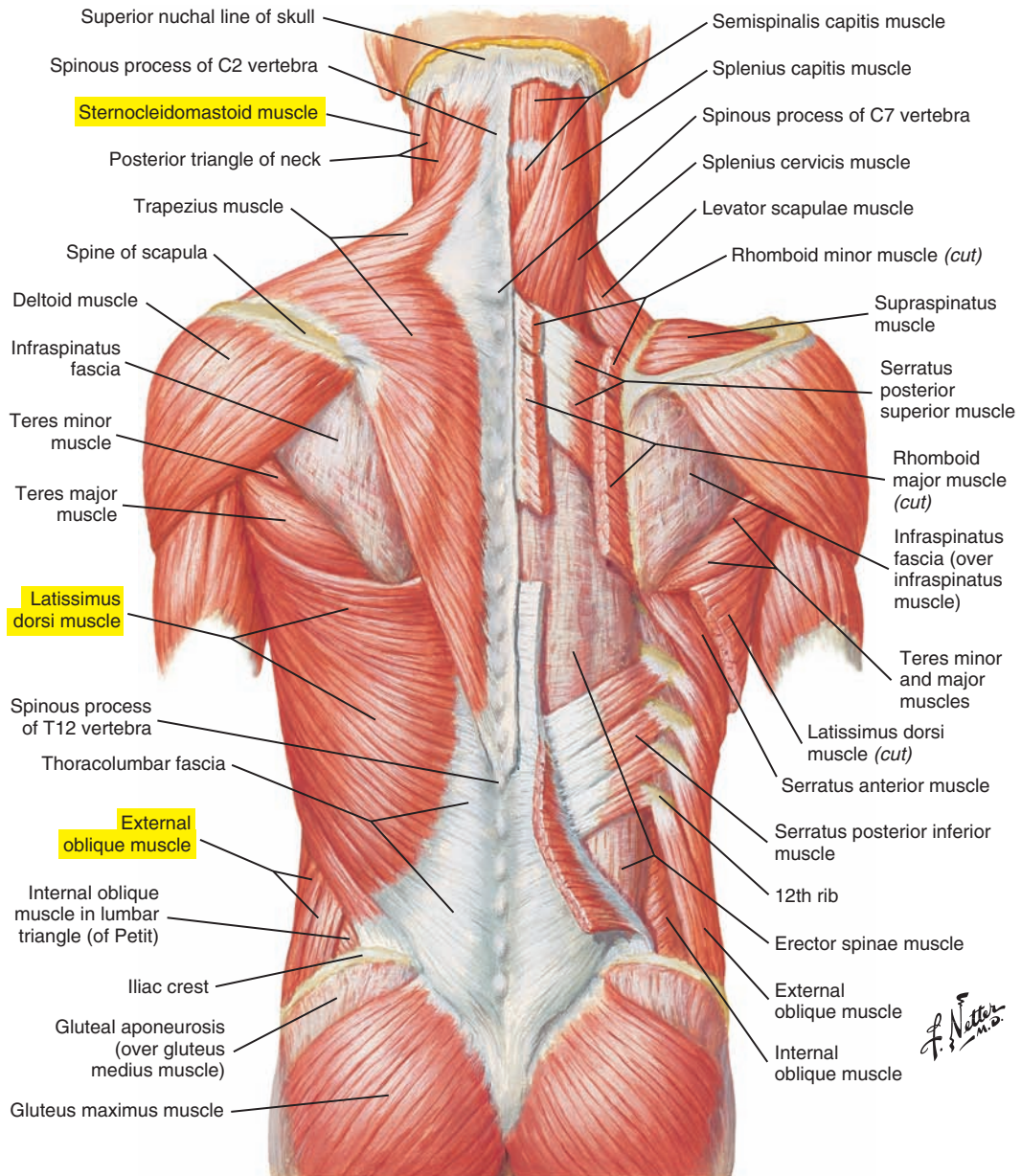
**Transversus Abdominis Muscle** (see Figures 1-20 [p. 57], 1-21 [p. 59], and 1-22 [p. 60])

The most internal of the lateral abdominal muscles, the transverse abdominis muscle arises from the thoracolumbar fascia (lumbodorsal fascia), the iliac crest, the inguinal ligament, and the inner surfaces of the cartilages of the lower six ribs to run circumferentially and ventrally to terminate in the aponeurosis of the transversus abdominis muscle.

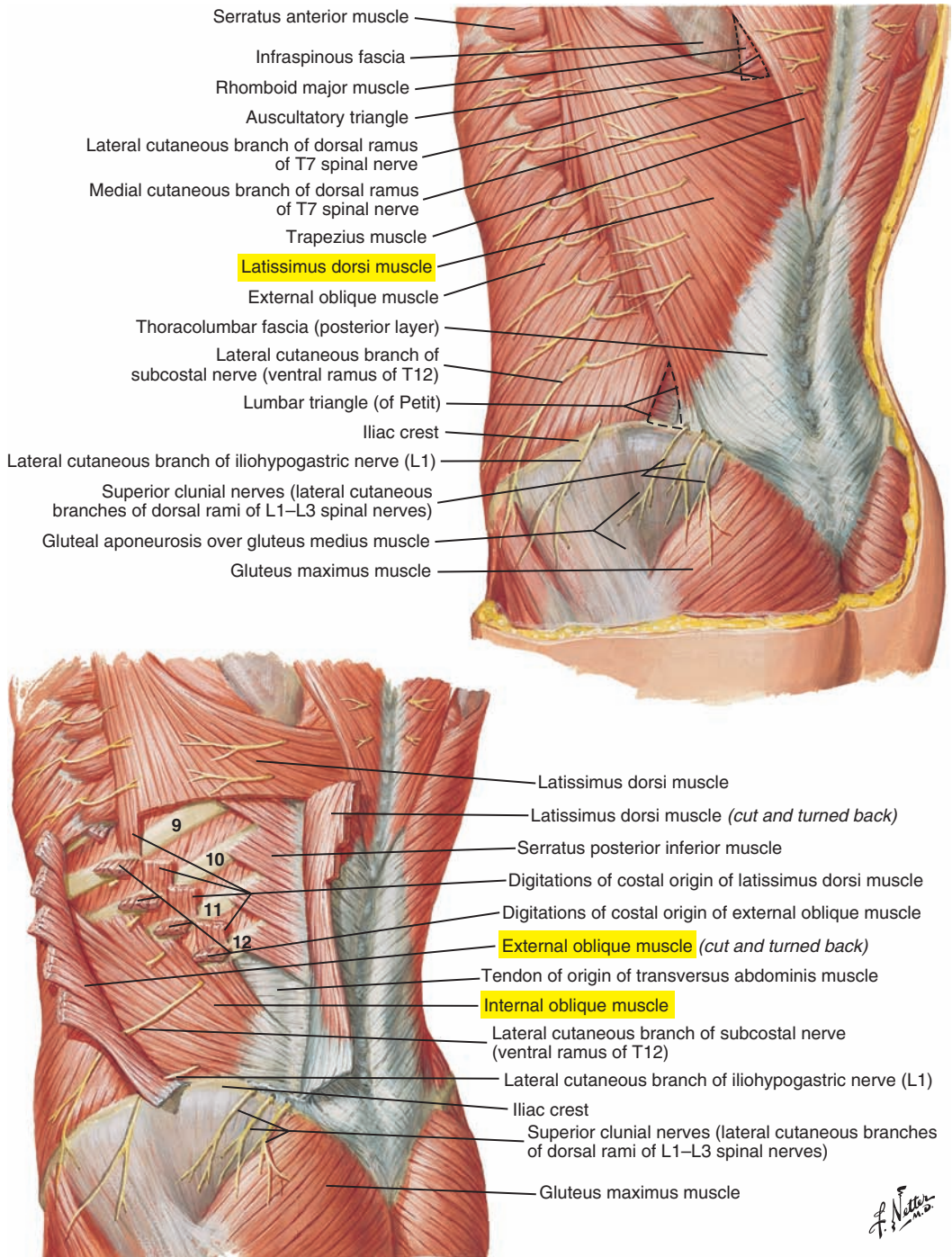
The transversus abdominis muscle is innervated by intercostal nerves T7 to T11, the subcostal nerve of T12, and the iliohypogastric and ilioinguinal branches of the first lumbar nerve.

Tonic abdominal muscle activation, at least in the upright posture, may serve an important “inspiratory” role. Abdominal muscle contraction and the movement of abdominal contents lengthen the diaphragm and increase its force (pressure) generating capabilities. This “inspiratory” action of abdominal muscles may be important for a variety of respiratory functions, including resting quiet breathing and speech production.





**Figure 1-24.** Superficial layers of the muscles of the back. Note the external oblique muscle.



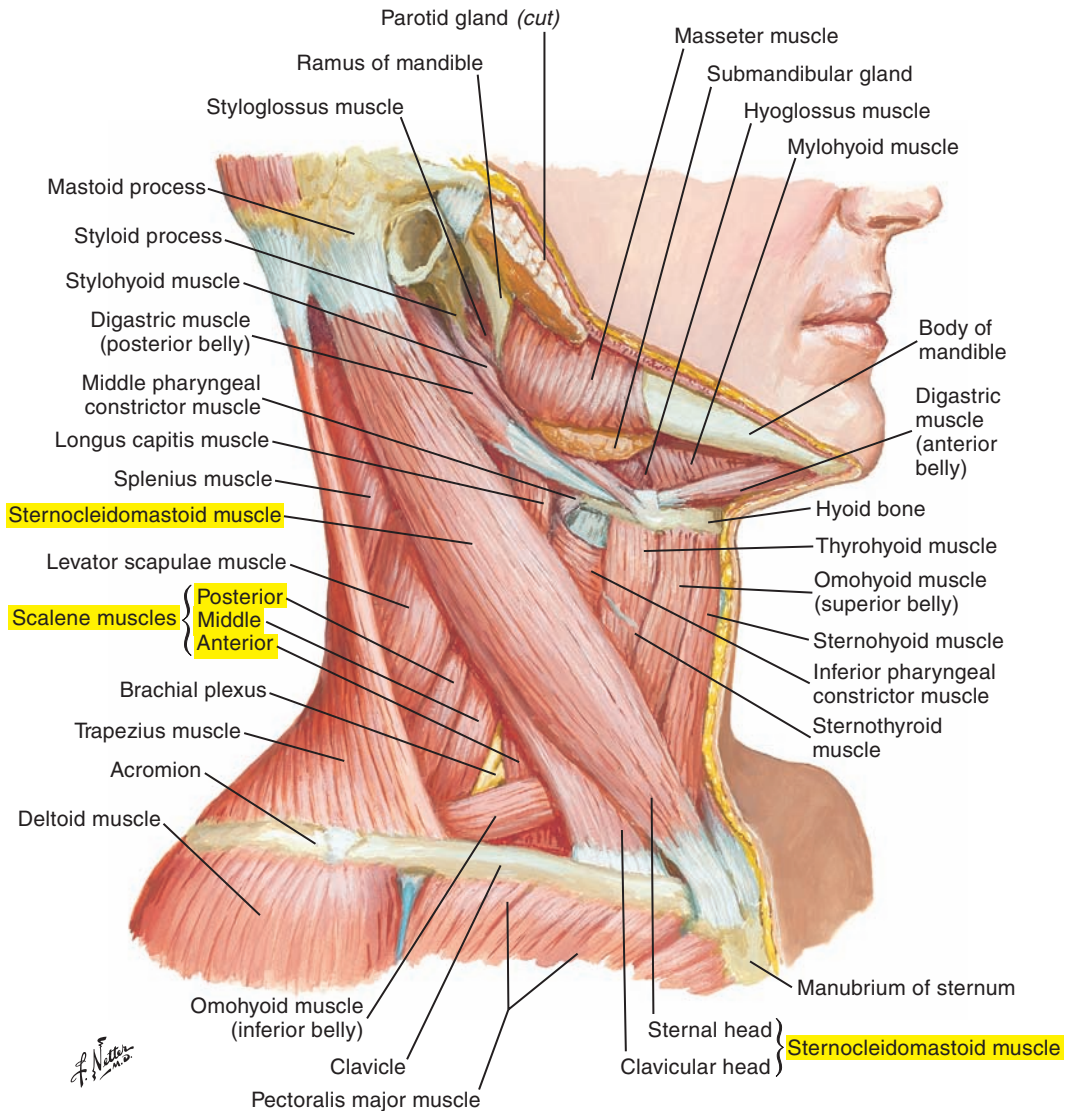
**Figure 1-25.** The posterolateral abdominal wall. Note the internal oblique muscle.

Primary Muscles of Inspiration				
Muscle(s)	Origin	Insertion	Action(s)	Innervation
<p>Diaphragm (see <a href="#">Figures 1-15</a> [p. 50] and <a href="#">1-16</a> [p. 51])</p> <p><b>Three parts</b></p> <ol style="list-style-type: none"> <li>1. Sternal portion</li> <li>2. Costal portion</li> <li>3. Lumbar portion</li> </ol> <p><b>Central tendon</b> Aponeurosis in which the three muscular parts insert</p> <p><b>Openings</b></p> <ol style="list-style-type: none"> <li>1. The aorta passes behind the median arcuate ligament of the diaphragm (see <a href="#">Figure 1-16</a> [p. 51])</li> <li>2. Esophageal hiatus</li> <li>3. Foramen of the inferior vena cava (caval opening)</li> </ol>	<ol style="list-style-type: none"> <li>1. Xiphoid process, inner surface</li> <li>2. Costal cartilages and adjacent portions of the lower six ribs, inner surface</li> <li>3. Superior lumbar vertebrae and medial and lateral arcuate ligaments</li> </ol>	All insert into the central tendon	Contraction; pulls central tendon downward, increasing the vertical and anterolateral dimensions of the thorax	Phrenic nerves originating from cervical spinal nerves C3-C5
External intercostals (see <a href="#">Figure 1-20</a> [p. 57])	Inferior surface of the superior rib	Superior surface of the rib below	Expand the rib cage Stiffen the chest wall	Intercostal nerves (T1-T11)
Interchondral (parasternal) portion of internal intercostals (see <a href="#">Figure 1-21</a> , p. 59)	Inferior surface of rib spaces from the costochondral junction to the sternum	Superior surface of the rib below	Expand the rib cage Stiffen the chest wall	Intercostal nerves (T1-T11)

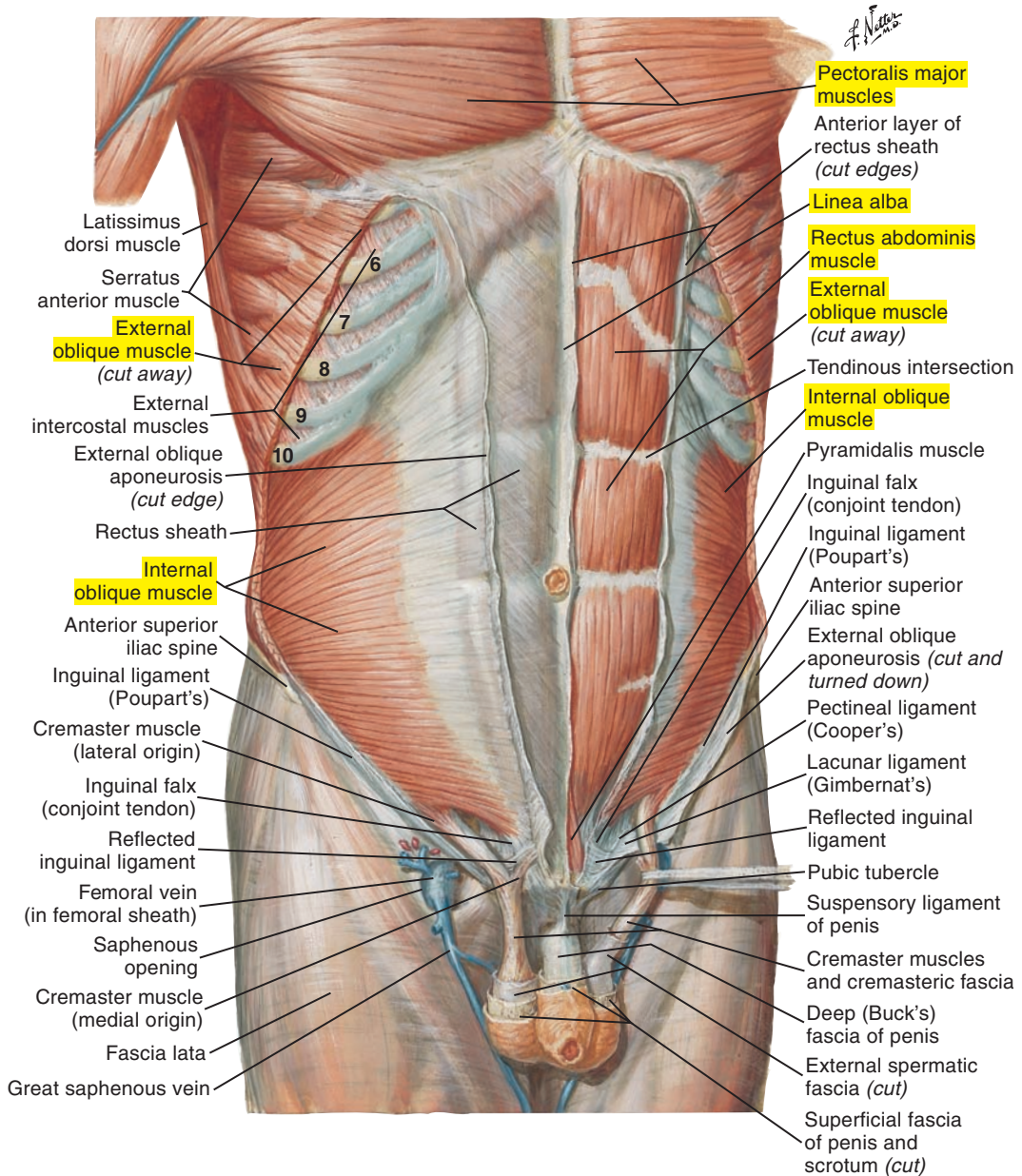
Accessory Muscles of Inspiration				
Muscle(s)	Origin	Insertion	Action(s)	Innervation
Pectoralis major (see <a href="#">Figure 1-18</a> [p. 54])	Greater tubercle of the humerus	Clavicle Sternum Cartilages of ribs 1 or 2 through 6 or 7 Aponeurosis of external oblique	With arm fixed, portions of the muscle pull sternum and ribs upward during forced inspiration May also facilitate forced expiration by drawing the arms medially to compress the rib cage	Lateral and medial pectoral nerves (C5-C8 and T1)
Pectoralis minor (see <a href="#">Figure 1-20</a> [p. 57])	Coracoid process of the scapula	Outer surfaces of ribs 3-5	With the scapula fixed, elevates ribs 3-5 during forced inspiration	Lateral and medial pectoral nerves (C5-C8 and T1)
Serratus anterior (see <a href="#">Figure 1-18</a> [p. 54])	Inner, medial border of the scapula	Eight or nine upper ribs	With the scapula fixed, elevates upper ribs in forced inspiration	Long thoracic nerve (C5-C7)
Sternocleidomastoid ( <a href="#">Figure 1-26</a> ; see also <a href="#">Figure 1-18</a> [p. 54])	Mastoid process of temporal bone	Sternum (manubrium) and clavicle	Raises the sternum and thus the ribs in forced inspiration	Spinal accessory nerve (cranial nerve XI) and cervical spinal nerves C2-C4
Quadratus lumborum (see <a href="#">Figures 1-16</a> [p. 51] and <a href="#">1-17</a> [p. 53])	Iliolumbar ligament and posterior portion of the iliac crest	Medial half of the twelfth ribs and transverse processes of the superior lumbar vertebrae	Fixes the lower rib and provides a base for inspiratory movements of the diaphragm May aid in the precise relaxation of the diaphragm during the expiratory phases of speech and singing	Thoracic spinal nerve (T12) and lumbar spinal nerves (L1-L4)
Scalene muscles*: anterior, middle, and posterior ( <a href="#">Figure 1-26</a> )	Transverse processes of cervical vertebrae C2-C7	Upper surfaces of first and second ribs	Elevate the ribs	Anterior: cervical spinal nerves C4-C6 Middle: C3-C8 Posterior: C6-C8

\*Often listed as accessory muscles of respiration, scalene muscles have been shown to be consistently active during resting inspiration in a variety of animal species, including humans. Some authors, therefore, consider them to be primary muscles of inspiration.





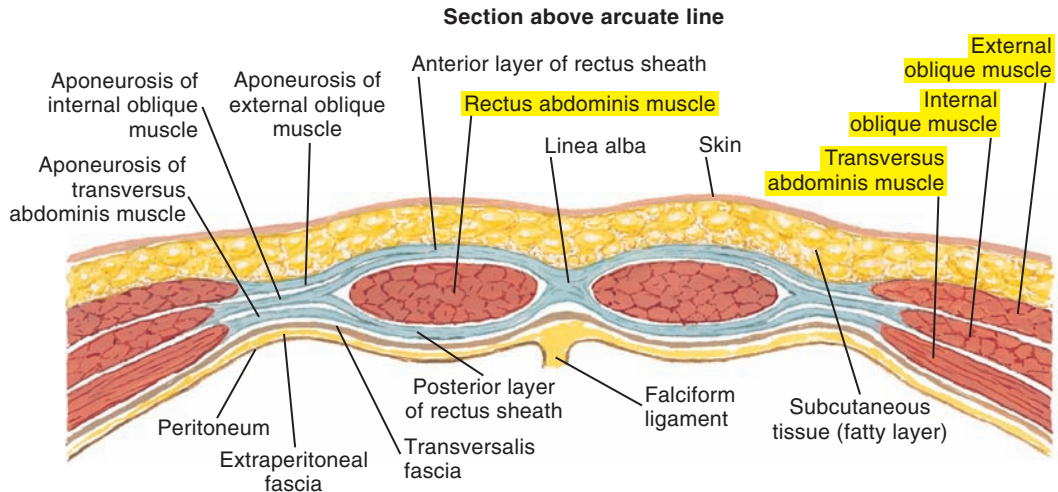
**Figure 1-26.** A lateral view of the muscles of the neck. Note the sternocleidomastoid muscle.



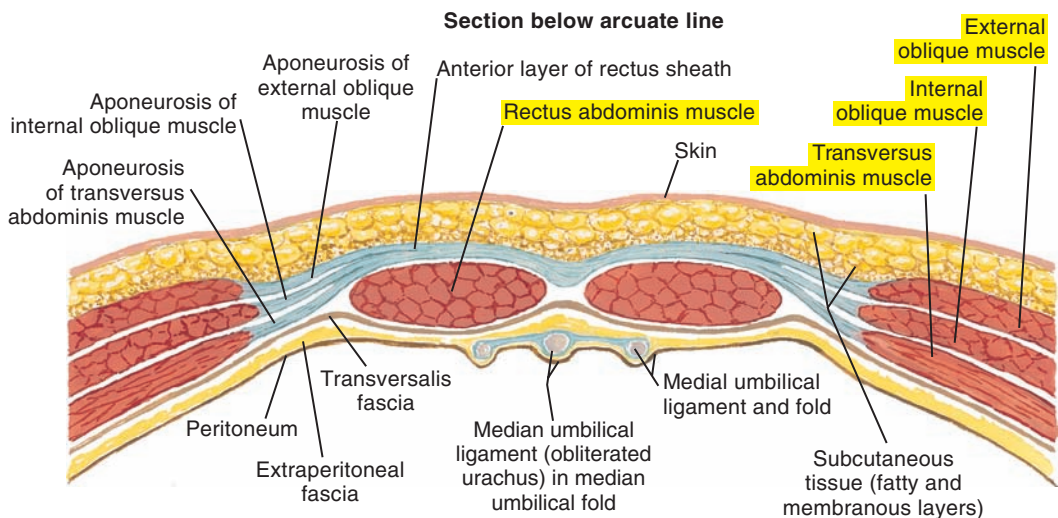
**Figure 1-27.** An intermediate dissection of the anterior abdominal wall. Note the muscles of expiration.



Principal Muscles of Expiration				
Muscle(s)	Origin	Insertion	Action(s)	Innervation
Interosseous portion of internal intercostals (see <a href="#">Figure 1-23</a> [p. 61])	Inner superior surface of the rib below	Inner inferior surface of the rib above	Pull ribs downward Stiffen the chest wall	Intercostal nerves (T1-T11)
Rectus abdominis ( <a href="#">Figures 1-27</a> and <a href="#">1-28</a> [p. 70]; see also <a href="#">Figures 1-18</a> [p. 54] and <a href="#">1-21</a> [p. 59])	Pubic symphysis and pubic crest	Costal cartilages ribs 5-7 and xiphoid process of the sternum	Compresses abdomen	Intercostal nerves (T7-T11) Subcostal nerve (T12)
External oblique ( <a href="#">Figures 1-27</a> and <a href="#">1-28</a> [p. 70]; see also <a href="#">Figures 1-18</a> [p. 54] and <a href="#">1-22</a> [p. 60])	External surfaces of the eight lowest ribs	Iliac crest Inguinal ligament Aponeurosis of the external oblique	Compresses abdomen	Intercostal nerves (T7-T11) Subcostal nerve (T12)
Internal oblique ( <a href="#">Figures 1-27</a> and <a href="#">1-28</a> [p. 70]; see also <a href="#">Figures 1-18</a> [p. 54] and <a href="#">1-22</a> [p. 60])	Iliac crest Inguinal ligaments Thoracolumbar fascia	Costal cartilages of the lowest three or four ribs Aponeurosis of the internal oblique	Compresses abdomen	Intercostal nerves (T7-T11) Subcostal nerve (T12) First lumbar spinal nerve, L1 (iliohypogastric and ilioinguinal branches)
Transversus abdominis ( <a href="#">Figures 1-28</a> [p. 70] and <a href="#">1-29</a> [p. 71]; see also <a href="#">Figures 1-17</a> [p. 53], <a href="#">1-20</a> [p. 57], and <a href="#">1-22</a> [p. 60])	Iliac crest Inguinal ligaments Thoracolumbar fascia Inner surface of cartilages of the lower six ribs	Aponeurosis of the transversus abdominis	Compresses the abdomen	Intercostal nerves (T7-T11) Subcostal nerve (T12) First lumbar spinal nerve, L1 (iliohypogastric and ilioinguinal branches)
Transverse thoracis (triangularis sterni) (see <a href="#">Figure 1-23</a> [p. 61])	Internal surface of the rib cage from the sternum and costal cartilages 5-7	Internal surface of costal cartilages and adjacent portions of ribs 2-6	May pull the ribs slightly downward	Intercostal nerves (T2-T6)
Latissimus dorsi (see <a href="#">Figures 1-24</a> [p. 63] and <a href="#">1-25</a> [p. 64])	Spinous process of the lower six thoracic vertebrae Thoracolumbar fascia Iliac crest Lower 3 or 4 ribs	Anterior superior surface of the humerus	Compresses the thorax for forced expiration such as for coughing With humerus fixed, also elevates ribs for forced inspiration	Thoracodorsal nerve (C6-C8)

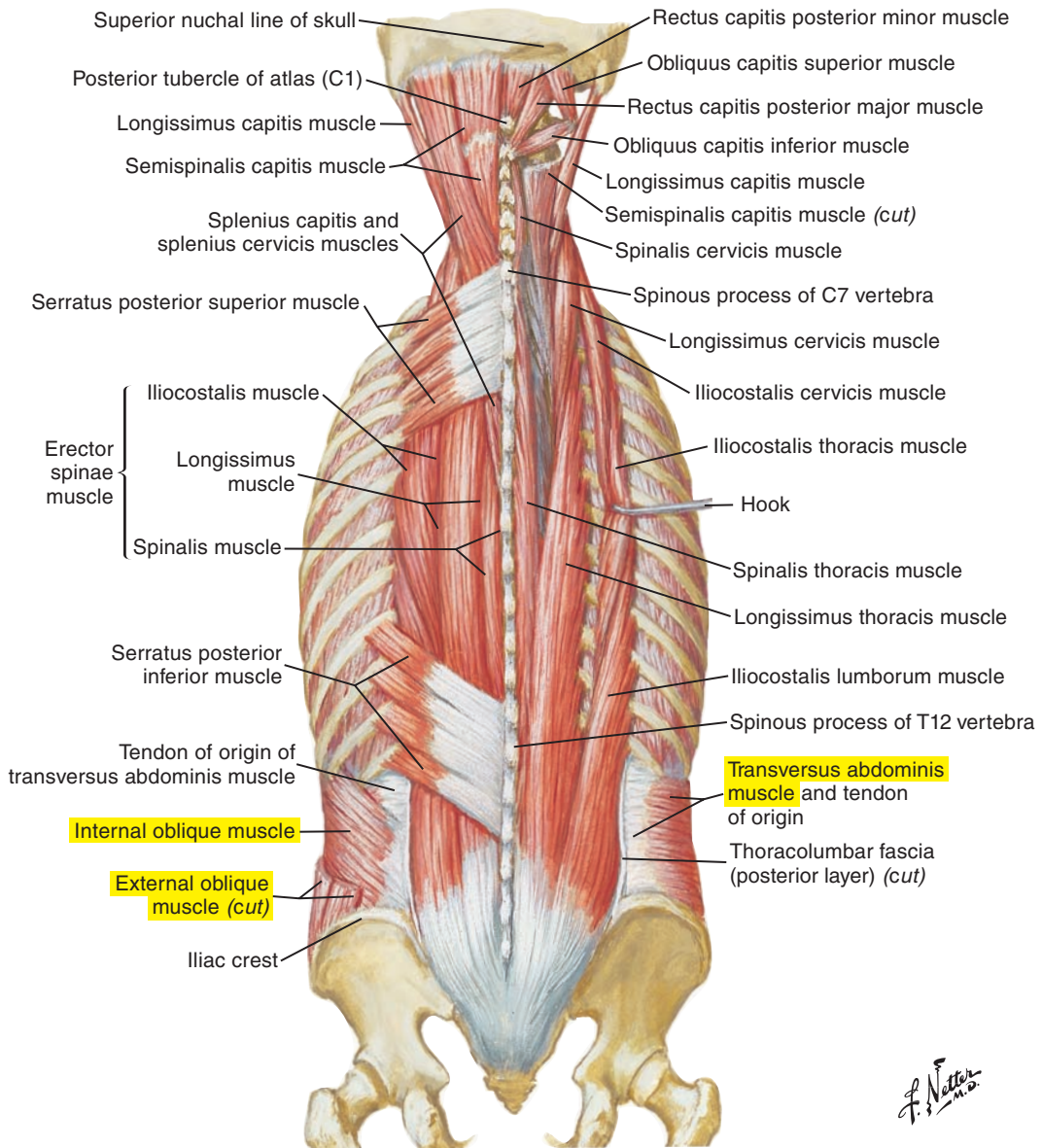


Aponeurosis of internal oblique muscle splits to form anterior and posterior layers of rectus sheath. Aponeurosis of external oblique muscle joins anterior layer of sheath; aponeurosis of transversus abdominis muscle joins posterior layer. Anterior and posterior layers of rectus sheath unite medially to form linea alba.



Aponeurosis of internal oblique muscle does not split at this level but passes completely anterior to rectus abdominis muscle and is fused there with both aponeurosis of external oblique muscle and that of transversus abdominis muscle. Thus, posterior wall of rectus sheath is absent below arcuate line, and rectus abdominis muscle lies on transversalis fascia.

**Figure 1-28.** Cross-sections of the rectus sheath. Note the aponeurosis of the external oblique muscle.



**Figure 1-29.** Intermediate layers of the muscles of the back.

## ■ RESPIRATORY VOLUMES AND CAPACITIES

### Volumes (Figure 1-30)

The different respiratory volumes are mutually exclusive, meaning that they do not overlap, and are as follows:

- **Tidal** volume is the volume (or amount) of air inspired or expired during normal, quiet breathing.
- **Inspiratory reserve** volume is the maximal amount of air that can be inspired above normal inspiratory tidal volume.
- **Expiratory reserve** volume is the maximal amount of air that can be expired below normal expiratory tidal volume.
- **Residual** volume is the amount of air remaining in the lungs after a maximal forced expiration (thus the lungs cannot be completely emptied voluntarily).

### Capacities

Respiratory capacities are sums of volumes and are measured during the following pulmonary function tests:

- **Inspiratory** capacity is the total amount of air that can be inspired after a tidal expiration (tidal volume + inspiratory reserve volume).
- **Functional residual** capacity is the amount of air remaining in the lungs after a normal tidal expiration (expiratory reserve volume + residual volume).
- **Vital** capacity is the total amount of air that can be forcibly expired after a maximal inspiration (inspiratory reserve volume + tidal volume + expiratory reserve volume).
- **Total lung** capacity is the total amount of air after a maximal inspiration. It is the sum of all volumes (residual volume + expiratory reserve volume + tidal volume + inspiratory reserve volume).

### Other Functional Measures

**Minute ventilation** is the amount of air moved into or out of the lungs per minute and is calculated by multiplying tidal volume by breaths per minute (respiratory rate).

**Physiological dead space** is the volume of air remaining in the conducting airways (such as the bronchi, trachea, pharynx, and so on) that does not reach the alveoli and participate in gas exchange (referred to as *anatomical dead space*) and the volume of air that reaches the alveoli but does not exchange carbon dioxide or oxygen (referred to as *alveolar dead space*). Physiological dead space is nearly equal to anatomical dead space in healthy individuals.

**Alveolar ventilation** is the volume of air per minute that reaches the alveoli *and* takes part in gas exchange. It is calculated by subtracting physiological dead space volume from tidal volume and multiplying by respiratory rate.

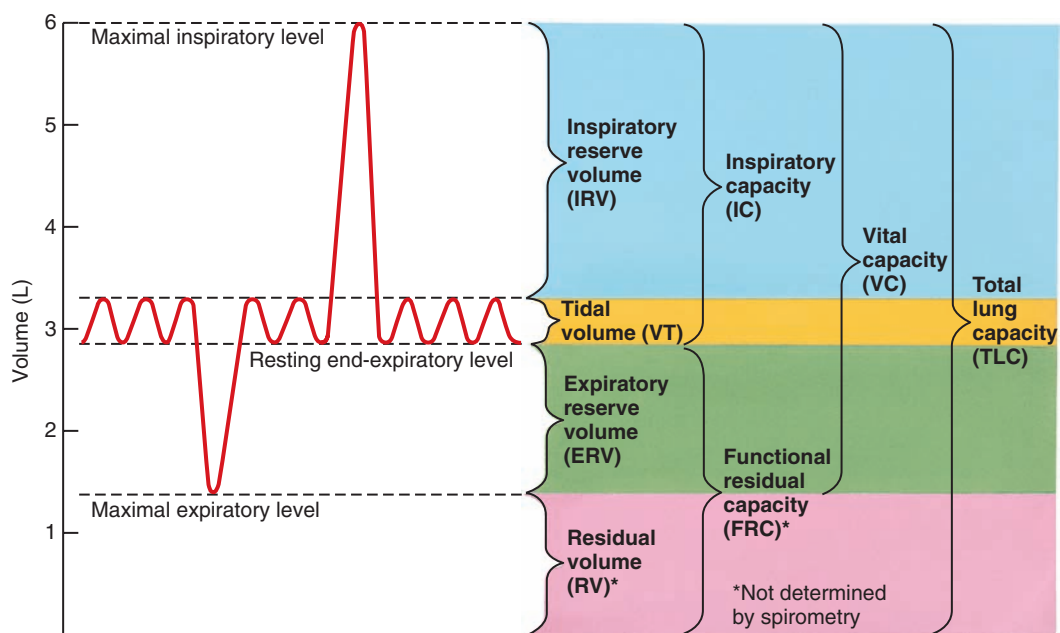
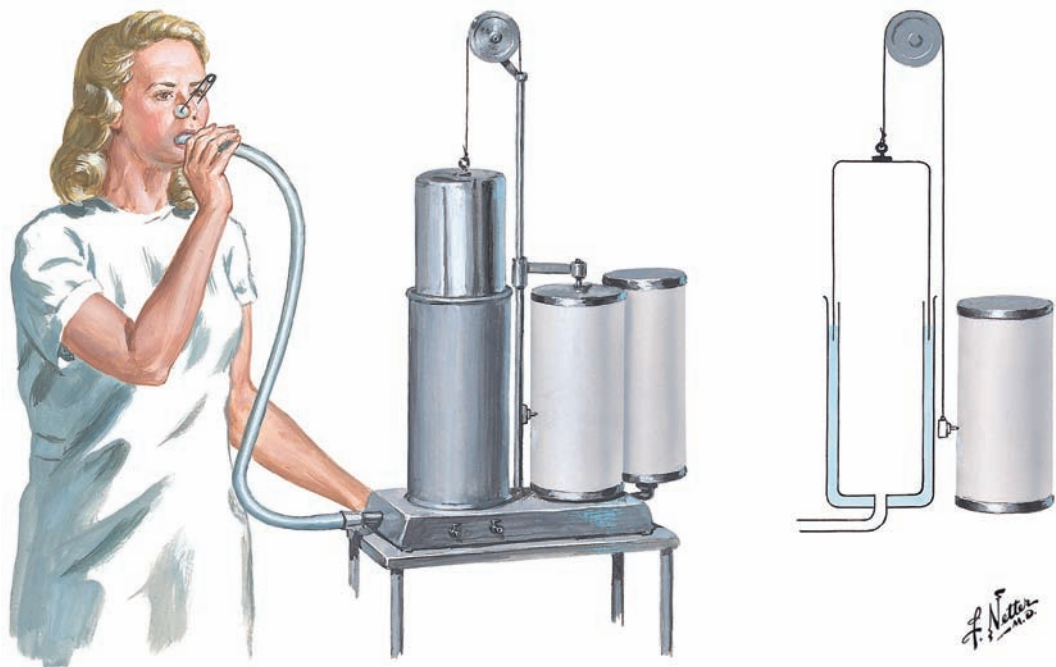


Figure 1-30. Spirometry: lung volumes and subdivisions.



This page intentionally left blank

# LARYNGEAL-PHONATORY SYSTEM

**Overview, 77**

**Larynx, 78**

**Cartilages of the Larynx, 80**

Thyroid Cartilage, 80

Cricoid Cartilage, 80

Arytenoid Cartilages, 80

Corniculate, or Santorini's, Cartilages,  
82

Cuneiform Cartilages, 82

Triticeal (Tritiate) Cartilages, 82

**Epiglottis, 82**

**Hyoid Bone, 83**

**Types of Joints, 83**

**Ligaments and Membranes, 84**

Extrinsic Ligaments and Membranes, 84

**Intrinsic Ligaments and Membranes,  
84**

**Vocal Folds, 86**

Tissue Layers of the Vocal Folds, 86

Classifications of Vocal Fold Layers, 91

**Muscles of the Larynx, 92**

Intrinsic Muscles of the Larynx, 92

Extrinsic Muscles of the Larynx, 96

This page intentionally left blank

## ■ OVERVIEW

The larynx has three primary biological functions. First, it protects and prevents foreign objects from entering the airway (e.g., during swallowing). Second, it traps air in the lungs and stabilizes the torso for physical exertion, such as lifting heavy objects; and third, it modifies upper airway resistance during the inspiratory and expiratory phases of breathing to ensure adequate gas exchange.

Superimposed on these functions is the use of the vocal folds for sound generation. To produce voiced sounds, the vocal folds are closed (adducted), and subglottal pressure (the pressure buildup beneath the folds) overcomes the resistance of the folds, and they open, which releases a burst of compressed air into the supraglottal space known as the *vocal tract*. The elastic recoil of the stretched tissue combined with Bernoulli forces returns the folds to their closed position. The cycle then repeats itself when subglottal pressure overcomes the resistance of the continuously adducted vocal folds. Driven by these pressure pulses, the air above the vocal folds vibrates and provides the acoustic sound source. The sound generated by the vibrating vocal folds is a complex sound that contains a fundamental frequency and harmonics with significant energy up to approximately 4500 Hz. It is this complex acoustical signal that is modified by the resonant characteristics of the vocal tract to produce specific sounds such as vowels.

Variations in fundamental frequency (the rate of opening and closing of the vibrating vocal folds) and its perceptual correlate pitch serve important signalling roles in speech production. Changes in fundamental frequency result from changes in the length and tension of the vocal folds, which in turn result from a complex interplay between intrinsic and extrinsic laryngeal muscles, with the cricothyroid and thyroarytenoid playing crucial roles. Changes in subglottal pressure also influence fundamental frequency.

Increases in vocal intensity (loudness) are related to increased expiratory drive and greater medial compression and tension of the adducted vocal folds. Increased subglottal pressure creates greater lateral excursion of the vocal folds during opening and, consequently, larger pressure pulses (and associated acoustic energy) entering the supralaryngeal vocal tract.

The anatomical terms *abduction* and *adduction* refer to midline movements of the vocal folds to open and closed positions, respectively, by muscular forces. During phonation, the vocal folds are brought to a position of adduction and they remain in this state during vocal fold vibration. The opening and closing of the vocal folds superimposed on the adduction of the vocal folds occurs through the complex interaction of the mechanical and aerodynamic factors described previously.

It should be noted that the laryngeal system also functions as an articulator, rapidly adducting and abducting the vocal folds for voiced (those that involve vocal fold vibration) and unvoiced sounds, respectively, during connected speech. This activity must be precisely timed with respiratory drive and supralaryngeal articulatory movements for specific sound production. The vocal folds also serve a vital function for swallowing. They protect the airway against the penetration and aspiration of foods and liquids.

The components of the laryngeal-phonatory system are presented in this section, including the structural framework of the larynx, the vocal folds, and the associated laryngeal muscles.

## ■ LARYNX (Figures 2-1 and 2-2, [p. 81])

---

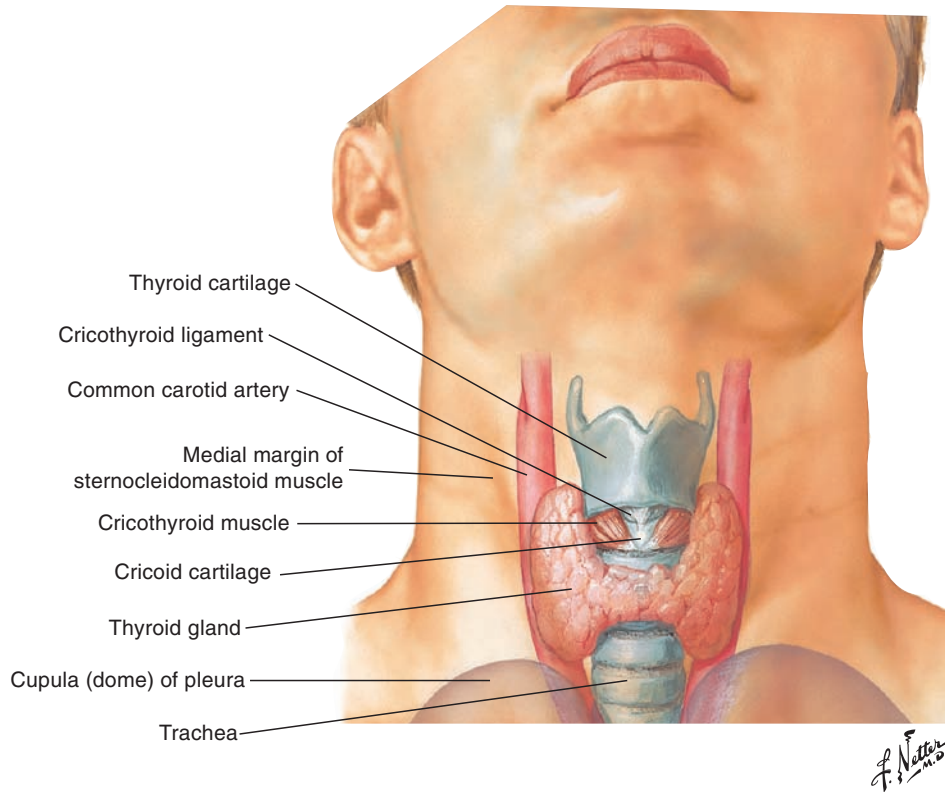
The larynx is approximately 5 cm in length and extends from the level of the third or fourth cervical vertebra to the sixth. It is located in the anterior portion of the neck, in front of the pharynx, above the trachea, and below the hyoid bone. The larynx functions as a two-way valve for the respiratory airway. It can function in this way because of two mobile muscular (and other soft tissue) bands called the *vocal folds*.

The structural framework of the larynx is composed of several paired and unpaired laryngeal cartilages and associated membranes and ligaments, as follows:

- Larger unpaired cartilages:
  - Thyroid cartilage
  - Cricoid cartilage
  - Epiglottis
- Smaller paired cartilages:
  - Arytenoid cartilages
  - Corniculate, or Santorini's, cartilages
  - Cuneiform cartilages
  - Triticeal cartilages

The epiglottis and the corniculate, cuneiform, and triticeal cartilages are formed of elastic cartilage; the rest are formed of hyaline cartilage, which may calcify with advancing age, with the exception of the arytenoid cartilages, which have a dense concentration of elastic cartilage in their vocal processes.





**Figure 2-1.** Position of the larynx, anterior view, in situ.

## ■ CARTILAGES OF THE LARYNX (Figure 2-2)

### Thyroid Cartilage

Situated above and partially surrounding the cricoid cartilage, the thyroid cartilage is composed of two convex lateral, approximately quadrilateral laminae: the quadrilateral or thyroid laminae. These laminae fuse anteriorly to form the thyroid angle of approximately 120 degrees in adult females and 90 degrees in adult males. The more acute angle in the male (which develops during puberty) as contrasted to the female reflects longer and more massive vocal folds. This in turn relates to a lower fundamental frequency of vocal fold vibration (pitch) in adult males (approximately 125 Hz) versus females (approximately 210 Hz) because frequency is inversely proportional to mass.

- A palpable depression or “notch” on the superior surface of the two fused laminae is called the *thyroid notch*. This notch lies directly superior to the laryngeal prominence, or “Adam’s apple,” which is more prominent (and visible) in males versus females. The notch is at the approximate level of the horizontally oriented vocal folds (see later section).
- There are two pairs of horns: two superior horns that articulate with the hyoid bone via the lateral thyrohyoid ligament (lateral thickening of the thyrohyoid membrane), and two smaller inferior horns that articulate with the cricoid cartilage.
- The oblique line on the lateral surface is the point of attachment of the sternothyroid, thyrohyoid, and thyropharyngeus (part of the inferior pharyngeal constrictor) muscles.
- The median (anterior) cricothyroid ligament attaches the thyroid with the cricoid anteriorly.

### Cricoid Cartilage

Cricoid cartilage is situated just above the superior tracheal cartilage. It forms the inferior portion of the larynx and attaches to the trachea via the cricotracheal membrane or ligament. Cricoid cartilage forms a complete “signet” ring, as follows:

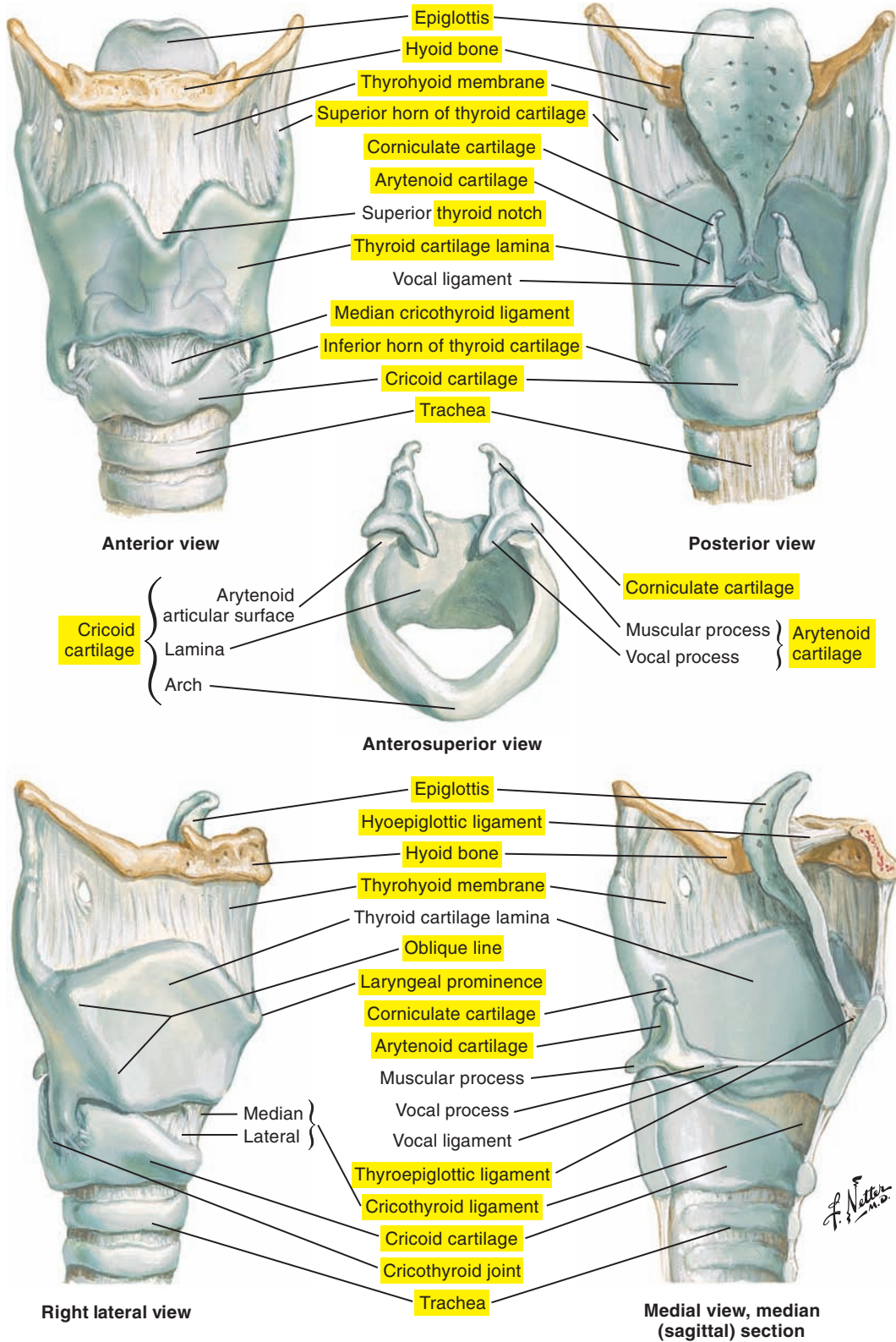
- The front is composed of a low anterior arch.
- The back is composed of a taller posterior quadrate (cricoid) lamina.  
The two paired points of articulation with synovial joints are as follows:
- One point for the arytenoid cartilages is located on the superior surface of the quadrate lamina and allows for adduction and abduction of the paired vocal folds.
- One point for the inferior horns of the thyroid cartilage is located on the lateral surface and allows for movement between the cricoid and thyroid cartilages to adjust the length and tension of the vocal folds.

### Arytenoid Cartilages

The arytenoid cartilages are small pyramidal cartilages with the inferior concave surface or base resting on the convex arytenoid facets on the lateral border of the superior surface of the posterior quadrate lamina of the cricoid. The location and movement of these two cartilages are crucial to laryngeal function.

Three processes of the arytenoid cartilages are as follows:

1. The apex (the pyramid’s summit) is the superior process.
2. The muscular process (site of muscular insertion) extends laterally.
3. The vocal process (site of vocal fold insertion) extends anteriorly.



**Figure 2-2.** The laryngeal cartilages.

NOTE: Labels of certain figures are highlighted in yellow to emphasize the related elements in the corresponding text.

**Corniculate, or Santorini's, Cartilages**

Corniculate cartilages, or Santorini's cartilages, are elastic conical cartilages on the apex of the arytenoid cartilages.

**Cuneiform Cartilages**

Cuneiform cartilages ([Figure 2-3](#) [p. 85]) are covered in soft tissue and situated within the aryepiglottic folds anterosuperior to the corniculate cartilages. They cannot be directly seen, but their presence is indicated by the cuneiform tubercles.

**Triticeal (Tritiate) Cartilages**

The triticeal cartilages are small cartilages located in the lateral hyothyroid ligaments (not present in all people).

**Epiglottis**

The epiglottis is a flexible elastic cartilage situated behind the median portion of the thyroid cartilage, which it exceeds superiorly. It is attached to the inner medial surface of the thyroid angle by the thyroepiglottic ligament. The epiglottis extends obliquely superiorly and posteriorly and attaches to the hyoid bone via the hyoepiglottic ligament. The aryepiglottic fold extends from the lateral margins of the epiglottis to the apexes of the arytenoids.

The epiglottis is attached to the root of the tongue via the median and lateral glossoepiglottic folds to create the valleculae (see Part 3: Oropharyngeal-Articulatory System, pp. 107-170). The pyriform (piriform) sinus (fossa) is a small lateral recess between the aryepiglottic fold (medially) and the thyroid cartilage and thyrohyoid membrane (laterally). The “tipping” of the epiglottis during laryngeal elevation for swallowing may assist in protecting the upper airway.

## ■ HYOID BONE (see Figure 2-2 [p. 81])

---

The hyoid bone provides support for the tongue and the larynx, but it is not generally considered a part of the larynx. It is a “floating” bone that does not have direct contact with any other bone. It is instead attached by a complex system of muscles and ligaments from the tongue and the extrinsic muscles of the larynx and other facial, cranial, and skeletal structures. It is therefore a very mobile structure acted on by several muscle systems.

Located in the neck at the level of the third cervical vertebrae, it is oriented horizontally and has a horseshoe-like shape with the following components:

- A rectangular body (corpus)
- A pair of lesser horns (cornua)
- A pair of greater horns (cornua)

## ■ TYPES OF JOINTS (see Figure 2-2 [p. 81])

---

Three types of joints exist, each differing in its degree of mobility, as follows:

1. Fibrous joint is immobile.
2. Cartilaginous joint is slightly mobile.
3. Synovial joint is highly mobile.

The two important points of articulation and associated joints of the larynx are as follows:

- **Cricothyroid** is the synovial joint between the lesser thyroid horn (inferior horn) of the thyroid cartilage and the articular facets of the cricoid. This joint allows for two types of movements: (1) forward “bending” of the thyroid over the cricoid and (2) anteroposterior gliding of the thyroid in the horizontal axis. Each of these movements potentially impacts the length (and tension) of the vocal folds.
- **Cricoarytenoid** is the synovial joint between the base of the arytenoids and the superior surface of the quadrate lamina of the cricoid. It allows rocking toward (inferiorly medially) or away from (superiorly laterally) the interior of the cricoid, bringing the vocal processes and, consequently, the vocal folds into adduction and abduction, respectively.



## ■ LIGAMENTS AND MEMBRANES

The laryngeal cartilages are linked together and to adjacent structures by extrinsic and intrinsic ligaments and membranes.

### **Extrinsic Ligaments and Membranes** (see [Figure 2-2](#) [p. 81])

The function of the extrinsic ligaments and membranes is to suspend and link the larynx to the following adjacent structures.

#### ***Thyrohyoid (Hyothyroid) Membrane and Ligaments***

The thyrohyoid membrane lies between the superior border of the thyroid cartilage and the hyoid bone. It becomes thicker medially to form the median (middle) thyrohyoid ligament. This membrane also becomes thicker posteriorly and laterally to form the lateral thyrohyoid ligaments, which link the superior horn of the thyroid to the hyoid bone.

#### ***Hyoepiglottic Ligament***

The hyoepiglottic ligament links the anterior surface of the epiglottis to the inner surface of the superior surface of the body of the hyoid.

#### ***Cricotracheal Membrane***

The cricotracheal membrane joins the superior border of the first tracheal ring to the inferior surface of the cricoid.

### **Intrinsic Ligaments and Membranes** ([Figure 2-3](#))

The function of the intrinsic ligaments and membranes is to link and support the laryngeal cartilages. Most of the intrinsic laryngeal membranes arise from a sheet of connective tissue called the *fibroelastic membrane*. Its inferior division is called the *conus elasticus*, and the superior portion is called the *quadrangular membrane*.

#### ***Quadrangular Membrane***

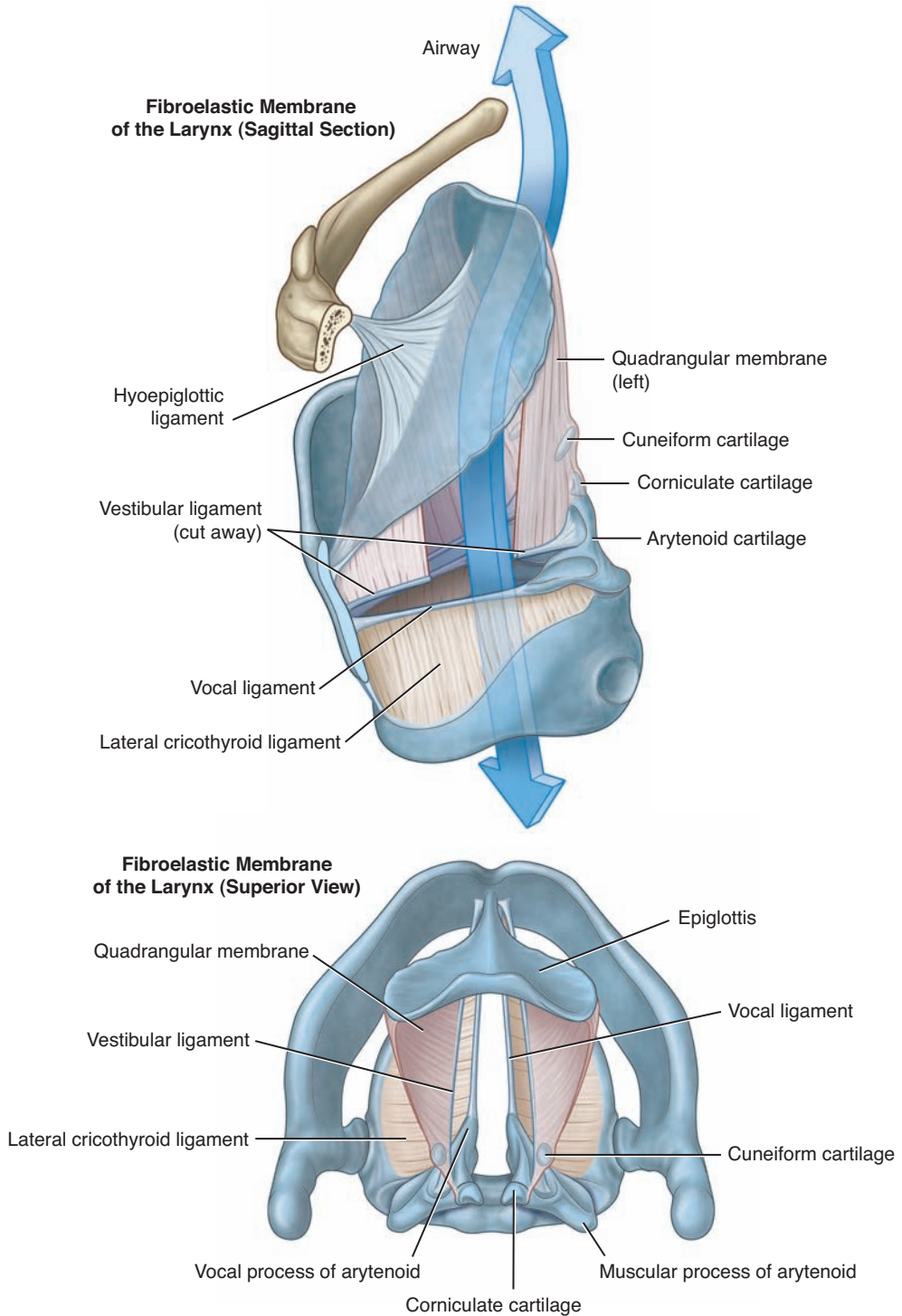
The quadrangular membrane is formed of paired membranes from the lateral edge of the epiglottis and the angle of the thyroid cartilage. These extend posteriorly and inferiorly to the corniculate cartilages and the medial borders of the arytenoids. The quadrangular membrane is wider superiorly and narrows inferiorly to form the vestibular ligament.

The aryepiglottic folds form the free superior border of the quadrangular membrane and extend from the lateral surface of the epiglottis to the apexes of the arytenoids. The cuneiform cartilages are embedded in these folds.

#### ***Conus Elasticus, Cricovocal, or Lateral Cricothyroid Ligament or Membrane***

The conus elasticus is a cone-shaped, thin continuous membrane that extends from the superior surface of the cricoid cartilage, terminating medially as the vocal ligaments. These ligaments extend from the vocal process of the arytenoid cartilages to the angle of the thyroid cartilage and form a portion of the vocal folds.

The conus elasticus is sometimes considered to include the anterior or median cricothyroid ligament (see [Figure 2-2](#) [p. 81]), which is a well-defined elastic tissue that extends from the superior surface of the cricoid arch to the inferior border of the thyroid cartilage near the angle of the thyroid.



**Figure 2-3.** Intrinsic ligaments and membranes of the larynx. (From Drake RL, Vogl AW, Mitchell AWM: *Gray's anatomy for students*, ed 3, Philadelphia, 2015, Churchill Livingstone.)

## ■ VOCAL FOLDS (Figures 2-4, 2-5 [p. 88], and 2-6 [p. 89])

Throughout this atlas, the term *vocal folds* is used to designate the structures involved in the generation of the laryngeal sound source of speech. Although the term *vocal cords* is perhaps better known to the general public, the term *vocal folds* is the more appropriate anatomical term to designate these key laryngeal structures.

The use of the term *vocal cords* may have come from the early visual inspections of the larynx and the appearance of the thickened vocal ligaments, which resemble “cords.” Since then, our understanding of the structure and function of the vibration of the vocal folds has advanced, and we now know that these are complex structures in the form of folds composed of muscles, ligaments, and membranes.

The larynx serves several primary biological functions, including protecting the airway. Simple cords obviously cannot prevent the entry of foreign objects into the lower airway, but false vocal folds forming a laryngeal valve can. There are actually two pairs of vocal folds arranged in parallel and in an anteroposterior orientation, which can be most clearly seen in a coronal section of the larynx (see Figure 2-6 [p. 89]) and described as the following:

- The false vocal folds (vestibular or ventricular folds) do not normally generate a sound source.
- The true vocal folds are inferior to the false vocal folds and are separated from the false vocal folds by a small fissure called the *laryngeal ventricle*.
- The laryngeal vestibule (supraglottic cavity) is superior to the false vocal folds.
- The infraglottic (subglottic) cavity extends from the inferior border of the true folds to the inferior border of the cricoid cartilage.
- The glottic region corresponds to the space between the true vocal folds, which is also known as the *glottis*.
- The aryepiglottic folds form the “collar” or point of constriction of the entryway to the larynx (the laryngeal inlet).
- The quadrangular membrane is located above the vocal folds.
- The conus elasticus is the membranous covering in the subglottic region.

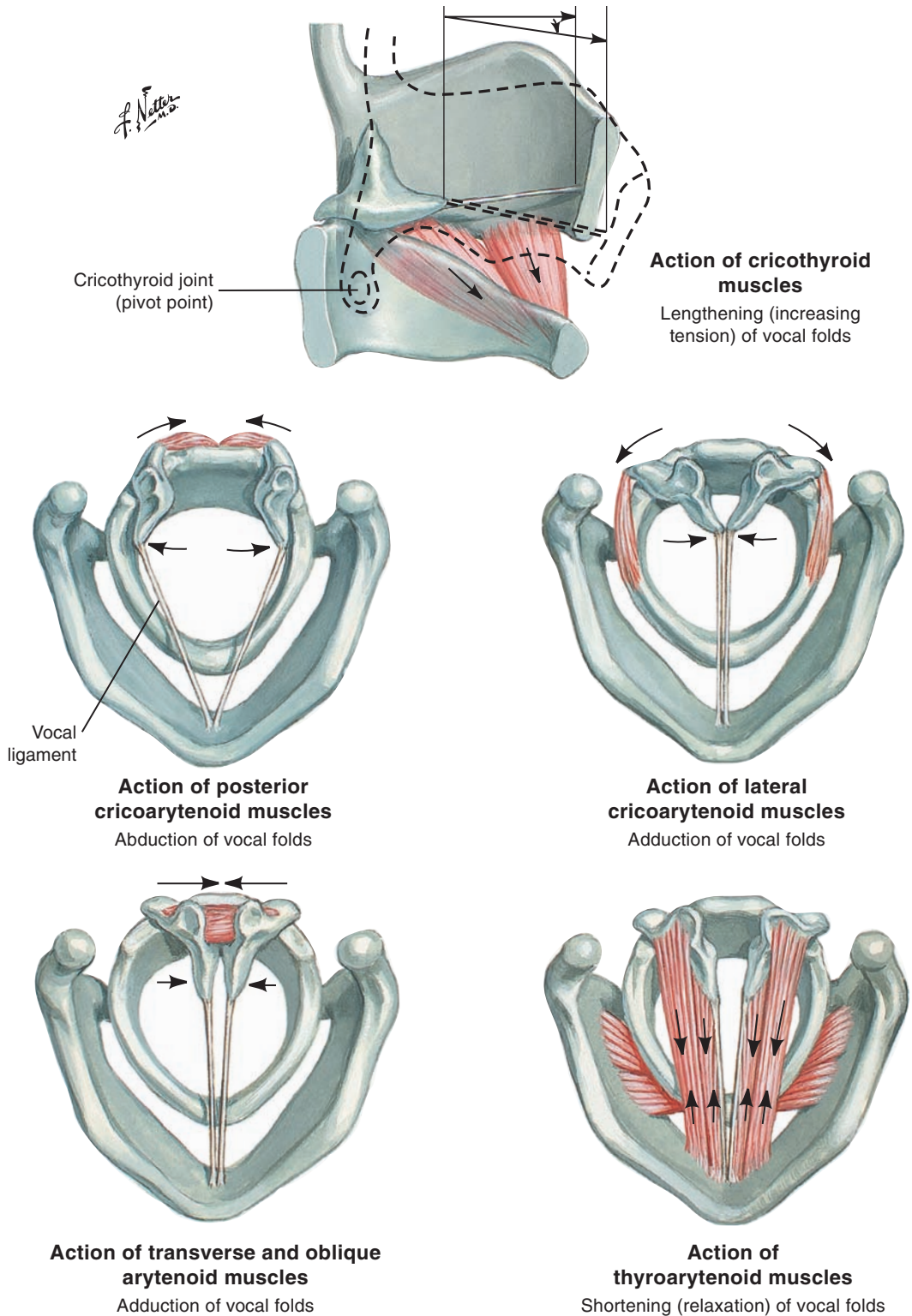
Although estimates vary, vocal fold lengths generally have the following ranges:

- Men: 17 to 25 mm
- Women: 13 to 18 mm

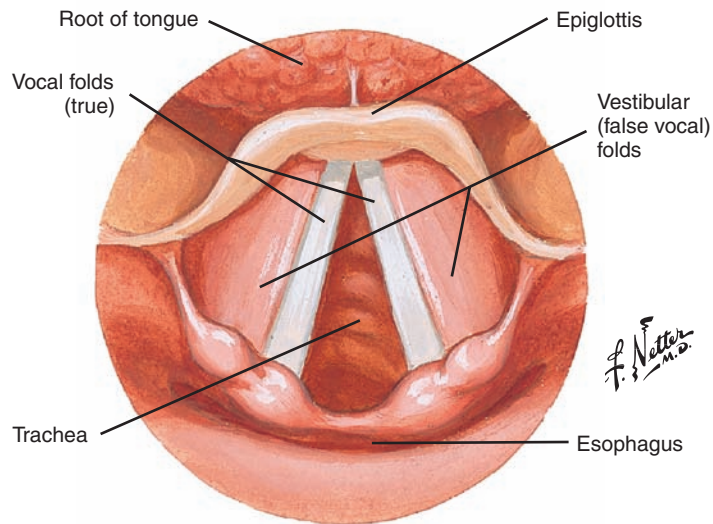
The thickness of the vocal folds is approximately 5 mm.

### Tissue Layers of the Vocal Folds

The vocal folds of an adult are composed of five layers of tissue: (1) the epithelium; (2) the superficial layer; (3) the intermediate layer; (4) the deep layer; and (5) the thyroarytenoid muscle. Each layer differs in terms of thickness and rigidity.

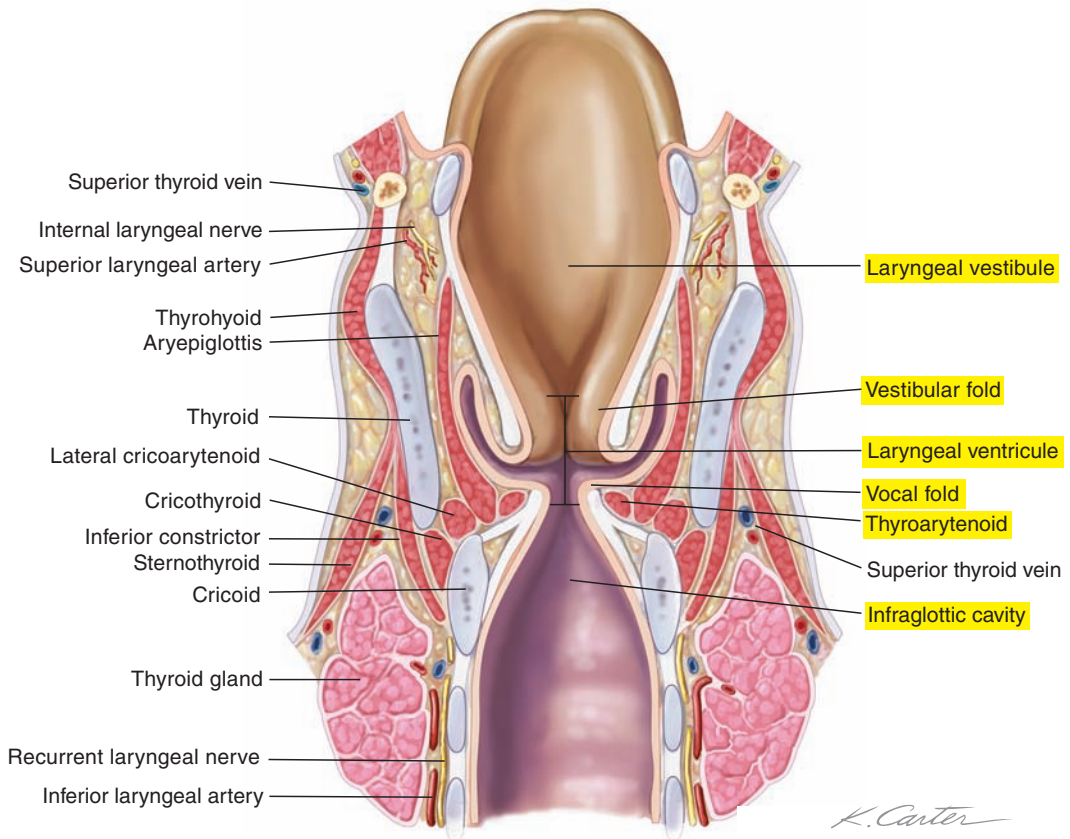


**Figure 2-4.** Actions of the intrinsic muscles of the larynx.

**Laryngoscopic View of the Larynx: Inspiration**

**Figure 2-5.** Abduction of the vocal folds during inspiration.





**Figure 2-6.** The coronal section of the larynx. Note the vestibular and true vocal folds.

### **Epithelium**

The epithelium is stratified, has a thickness of approximately 0.05 to 0.10 mm, and is the rigid layer that maintains the shape of the vocal folds. Under the epithelium is a composite structure of three layers called the *lamina propria*. The lamina propria has a thickness of 1 mm. The epithelium is attached to the superficial layer of the lamina propria by a complex basement membrane.

### **Superficial Layer (Reinke's Space)**

The superficial layer, or Reinke's space, is composed of loosely organized cells that form a gelatinous-like matrix approximately 0.5 mm thick. This layer is responsible for much of the vibratory movements of the vocal folds.

### **Intermediate Layer**

The intermediate layer is formed by elastic fibers and in cross-section appears to resemble a bunch of cut, supple rubber bands.

### **Deep Layer**

The deep layer is formed primarily by collagen fibers, with the consistency of a group of large cotton threads. The intermediate and deep layers form the vocal ligament and together are approximately 1 to 2 mm thick.

### **Thyroarytenoid Muscle**

The thyroarytenoid muscle forms the bulk of the vocal folds and its muscle fibers have the consistency of a packet of rigid rubber bands.

## **Classifications of Vocal Fold Layers**

A variety of biomechanical models have been proposed to explain the vibratory or oscillatory behavior of the vocal folds during phonation. Within a biomechanical perspective, the vocal folds can be grouped into the following functional divisions:

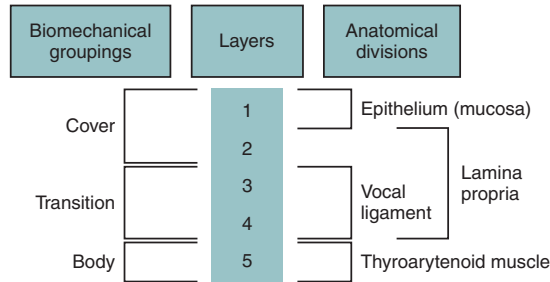
- The **cover** consists of the epithelium (mucosa) and the superficial layer of the lamina propria (layers 1 and 2).
- The **transition** consists of the intermediate and deep layers of the lamina propria (layers 3 and 4) which together form the vocal ligament.
- The **body** consists of the thyroarytenoid muscle (layer 5).

Another two-layer biomechanical scheme combines layers 1 through 3 to form the **cover** and layers 4 and 5 to form the **body**.

From a simplified biomechanical perspective, changes in the length, stiffness (tension), and mass of the vocal folds determine the fundamental frequency of vocal fold vibration and its perceptual correlate of pitch. These parameters, and thus fundamental frequency, are thought to be regulated primarily through activation of the cricothyroid and thyroarytenoid muscles, with the cricothyroid muscle being the primary controller.

The cricothyroid muscle controls fundamental frequency by lengthening and thinning the vocal folds, which increases longitudinal tension and results in increased fundamental frequency.

The contribution of the thyroarytenoid muscle is potentially more complex and may act to raise or lower fundamental frequency depending upon the degree of cricothyroid co-activation and the frequency range being produced (such as high or low pitch).



### Blood Supply

The superior laryngeal branch (superior laryngeal artery) of the superior thyroid artery (a branch of the external carotid artery) supplies the superior part of the larynx. The inferior laryngeal branch of the inferior thyroid artery (from the thyrocervical trunk) supplies the inferior part of the larynx.

### Innervation

The laryngeal muscles and their associated structures are innervated by the following two branches of the vagus nerve\* (cranial nerve X):

1. The internal branch of the superior laryngeal nerve provides sensory innervation for the mucous membrane of the larynx above the vocal folds. The external branch provides motor innervation for the cricothyroid muscle.
2. The recurrent laryngeal nerve provides motor innervation of all intrinsic laryngeal muscles, except for the cricothyroid muscle. It has a sensory function for the mucous membranes below the vocal folds.

The third branch, the pharyngeal nerve, innervates the muscles and mucous membranes of the pharynx and soft palate principally with the contribution of the glossopharyngeal (cranial nerve IX) and trigeminal (cranial nerve V) nerves.

The term *recurrent* means “returns, goes back to its origin.” The recurrent laryngeal nerves distribute widely (particularly on the left side) before returning to provide motor innervation to laryngeal muscles. In their trajectory, the recurrent laryngeal nerves pass near many structures that make them vulnerable to disease and damage during surgical intervention.

\*The name of the vagus nerve comes from the word vagabond, which is related to its large distribution.

## ■ MUSCLES OF THE LARYNX

---

The following two types of muscles affect laryngeal function:

1. The intrinsic muscles, which have their points of attachments within the skeletal framework of the larynx
2. The extrinsic muscles, which have one point of attachment on the laryngeal structures and another attachment outside of the larynx

These muscles are discussed primarily in terms of their impact on the vibratory characteristics of the vocal folds for phonation.

### **Intrinsic Muscles of the Larynx** (Figure 2-7)

The intrinsic muscles of the larynx have their origin and insertion within the larynx. Five intrinsic muscles control the following:

- Adduction-abduction
- Tension-relaxation of the vocal folds
- For adduction, the vocal processes (and the attached vocal folds) are rotated medially and inferiorly; for abduction, the vocal processes are rotated superiorly and laterally.

During phonation, the following two types of adjustment are made:

1. Variation of the medial compression or the degree of force by which the vocal folds are joined at the median line
2. Variation of the longitudinal tension or the degree of stretching of the vocal folds

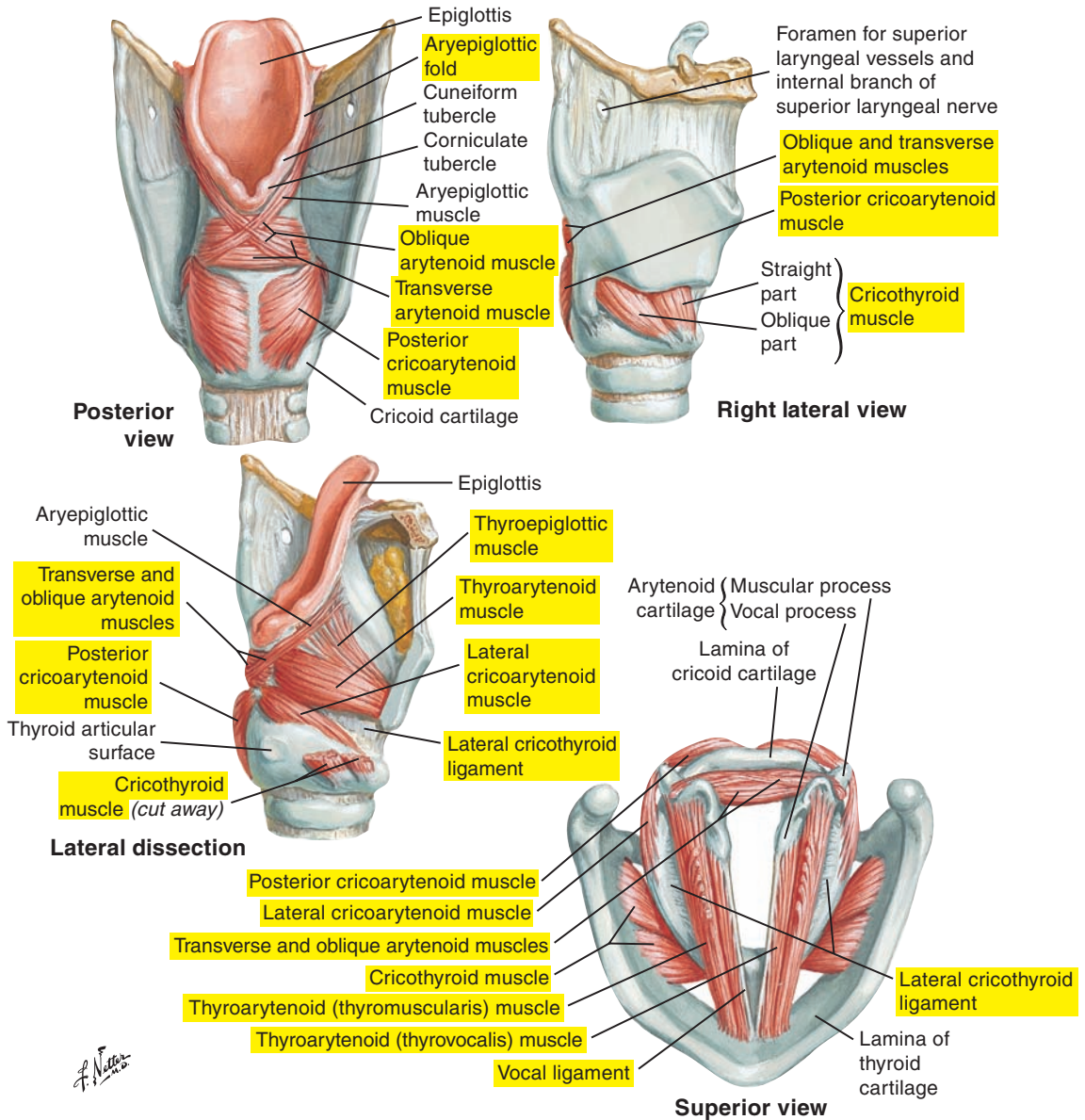
### **Thyroarytenoid Muscle**

The thyroarytenoid muscle forms the major mass of the vocal folds and, consequently, the major portion of the laryngeal “valve” that protects the airway and serves other primary biological functions as previously mentioned. Its anterior origin is the inner surface of the thyroid, below the notch and near the thyroid angle. Taken as a whole, this muscle courses posteriorly to insert on the arytenoid cartilage, from the vocal to the muscular processes. It is deep to, and bounded medially by, the vocal ligament. The thyroarytenoid muscle is often divided into two parts or two subdivisions:

1. Thyrovocalis: medial portion (the vocalis or internal thyroarytenoid)
2. Thyromuscularis: lateral portion (muscularis or external thyroarytenoid)

Isolated, unopposed contraction of the thyroarytenoid shortens and thickens the body of the vocal folds but loosens the cover. The impact on fundamental frequency of vibration of the vocal folds depends upon the degree of co-contraction with the cricothyroid and the frequency range being produced, as discussed previously. Muscle shortening and increased mass may contribute to vocal fold adduction.

The thyroarytenoid muscle is innervated by the anterior division (also known as the *inferior laryngeal nerve*) of the recurrent laryngeal nerve.



**Figure 2-7.** The intrinsic muscles of the larynx.



***Cricothyroid Muscle***

The cricothyroid muscle is a major contributor to increasing vocal fold length and tension (vocal fold tensor) and may also assist in vocal fold abduction.

This muscle has the following two divisions:

1. The upper, more vertically directed portion (pars recta) courses from the anterior portion of the cricoid arch just lateral to the median line to the inferior surface of the thyroid cartilage.
2. The lower oblique portion (pars oblique) arises from the anterior portion of the cricoid arch (laterally to the median line) posteriorly and superiorly to insert on the inferior border of the inferior horn of the thyroid cartilage.

The exact actions of the two portions of the cricothyroid are controversial. The pars recta is thought to rotate the thyroid cartilage inferiorly, and the pars oblique is thought to pull the thyroid anteriorly. This increases the distance between the thyroid and arytenoid cartilages, and because of the attachment of the vocal folds between these two cartilages, increases the length and tension of the vocal folds.

The cricothyroid muscle is innervated by the external branch of the superior laryngeal nerve.

***Posterior Cricoarytenoid Muscle***

The posterior cricoarytenoid muscle is a fan-shaped muscle that is the only abductor muscle of the vocal folds. It arises from the posterior quadrangle lamina of the cricoid, and fibers course superiorly and laterally to insert onto the posterior surface of the muscular process of the arytenoid. This muscle is often divided into medial and lateral bellies. Its action is to rotate the muscular processes downward and toward the midline, which moves the vocal processes laterally and superiorly, lengthening, elevating, and abducting the vocal folds (opens the glottis).

The posterior cricoarytenoid muscle is innervated by the posterior branch of the recurrent laryngeal nerve.

***Lateral Cricoarytenoid Muscle***

The lateral cricoarytenoid muscle acts as a vocal fold adductor. It arises from the superior surface of the lateral border of the cricoid arch to course superiorly and posteriorly and to insert on the anterior portion of the muscular process of the arytenoids. The contraction of the lateral cricoarytenoid muscle pulls on the muscular process and rotates the vocal processes toward the median line, which adducts the vocal folds (closes the glottis).

The lateral cricoarytenoid muscle is innervated by the anterior division of the recurrent laryngeal nerve.

***Interarytenoid (Arytenoid) Muscle***

The interarytenoid (arytenoid) muscle is also an adductor muscle, with the following two parts:

1. The transverse portion is the deeper portion, with horizontally directed fibers from the lateral margin of one arytenoid (between the muscular process and the apex) to the lateral margin of the other.
2. The oblique portion is more superficial, with obliquely directed fibers from the base to the muscular process of one arytenoid to the apex of the other. Some fibers continue superiorly as the aryepiglottic muscle.

The action of the interarytenoid muscle is to pull the two arytenoids together to the midline and thus adduct the vocal folds. The muscle is also involved in the regulation of medial compression between the vocal folds.

The interarytenoid is innervated by the anterior division of the recurrent laryngeal nerve.

**Extrinsic Muscles of the Larynx** (Figures 2-8 and 2-9 [p. 99])

All of the extrinsic muscles have one point of attachment on laryngeal structures or structures that influence laryngeal position and movement (e.g., the hyoid bone). They contribute to the suspension, support, and mobility of the larynx. Extrinsic laryngeal muscles are further classified by whether they are located above or below the hyoid bone.

Actions of the extrinsic muscles are classified in the following two basic groups:

1. Four infrahyoid muscles are sometimes classified as laryngeal “depressors.”
2. Four suprahyoid muscles are sometimes classified as laryngeal “elevators.”

**Four Infrahyoid Muscles**

The unopposed action of the four infrahyoid muscles is to move the larynx downward and to approximate the thyroid cartilage and the hyoid bone. In collaboration with other muscles (suprahyoid muscles), the infrahyoids function to stabilize (fix) the hyoid to provide a firm base for movements of the tongue, such as for speech and swallowing, and for jaw opening.

**Thyrohyoid Muscle**

The thyrohyoid muscle is located deep to the superior portion of the sternohyoid muscle. It courses from the oblique line of the thyroid cartilage to the greater horn of the hyoid bone. Contraction of the thyrohyoid muscle approximates the thyroid cartilage and hyoid bone. Depending on which point of attachment is most mobile and the simultaneous activation of other muscles, the thyrohyoid muscle can pull down on the hyoid bone or lift the thyroid cartilage. Thus this muscle can be classified as either a laryngeal elevator or a laryngeal depressor. As a laryngeal elevator, it contributes to the opening of the upper esophageal sphincter for swallowing.

**Sternohyoid Muscle**

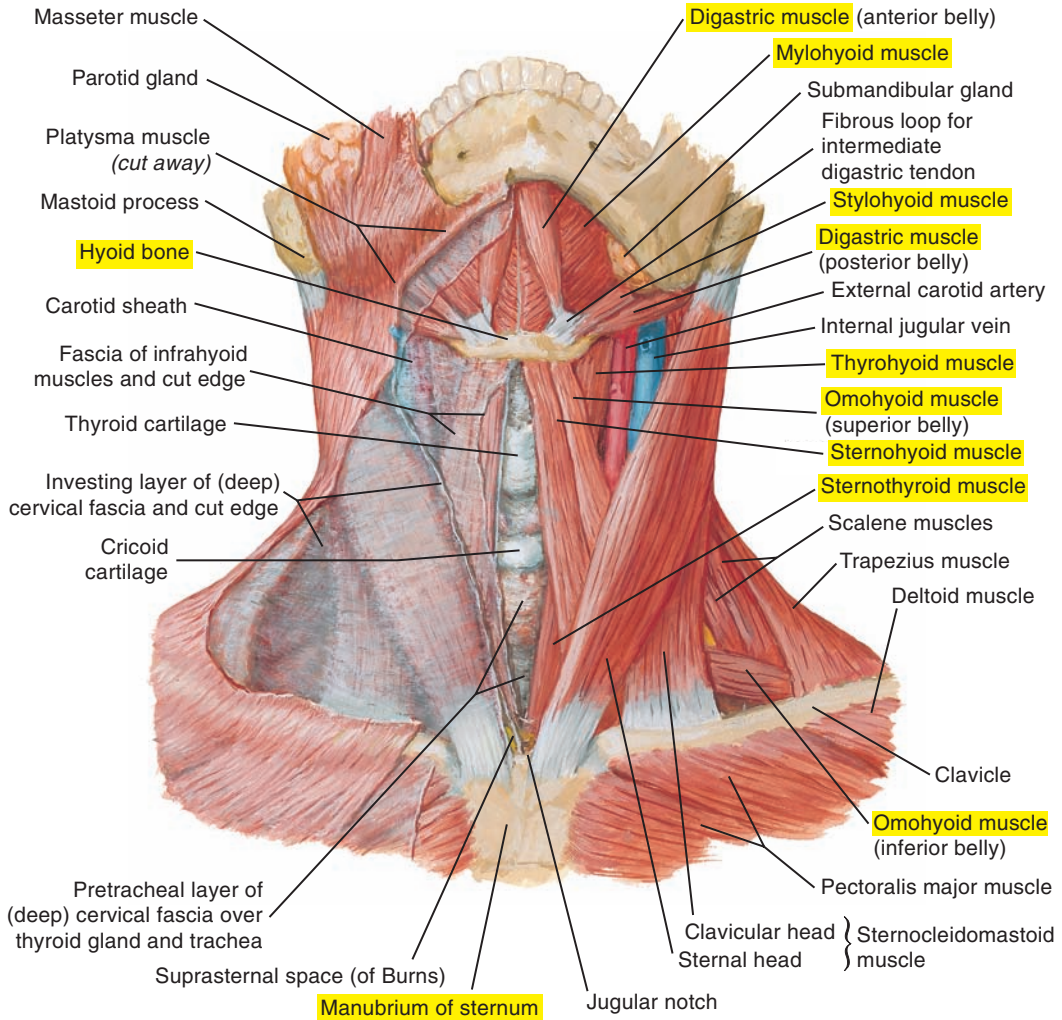
The sternohyoid muscle courses from the sternum to the hyoid bone. It can pull down on the hyoid bone and, with it, the larynx.

**Omohyoid Muscle**

The omohyoid muscle is a two-bellied muscle (inferior and superior) that extends from the scapula through an intermediate tendon to the hyoid bone. Contraction can pull down on the hyoid bone.

**Sternothyroid Muscle**

The sternothyroid muscle is located deep to the sternohyoid muscle and courses from the sternum and first costal cartilage to the oblique line of the thyroid. Contraction of this muscle results in downward movement of the thyroid. It also may shorten the vocal folds, decreasing tension and frequency of vibration.



**Figure 2-8.** An anterior view of the muscles of the neck. Note the four infrahyoid muscles: (1) thyrohyoid, (2) sternohyoid, (3) omohyoid, and (4) sternothyroid.

***Four Suprahyoid Muscles or Laryngeal Elevators***

With the hyoid fixed by the infrahyoid muscles, suprahyoid muscle contraction opens the jaw by pulling down on the mandible. Suprahyoid muscles also elevate the hyoid bone, and move the larynx upward, forward, or backward. As laryngeal elevators, they contribute to the opening of the upper esophageal sphincter.

The four muscles are as follows:

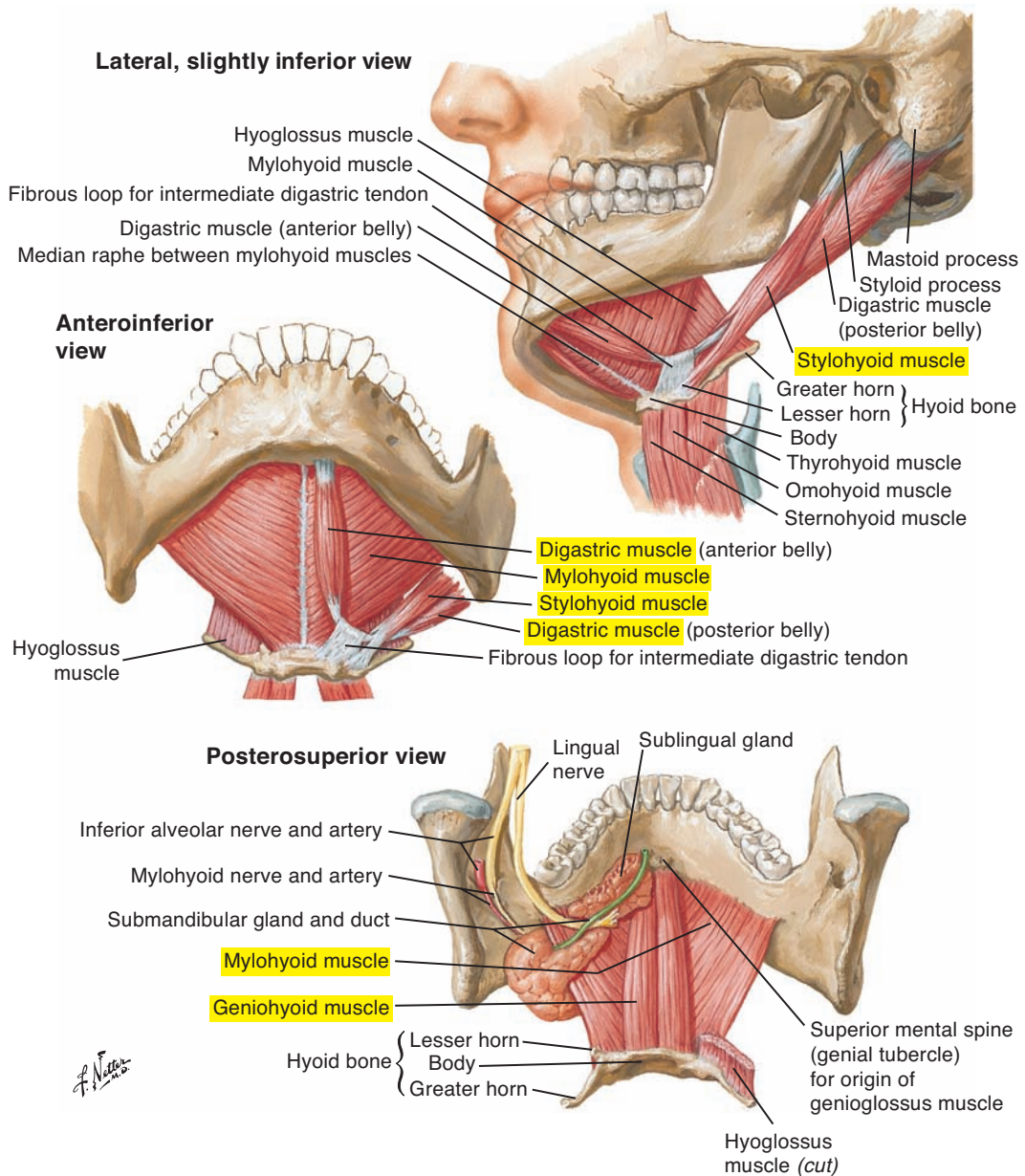
1. Digastric muscle
2. Mylohyoid muscle
3. Geniohyoid muscle
4. Stylohyoid muscle

These muscles all have a point of attachment on the skull or the mandible and another point of attachment on the hyoid bone. Because they play important roles in mastication, swallowing, and the articulatory movements of speech production, the mylohyoid, geniohyoid, and digastric muscles are examined in further detail in Part 3: Oropharyngeal-Articulatory System, pp. 107-170. The stylohyoid muscle is detailed in the table describing extrinsic muscles on p. 102.

***Cricopharyngeal Muscle***

The cricopharyngeal is part of the inferior constrictor muscle forming a portion of the pharynx. It plays an important role in swallowing (see Part 3: Oropharyngeal-Articulatory System, pp. 107-170).





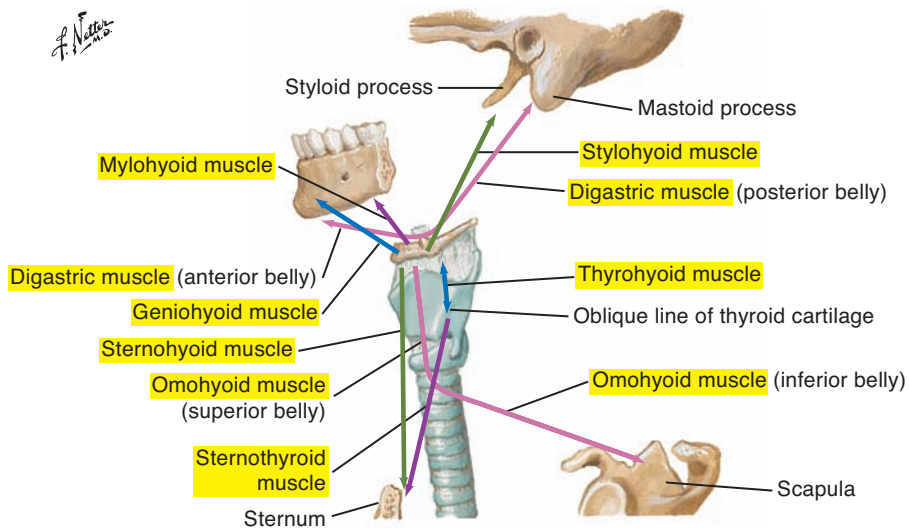
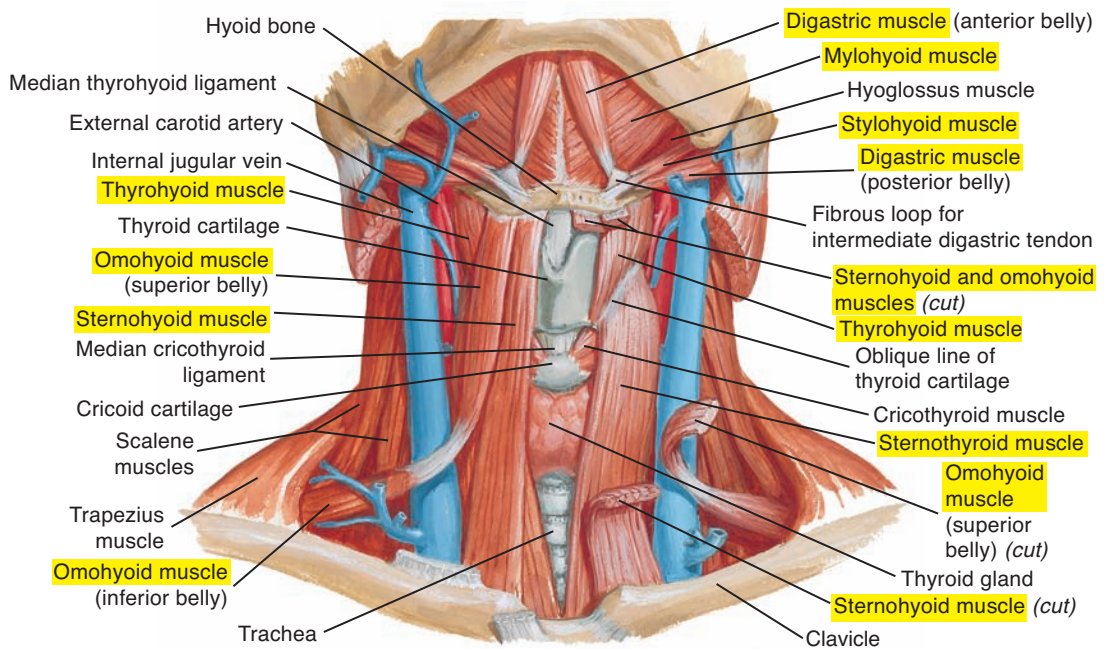
**Figure 2-9.** The floor of the mouth. Note the four suprahyoid muscles: (1) digastric, (2) mylohyoid, (3) geniohyoid, and (4) stylohyoid.

Intrinsic Muscles of the Larynx (see <a href="#">Figures 2-4</a> [p. 87] and <a href="#">2-7</a> [p. 93])		
Muscle(s)	Description	Origin
Thyroarytenoid muscle (sometimes divided into thyromuscularis (muscularis) and thyrovocalis (vocalis) muscles)	Muscle fibers contributing to the vocal folds	Anteriorly from the inner surface of the thyroid
Cricothyroid	Fan-shaped muscle located between the cricoid and the thyroid cartilages, with two divisions: (1) pars oblique and (2) pars recta	Cricoid arch
Posterior cricoarytenoid	Fan-shaped muscle on the posterior surface of the cricoid	Quadrante lamina of the cricoid
Lateral cricoarytenoid	Located deep to the thyroid cartilage	Superior surface of the anterolateral border of the cricoid arch
Interarytenoid	Nonpaired muscle composed of fibers oriented in oblique and transverse direction; oblique fibers cross between the arytenoids to form an X and are located superficial to the transverse fibers	<b>Oblique fibers</b> Between the base and the muscular process of one arytenoid <b>Transverse fibers</b> Lateral border of the arytenoid between the muscular process and the apex

Insertion	Action	Motor Innervation
Vocal and muscular processes of the arytenoids	May function to increase <i>or</i> decrease fundamental frequency depending upon the co-activation of other intrinsic muscles such as the cricothyroid	Recurrent laryngeal nerve of the vagus (cranial nerve X)
Inferior border of the lamina and inferior cornu of the thyroid	Decreases the distance between the thyroid and the cricoid Pulls thyroid anteriorly, lengthening and thinning the vocal folds and increasing longitudinal tension and pitch (tensor)	External branch of the superior laryngeal nerve of the vagus (cranial nerve X)
Posterior surface of the muscular process of the arytenoid	Laterally rotates the arytenoids and opens the glottis (abductor)	Recurrent laryngeal nerve of the vagus (cranial nerve X)
Anterior surface of the muscular process of the arytenoid	Medially rotates the arytenoids and closes the glottis (adductor)	Recurrent laryngeal nerve of the vagus (cranial nerve X)
<b>Oblique fibers</b> Apex of the opposite arytenoid Continuous with aryepiglottic muscle fibers <b>Transverse fibers</b> Lateral border of the opposite arytenoid	Approximates the arytenoids and closes the glottis (adductor)	Recurrent laryngeal nerve of the vagus (cranial nerve X)

Extrinsic Muscles of the Larynx (Suprahyoid Muscles)					
Muscle(s)	Description	Origin	Insertion	Action	Innervation
Digastric ( <a href="#">Figure 2-10</a> [p. 104]; see also <a href="#">Figure 2-9</a> [p. 99])	Anterior and posterior bellies linked by a tendon attached to the body and greater horn of the hyoid bone	Medial surface of the mastoid process of the temporal bone	Lower border of the mandible near the midline with the intermediate tendon tethered to the hyoid by a fibrous loop of connective tissue	With the mandible stabilized, aids in elevating the hyoid	<b>Posterior belly</b> Digastric branch of the facial nerve (cranial nerve VII) <b>Anterior belly</b> Mylohyoid branch of the inferior alveolar nerve of the mandibular division of the trigeminal (cranial nerve V)
Mylohyoid ( <a href="#">Figure 2-11</a> [p. 105]; see also <a href="#">Figure 2-9</a> [p. 99])	Thin muscle forming the muscular “floor” of the oral cavity Deep to the digastric	Mylohyoid line on the internal surface of the mandible	<b>Posterior fibers</b> Body of the hyoid bone <b>Anterior fibers</b> Linked with fibers of the opposite side through the median raphe	Pulls hyoid superiorly	Mylohyoid branch of the inferior alveolar nerve of the mandibular division of the trigeminal (cranial nerve V)
Geniohyoid (see <a href="#">Figures 2-9</a> [p. 99] and <a href="#">2-11</a> [pp. 105])	Narrow, cylindrical muscle deep to the mylohyoid	Inferior mental spine (genial tubercle) on the internal surface of the mandible	Anterior surface of the body of the hyoid	Pulls hyoid anteriorly	First cervical spinal nerve (C1) traveling with fibers of the hypoglossal nerve (cranial nerve XII)
Stylohyoid (see <a href="#">Figures 2-9</a> [p. 99] and <a href="#">2-11</a> [p. 105])	Long, thin muscle roughly parallel to the posterior belly of the digastric	Styloid process of the temporal bone	Body of the hyoid bone near the greater horn	Elevates and retracts the hyoid bone	Stylohyoid branch of the facial nerve (cranial nerve VII)

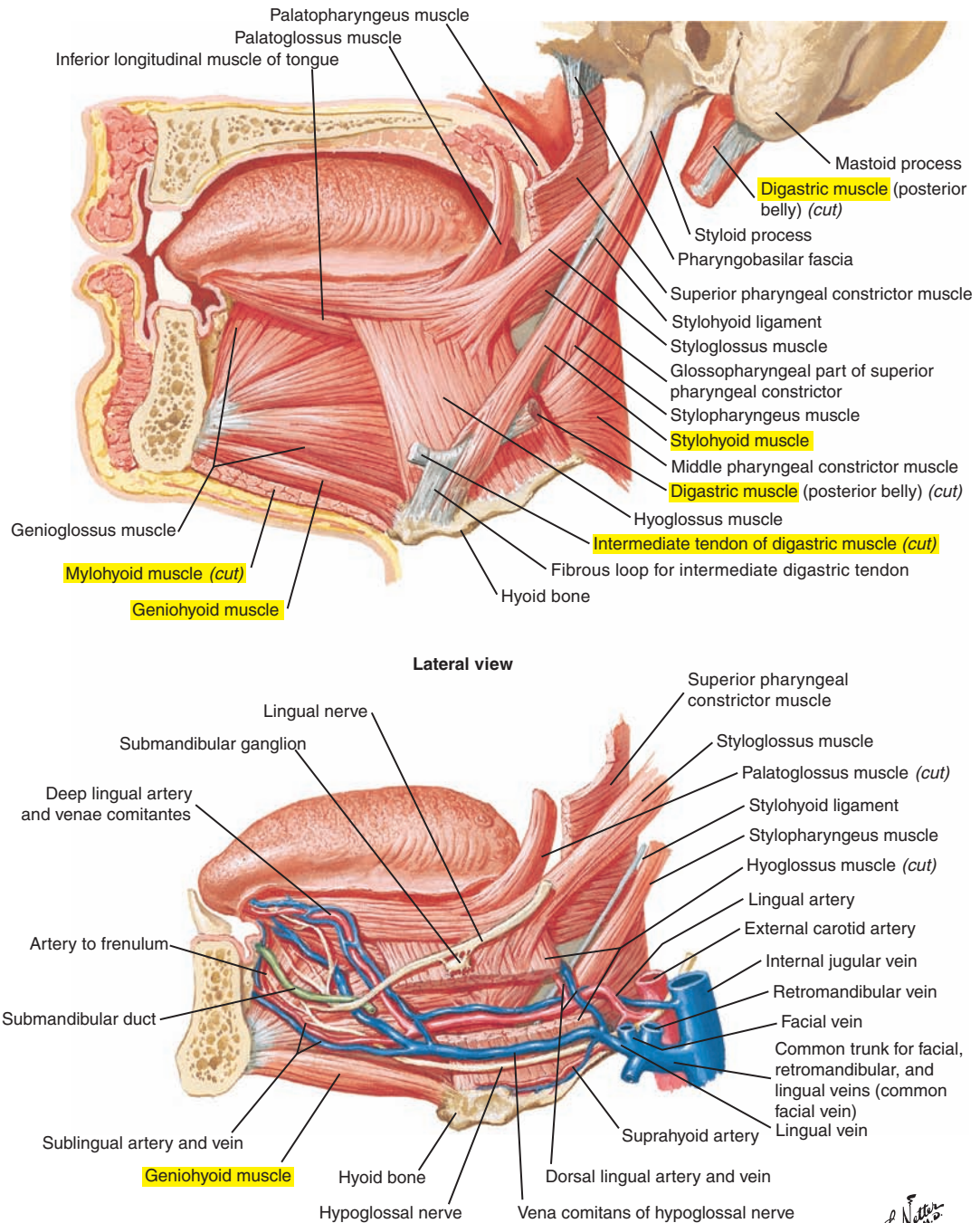
Extrinsic Muscles of the Larynx (Infrahyoid Muscles) (see Figure 2-10 [p. 104])					
Muscle(s)	Description	Origin	Insertion	Action	Innervation
Thyrohyoid	Thin muscle that appears as a continuation of sternohyoid muscle	Oblique line of the thyroid cartilage	On the inferior side of the body and the greater horn of hyoid bone	Approximates the hyoid and thyroid	First cervical spinal nerve (C1) traveling with fibers of the hypoglossal nerve (cranial nerve XII)
Sternohyoid	Thin muscle on the anterior surface of the neck	Posterior surface of the manubrium and medial border of the clavicle	Inferior border of the body of the hyoid bone	Depresses the hyoid	Cervical spinal nerves C1-C3 via ansa cervicalis
Omohyoid	Thin, narrow muscle, with superior and inferior bellies joined by a central tendon connected by deep fascia to the clavicle	Superior border of the scapula	Inferior border of the body of the hyoid	Depresses the hyoid	Cervical spinal nerves C1-C3 via ansa cervicalis
Sternothyroid	Long, thin muscle on the anterior surface of the neck	Posterior surface of the manubrium of the sternum and the first costal cartilage	Oblique line of the thyroid cartilage	Lowers the thyroid cartilage	Cervical spinal nerves C1-C3 via ansa cervicalis



### Infrahyoid and suprahyoid muscles and their action

Figure 2-10. The infrahyoid and suprahyoid muscles and their actions.





**Figure 2-11.** A lateral view of the tongue and surrounding muscles. Note the extrinsic muscles of the larynx.

This page intentionally left blank

# OROPHARYNGEAL-ARTICULATORY SYSTEM

## **Overview, 109**

### **Cranial Anatomy, 110**

Cranium, 110

Facial Skeleton, 114

**Sinuses, 118**

### **Vocal Tract, 119**

Pharyngeal Cavity, 119

Nasal Cavity, 122

Oral Cavity, 124

Tonsils, 126

Palate, 126

Tongue, 126

Salivary Glands, 128

Lips, 128

**Teeth, 130**

### **Muscles of the Lips and Facial Expression, 134**

Orbicularis Oris Muscle, 134

Two Transverse Muscles, 134

Five Angular Muscles, 136

**Three Vertical Muscles, 138**

### **One Muscle of the Neck, 139**

Platysma Muscle, 139

### **Muscles of the Tongue, 140**

Intrinsic Muscles of the Tongue, 140

**Extrinsic Muscles of the Tongue, 142**

### **Muscles of Mastication, 144**

Temporomandibular Joint, 144

Three Jaw-Closing Muscles (Jaw Elevators), 146

**Four Jaw-Opening Muscles (Jaw Depressors), 148**

### **Muscles of the Soft Palate, 152**

Levator Veli Palatini Muscle, 152

Tensor Veli Palatini Muscle, 152

Palatoglossus (Glossopalatine) Muscle, 154

Palatopharyngeus Muscle, 154

**Uvular Muscle (Musculus Uvulae), 154**

### **Muscles of the Pharynx, 155**

Superior Pharyngeal Constrictor Muscle, 155

Middle Pharyngeal Constrictor Muscle, 155

Inferior Pharyngeal Constrictor Muscle, 155

Salpingopharyngeus Muscle, 157

Stylopharyngeus Muscle, 157

**Velopharyngeal Mechanism, 157**

### **Esophagus, 160**

Upper Esophageal, or Cricopharyngeal, Sphincter, 160

Primary Esophageal Peristalsis, 160

Lower Esophageal Sphincter, 160

This page intentionally left blank

## ■ OVERVIEW

---

The supralaryngeal vocal tract is crucial for speech sound generation. Its function is to modify the laryngeal sound source to produce the sounds of speech. Vowels are created by changing the configuration of the vocal tract, which acts as a filter with modifiable resonant modes. Frequencies at or near these resonant modes (called *formant frequencies*) pass most effectively, whereas others are attenuated. Consequently, the frequency spectrum of the sound generated by the vibrating vocal folds is modified as it passes through the filter. The filter characteristics of the upper vocal tract depend on its shape, which is modified by movements of the articulators (e.g., tongue, jaw, and lips) through muscular action.

Consonants are more complex and require rapid movements of one or more of the speech articulators to create transient or turbulent sound sources and may include an additional sound source from the vibrating vocal folds for voiced consonants. The nasal cavity is coupled (for nasalized sounds) or decoupled from the rest of the supralaryngeal vocal tract through the action of the velopharyngeal mechanism. The same oral-articulatory structures that participate in speech production are also vital for the manipulation and movement of food and liquids during mastication and swallowing.

This section focuses on a study of the oropharyngeal-articulatory system. First, cranial anatomy relative to the articulators and other associated structures of the vocal tract is discussed, followed by an examination of the various muscles of articulation and swallowing and their respective functions.

## ■ CRANIAL ANATOMY

---

The skull is an extremely complex osseous structure that provides protection for the brain (and middle and inner ears) and is the point of attachment of many muscles important for speech, mastication, and swallowing. The skull is composed of 22 bones (excluding the 6 middle ear ossicles), 8 paired and 6 unpaired. They are joined by sutures, which provide for growth in the developing skull, except for the mandible or lower jaw, which is the only movable cranial bone. In fact, the skull is sometimes divided into the cranium (which includes the facial skeleton) and the mandible. The cranium can be further divided into the *cranial vault*, the upper bowl-like portion that includes the skullcap or calvaria, and the *cranial base*. We will use the following main divisions of the skull:

1. The cranium (cranial skeleton), which is located in the superoposterior quadrant of the skull
2. The facial skeleton (including the mandible), which is located in the anteroinferior quadrant of the skull

### **Cranium** (Figures 3-1, 3-2 [p. 112], and 3-3 [p. 113])

The cranium contains eight bones, four of which are unpaired.

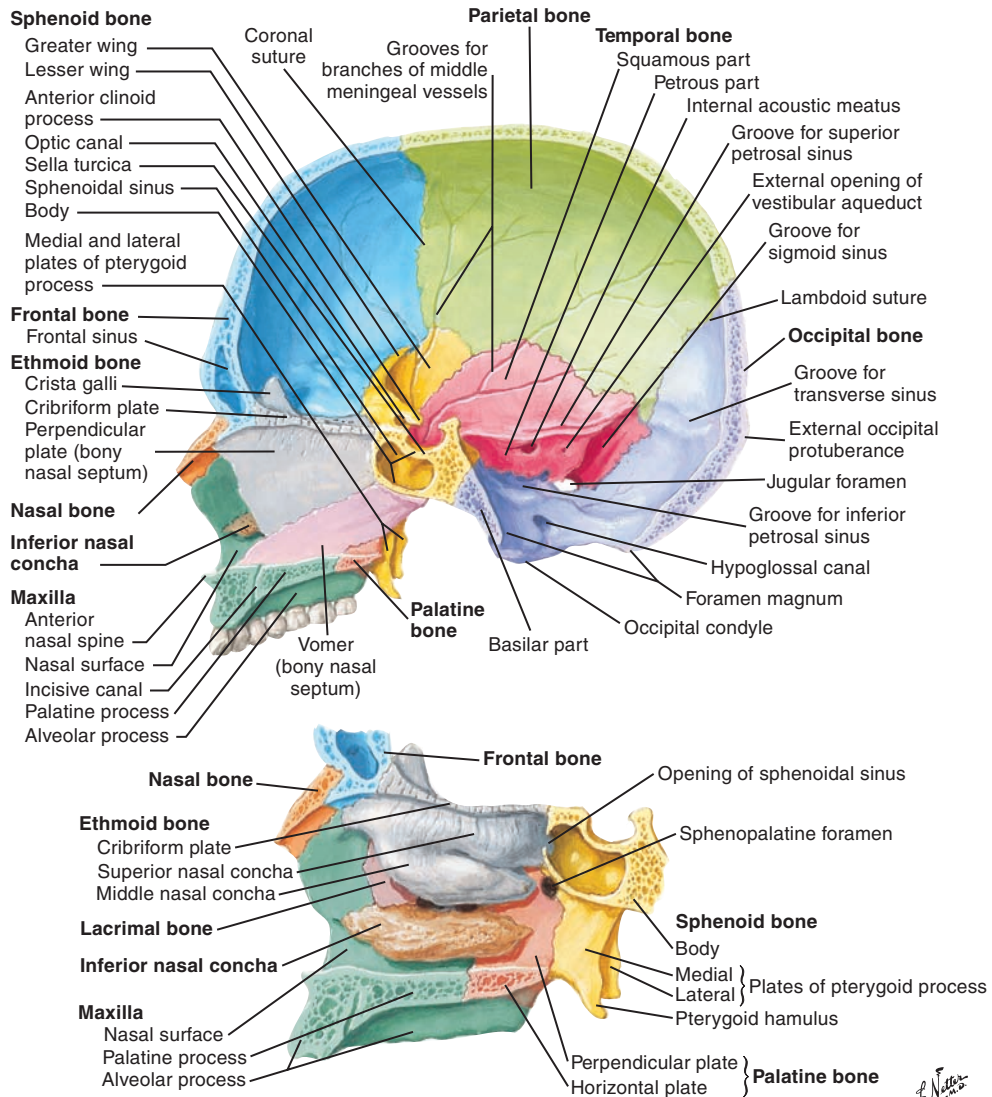
#### **Unpaired Bones**

- The frontal bone contributes to the forehead, the anterior internal surface of the skull, the anterior cranial fossa, the orbit, and the nasal cavity.
- The occipital bone forms the posteroinferior margin of the cranial cavity and contributes to the posterior cranial fossa. It encloses the foramen magnum, which is the point of communication between the brain and spinal cord.
- The sphenoid bone forms the pterygoid fossa located between the medial and lateral pterygoid plates. It contributes to the anterior and middle cranial fossae, the orbit, the temporal fossa, the infratemporal fossa, the pterygopalatine fossa, the scaphoid fossa, the nasal cavity, and the lateral wall of the cranial vault.
- The ethmoid bone contributes to the anterior cranial fossa, the lateral and superior walls of the nasal cavity, the nasal septum, and the medial wall of the orbital cavity.

#### **Paired Bones**

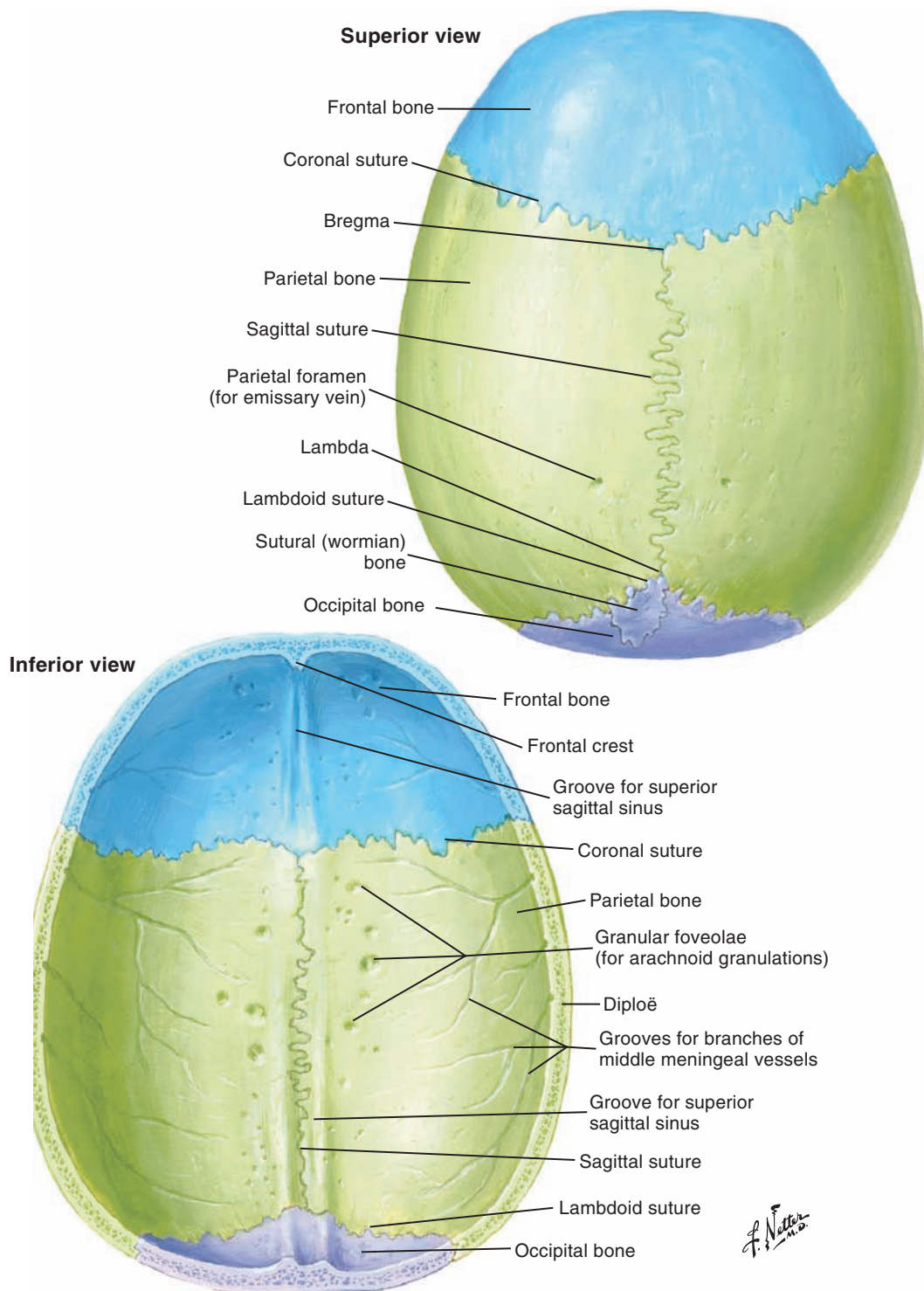
- Temporal bones contribute to the inferolateral margins of the cranial vault. They form the posterolateral part of the middle cranial fossa, the anterolateral part of the posterior cranial fossa, and the mandibular fossa; they also contain the middle and inner ear.
- Parietal bones contribute to the superior, lateral, and posterior portions of the cranial vault.





View of lateral nasal wall with nasal septum removed

Figure 3-1. A midsagittal section of the cranium.



**Figure 3-2.** Superior and inferior views of the skullcap.

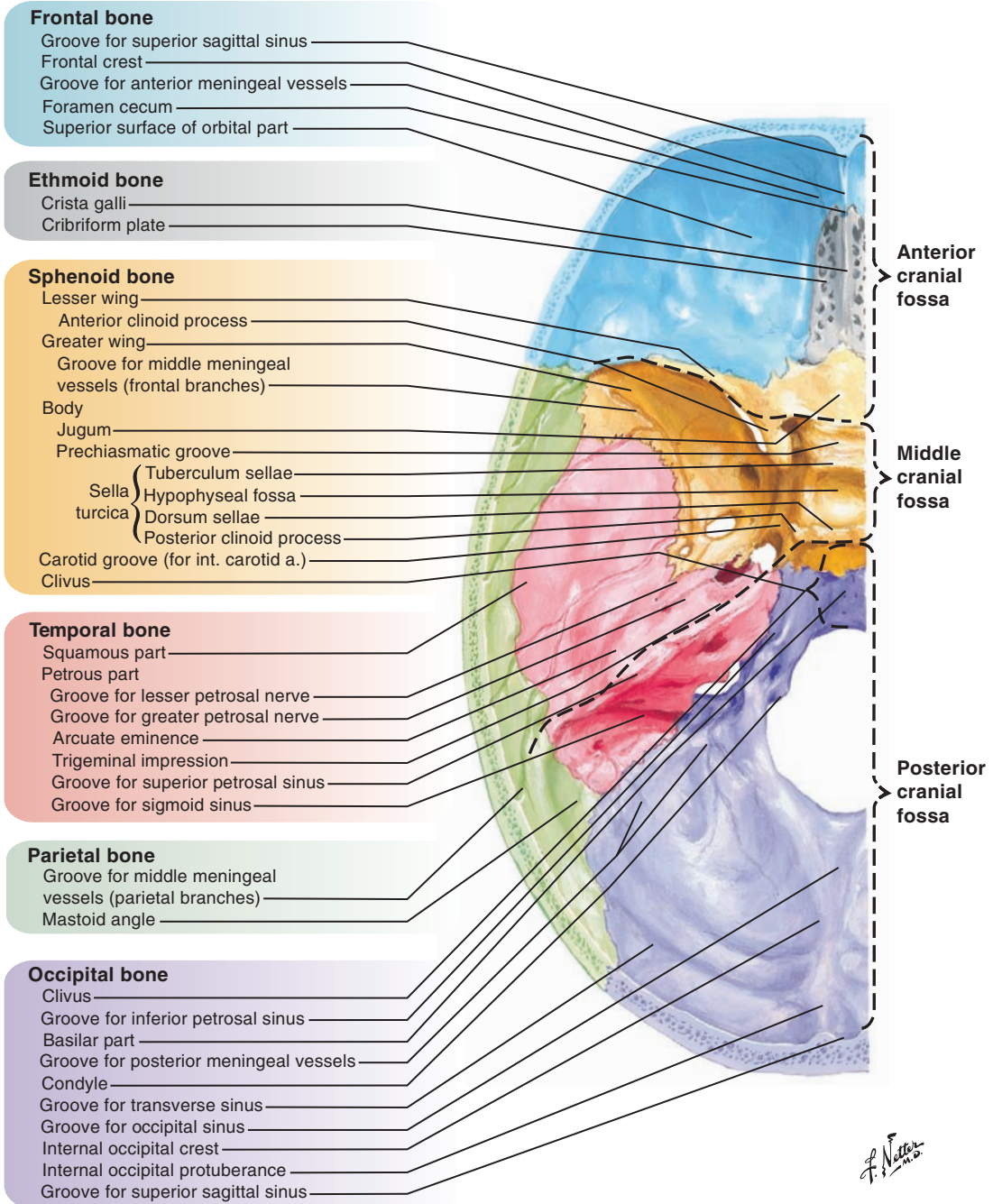


Figure 3-3. Superior view of the cranial base.

**Facial Skeleton** (Figures 3-4, 3-5 [p. 116], and 3-6 [p. 117])

The facial skeleton is constructed of 14 bones, 2 of which are unpaired.

***Unpaired Bones of the Facial Skeleton*****Mandible**

The mandible forms the inferior border of the face and is composed of three parts: the horizontal body containing the alveolar process and the mandibular teeth and the two rami. On each ramus are the coronoid and condylar processes. The condylar processes articulate with the cranial temporal bones by temporomandibular articulations that form the temporomandibular joint.

**Vomer**

The vomer forms part of the bony nasal septum (with the perpendicular plate of the ethmoid) and the posterior wall of the nasal cavity.

***Paired Bones of the Facial Skeleton*****Maxilla**

The maxilla is made up of two bones that join at the median line. They contribute to the upper jaw, cheek, infratemporal region, pterygopalatine fossa, floor of the orbit, palatal vault, and lateral wall and floor of the nasal cavity. Each bone has four processes: zygomatic, frontal, palatine, and alveolar (supporting the maxillary teeth).

**Nasal Bones**

Nasal bones contribute to the top and lateral walls of the nasal cavity and the external “bridge” of the nose.

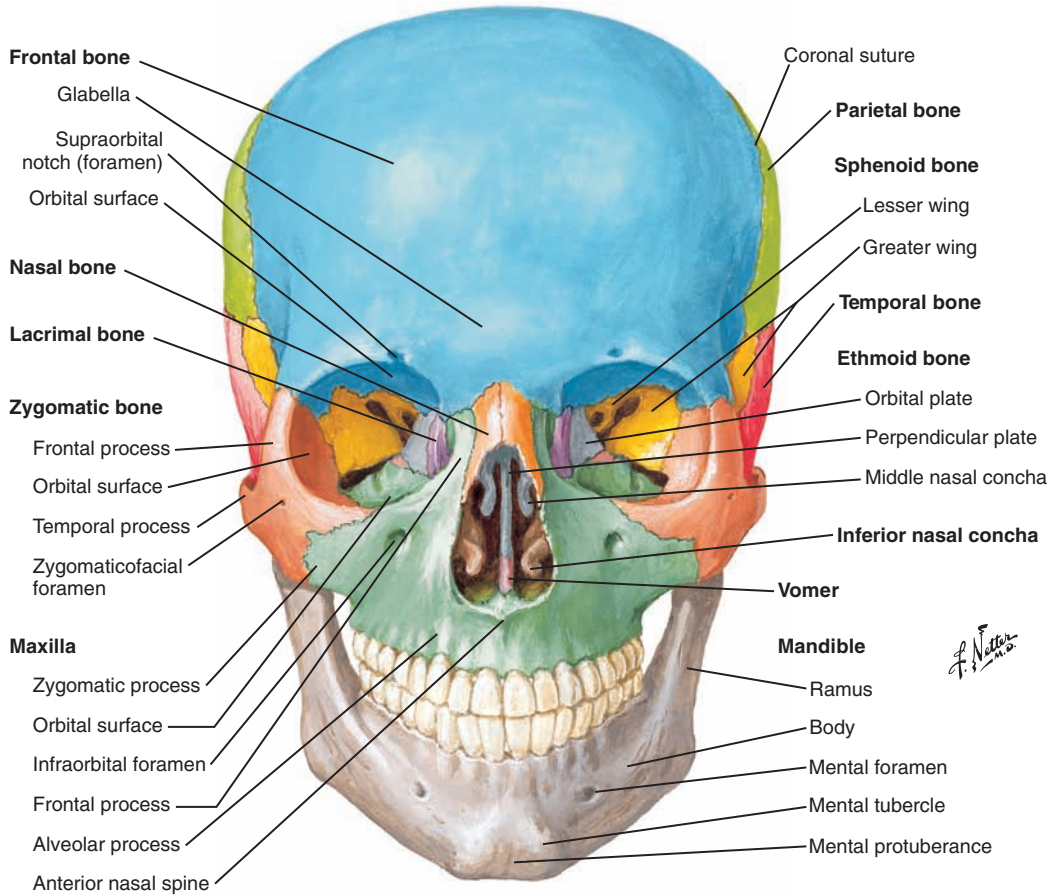
**Palatine Bones**

The palatine bones contribute to the lateral wall and floor of the nasal cavity, the oral cavity (more precisely the posterior one-third of the hard palate), the pterygopalatine fossa, and the posterior wall of the orbit.

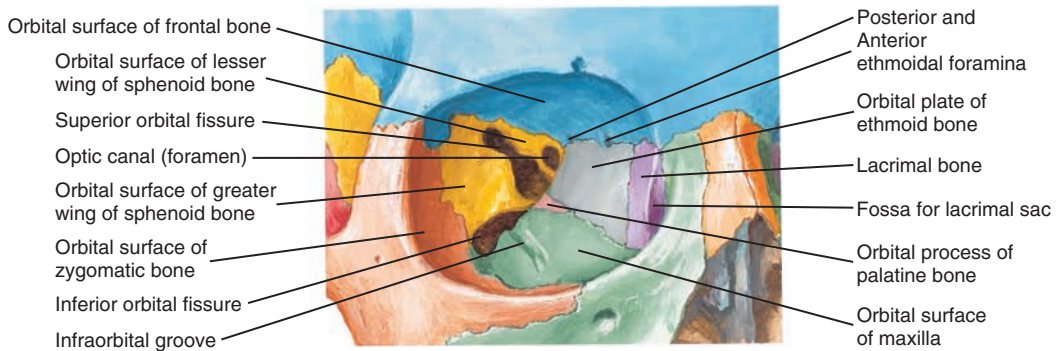
**Lacrimal Bones**

The lacrimal bones contribute to the medial wall of the orbit and the lateral wall of the nasal cavity.

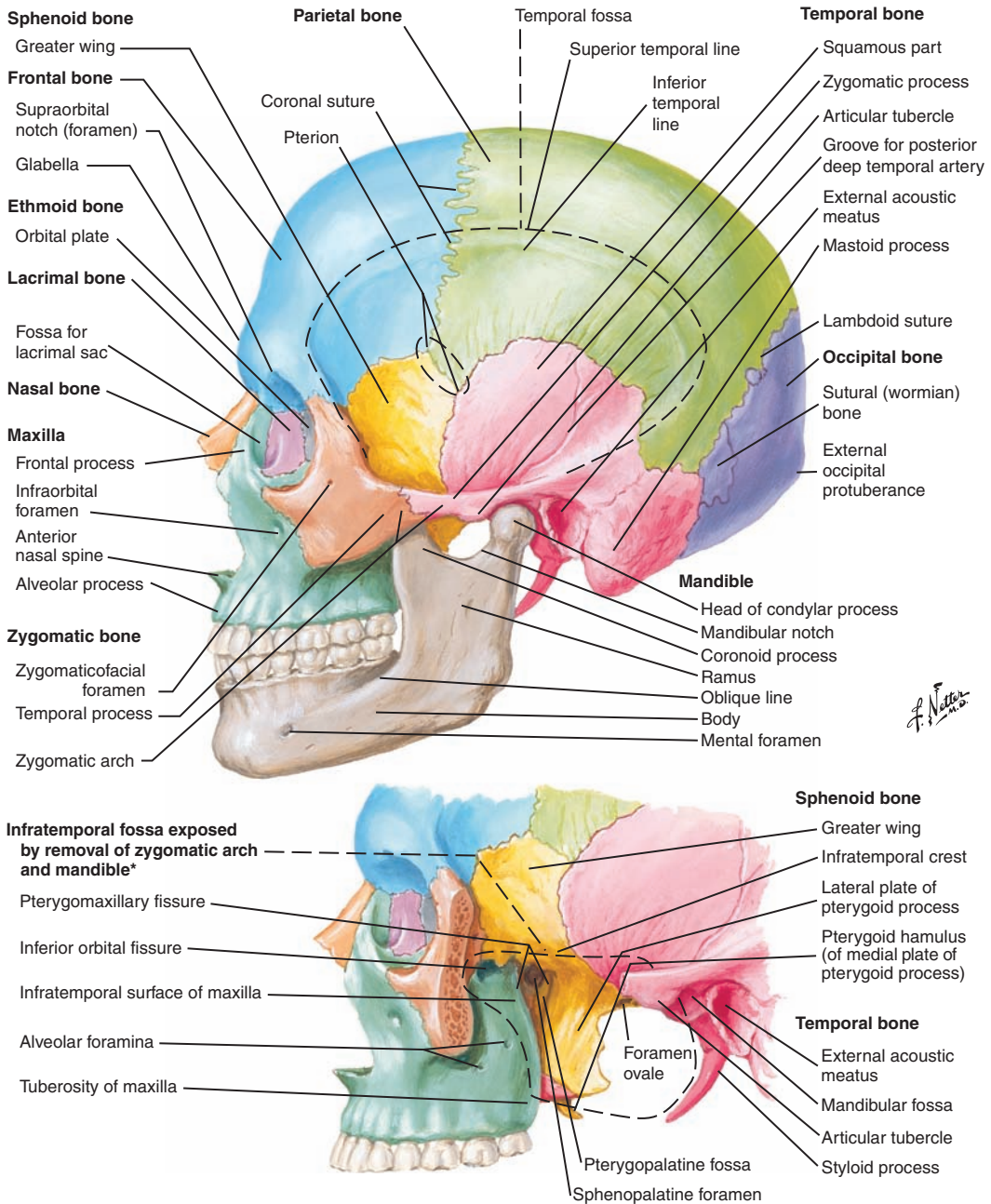




### Right orbit: frontal and slightly lateral view



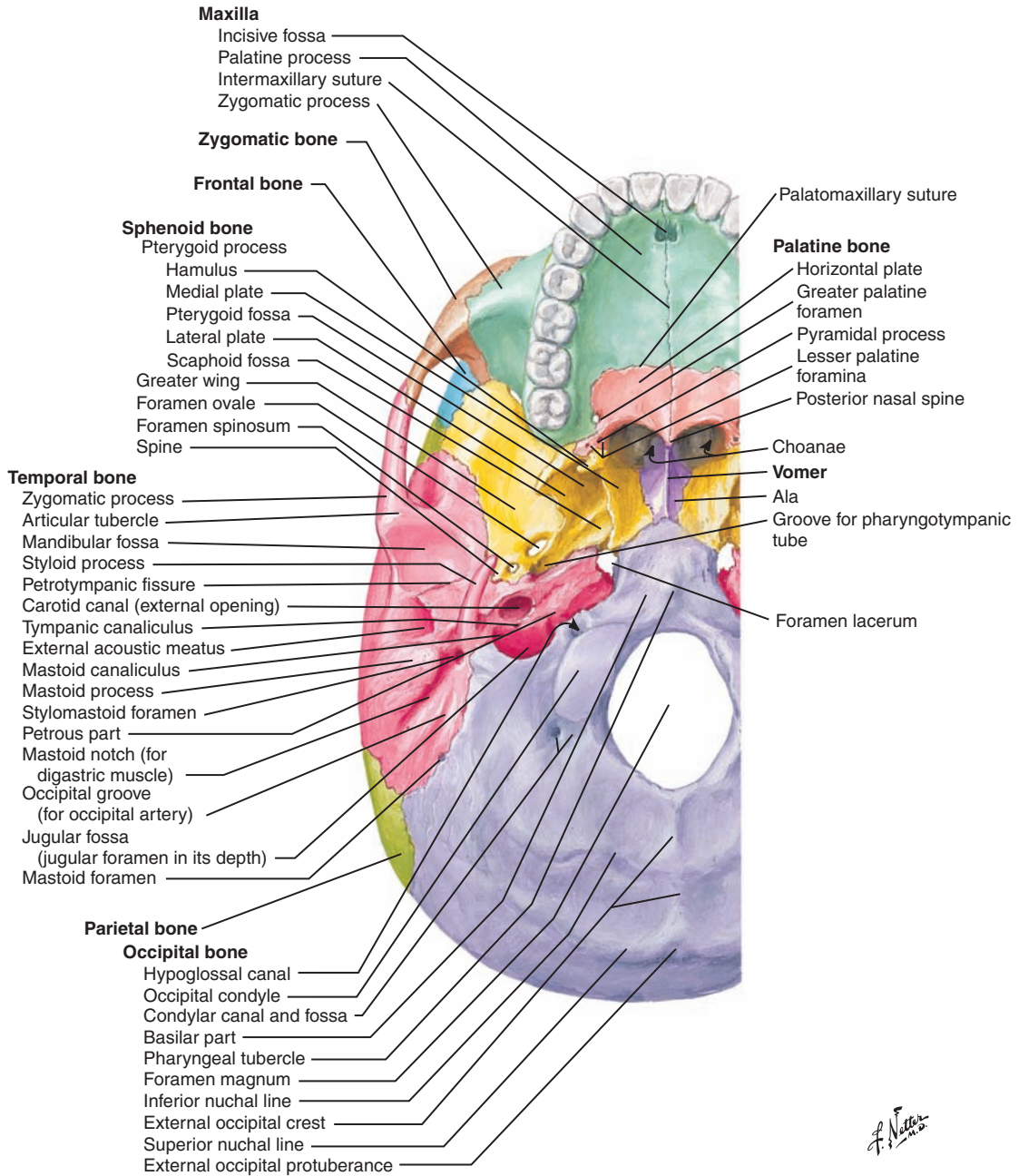
**Figure 3-4.** Anterior view of the skull and the facial skeleton.



\*Superficially, mastoid process forms posterior boundary.

**Figure 3-5.** Lateral view of the skull and the facial skeleton.





**Figure 3-6.** Inferior view of the cranial base.

**Zygomatic Bones**

The zygomatic bones form the skeletal support of the cheek (thus the common name “cheekbone”). They contribute to the zygomatic arch, the lateral wall of the orbit, and the anterior wall of the infratemporal region.

**Inferior Nasal Conchae**

The inferior nasal conchae contribute to the formation of the lateral wall of the nasal cavity and the medial wall of the maxillary sinus.

**Sinuses**

Cranial and facial bones contain sinuses, which are air-filled cavities located near the nasal cavity, and are as follows:

- Maxillary sinus
- Frontal sinus
- Sphenoidal sinus
- Ethmoidal sinus

## ■ VOCAL TRACT

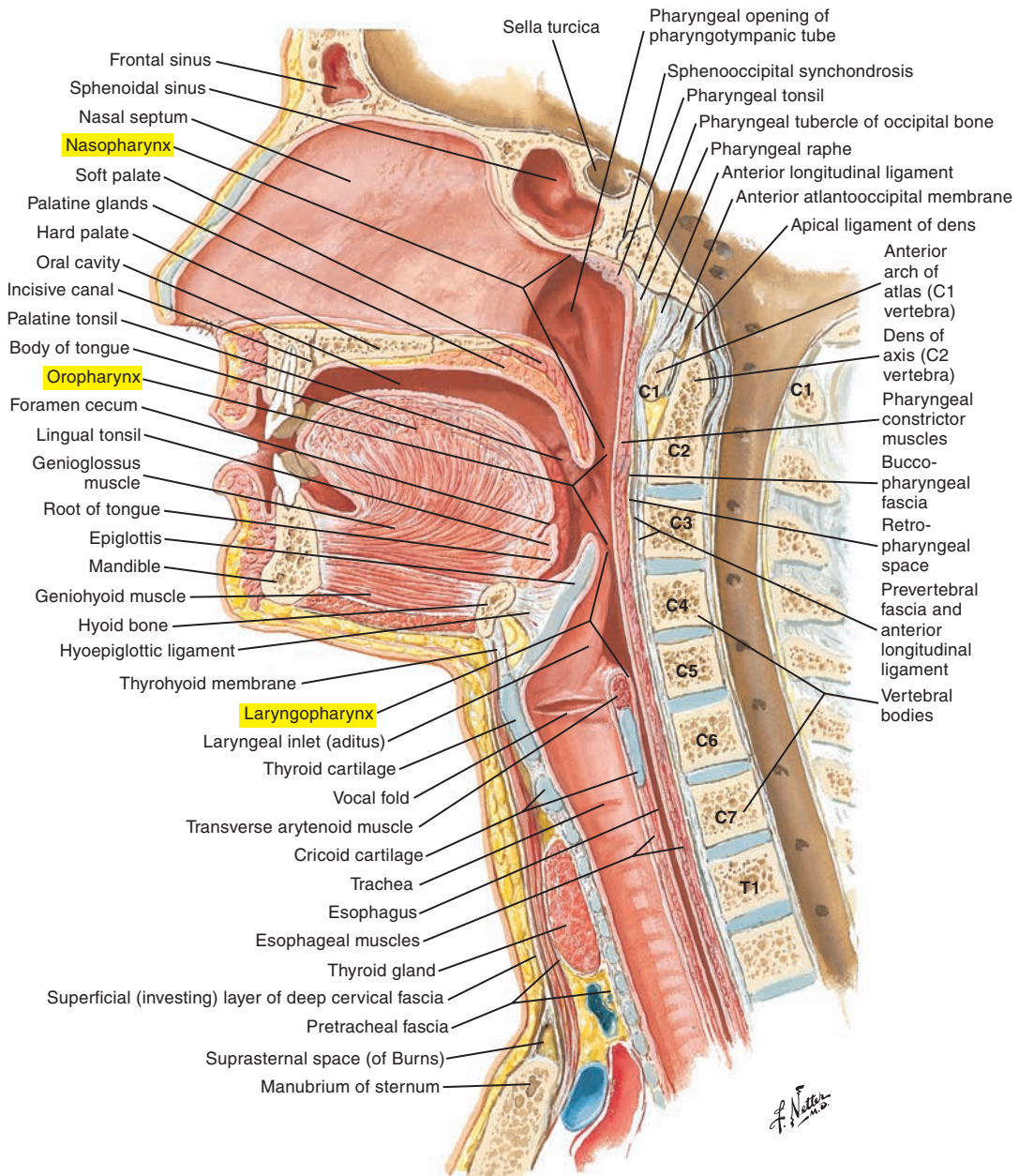
---

The vocal tract is the portion of the upper airway above the vocal folds and is composed of the pharyngeal, nasal, and oral cavities.

### **Pharyngeal Cavity** (Figures 3-7 and 3-8 [p.121])

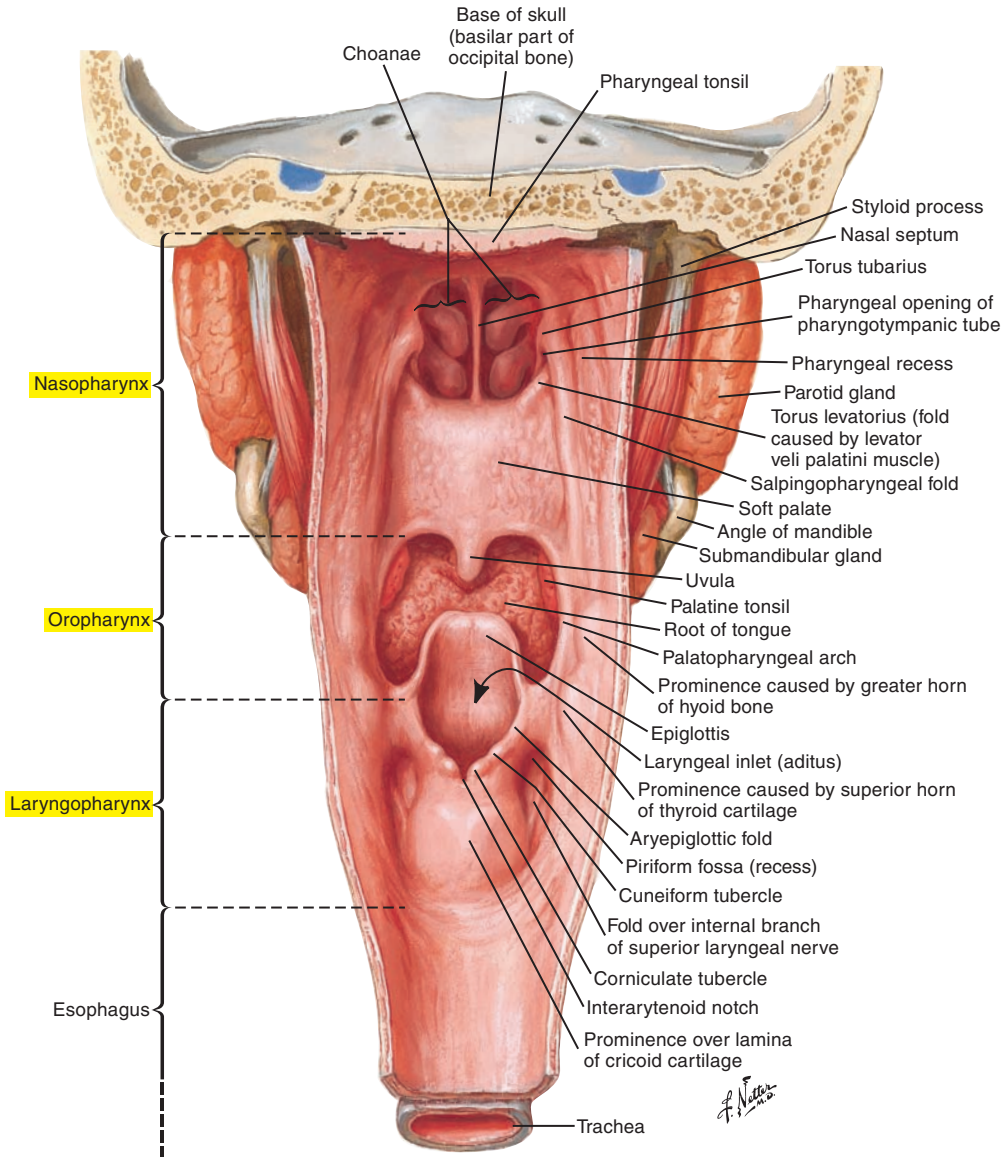
The pharyngeal cavity is made of the following three parts:

1. Nasopharynx
2. Oropharynx
3. Laryngopharynx



**Figure 3-7.** Median section of the head and neck. Note the pharyngeal cavity and associated structures.

Note: Labels of certain figures are highlighted in yellow to emphasize the related elements in the corresponding text.



**Figure 3-8.** Opened posterior view of the pharynx.

**Nasal Cavity** (Figure 3-9)

The nasal cavity is divided medially by the nasal septum. The lateral walls are delineated by coiled, bony structures called *conchae* that are covered with mucous membranes. There are three conchae on each side: the superior, middle, and inferior nasal conchae. The conchae filter, moisten, and warm respired air. These convoluted structures increase surface area contact with the air.

During the production of non-nasal sounds of speech and for swallowing, the nasal cavity is isolated from the rest of the vocal tract by action of the velopharyngeal mechanism (see p. 157). The cartilages of the nasal cavity include the following:

- Septal cartilage
- Lateral cartilage
- Major alar cartilage
- Minor alar cartilage



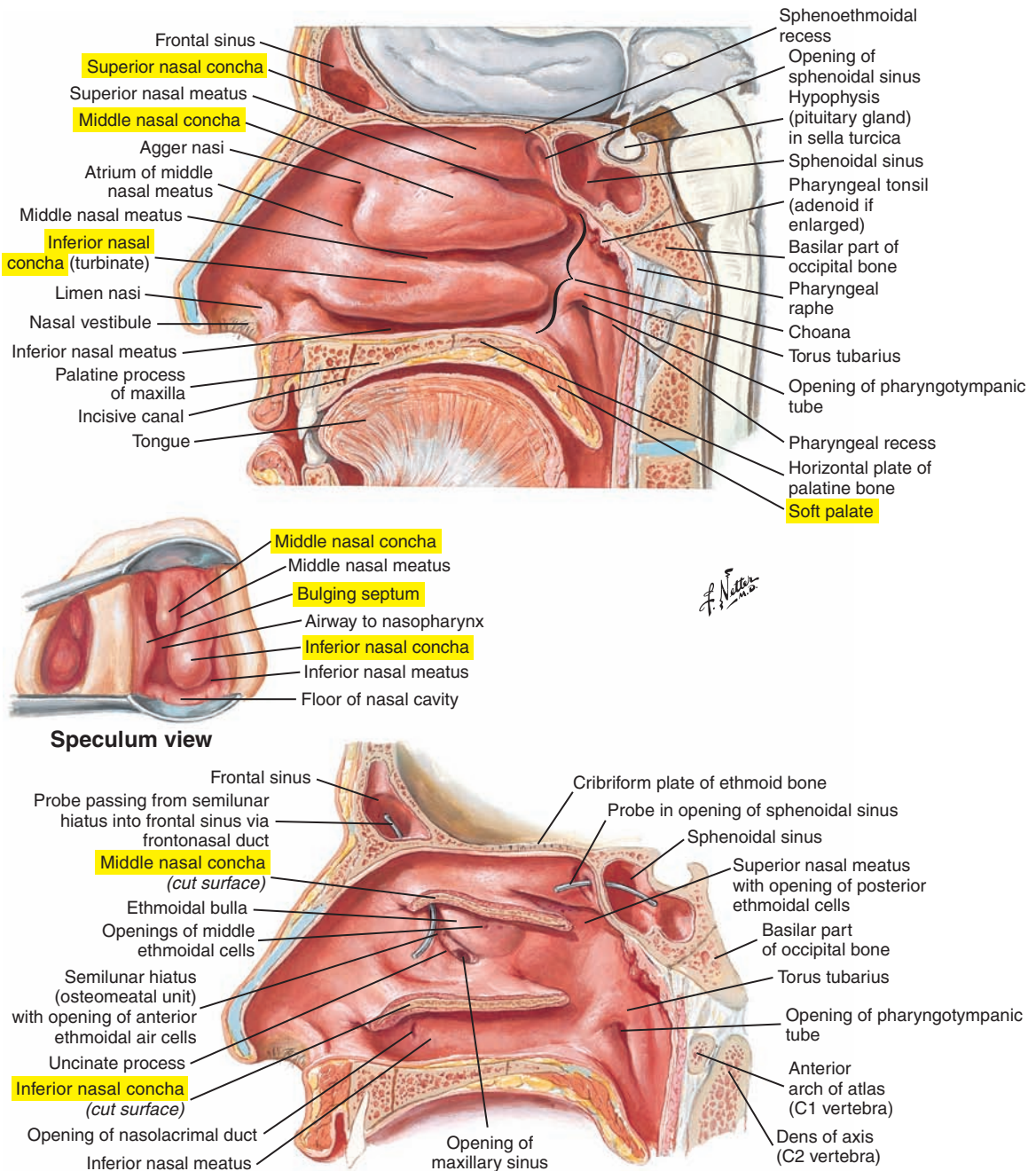


Figure 3-9. Lateral wall of the nasal cavity.

**Oral Cavity** (Figure 3-10)

Delineation of the oral cavity is as follows:

- Anterior limit is the lips and teeth.
- Lateral limit is the cheeks and teeth.
- Posterior limit is the palatoglossal arch.
- Superior limit is the palate.
- Inferior limit is the tongue and floor of the mouth.

Note that the delineation of the oral cavity varies considerably from one reference text to another.

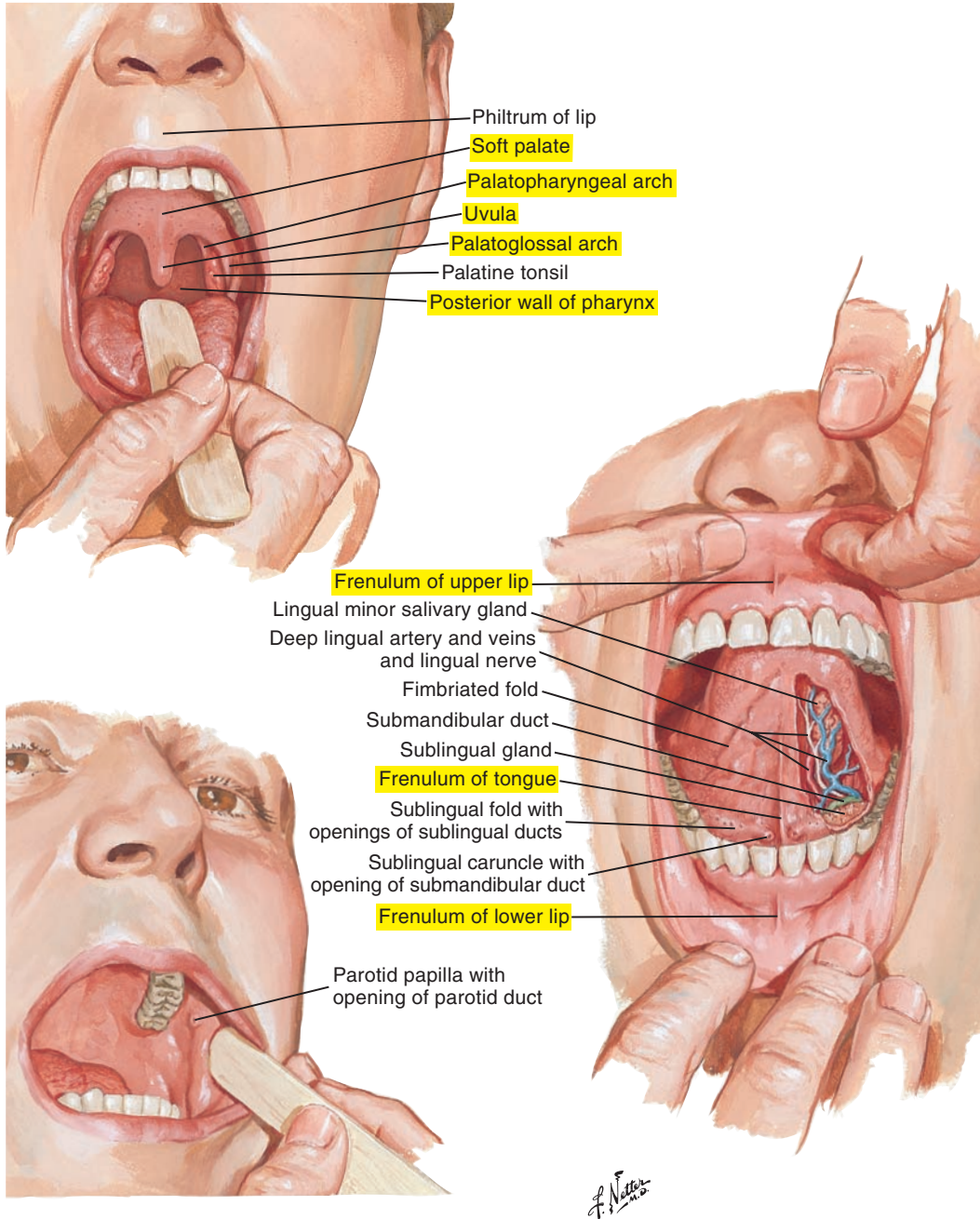
The buccal space (oral vestibule), or cavity, represents the space between the lips and the teeth and between the cheeks and the teeth.

The articulators include the following (see Figure 3-10):

- Lips
- Cheeks
- Teeth
- Mandible
- Tongue
- Hard palate
- Soft palate
- Pharynx

During an examination of the oral cavity it is possible to see two pairs of folds located in the posterolateral part of the oral cavity, as follows:

1. The palatoglossal arch is formed by the palatoglossal muscle.
2. The palatopharyngeal arch is formed by the palatopharyngeus muscle.



**Figure 3-10.** Examination of the oral cavity.

**Tonsils** (see [Figure 3-7](#) [p. 120])

- Palatine tonsils, composed of lymphatic tissue, are located between the palatoglossal arch and the palatopharyngeal arch.
- Nasopharyngeal tonsils or pharyngeal tonsils (adenoids) are located on the posterior wall of the nasopharynx.
- Tubal tonsils are located near the opening of the pharyngotympanic (auditory) tube.
- Lingual tonsils cover the base of the tongue.

Together, these tonsils form Waldeyer's tonsillar ring, which may protect the body from infections.

**Palate** (see [Figure 3-7](#) [p. 120])

The palate can be seen on the superior border of the oral cavity and is composed of the following:

- Hard palate is the osseous anterior two-thirds of the palate formed by the palatine processes of the maxilla (anteriorly) and the horizontal plates of the palatine bones (posteriorly).
- Soft palate or velum is a mobile structure forming the posterior one-third of the palate composed of connective tissue, muscular fibers, and mucosa.

At the posterior extremity of the palate, the uvula appears as an inferiorly directed projection of the posterior border of the soft palate.

**Tongue** ([Figure 3-11](#))

The tongue is the primary articulator for speech sound production and is also crucial for the manipulation of food and liquid for mastication and swallowing. The following landmarks can be observed on the tongue surface:

- Foramen cecum
- Terminal sulcus
- Median sulcus (midline groove)
- Vallate, foliate, filiform, and fungiform papillae
- Lingual tonsils

When looking at the underside of the tongue, it is possible to see a bridge of tissue on the median line that links the tongue to the mouth floor. This fold is called the *lingual frenulum* (frenulum of the tongue) (see [Figures 3-10](#) [p. 125] and [3-12](#) [p. 129]).



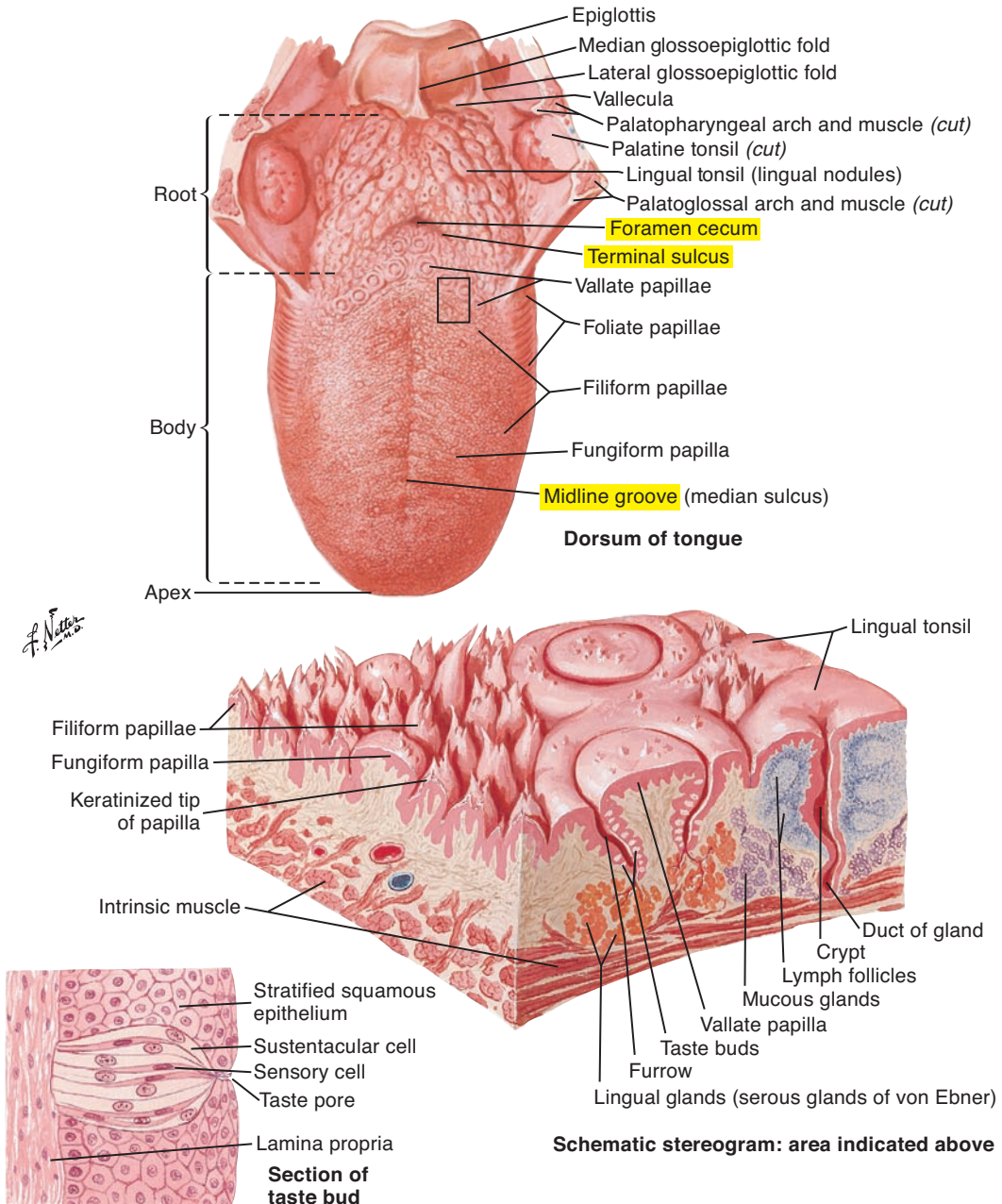


Figure 3-11. Superior view of the tongue.

**Salivary Glands** (Figure 3-12)

Saliva is extremely important for the breakdown and transport of food during mastication, taste, swallowing, and digestion. It is also crucial for oral health and as a lubricant for speech production and other oral motor activities. Saliva is produced by extrinsic and intrinsic salivary glands. There are three pairs of extrinsic salivary glands that produce the majority of the saliva. They are located outside but secrete into the oral cavity and are as follows:

1. Parotid glands
2. Submandibular glands
3. Sublingual glands

**Lips** (see Figure 3-10 [p. 125])

The lips occupy the anterior extremity of the oral cavity and are important for speech sound production, mastication, and swallowing. The external surface of the lips is covered by skin and the internal surface by mucous membrane. The tissue between these two layers (external and internal) is muscular, adipose, and glandular.

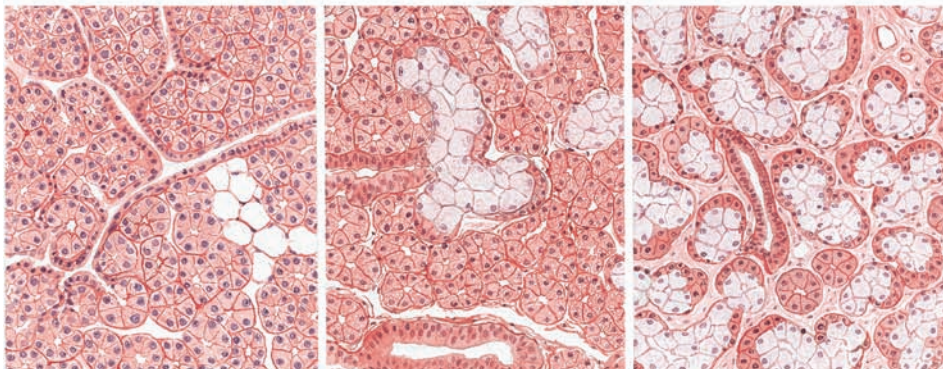
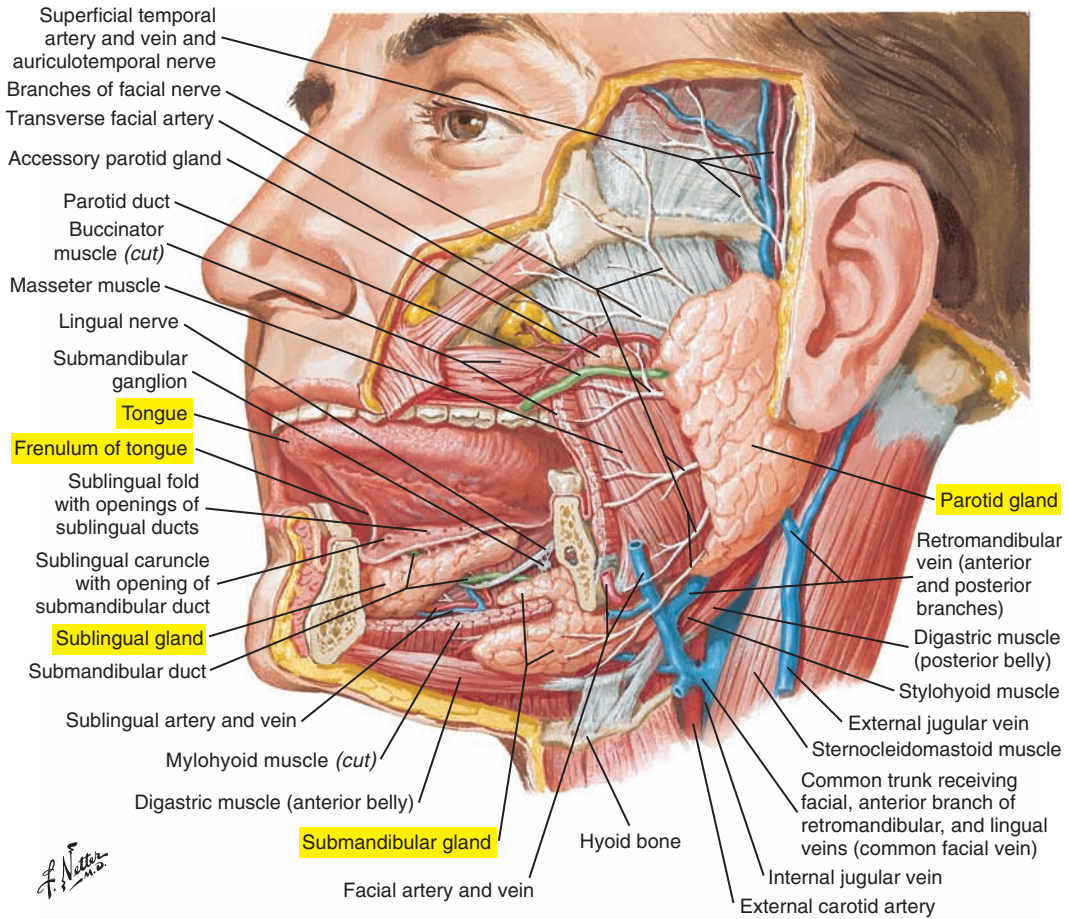
Looking at the external surface of the lips, the following are visible:

- The nasolabial fold (and associated crease, furrow, or sulcus) is a prominent fold from the lateral margin of the nose to the angle of the mouth.
- The labiomandibular fold extends from the corner of the mouth to the mandible. It is often seen as a continuation of the more superior nasolabial fold. Facial muscle contraction and movements of the nasolabial and labiomandibular folds (and associated creases) signal important facial expressions such as smiling.
- Philtral ridges are the two vertical parallel crests above the superior lip.
- The philtrum is the space between the philtral ridges.
- The mentolabial sulcus is between the lower lip and the chin.
- Cupid's bow is the well-defined border of the upper lip.
- Vermilion zones are the transition zones between the skin of the face and the mucous membrane that covers the internal surface of the upper and lower lips.
- The labial commissure is the angle or corner of the mouth.
- The modiolus is not visible on surface inspection but is located lateral to the labial commissure. There is one on each side of the mouth, and they are dense, mobile, approximately cone-shaped masses formed by the convergence of muscle fibers from several labial/facial muscles and other fibrous tissue. They are key anatomical structures for controlling movements of the lips for a variety of activities, including speech, mastication, swallowing, and facial expression.

The internal surface of the lips is covered by a mucous membrane with a thin and transparent epithelium. The pink color is due to underlying vascularity.

Pulling up on the upper lip exposes the frenulum of the upper lip, which is the median tissue that links the lip to the maxilla. Pulling down on the lower lip exposes the frenulum of the lower lip, which is a median fold of tissue that links the lower lip to the mandible.





Parotid gland:  
totally serous

Submandibular gland:  
mostly serous, partially mucous

Sublingual gland:  
almost completely mucous

**Figure 3-12.** The salivary glands.

**Teeth** (Figures 3-13 and 3-14 [p. 132])

The teeth develop and emerge from alveolar processes of the mandible and maxilla. The alveoli are covered externally by the gingivae or gums, which are made of fibrous connective tissue. A normal adult has 32 permanent teeth, which are as follows:

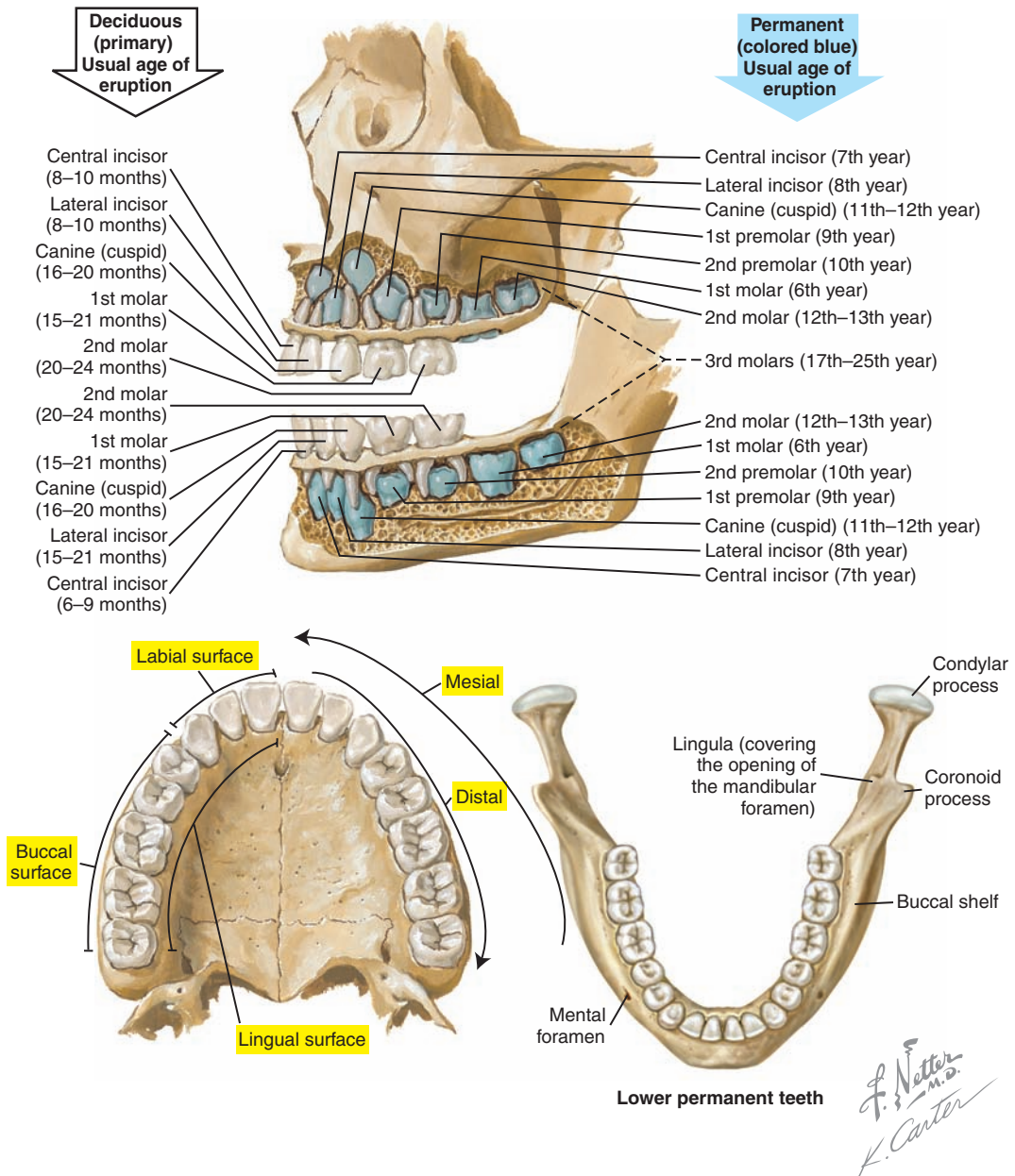
- 8 incisors
- 4 canines, or cuspids
- 8 premolars, or bicuspid
- 12 molars, including the third molars, commonly called *wisdom teeth*

Each tooth is composed of the following:

- The crown is the portion of the tooth that extends above the alveolar boundary.
- The root is the portion of the tooth attached to the alveolar processes of the maxilla or mandible. The dental hole, or canal, located at the extremity of the roots, allows for the dental nerves and the vessels.
- The cusp is the prominence on the occlusal surface of the tooth. Canines have one such prominence. Premolars have two, and molars have four or five.

Surfaces are used to describe the external appearance of a tooth, and each tooth contains five surfaces, as follows:

1. Occlusal surface is the part of the tooth that is in contact with the tooth of the opposite jaw (maxilla or mandible).
2. Lingual surface is adjacent to the tongue.
3. Buccal surface is adjacent to the cheek for premolars and molars.
4. Labial surface is adjacent to the lips for incisors and canines.
5. Distal and mesial surfaces represent the sides of each tooth that are adjacent to other teeth in the same jaw (maxilla or mandible). The mesial surface is oriented anteriorly, and the distal surface is located posteriorly.



**Figure 3-13.** Teeth: age of eruption and surfaces.



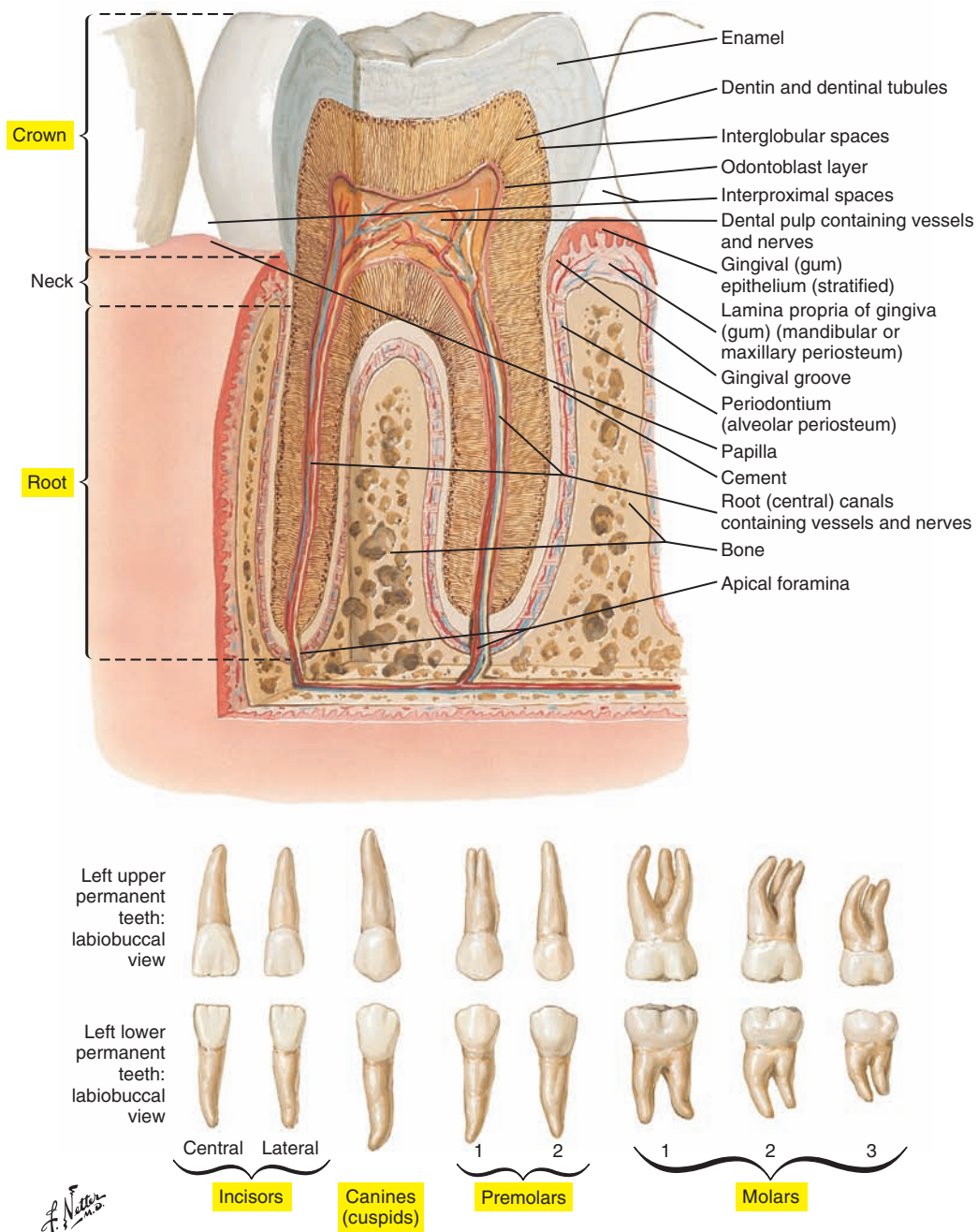


Figure 3-14. Teeth: composition and types.

**Dental Occlusion**

Globally, dental occlusion is the alignment and relationship between the teeth. Occlusion can also be defined as the normal contact between the occlusal surfaces of the teeth of the mandible and maxilla. The classification system of Dr. Edward H. Angle is often used, although not without controversy, to describe occlusal relationships between teeth. This system uses the relationship between the first molars of the mandible and maxilla and does not describe other potential problems with tooth alignment (e.g., crowding). Angle's system includes the following classifications:

- Class I neutral occlusion occurs when the first maxillary molar is slightly posterior and external to the first mandibular molar. More precisely, the mesiobuccal cusp of the first maxillary molar is aligned with the mesiobuccal groove (the one that separates the distal and mesial cusps) of the first mandibular molar.
- Class I malocclusion occurs when there is a neutral relationship between the molars, but there are problems with the alignment of anterior (mesial) teeth.
- Class II ("overbite") occurs when the first maxillary molar is anterior to the first mandibular molar or aligned with the first mandibular molar. More precisely, the mesiobuccal cusp of the first maxillary molar is anterior to the mesiobuccal groove (the one that separates the distal and mesial cusps) of the first mandibular molar. Class II is divided into the following:
  - Division I, in which the relationship between the central incisors is normal (i.e., the maxillary central incisors are in protrusion and slightly overhang the mandibular central incisors).
  - Division II, in which the relationship between the central incisors is abnormal (i.e., the maxillary central incisors, even if they are anterior to the mandibular incisors, are in retraction and inclined toward the tongue).
- Class III ("underbite") occurs when the first maxillary molar is significantly posterior to the first mandibular molar. More precisely, the mesiobuccal cusp of the first maxillary molar is posterior to the mesiobuccal groove (the one that separates the distal and mesial cusps) of the first mandibular molar.

## ■ MUSCLES OF THE LIPS AND FACIAL EXPRESSION

The muscles of the lips and facial expression are not always attached from bone to bone or bone to cartilage. Rather, many originate from a bone and insert on the skin or on other muscles. A complex orientation and interdigitation of lip muscle fibers underlie the synergistic actions of these muscles to generate the precise movements necessary for facial expression, social interaction, speech production, mastication, and swallowing. The considerable complexity of facial and lip musculature combined with variability in location and morphology across individuals (which may be due to differences in facial size and shape) make exact determinations of muscle function difficult.

We will concentrate on muscles of the midface, lower face, and neck, and muscles will be classified in relationship to the orbicularis oris muscle, giving rise to transverse, angular, and vertical muscles.

### **Orbicularis Oris Muscle** (Figure 3-15 and 3-16 [p. 137])

The orbicularis oris muscle is composed of primarily horizontally oriented muscle fibers that encircle the mouth in four quadrants: left, right, superior, and inferior, with each quadrant fanning out from the modiolus to the facial midline. Muscle fibers in each quadrant can be further delineated into marginal portions (*pars marginalis*), deep to the vermillion, and peripheral portions (*pars peripheralis*), around the lips.

Once thought to have a simple sphincter-like or constrictor function, our current understanding is of a much more complex muscle whose actions depend on the co-activation of other facial muscles. The orbicularis oris muscle is involved in lip compression for mastication, swallowing, and speech sound production.

The orbicularis oris muscle is innervated by the buccal and mandibular branches of the facial nerve (cranial nerve VII).

### **Two Transverse Muscles** (Figure 3-15 and 3-16 [p. 137])

#### ***Buccinator Muscle***

The buccinator muscle is a deep facial muscle and a primary muscle of the cheeks. To obtain a good view of this muscle, we have to remove the masseter, which is an important jaw-closing muscle. The buccinator is a quadrilateral muscle that originates from the pterygomandibular raphe (ligament) and the molar alveolar processes of the mandible and maxilla. Muscle fibers course anteriorly (horizontally) to insert into the modiolus and the superior and inferior portions of the orbicularis oris muscle (crossed and uncrossed fibers) at the angle of the mouth. Muscle contraction pulls the lips laterally (retraction), compresses the cheeks, and assists in manipulating the food bolus during mastication and swallowing.

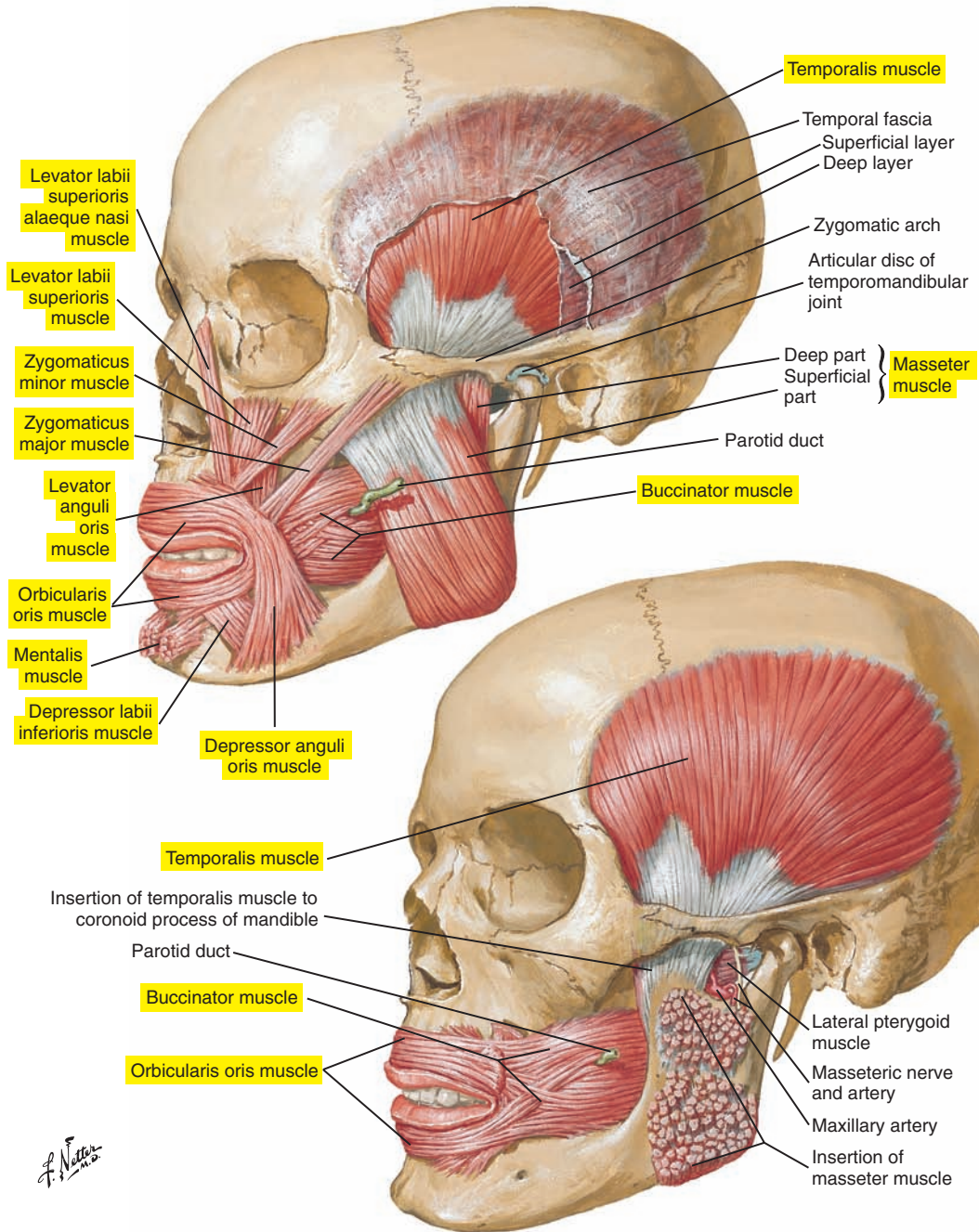
The buccinator muscle is innervated by the buccal branch of the facial nerve (cranial nerve VII).

#### ***Risorius Muscle***

The risorius muscle shows considerable individual variability and is often absent. It is parallel and superficial to the buccinator muscle. It originates from the fascia above the parotid gland and the aponeurosis of the masseter muscle and inserts into the modiolus. Muscular contraction pulls the lips laterally, as in laughing or smiling.

The risorius is innervated by the zygomatic and buccal branches of the facial nerve (cranial nerve VII).





**Figure 3-15.** The muscles of facial expression and mastication.

**Five Angular Muscles** (see [Figure 3-15](#) [p. 135] and [3-16](#) [p. 137])***Levator Labii Superioris Alaeque Nasi Muscle***

The levator labii superioris alaeque nasi muscle originates from the frontal process of the maxilla and divides into medial and lateral muscular portions. The medial portion inserts into the alar cartilage and acts to dilate the nostril. The lateral portion inserts into the lateral portion of the superior orbicularis muscle, elevates and everts (turns inside out) the upper lip, and contributes to deepening the nasolabial sulcus.

The levator labii superioris alaeque nasi muscle is innervated by the zygomatic and buccal branches of the facial nerve (cranial nerve VII).

***Levator Labii Superioris Muscle***

The levator labii superioris muscle originates lateral to the levator labii superioris alaeque nasi muscle from the inferior surface of the orbit to course inferiorly and medially to insert into the superior orbicularis oris muscle. It elevates and everts the upper lip and contributes to deepening the nasolabial furrow.

The levator labii superioris (superior) muscle is innervated by the zygomatic and buccal branches of the facial nerve (cranial nerve VII).

***Zygomaticus Minor Muscle***

Sometimes absent, the zygomaticus minor muscle originates from the zygomatic bone lateral to the levator labii superioris and tracks inferiorly and medially to insert into the superior portion of the orbicularis oris muscle. Its action elevates the upper lip and contributes to deepening the nasolabial fold, as in smiling.

The zygomaticus minor muscle is innervated by the zygomatic and buccal branches of the facial nerve (cranial nerve VII).

***Zygomaticus Major Muscle***

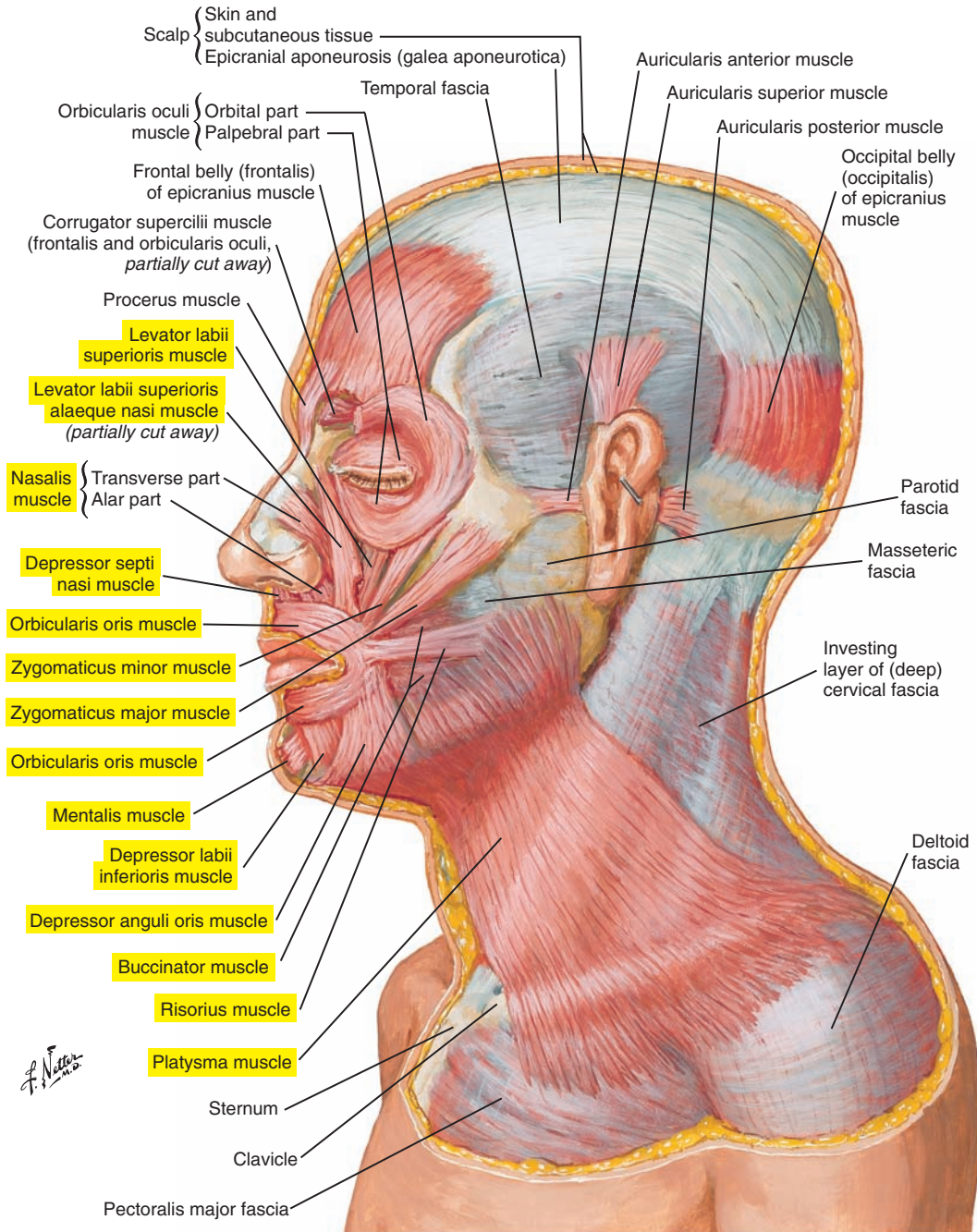
The zygomaticus major muscle originates from the zygomatic bone, lateral to the zygomaticus minor muscle. It courses inferiorly and medially to insert into the superior portion of the orbicularis oris muscle and the modiolus. It is often composed of superficial and deep portions. Together with the levator anguli oris, its action pulls the lips superiorly and laterally such as when smiling or laughing.

The zygomaticus major muscle is innervated by the buccal and zygomatic branches of the facial nerve (cranial nerve VII).

***Depressor Labii Inferioris Muscle***

The depressor labii inferioris muscle originates from the external oblique line of the mandible. It travels superiorly and medially to insert into the modiolus and the inferior orbicularis oris muscle. Its action pulls the lower lip down during mastication and may contribute to facial expressions such as sadness or sorrow.

The depressor labii inferioris muscle is innervated by the mandibular branch of the facial nerve (cranial nerve VII).



**Figure 3-16.** Lateral view of the muscles of facial expression.

**Three Vertical Muscles** (see [Figure 3-15](#) [p. 135] and [3-16](#) [p. 137])***Mentalis Muscle***

The mentalis muscle originates from the anterior surface of the body of the mandible to insert on the skin of the chin and on the inferior portion of the orbicularis oris muscle and the modiolus. Its action elevates, protrudes, and everts the lower lip and may crease the chin.

The mentalis muscle is innervated by the mandibular branch of the facial nerve (cranial nerve VII).

***Levator Anguli Oris Muscle (Caninus)***

The levator anguli oris muscle originates from the canine fossa to insert into the modiolus and the superior portion of the orbicularis oris superior muscle. As indicated by its name, its action elevates the angle of the mouth and, together with the zygomaticus major muscle, pulls the lips superiorly and laterally and deepens the nasolabial fold, as in smiling or laughing.

The levator anguli oris muscle is innervated by zygomatic and buccal branches of the facial nerve (cranial nerve VII).

***Depressor Anguli Oris Muscle***

The depressor anguli oris muscle partially covers and is lateral to the depressor labii inferioris muscle and is superficial to the platysma muscle. It originates from the external oblique line of the mandible and courses superiorly to the modiolus and the inferior portion of the orbicularis oris. Superiorly it is continuous with the levator anguli oris muscle and inferiorly with the platysma muscle. Its action depresses the angle of the mouth, as indicated by its name, such as in an expression of sadness.

The depressor anguli oris is innervated by the mandibular and buccal branches of the facial nerve (cranial nerve VII).

## ■ ONE MUSCLE OF THE NECK

---

### **Platysma Muscle** (see [Figure 3-16](#) [p. 137])

The platysma muscle is very thin, flat, and large. It covers the majority of the anterior and lateral surfaces of the neck. Its extension is very variable. It is deep to the depressor anguli oris muscle. In most individuals, it extends to the cheeks and the muscles of the mouth and the modiolus. However, for some, it can spread even farther up to the muscles surrounding the eyes. When this muscle contracts, it expands the neck and pulls the skin of the neck upward, which may also facilitate the drainage of nearby blood vessels. Also, this muscle may play a role in the downward movements of the lower lip and jaw.

The platysma is innervated by the cervical branch of the facial nerve (cranial nerve VII).



## ■ MUSCLES OF THE TONGUE

---

At a functional level, the tongue can be divided into the following sections (see [Figure 3-11](#) [p. 127]):

- The body constitutes the major mass of the tongue.
- The root is the posterior portion that forms the anterior boundary of the pharyngeal cavity.
- The dorsum is the dorsal surface of the tongue.
- The blade is the anterior part of the tongue, just behind the apex and beneath the alveolar ridge of the maxilla.
- The apex is the tip or the most anterior portion of the tongue.

These parts are particularly important for the tongue's actions for the production of the sounds of speech and for swallowing.

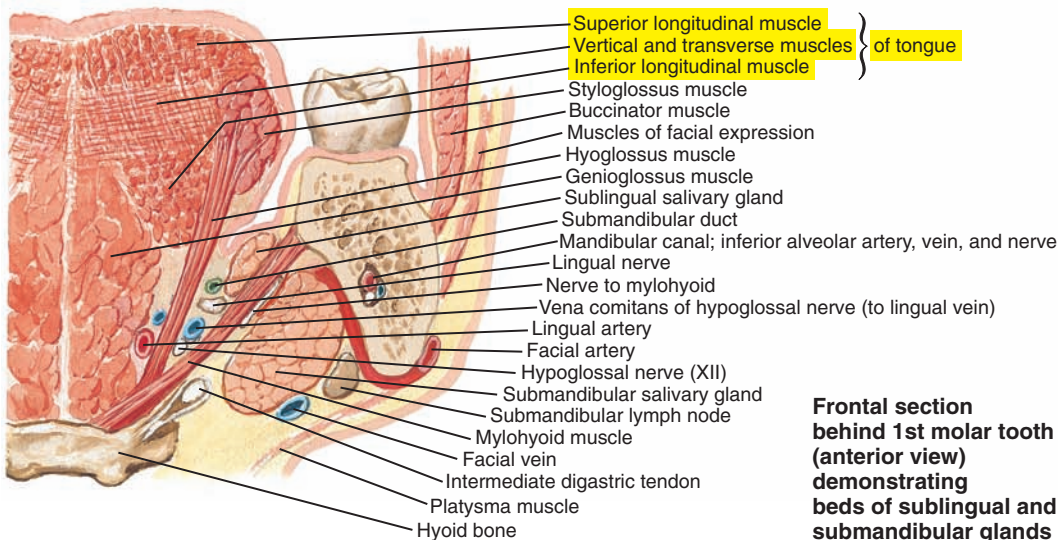
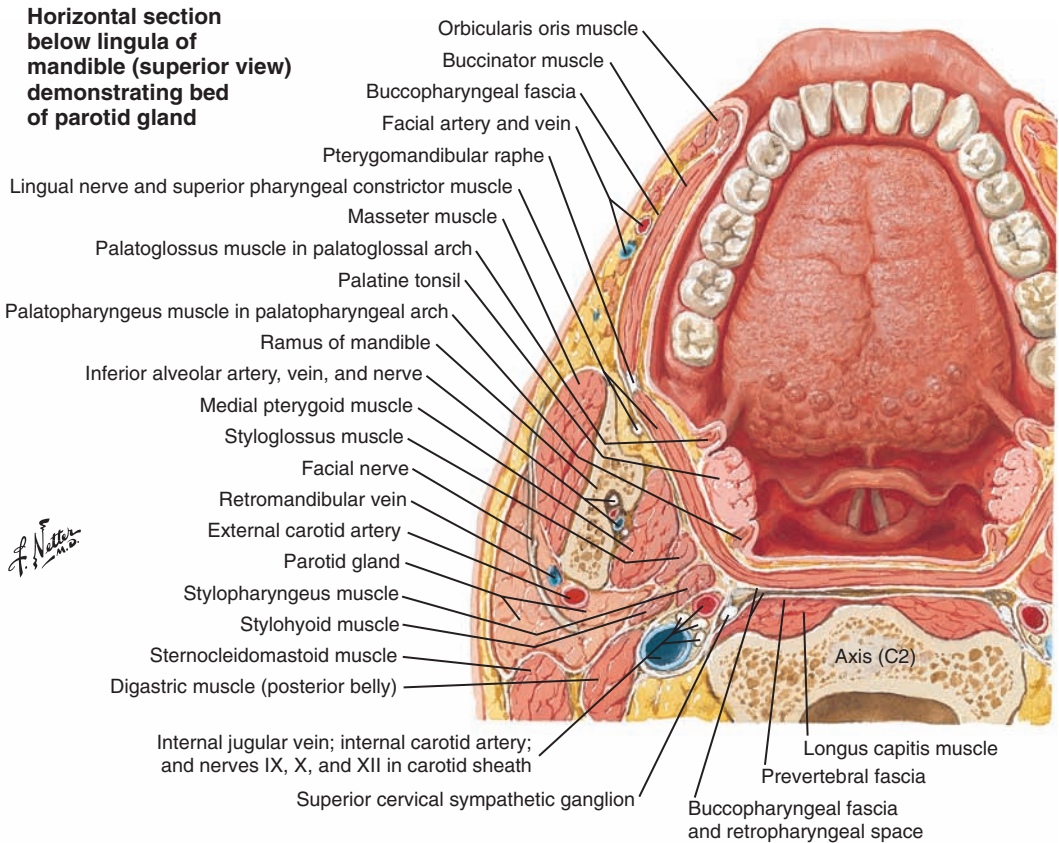
The tongue is composed of and controlled by the following two groups of muscles:

1. Intrinsic muscles have origins and insertions inside the tongue.
2. Extrinsic muscles have an origin outside the tongue and an insertion in the tongue.

### **Intrinsic Muscles of the Tongue** ([Figure 3-17](#))

The intrinsic muscles form a complex array of interdigitating muscle fibers. This complex arrangement allows for precise adjustments in tongue form and position. There are four intrinsic muscles, as follows:

1. Superior longitudinal muscle
2. Inferior longitudinal muscle
3. Transverse muscle
4. Vertical muscle

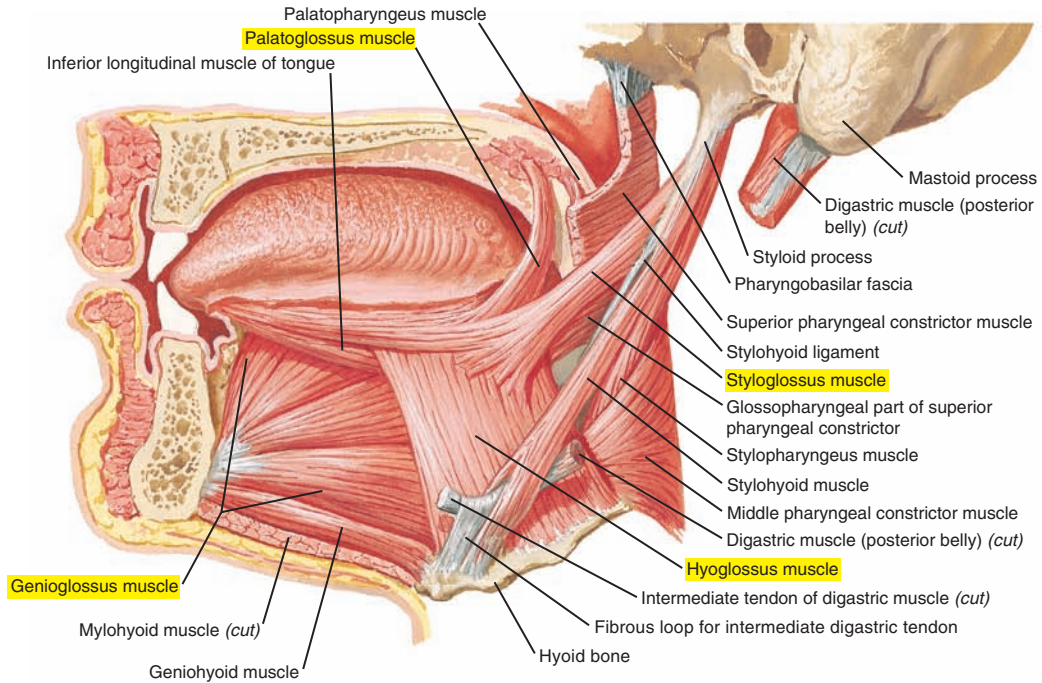


**Figure 3-17.** Superior view and coronal section of the tongue.

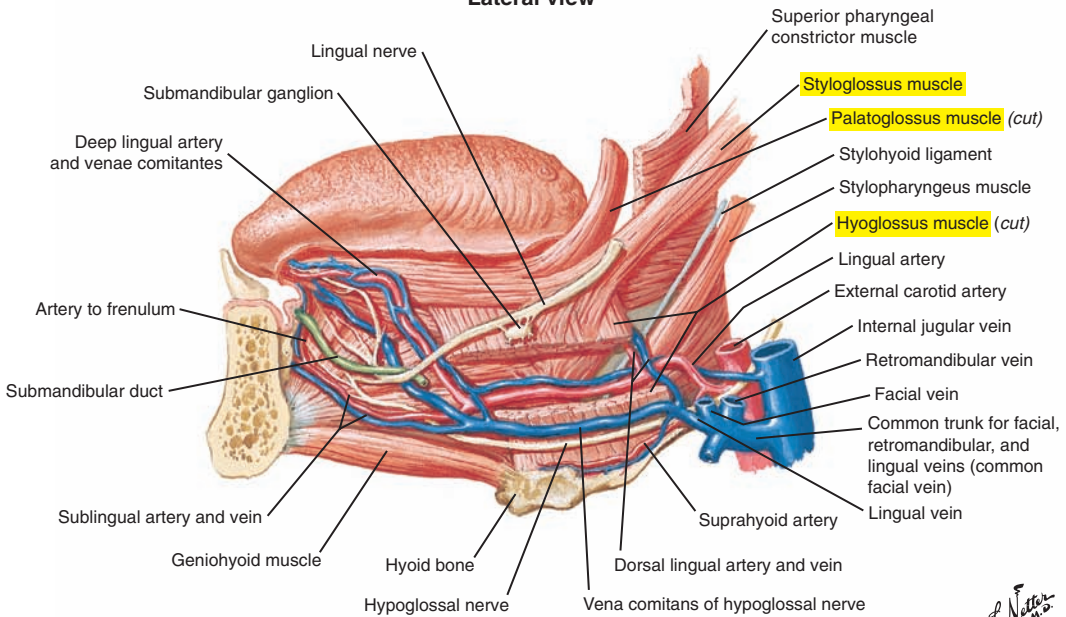
**Extrinsic Muscles of the Tongue** (Figure 3-18)

Extrinsic muscles link the tongue with surrounding structures. These muscles allow the tongue to move forward, backward, upward, downward, and laterally. Each name includes the word *glossus*, which means tongue, and another term indicating the external origin. There are four extrinsic muscles, as follows:

1. Palatoglossus muscle
2. Styloglossus muscle
3. Hyoglossus muscle
4. Genioglossus muscle



#### Lateral view



**Figure 3-18.** Lateral view of the tongue and associated muscles.

## ■ MUSCLES OF MASTICATION

Mastication is the process of food reduction and preparation for swallowing. It requires the complex coordinated movements of the jaw, lips, cheeks, and tongue. The origin of jaw muscles, often called *muscles of mastication*, is typically on the skull and the insertion of jaw muscles is on the mandible, which is the movable portion of the jaw around the temporomandibular joint. Clearly, movements of the jaw are important for speech production, and as a result of biomechanical linkage, they influence the lips and the tongue. The muscles of mastication can generally be divided into jaw-opening and jaw-closing muscles, or jaw elevators and jaw depressors, respectively.

### **Temporomandibular Joint** (Figure 3-19)

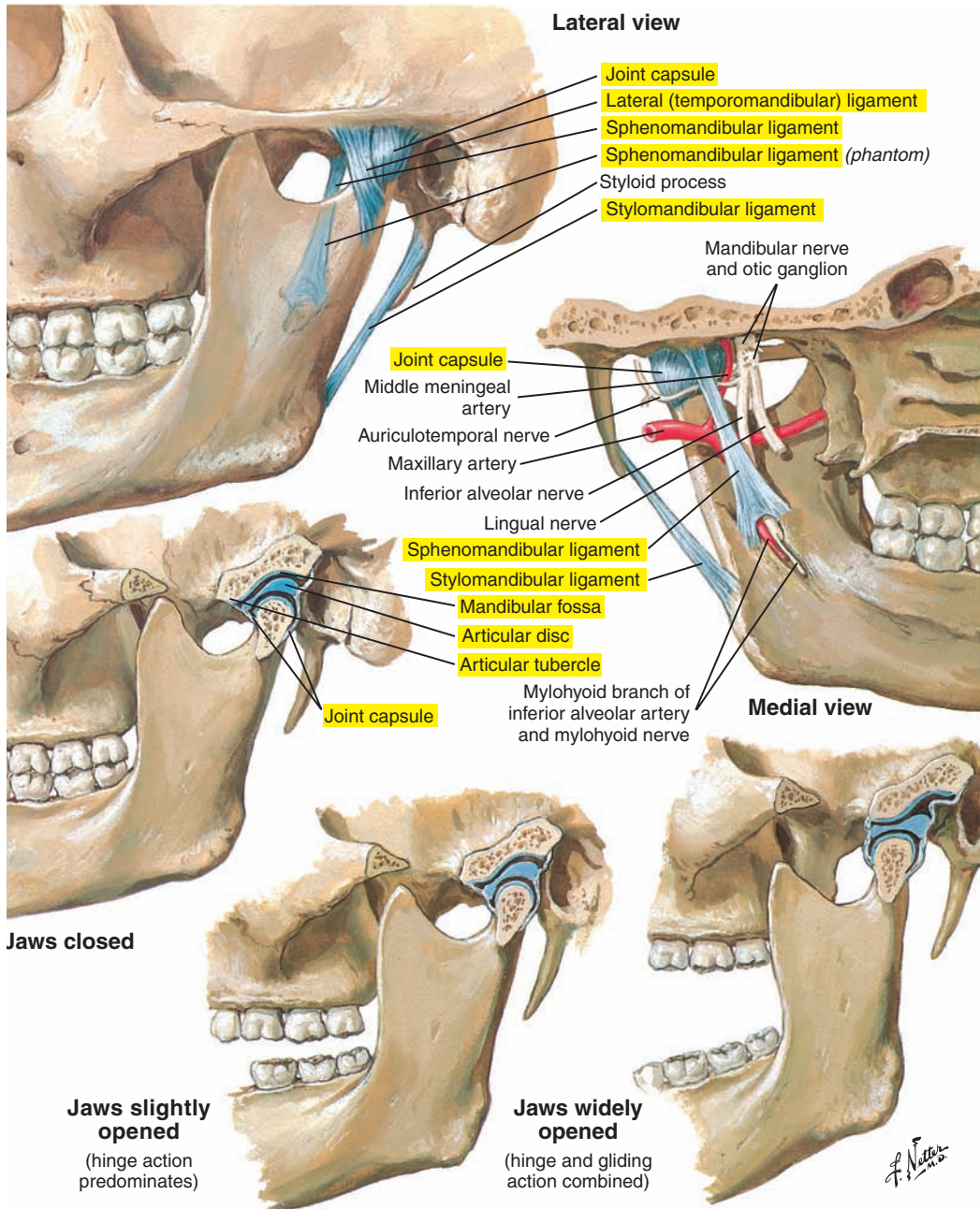
The temporomandibular joint is a synovial joint between the condylar process of the mandible and the mandibular (articular, glenoid) fossa of the temporal bone. The articular surfaces of both structures are covered with fibrocartilage and separated by and connected to a cartilaginous articular disc. A fibrous articular capsule (joint capsule) surrounds these structures and thickens laterally to form the temporomandibular (lateral) ligament. This ligament courses from the mandible to the articular tubercle and zygomatic process of the temporal bone. Two other ligaments, the stylomandibular ligament and the sphenomandibular ligament, both located medially, may provide some additional support.

Two movements are associated with the temporomandibular joint, as follows:

1. Translation is a gliding type of movement that can be either bilateral (backward-forward movements of the jaw) or unilateral (the mandible moves from one side to the other).
2. Rotation is a “hinge”-type movement of the jaw. Imagine the jaw rotating around an imaginary horizontal axis through the condylar processes of the two sides of the mandible.

Mastication and speech involve a combination of these two types of jaw movements, with specific movement trajectories influenced by the nature of the food bolus and the position within the masticatory sequence (from food ingestion to swallowing for mastication) and the specific speech sound produced and phonetic environment (for speech). There is also individual variability in both masticatory and speech movements.





**Figure 3-19.** The temporomandibular joint.

**Three Jaw-Closing Muscles (Jaw Elevators)** (Figure 3-20; see also Figure 3-15 [p. 135])***Masseter Muscle***

The masseter muscle has superficial (external) and deep (internal) fibers. The masseter muscle originates from the zygomatic process of the maxilla and the zygomatic arch. Fibers travel inferiorly to insert on the external surface of the angle and ramus of the mandible. Some fibers also insert on the coronoid process of the mandible. The masseter elevates the mandible. Superficial fibers may contribute to jaw protrusion and deep fibers to jaw retraction.

The masseter muscle is innervated by the masseter nerve of the mandibular division of the trigeminal nerve (cranial nerve V).

***Temporalis Muscle***

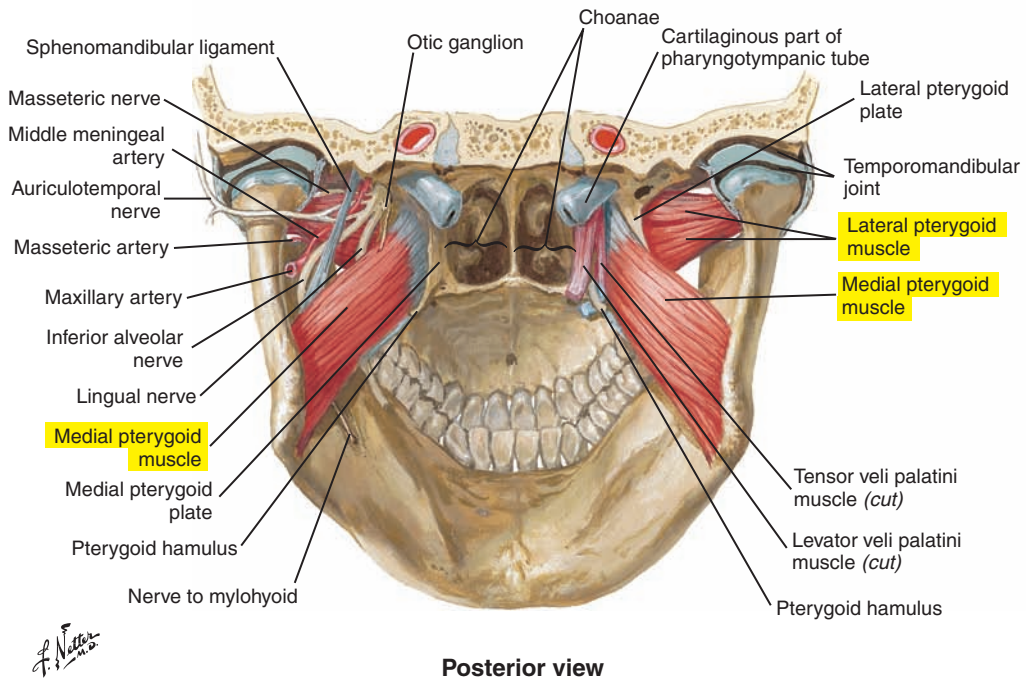
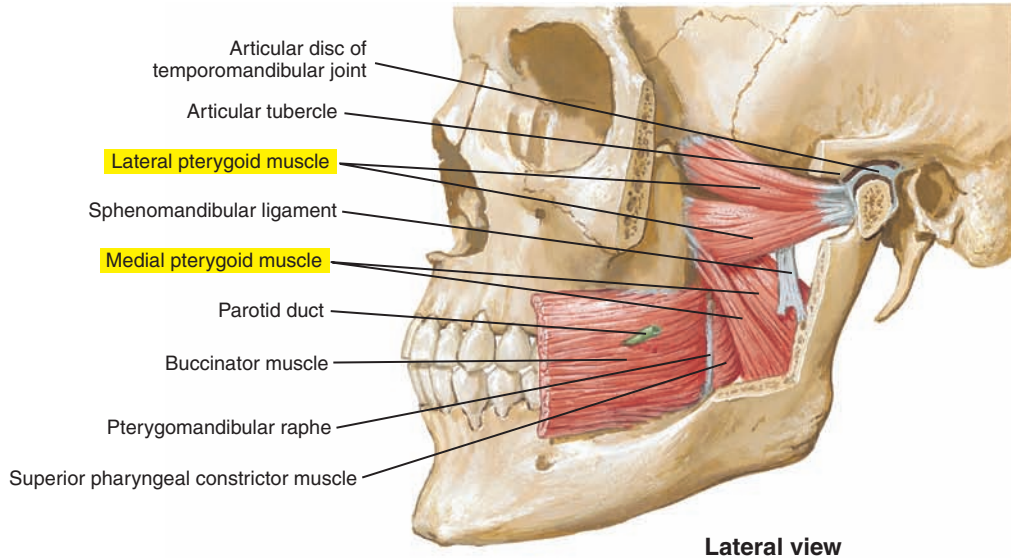
The temporalis muscle is composed of anterior, middle, and posterior portions. It originates from the temporal fossa on the frontal, parietal, temporal, and sphenoid bones. Its fibers converge under the zygomatic arch to form a tendon that inserts on the coronoid process and the anterior surface of the ramus of the mandible. Contraction of the anterior and middle portions, composed principally of vertical fibers, elevates the mandible. Contraction of the posterior portion, which is made of more horizontal fibers, may elevate and retract the mandible. Unilateral contraction of these muscle fibers may contribute to lateral movements of the jaw.

The temporalis muscle is innervated by the deep temporal nerve of the mandibular division of the trigeminal nerve (cranial nerve V).

***Medial (Internal) Pterygoid Muscle***

The medial (internal) pterygoid muscle originates primarily from the medial surface of the lateral pterygoid plate of the sphenoid bone. A small group of fibers originates from the maxillary tuberosity and from the pyramidal process of the palatine bone. The fibers travel inferiorly, posteriorly, and laterally to insert on the internal surface of the angle and ramus of the mandible. This muscle forms, with the masseter muscle, a sling that surrounds the angle of the mandible and works with the masseter muscle and temporalis muscle to elevate the jaw. It acts in synergy with the lateral pterygoid muscle and the masseter muscle for jaw protrusion. Unilateral contraction of the medial pterygoid muscle moves the mandible laterally toward the opposite side. This action permits grinding movements during mastication.

The medial pterygoid muscle is innervated by the medial pterygoid nerve of the mandibular division of the trigeminal nerve (cranial nerve V).



**Figure 3-20.** Lateral and posterior views of the muscles of mastication.

**Four Jaw-Opening Muscles (Jaw Depressors)** (Figures 3-21 [p. 150] and 3-22 [p. 151]; see also Figure 3-20 [p. 147])

***Lateral (External) Pterygoid Muscle***

The lateral (external) pterygoid muscle has two heads. The superior portion originates from the fossa of the greater wing of the sphenoid bone and the inferior portion from the external surface of the lateral pterygoid plate of the sphenoid bone. Fibers course horizontally to insert on the articular disc of the temporomandibular joint and on the condylar process of the mandible. The superior portion of this muscle is co-activated with jaw-closing muscles during mastication. The bilateral contraction of the inferior portion protrudes the mandible. The alternating unilateral contraction of the inferior portion produces a lateral movement of the mandible toward the opposite side.

The lateral pterygoid muscle is innervated by the anterior trunk of the mandibular division of the trigeminal nerve (cranial nerve V).

***Digastric Muscle***

The digastric muscle is frequently classified as a suprahyoid muscle. Anatomically, this muscle contains posterior and anterior “bellies” (hence its name) that are linked by a central tendon. This central tendon is fixed to the hyoid bone by a loop-shaped intermediate tendon. With the jaw fixed by other muscles, muscular contraction may contribute to the elevation of the hyoid bone. With the hyoid bone fixed by other muscles, the digastric muscle acts as a jaw opener.

The posterior belly of the digastric muscle is innervated by the digastric branch of the facial nerve (cranial nerve VII), and the anterior belly of the digastric muscle is innervated by the mylohyoid branch of the inferior alveolar nerve of the mandibular division of the trigeminal nerve (cranial nerve V).

***Mylohyoid Muscle***

The mylohyoid muscle originates from the mylohyoid line (internal oblique line) of the mandible. The anterior and middle fibers insert into the median mylohyoid raphe joined by muscular fibers of the opposite side. The posterior fibers insert on the hyoid bone. The mylohyoid is fan-shaped and contributes to the muscular floor of the mouth. Contraction elevates the hyoid and the floor of the mouth (or stabilizes the floor). It can also contribute to jaw opening if the hyoid bone is fixed.

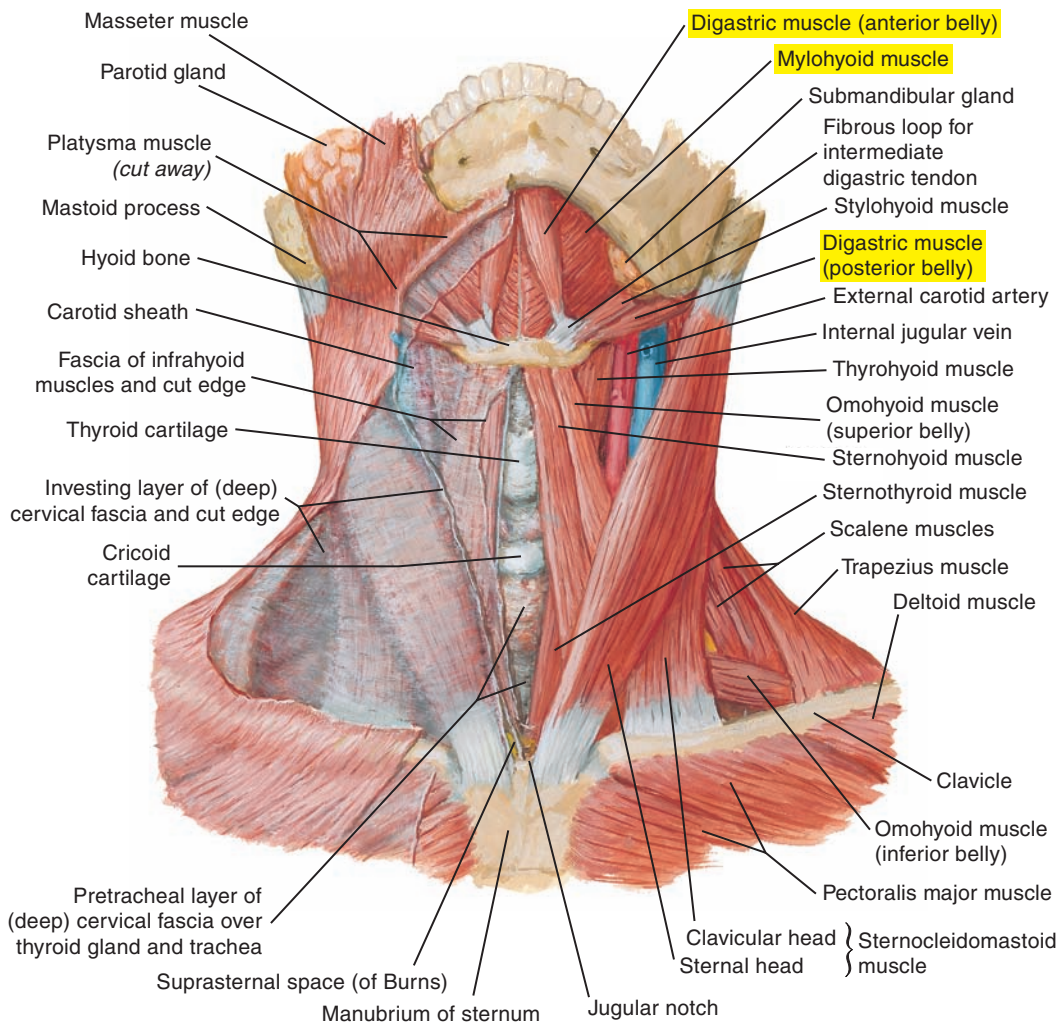
The mylohyoid muscle is innervated by the mylohyoid branch of the inferior alveolar nerve of the mandibular division of the trigeminal nerve (cranial nerve V).

***Geniohyoid Muscle***

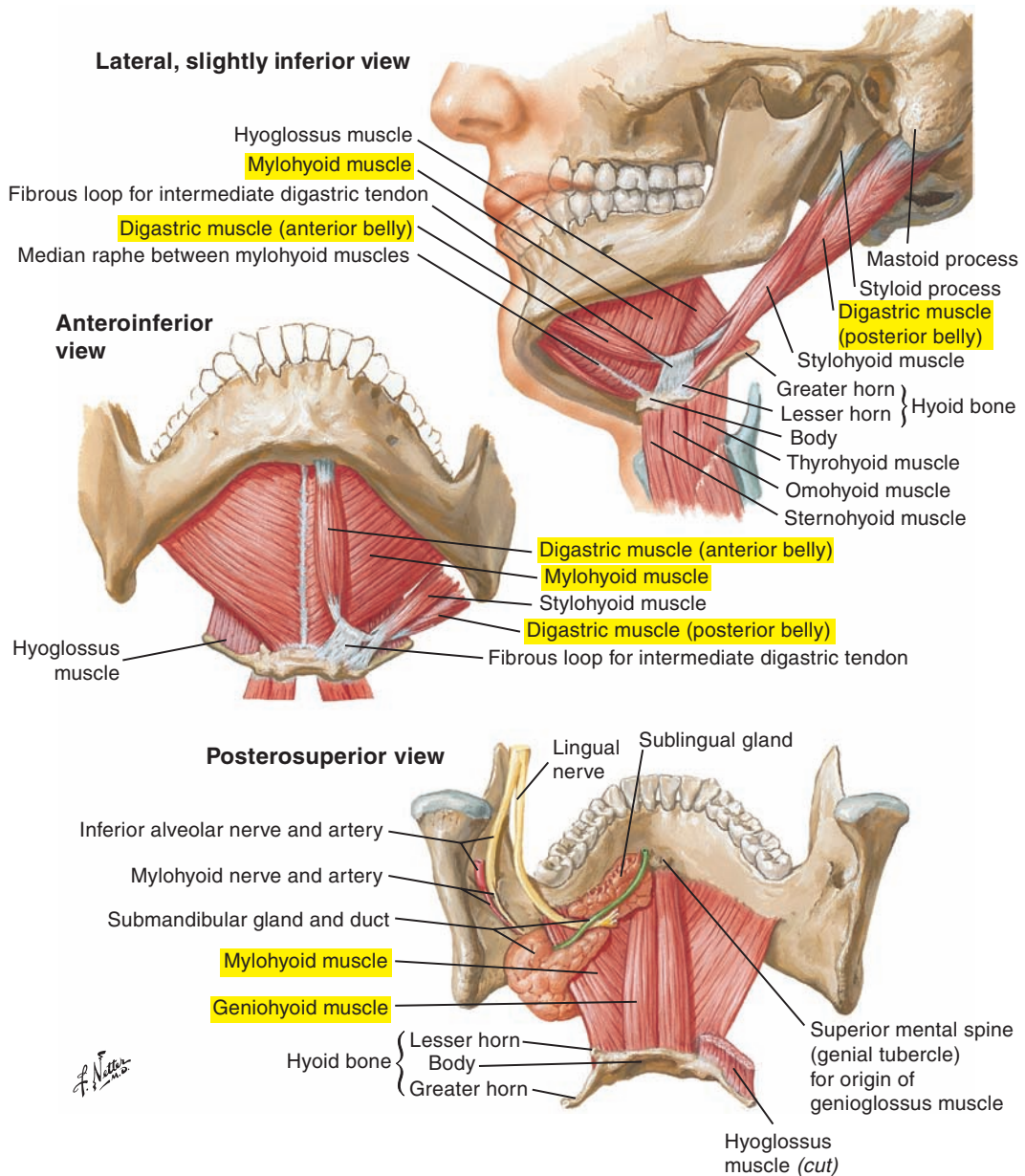
The geniohyoid muscle extends from the internal surface of the mandible (inferior mental spine) to the hyoid bone. Two bellies are located on each side of the median line and almost parallel to the anterior bellies of the digastric muscle, which are inferior. Contraction of the mylohyoid and the geniohyoid muscles may retract the jaw. Their contraction also contributes to jaw opening if the hyoid bone is stabilized.

The geniohyoid muscle is innervated by the first cervical spinal nerve (C1) traveling with the fibers of the hypoglossal nerve (cranial nerve XII).





**Figure 3-21.** Anterior view of the neck. Note the digastric and the mylohyoid muscles, both jaw openers.



**Figure 3-22.** The floor of the mouth and three muscles contributing to jaw opening: (1) the digastric, (2) the mylohyoid, and (3) the geniohyoid.

## ■ MUSCLES OF THE SOFT PALATE

---

The soft palate, or velum, is a posterior extension of the hard or bony palate. It is formed principally by five muscles: the levator veli palatini, the tensor veli palatini, the palatoglossus, the palatopharyngeus, and the uvular. The only intrinsic muscle of the soft palate is the uvular muscle. All other muscles have an exterior attachment.

### **Levator Veli Palatini Muscle** (Figure 3-23)

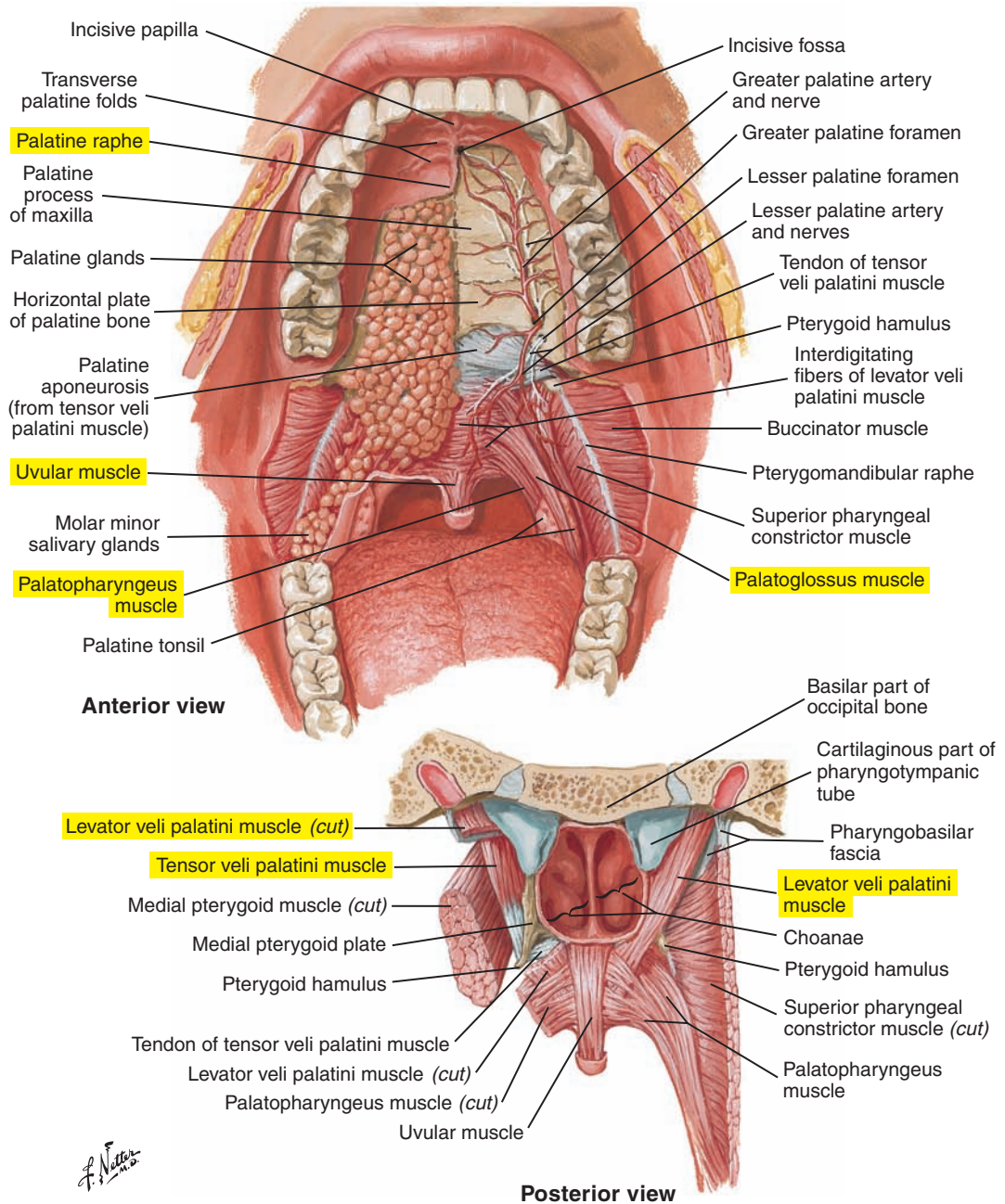
The levator veli palatini muscle is a palatal elevator. Fibers originate from the petrous portion of the temporal bone and the inferior aspect of the cartilaginous pharyngotympanic (auditory) tube. Fibers travel inferiorly and toward the midline to insert into the palatine raphe (aponeurosis) of the soft palate. Contraction of this muscle pulls the soft palate toward the posterior pharyngeal wall. The role of this muscle in contributing to the opening of the pharyngotympanic (auditory) tube for the ventilation of the middle ear is controversial (see Figure 3-9 [p. 123]).

The levator veli palatini muscle is innervated by the pharyngeal branch of the vagus nerve (cranial nerve X) via the pharyngeal plexus.

### **Tensor Veli Palatini Muscle** (see Figure 3-23; see also Figure 3-8 [p. 121])

The tensor veli palatini muscle has three origins: the scaphoid fossa of the pterygoid process, the spine of the sphenoid bone, and the lateral cartilaginous walls of the pharyngotympanic tube. The fibers travel forward and downward to converge on a tendon that wraps around the hamulus and inserts into the palatine raphe (aponeurosis) and the horizontal plates of the palatine bone. This muscle dilates the pharyngotympanic tube and may also tense the palate.

The tensor veli palatini muscle is innervated by the medial pterygoid nerve of the mandibular division of the trigeminal nerve (cranial nerve V).



**Figure 3-23.** The soft palate and associated structures.



**Palatoglossus (Glossopalatine) Muscle** (see [Figure 3-23](#) [p. 153])

The palatoglossus (glossopalatine) muscle originates from the inferior surface of the palatine raphe (aponeurosis). Fibers course inferiorly to insert underneath the sides of the posterior portion of the tongue, principally on superficial muscles (located under the posterior portions of the sides of the tongue) and transverse muscles. The muscular fibers of the palatoglossus muscle form the bulk of the palatoglossal arch (or anterior faucial pillar) visible in the oral cavity. Contraction of this muscle may depress the soft palate or elevate the tongue with the soft palate fixed. This muscle approximates the palatoglossal arches.

The palatoglossus muscle is innervated by the pharyngeal branch of the vagus nerve (cranial nerve X) via the pharyngeal plexus.

**Palatopharyngeus Muscle** (see [Figure 3-23](#) [p. 153])

The palatopharyngeus muscle originates from the palatine raphe (aponeurosis). Its fibers form the bulk of the palatopharyngeal arch (posterior faucial pillar). Fibers travel inferiorly with the muscular fibers of the stylopharyngeus muscle. The palatopharyngeus muscle inserts on the posterior border of the thyroid cartilage and on the inferior pharynx. Contraction of this muscle may depress the soft palate, elevate and constrict the pharynx, and elevate the larynx. This muscle approximates the palatopharyngeal arches.

The palatopharyngeus muscle is innervated by the pharyngeal branch of the vagus nerve (cranial nerve X) via the pharyngeal plexus.

**Uvular Muscle (Musculus Uvulae)** (see [Figure 3-23](#) [p. 153])

The uvular muscle extends from the posterior nasal spine and the palatine raphe (aponeurosis) to insert into the mucosa of the uvula. The function of this muscle is not well understood. However, it may play a role in the elevation of the soft palate. The uvula is an important landmark during an oral examination because its orientation and form may reflect anomalies of the hard and soft palate.

The uvular muscle is innervated by the pharyngeal branch of the vagus nerve (cranial nerve X) via the pharyngeal plexus.



## ■ MUSCLES OF THE PHARYNX

### **Superior Pharyngeal Constrictor Muscle** (Figure 3-24 [p. 156])

The superior pharyngeal constrictor muscle forms a tube starting at the level of the pterygomandibular raphe. Its fibers circle around posteriorly to insert into the median pharyngeal raphe. This muscle forms the sides and the back of the nasopharynx and a part of the posterior wall of the oropharynx. Contraction of this muscle pulls the pharyngeal wall forward and reduces the pharyngeal diameter during swallowing, thus contributing to the contraction (or propulsive) pressure applied to the swallowed bolus. It also contributes to pharyngeal tone and plays a role in velopharyngeal closure, which is discussed on p. 157.

The superior constrictor muscle is innervated by the pharyngeal branch of the vagus nerve (cranial nerve X) via the pharyngeal plexus.

### **Middle Pharyngeal Constrictor Muscle** (see Figure 3-24 [p. 156])

The middle pharyngeal constrictor muscle originates from the greater horns of the hyoid bone and the stylohyoid ligament to circle posteriorly to insert in the median pharyngeal raphe. Its contraction reduces the diameter of the pharynx and contributes to the contraction (or propulsive) pressure applied to the swallowed bolus. It also contributes to pharyngeal tone.

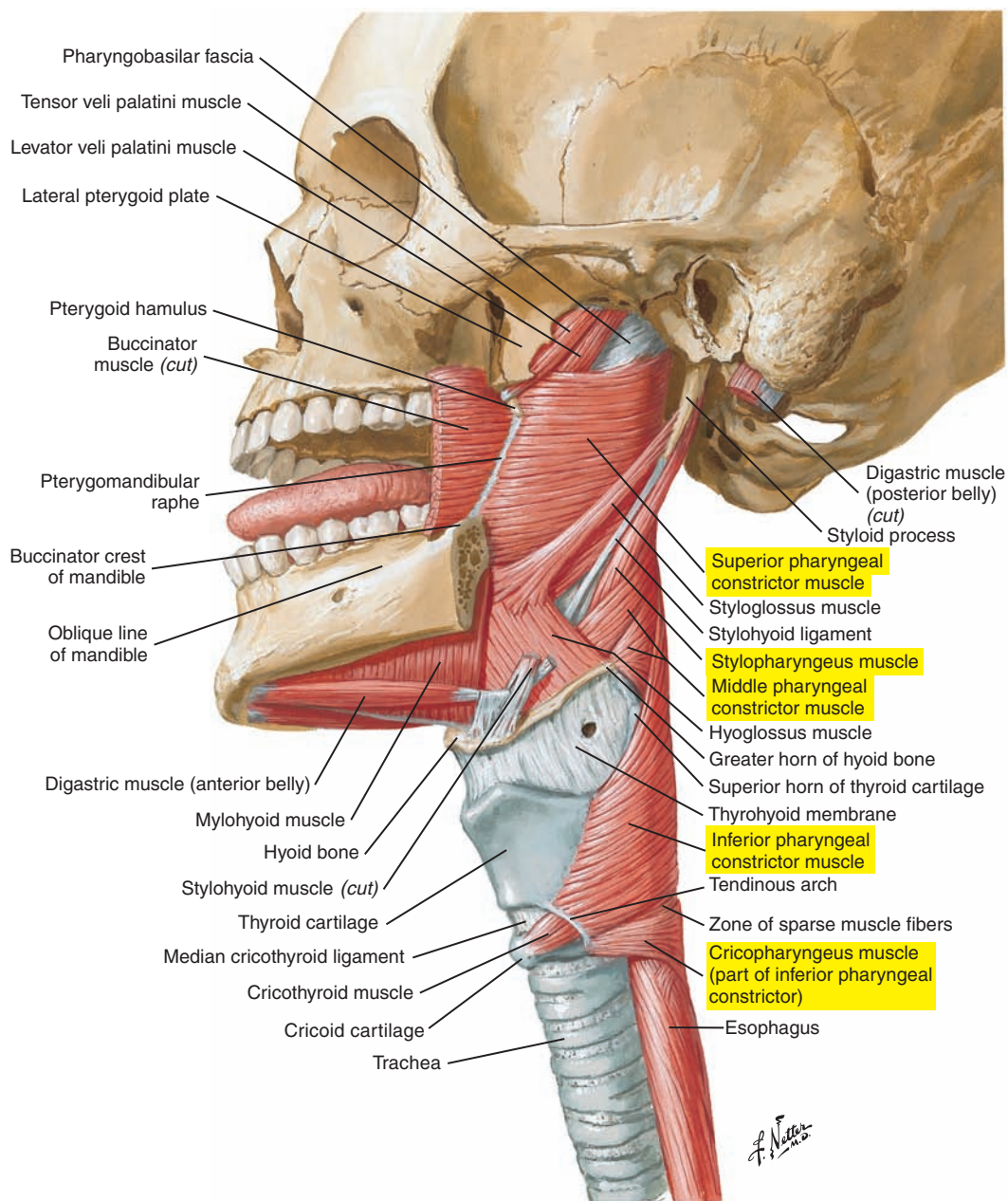
The middle constrictor muscle is innervated by the pharyngeal branch of the vagus nerve (cranial nerve X) via the pharyngeal plexus.

### **Inferior Pharyngeal Constrictor Muscle** (see Figure 3-24 [p. 156])

The inferior pharyngeal constrictor muscle exerts the most force of the pharyngeal constrictors. Some fibers originate from the sides of the cricoid cartilage to form the cricopharyngeus muscle, which forms the sphincter-like opening to the cervical esophagus during swallowing. A myotomized and residual form of this muscle and the pharynx are used to generate the esophageal sound source used by patients with laryngectomies. Swallowed air is expelled against a closed esophageal sphincter, causing it to vibrate.

Part of this muscle originates from the thyroid lamina and inserts on the median pharyngeal raphe (thyropharyngeus). Contraction of this muscle reduces the diameter of the inferior part of the pharynx.

The inferior constrictor muscle is innervated by the pharyngeal branch of the vagus nerve (cranial nerve X) via the pharyngeal plexus, as well as by the recurrent laryngeal nerve and external branch of the superior laryngeal nerve of the vagus nerve.



**Figure 3-24.** Lateral view of the muscles of the pharynx.

**Salpingopharyngeus Muscle** (Figure 3-25 [p. 158])

The salpingopharyngeus muscle originates at the inferoposterior surface of the cartilage of the pharyngotympanic tube and travels posteriorly to insert on the lateral walls of the pharynx. Its fibers mix with those of the palatopharyngeus muscle. Its contraction contributes to the elevation of the pharynx during swallowing and may contribute to the distortion of the tubal cartilage of the pharyngotympanic tube to permit aeration of the middle ear.

The salpingopharyngeus muscle is innervated by the pharyngeal branch of the vagus nerve (cranial nerve X) via the pharyngeal plexus.

**Stylopharyngeus Muscle** (Figure 3-26 [p. 159]; see also Figure 3-24 [p. 156])

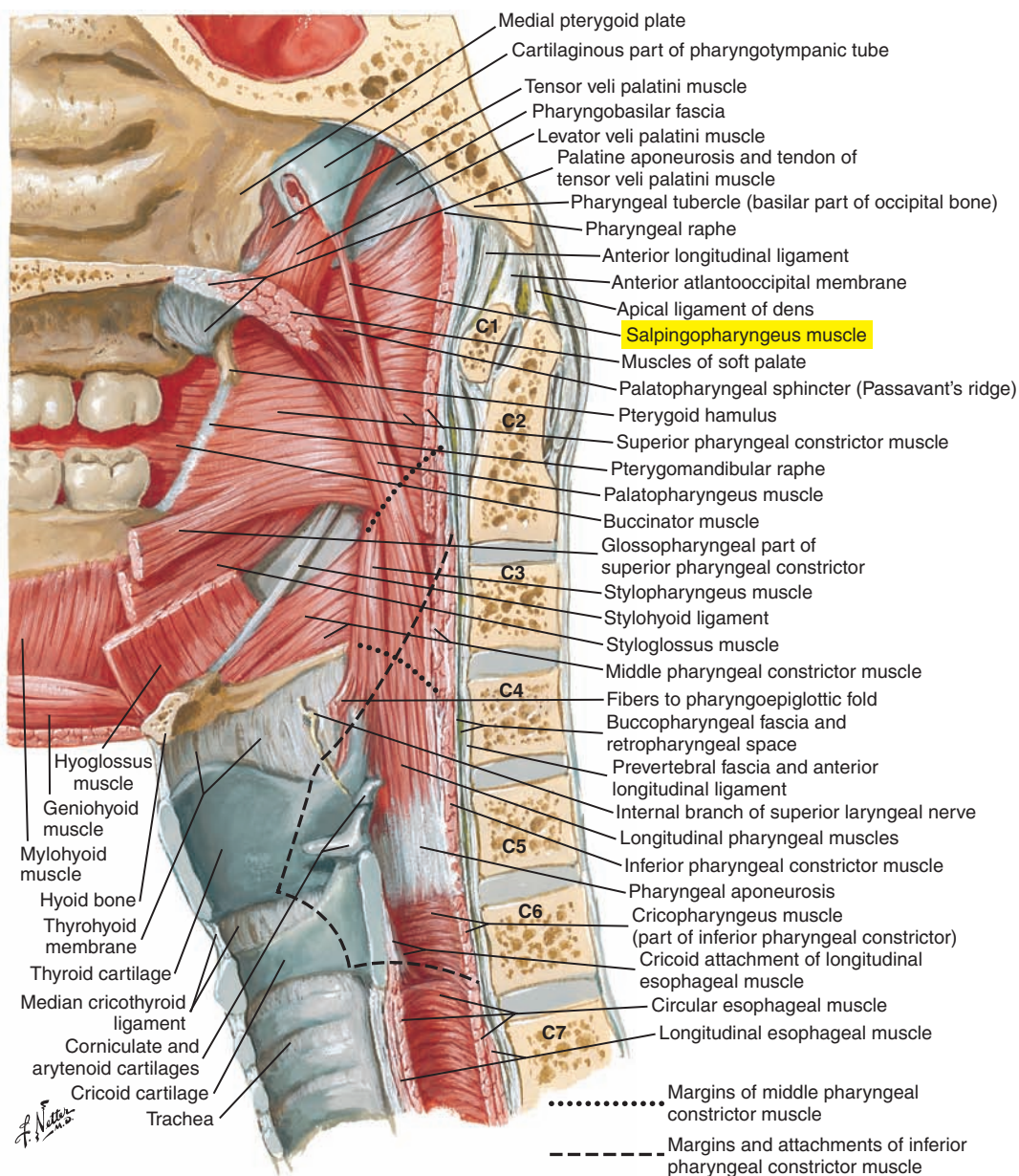
The stylopharyngeus muscle constitutes a thin group of muscular fibers. Its origin is on the base of the styloid process of the temporal bone. It travels inferiorly and medially between the superior and middle pharyngeal constrictor muscles. This muscle inserts in the mucous membrane of the pharynx and on the thyroid cartilage. Its contraction elevates the larynx and elevates and expands the pharynx during swallowing.

The stylopharyngeus muscle is innervated by the glossopharyngeal nerve (cranial nerve IX).

**Velopharyngeal Mechanism**

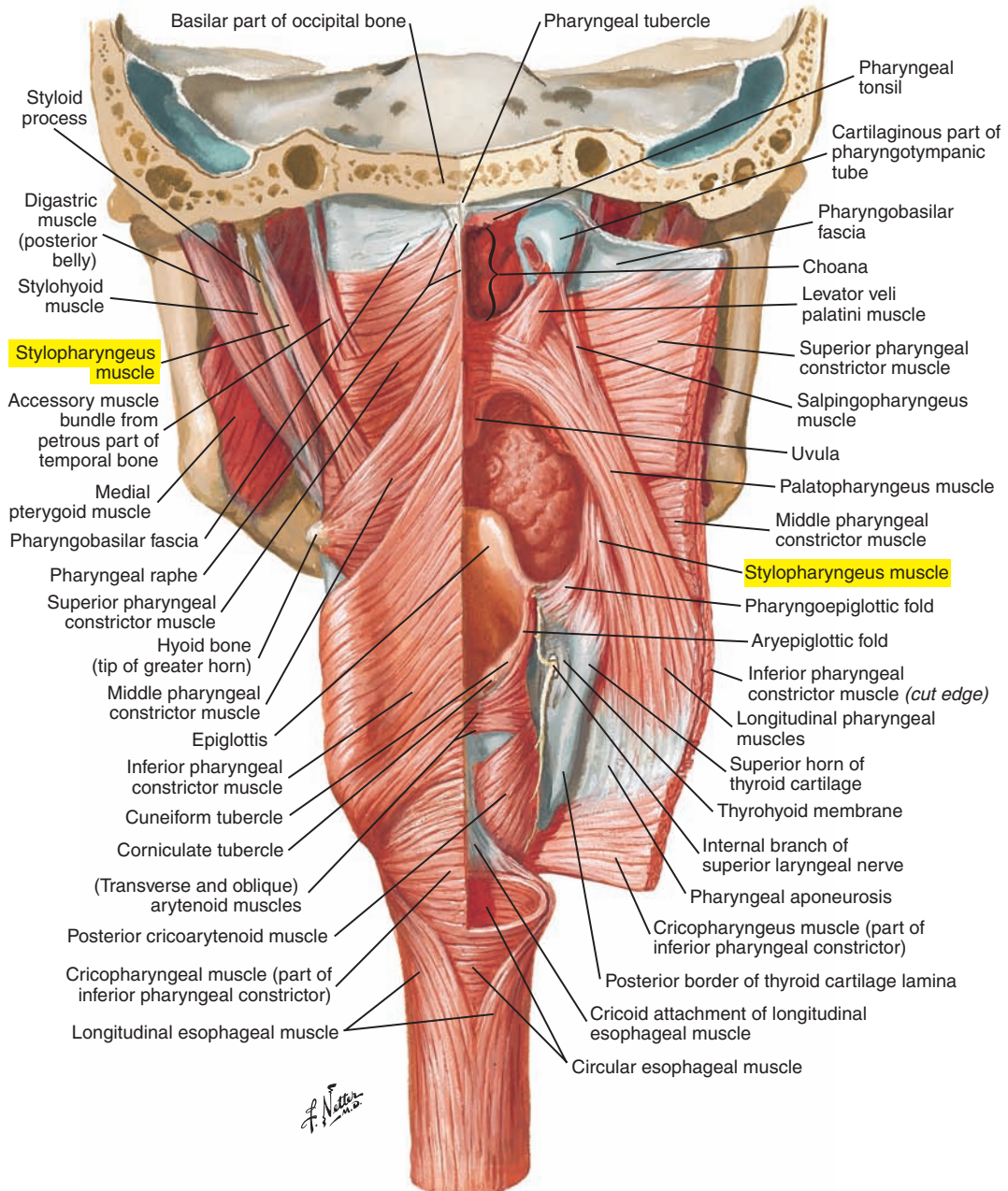
The velopharyngeal mechanism (velopharyngeal closure) is an essential process for speech and swallowing. It involves the movement of many articulatory structures that act to modify the coupling between the nasal and oral cavities. Some speech sounds are produced with the laryngeal voice source passing only through the vocal tract, excluding the nasal cavity (oral sounds), and some are produced with both the oral and nasal cavities (nasal sounds). The velopharyngeal mechanism acts as a regulator for coupling or decoupling of the nasal cavity from the rest of the vocal tract. Elevating and retracting the soft palate and constricting the walls of the nasopharynx and anterior movements of the posterior wall of the pharynx block the nasal cavity for the production of oral sounds. Opposite movements of the velopharynx allow the laryngeal sound source to pass through and thus be modified by the nasal cavity. This creates the nasal sounds.

Velopharyngeal closure is an important airway protective mechanism for swallowing. Closure prevents food from entering the nasal cavity during the passage of the bolus through the pharynx. Depression of the soft palate assists in containing the food and/or liquid bolus within the oral cavity before transport to the pharynx.



**Figure 3-25.** Median (sagittal) section of the pharynx. Note especially the salpingopharyngeus muscle.





**Figure 3-26.** A posterior, partially reflected view of the pharynx. Note especially the stylopharyngeus muscle.



## ■ ESOPHAGUS

---

The esophagus is an important muscular tube that is involved in transporting solids and liquids from the pharynx to the stomach during swallowing. This complex structure is briefly summarized here.

**Upper Esophageal, or Cricopharyngeal, Sphincter** (Figures 3-27, 3-28 [p. 162], and 3-29 [p. 163])

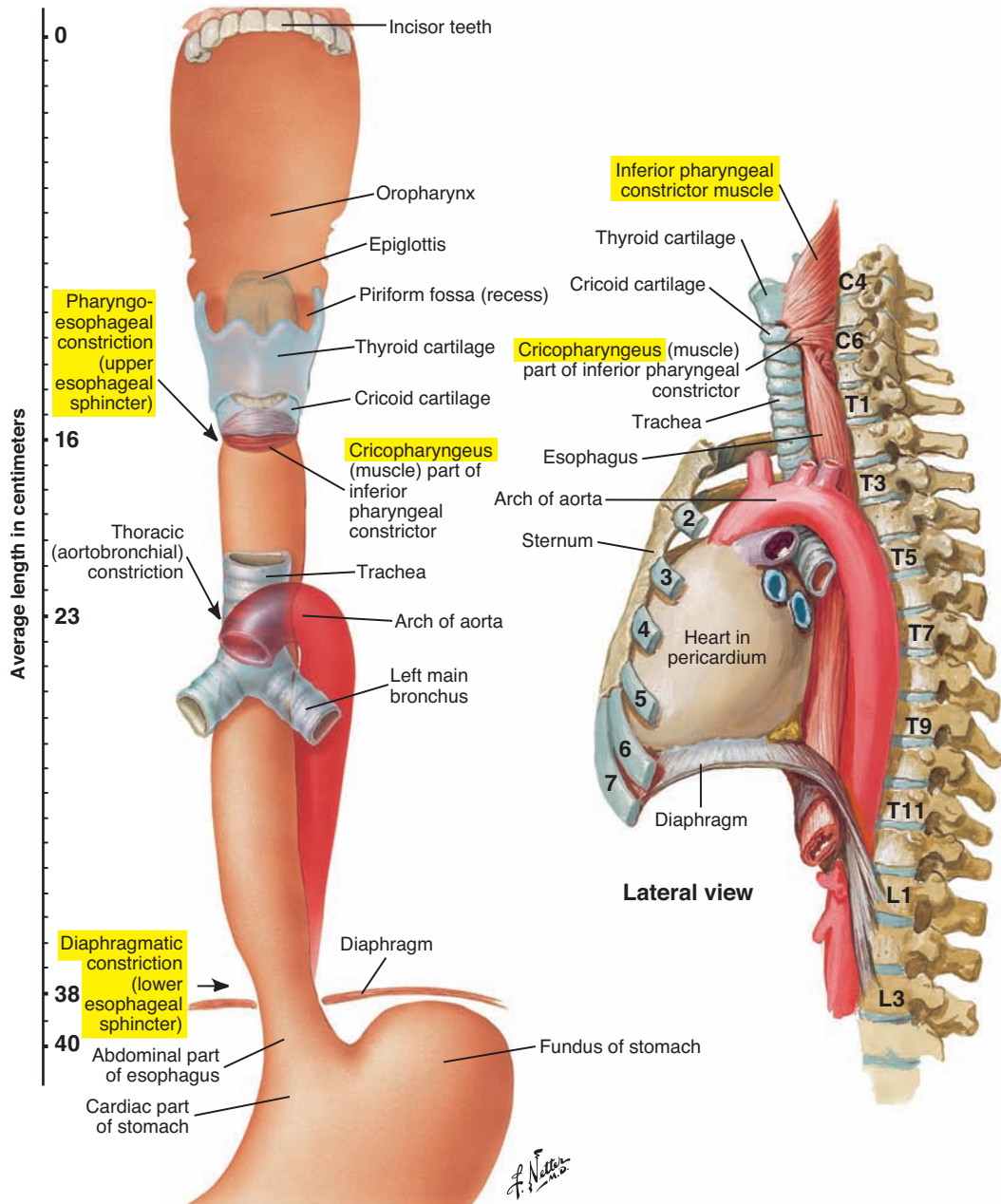
The upper esophageal sphincter is the opening to the cervical esophagus from the pharynx. It is formed by the cricopharyngeus muscle. The sphincter is normally closed as a result of passive relaxation forces and tension provided by the cricopharyngeus and the apposition of the cricoid cartilage anteriorly. It opens by relaxation of the cricopharyngeus muscle and “actively” from laryngeal elevation by suprahyoid muscles. The cricoid is “pulled away” from the posterior pharyngeal wall.

**Primary Esophageal Peristalsis** (see Figure 3-28 [p. 162] and 3-29 [p. 163])

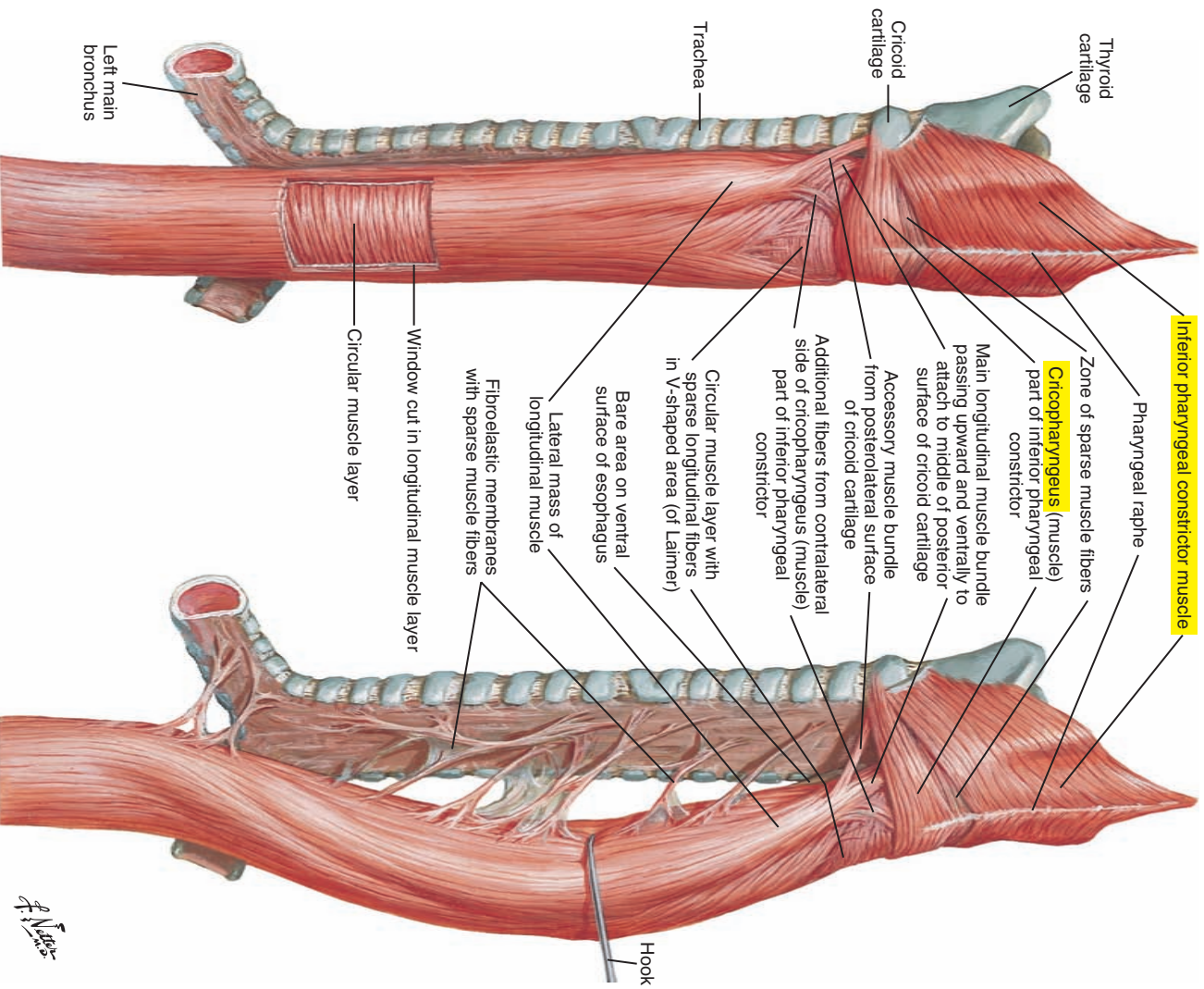
Peristalsis is the process by which liquids or solids move through the esophagus by muscular contraction. It occurs subsequent to pharyngeal contraction and the opening of the upper esophageal sphincter. Contractions in striated (cervical) esophageal muscle (inner circular and outer longitudinal fibers) are followed by smooth (thoracic) muscular contractions. Secondary peristalsis may clear bolus residue.

**Lower Esophageal Sphincter** (see Figure 3-27)

The lower esophageal sphincter is the muscular junction between the esophagus and the stomach. It is closed to prevent gastroesophageal reflux by smooth esophageal muscle and crural portions of the diaphragm. The sphincter opens to accommodate the passage of the swallowed bolus into and out of the esophagus.



**Figure 3-27.** Topography and constrictions of the esophagus.



**Figure 3-28.** Musculature of the esophagus.

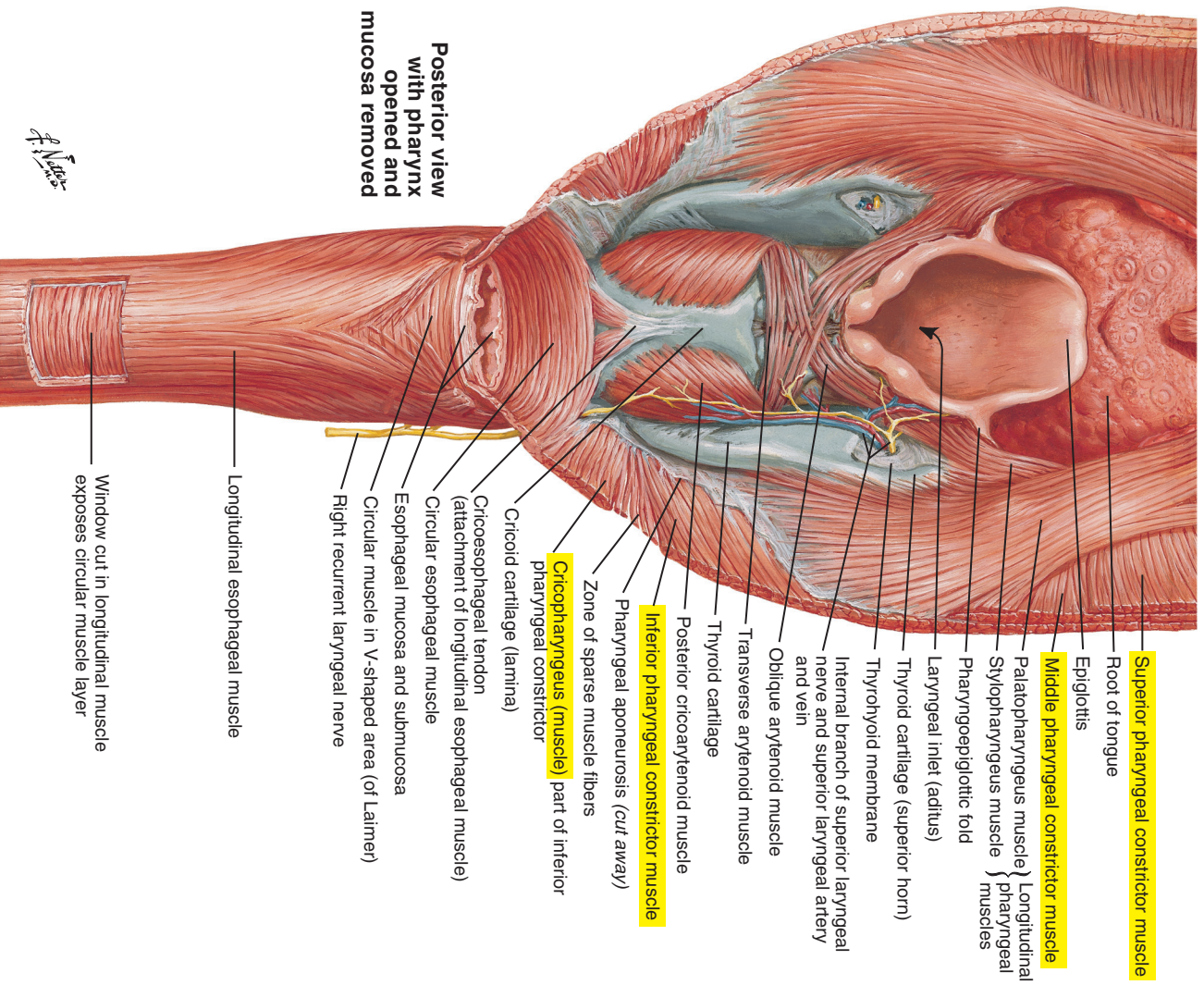


Figure 3-29. The pharyngoesophageal junction.



Muscles of the Lips and Facial Expression (see <a href="#">Figures 3-15</a> [p. 135] and <a href="#">3-16</a> [p. 137])				
Muscle	Origin	Insertion	Action	Innervation
<b>Muscles of the Lips</b>				
Orbicularis oris (pars marginalis and pars peripheralis)	Primarily horizontally oriented muscular fibers encircling the mouth from the modiolus	Facial midline	Complex function depends on other co-activated muscles: <ul style="list-style-type: none"> <li>Closes the lips and projects them forward</li> <li>Contracts and presses the lips against the incisors</li> </ul>	Buccal and mandibular branches of the facial nerve (cranial nerve VII)
Depressor anguli oris	External oblique line of the mandible	Modiolus and inferior portion of the orbicularis oris muscle	Depresses the angle of the mouth, as in a sad expression	Mandibular and buccal branches of the facial nerve (cranial nerve VII)
Levator anguli oris	Canine fossa of the maxilla	Modiolus and superior portion of the orbicularis oris muscle	Pulls the corner of the lips superiorly and laterally and deepens the nasolabial fold, as in smiling or laughing	Zygomatic and buccal branches of the facial nerve (cranial nerve VII)
Zygomaticus major	Zygomatic bone	Superior portion of the orbicularis oris muscle and modiolus	Pulls the lips superiorly and laterally, as when smiling or laughing	Buccal and zygomatic branches of the facial nerve (cranial nerve VII)
Risorius (variable muscle that is sometimes absent)	Fascia above the parotid gland Aponeurosis of the masseter muscle	Modiolus	Pulls the lips laterally, as in laughing	Zygomatic and buccal branches of the facial nerve (cranial nerve VII)
Levator labii superioris alaeque nasi	Frontal process of the maxilla	Medial portion: alar cartilage Lateral portion: superior orbicularis oris muscle	Medial portion: dilates nostril Lateral portion: elevates and everts the upper lip and contributes to deepen the nasolabial fold	Zygomatic and buccal branches of the facial nerve (cranial nerve VII)
Levator labii superioris	Inferior surface of the orbit	Superior orbicularis oris muscle	Elevates and everts the upper lip and contributes to deepen the nasolabial fold	Zygomatic and buccal branches of the facial nerve (cranial nerve VII)
Depressor labii inferioris	External oblique line of the mandible	Modiolus and inferior orbicularis oris muscle	Pulls the lower lip down and may contribute to expressions of sadness	Mandibular branch of the facial nerve (cranial nerve VII)



Zygomaticus minor (variable muscle that is sometimes absent)	Zygomatic bone	Superior portion of orbicularis oris muscle and modiolus	Elevates the upper lip and deepens the nasolabial fold, as in smiling	Zygomatic and buccal branches of the facial nerve (cranial nerve VII)
<b>Muscle of the Cheek</b>				
Buccinator	Alveolar processes of the mandible and maxilla and pterygo-mandibular raphe (ligament); fibers course horizontally	Modiolus and superior orbicularis oris muscle	Compresses the cheeks Pulls the lips laterally	Buccal branch of the facial nerve (cranial nerve VII)
<b>Muscle of the Chin</b>				
Mentalis	Incisive fossa of the mandible	Skin of the chin Inferior orbicularis oris muscle	Elevates, protrudes, and everts the lower lip May crease the chin	Mandibular branch of the facial nerve (cranial nerve VII)
<b>Muscles of the Nose</b>				
Nasalis compressor naris	Maxilla	Bridge of the nose	Compresses the back of the nose	Zygomatic and buccal branches of the facial nerve (cranial nerve VII)
Nasalis dilator naris	Nasal side of the maxillary bone	Alae of the nose	Dilates the nostrils	Zygomatic and buccal branches of the facial nerve (cranial nerve VII)
Depressor septi	Maxillary incisive fossa	Alae of the nose	Dilates the nostrils	Zygomatic and buccal branches of the facial nerve (cranial nerve VII)
<b>Muscle of the Neck</b>				
Platysma	Fascia covering the deltoid muscle and the pectoralis muscle	Cheeks and muscles of the mouth and modiolus Some fibers may extend to muscles surrounding eyes (extent is variable)	Expands neck, pulls skin of neck upward, and depresses the lower lip and jaw	Cervical branch of the facial nerve (cranial nerve VII)

Muscles of the Tongue (see <a href="#">Figures 3-17</a> [p. 141] and <a href="#">3-18</a> [p. 143])				
Muscle	Origin	Insertion	Action	Innervation
<b>Intrinsic Tongue Muscles</b>				
Superior longitudinal	Fibrous tissue at the root and median fibrous septum	Fibrous membrane on the sides of the tongue	Shortens the tongue Turns the apex upward	Hypoglossal nerve (cranial nerve XII)
Inferior longitudinal	Root of the tongue	Apex of the tongue	Shortens the tongue Pulls the apex downward	Hypoglossal nerve (cranial nerve XII)
Transverse	Median fibrous septum	Fibrous tissues at lateral margins	Makes the tongue narrower and elongates it	Hypoglossal nerve (cranial nerve XII)
Vertical	Mucous membrane of tongue dorsum	Inferior and lateral tongue margins	Flattens and widens the tongue	Hypoglossal nerve (cranial nerve XII)
<b>Extrinsic Tongue Muscles</b>				
Palatoglossus	Inferior surface of palatal aponeurosis	Posterolateral portion of the tongue	Approximates tongue and soft palate and constricts oropharyngeal isthmus	Pharyngeal branch of the vagus nerve (cranial nerve X) via the pharyngeal plexus
Styloglossus	Styloid process of the temporal bone Stylomandibular ligament	Posterolateral portion of the tongue	Lifts the sides of the tongue Retracts the base of the tongue	Hypoglossal nerve (cranial nerve XII)
Hyoglossus	Greater horn and body of hyoid	Lateral sides of the tongue	Pulls down the sides of the tongue	Hypoglossal nerve (cranial nerve XII)
Genioglossus	Superior mental spine (genial tubercle) on the internal surface of the mandible	Back and apex of the tongue Inferior fibers insert on the hyoid bone	Protrudes the tongue and depresses central portion Also has been reported that a unilateral contraction moves the tongue on opposite side	Hypoglossal nerve (cranial nerve XII)

Muscles of Mastication (see Figures 3-15 [p. 135] and 3-20 [p. 147])				
Muscle	Origin	Insertion	Action	Innervation
<b>Jaw-Closing Muscles</b>				
Masseter (superficial and deep)	Zygomatic process of the maxilla Zygomatic arch	External surface of the angle and ramus of the mandible Coronoid process of the mandible	Elevates the mandible Superficial: helps protrude the mandible Deep: contributes to retraction of the mandible	Nerve to the masseter from mandibular division of the trigeminal nerve (cranial nerve V)
Temporalis (anterior, middle, and posterior)	Temporal fossa	Coronoid process of the mandible Anterior surface of the ramus of the mandible	Contraction of anterior and middle fibers elevates mandible Contraction of posterior fibers may elevate and retract mandible Unilateral contraction may contribute to lateral movement of mandible	Deep temporal nerve of the mandibular division of the trigeminal nerve (cranial nerve V)
Medial (internal) pterygoid	Medial surface of lateral pterygoid plate of sphenoid Pyramidal process of the palatine bone Maxillary tuberosity	Internal surface of the angle and ramus of the mandible	Elevates the mandible with temporalis and masseter muscles Protrudes mandible with lateral pterygoid muscle Unilateral contracting: moves jaw laterally (opposite side)	Medial pterygoid nerve of the mandibular division of the trigeminal nerve (cranial nerve V)
<b>Jaw-Opening Muscles</b>				
Lateral (external) pterygoid	Superior: greater wing of sphenoid Inferior: external surface of lateral pterygoid plate of sphenoid	Articular disc of the temporomandibular joint Condyle of the mandible	Superior: co-activated with jaw-closing muscles Inferior: bilateral contraction protrudes mandible Unilateral contraction: moves mandible laterally toward the opposite side (grinding)	Anterior trunk of mandibular division of the trigeminal nerve (cranial nerve V)
Digastric	Medial surface of the mastoid process of temporal bone	Lower border of the mandible near the midline with the intermediate tendon tethered to the hyoid by a fibrous loop of connective tissue	With the mandible stabilized, aids in elevating the hyoid bone, which is necessary for swallowing Opens jaw when the hyoid bone is fixed	Posterior belly: digastric branch of the facial nerve (cranial nerve VII) Anterior belly: mylohyoid branch of the inferior alveolar nerve of the mandibular division of the trigeminal nerve (cranial nerve V) via the mylohyoid nerve
Mylohyoid	On the mylohyoid line (internal oblique line) on the internal surface of the mandible	Anterior and middle fibers: midline raphe, where fibers are linked with those of the opposite side Posterior fibers: body of the hyoid bone	Elevates the floor of the mouth and the hyoid bone Contributes to jaw opening if hyoid bone is fixed	Mylohyoid branch of the inferior alveolar nerve of the mandibular division of the trigeminal nerve (cranial nerve V)
Geniohyoid	Inferior mental spine on the internal surface of the mandible	Anterior surface of the body of the hyoid bone	Contributes to jaw opening if hyoid bone is fixed	First cervical spinal nerve (C1) traveling with fibers of the hypoglossal nerve (cranial nerve XII)

Muscles of the Soft Palate (see <a href="#">Figure 3-23</a> [p. 153])				
Muscle	Origin	Insertion	Action	Innervation
Levator veli palatini	Petrous portion of temporal bone Inferior aspect of the cartilaginous pharyngotympanic tube	Palatine raphe (aponeurosis)	Elevates the soft palate and may contribute to dilate pharyngotympanic tube	Pharyngeal branch of the vagus nerve (cranial nerve X) via the pharyngeal plexus
Tensor veli palatini	Scaphoid fossa Spine of the sphenoid Lateral cartilaginous walls of the pharyngotympanic tube	The tendon wraps around the pterygoid hamulus and inserts into the palatine aponeurosis and the horizontal plates of the palatine bone	Dilates the pharyngotympanic tube during swallowing and yawning and tenses the palate	Medial pterygoid nerve of the mandibular division of the trigeminal nerve (cranial nerve V)
Palatoglossus (forms palatoglossal arch)	Inferior surface of the palatine aponeurosis	Transverse and posterolateral muscular portions of the tongue	Lifts the tongue and pulls it backward Constricts the posterior limits of the oral cavity (to isolate from oropharynx)	Pharyngeal branch of the vagus nerve (cranial nerve X) via the pharyngeal plexus
Palatopharyngeus (forms palatopharyngeal arch)	Palatine aponeurosis	Posterior border of thyroid cartilage Inferior portion of pharynx	Pulls the soft palate down Constricts and lifts the pharynx Helps to direct the bolus into the pharynx during swallowing	Pharyngeal branch of the vagus nerve (cranial nerve X) via the pharyngeal plexus
Uvular	Posterior nasal spine Palatine aponeurosis	Mucosa of the uvula	May play a role in elevation of the soft palate	Pharyngeal plexus of the vagus nerve (cranial nerve X) via the pharyngeal plexus

Muscles of the Pharynx (see Figure 3-24 [p. 156])				
Muscle	Origin	Insertion	Action	Innervation
Superior pharyngeal constrictor	Medial pterygoid plate, pterygomandibular raphe, and mylohyoid line of mandible	Median pharyngeal raphe Pharyngeal tubercle on the basilar part of occipital bone	Reduces pharyngeal diameter during swallowing (propulsive pressure acting on bolus) and assists in velopharyngeal closure	Pharyngeal branch of the vagus nerve (cranial nerve X) via the pharyngeal plexus
Middle pharyngeal constrictor	Great horns of the hyoid bone and stylohyoid ligament	Median pharyngeal raphe	Reduces pharyngeal diameter during swallowing (propulsive pressure acting on bolus)	Pharyngeal branch of the vagus nerve (cranial nerve X) via the pharyngeal plexus
Inferior pharyngeal constrictor	Some fibers (cricopharyngeus muscle) originate from cricoid cartilage Most originate from thyroid lamina (thyropharyngeus muscle)	Median pharyngeal raphe (with the exception of the cricopharyngeus)	Reduces the diameter of the inferior portions of the pharynx and acts as the sphincter-like opening (cricopharyngeus muscle) to the cervical esophagus during swallowing	Pharyngeal branch of the vagus nerve (cranial nerve X) via the pharyngeal plexus, as well as recurrent laryngeal nerve and external branch of the superior laryngeal nerve of the vagus nerve (cranial nerve X)
Salpingopharyngeus muscle	Inferoposterior surface of the cartilage of the pharyngotympanic tube	Lateral walls of the pharynx (fibers mix with palatopharyngeus)	Contributes to elevation of the pharynx during swallowing and may contribute to the distortion of the tubal cartilage of the eustachian tube to permit aeration of the middle ear	Pharyngeal branch of the vagus (cranial nerve X) via the pharyngeal plexus
Stylopharyngeus muscle	Base of the styloid process of the temporal bone	Mucous membrane of the pharynx and on the thyroid cartilage	Elevates the larynx and elevates and expands the pharynx during swallowing	Glossopharyngeal nerve (cranial nerve IX)



This page intentionally left blank

# AUDITORY SYSTEM

## **Overview, 173**

### **Anatomical Divisions of the Ear, 174**

Outer Ear, 176

Middle Ear, 180

Inner Ear: Cochlea and Vestibular System, 186

Scala Media, or Cochlear Duct, 192

## **Cochlear Afferent and Efferent Innervation, 196**

Afferent Innervation, 196

Afferent Central Auditory Pathway, 197

Efferent Central Auditory Pathway (Auditory Centrifugal Pathway), 200

This page intentionally left blank

## ■ OVERVIEW

---

Hearing is vital to spoken language perception and production. Hearing impairment can drastically affect speech and language development in the infant and child. In the adult, hearing is an extremely important feedback source for appropriate speech sound production. It is also extremely important for many other aspects of day-to-day living, including the perception of music and other environmental sounds. Hearing is thus a crucial function that affects many aspects of quality of life in addition to its role in speech and language.

The study of the anatomy and function of the peripheral hearing system is typically divided into three functional components: (1) the outer ear, (2) the middle ear, and (3) the inner ear. Each of these components serves a different but complementary role in the transduction of environmental acoustic vibrations into neural impulses (sound).

The role of the external or outer ear is to capture sounds and direct them to a membrane that converts acoustic vibrations to mechanical energy. The membrane and three attached small bones and supporting muscles and ligaments in the middle ear transmit these sounds to the sensory end organ of hearing in the inner ear. They also provide an important impedance matching function between airborne sounds in the environment and fluid vibrations in the inner ear. In the inner ear, differences in stiffness along the basilar membrane cause it to vibrate with the greatest amplitude at different places along its length for different frequencies of sound. This stimulates complex and delicate sensory receptors, which transduce the motion into neural activity in the auditory nerve and higher levels of the central auditory system.

This chapter covers these three functional components of the peripheral hearing system—the outer ear, middle ear, and inner ear—and the central auditory pathway.

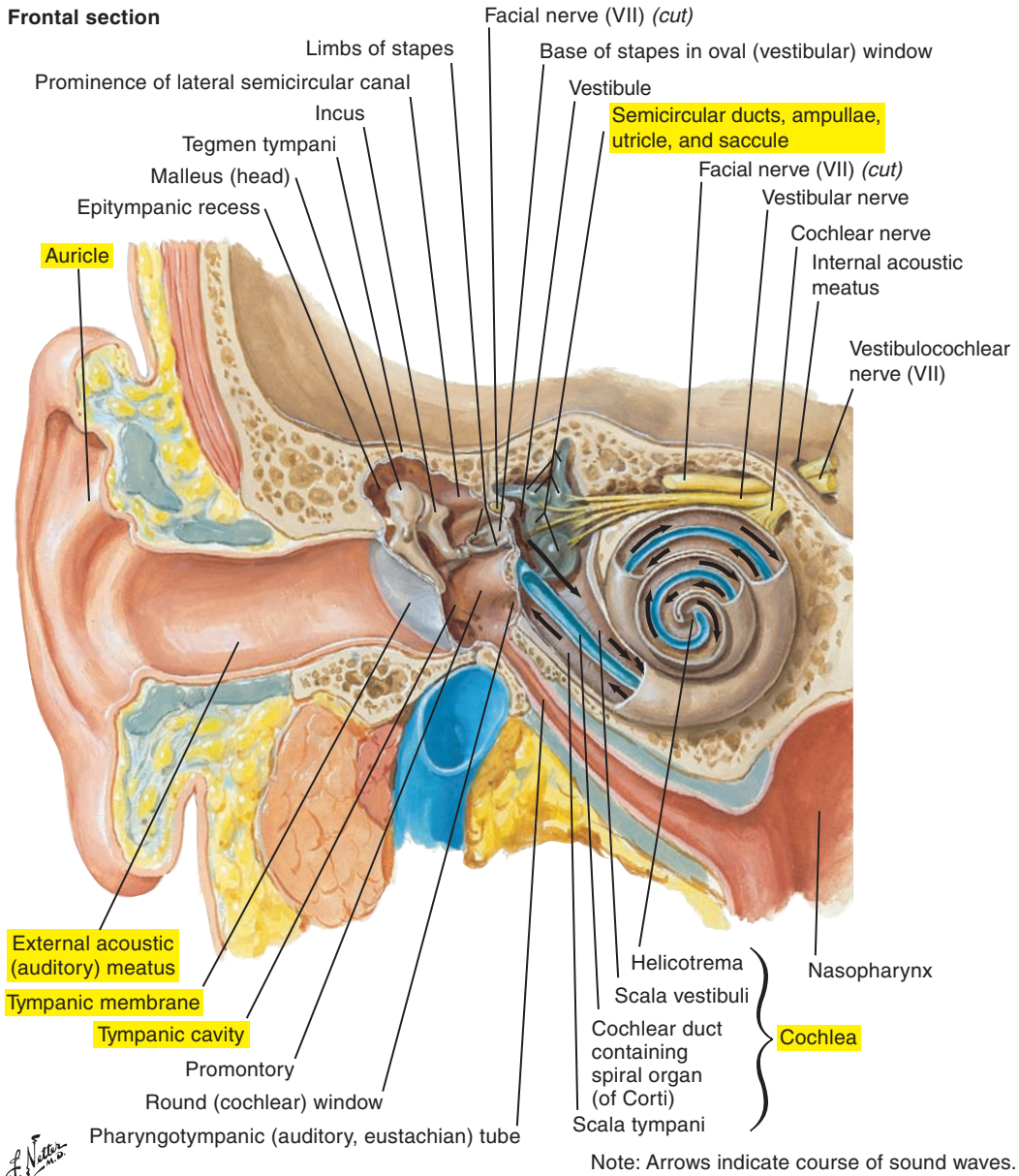
## ■ ANATOMICAL DIVISIONS OF THE EAR

---

The ear is divided into the following three major sections ([Figure 4-1](#)):

1. The outer ear is composed of the auricle and external acoustic (auditory) meatus.
2. The middle ear is composed of the tympanic cavity, the middle ear ossicles, and the middle ear muscles.
3. The inner ear is composed of the cochlea and the vestibular system.



**Frontal section**

**Figure 4-1.** The main anatomical divisions of the outer, middle, and inner ear.

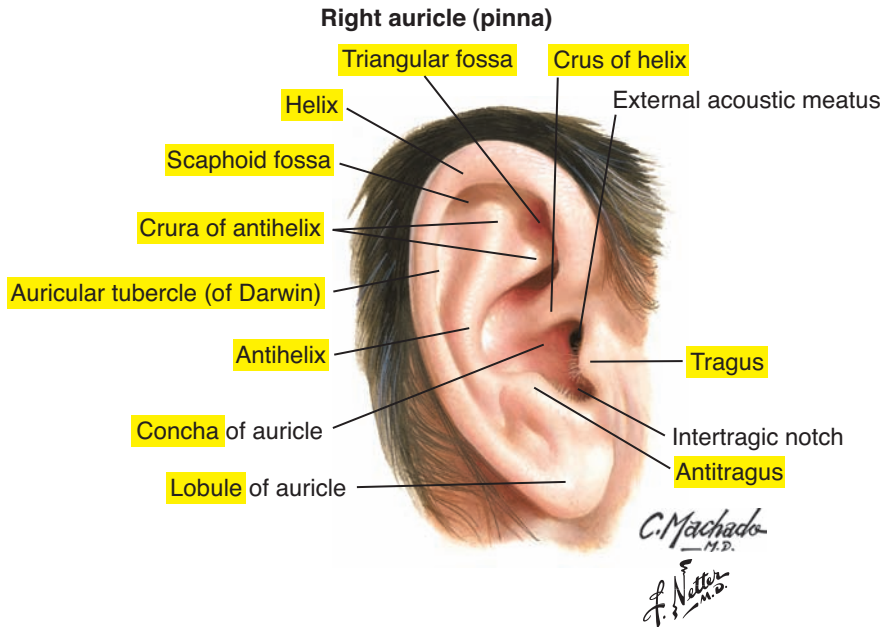
NOTE: Labels of certain figures are highlighted in yellow to emphasize the related elements in the corresponding text.

## Outer Ear

### **Auricle or Pinna** (Figure 4-2; see also Figure 4-1 [p. 175])

The auricle, or pinna, is a flaplike structure that helps direct sound waves into the external acoustic (auditory) meatus and aids in sound localization. Some animals can move their pinna extensively for additional directional selectivity. It is composed of fibrocartilage covered by skin and attached to the temporal bone by several extrinsic muscles and ligaments. Internal ligaments and muscles join auricular structures. The following are prominent surface landmarks:

- The helix is the curved outer rim.
- The crus of the helix divides the concha, with the inferior portion being the entrance to the external acoustic meatus.
- The auricular tubercle (of Darwin) is a small projection sometimes found on the lateral border of the helix.
- The antihelix is a second semicircular ridge anterior to the helix.
- The triangular fossa lies between the two crura of the antihelix.
- The scaphoid fossa lies between the helix and the antihelix.
- The tragus is the flap partially covering the entrance to the external auditory meatus.
- The antitragus is the smaller flap opposite the tragus.
- The lobule of the auricle (earlobe) is the noncartilaginous and highly vascular inferior extremity.



**Figure 4-2.** The auricle, or pinna.

**External Acoustic (Auditory) Meatus or Ear Canal** (see [Figure 4-1](#) [p. 175])

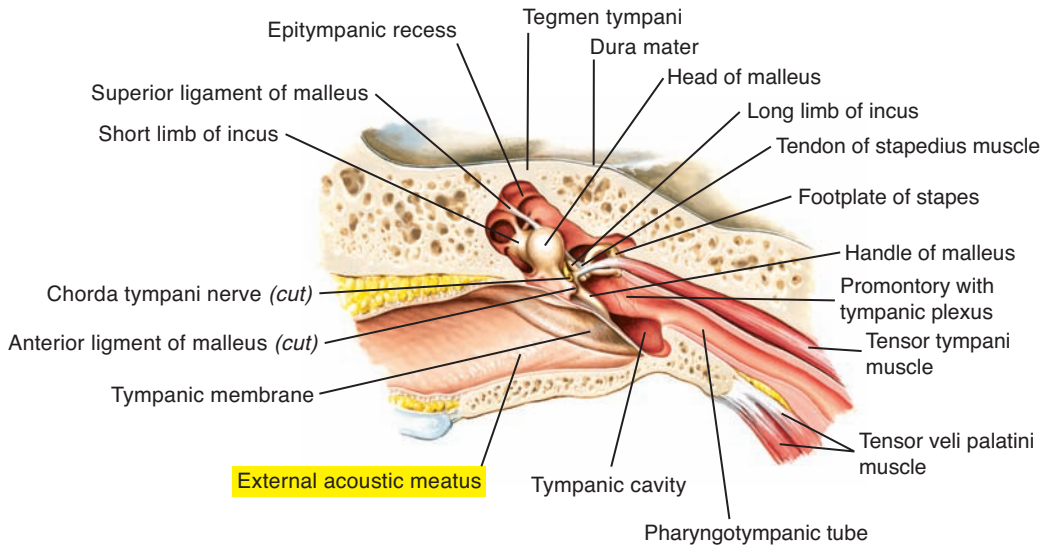
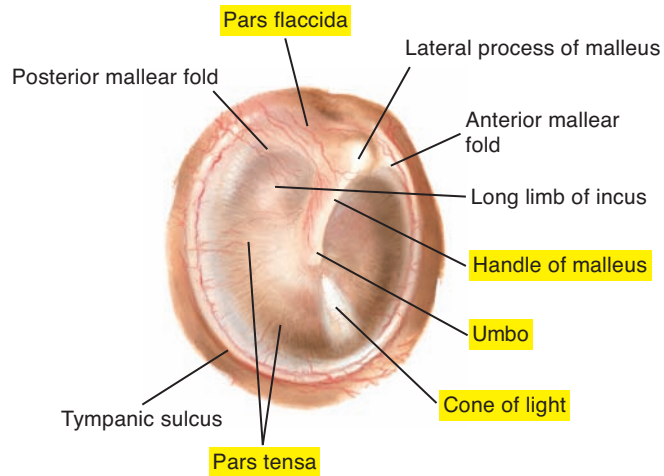
The external acoustic meatus, or ear canal, is an oval, S-shaped tube approximately 25 to 35 mm long and approximately 6 to 8 mm in diameter. The lateral third is cartilage and continuous with the cartilage of the auricle. The medial two-thirds are osseous. It contains cilia and glands that produce wax (ceruminous glands) and oils (sebaceous glands), and these keep the external acoustic meatus clean and supple. These substances also help, in combination with the shape of the tube, to prevent foreign bodies, such as insects, from entering the canal. The resonating frequencies of the tube are such that sensitivity is increased to sounds between approximately 1000 and 6000 Hz.

**Tympanic Membrane, Tympanum, or Eardrum** ([Figure 4-3](#))

The eardrum is a very thin but resilient membrane that vibrates in response to acoustic energy. It sits obliquely at the end of the external acoustic meatus. It is approximately 10 mm in diameter and its shape is almost circular; its thickened outer ring (annulus) attaches to a groove in the tympanic cavity (tympanic sulcus). The normal appearance of the tympanic membrane (e.g., during visual inspection with an otoscope) is concave, smooth, and translucent. An important landmark, the “cone of light,” can normally be seen radiating from a central depression called the *umbo*, which is formed by the attachment of the manubrium of the malleus (a middle ear ossicle). The process of the malleus can be seen extending toward the superior border.

The tympanic membrane has the following three layers:

1. The outer cutaneous layer is a thin layer continuous with the lining of the external acoustic meatus.
2. The middle fibrous layer is more substantial and composed of circular and radial fibers. It is deficient at the superior border, which creates the pars flaccida. The rest of the membrane is the pars tensa.
3. The internal mucous layer is continuous with the lining of the middle ear cavity.

**Coronal oblique section of external acoustic meatus and middle ear (tympenic cavity)****Otoscopic view of right tympanic membrane**

*C. Machado*  
— M.D. —  
*F. Netter*  
— M.D. —

**Figure 4-3.** The external acoustic (auditory) meatus (*top*) and tympanic membrane (*bottom*).



## Middle Ear

**Tympanic Cavity** (Figure 4-4; see also Figures 4-1 [p. 175] and 4-3 [p. 179])

A roughly rectangular air-filled cavity (“box”), the tympanic cavity lies medial to the tympanic membrane within the petrous portion of the temporal bone. It is formed by two cavities: (1) the epitympanic recess and (2) the tympanic cavity proper.

### Epitympanic Recess

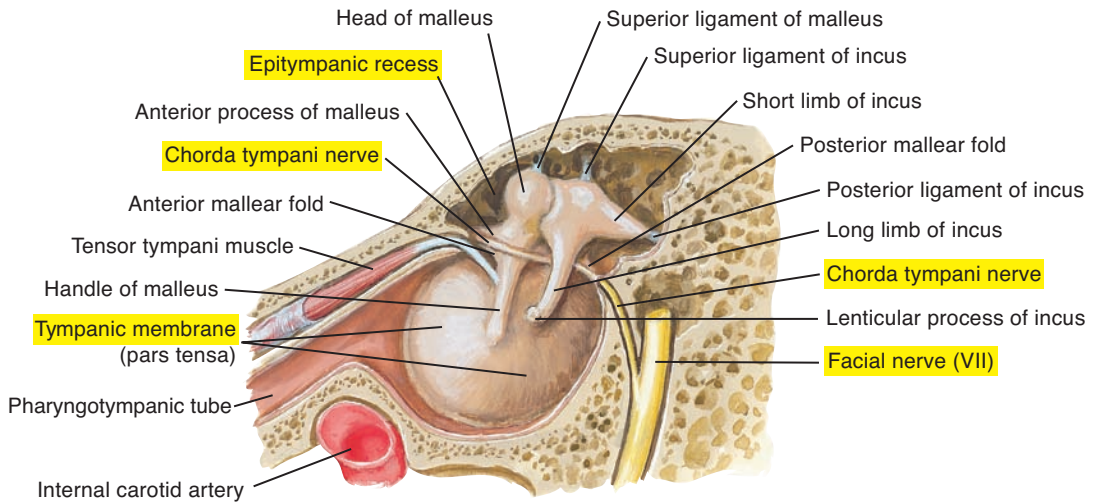
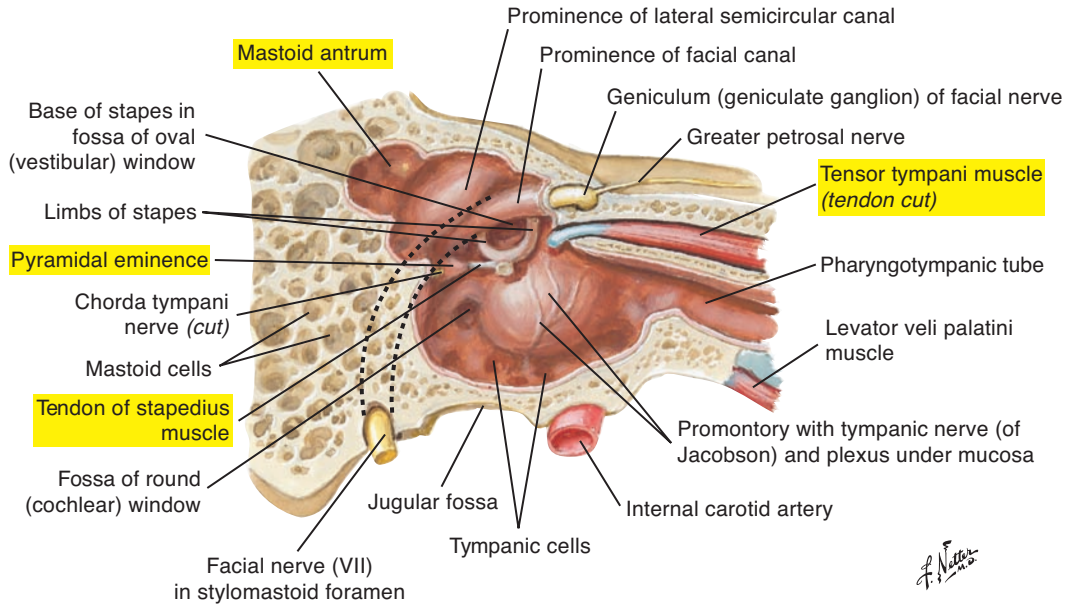
The epitympanic recess is superior to the tympanic membrane. It contains the head of the malleus and most of the incus.

### Tympanic Cavity Proper

The tympanic cavity is the “box” containing the middle ear ossicular system and points of communication with the inner ear and pharyngotympanic tube. The tegmental (superior) wall, or roof, is a thin plate of bone separating the tympanic cavity from the cranium and is called the *tegmen tympani*. The jugular (inferior) wall, or floor, is a thin bone that separates the tympanic cavity from the internal jugular vein. The tympanic nerve, a branch of the glossopharyngeal nerve (cranial nerve IX), passes through the floor of the tympanic cavity.

The membranous (lateral) wall is the tympanic membrane. The labyrinthine (medial) walls are the oval window (fenestra vestibule) and, below, the round window (fenestra rotunda). Superior to the oval window passes the chorda tympani nerve (a branch of the facial [VII] cranial nerve). The carotid (anterior) wall separates the tympanic cavity from the carotid artery. Superiorly, a canal houses the tensor tympani muscle and, more inferiorly, the opening of the pharyngotympanic tube connects the tympanic cavity to the nasopharynx (see later).

The mastoid (posterior) wall on the posterosuperior border is the mastoid antrum, a sinus with several openings to the mastoid air cells. It provides a path of direct communication between air cells and the tympanic cavity, as well as a potential path for the life-threatening infection mastoiditis. Inferior to this is the pyramidal eminence, the point of emergence of the tendon of the stapedial muscle. Lateral to this is the chordal eminence, the point of emergence of the chorda tympani nerve into the tympanic cavity.

**Lateral wall of tympanic cavity: medial (internal) view****Medial wall of tympanic cavity: lateral view****Figure 4-4.** The tympanic cavity.

**Middle Ear Ossicles** (Figure 4-5; see also Figure 4-4 [p. 181])

The tympanic cavity proper houses the middle ear ossicles and their supporting ligaments and muscles. This system transmits acoustic vibrations from the tympanic membrane to the inner ear. Cartilaginous synovial joints connect the three ossicles.

**Malleus (“Hammer”)**

The malleus, or “hammer,” is the largest (but still only 9 mm long) and most lateral of the middle ear ossicles. It is suspended in the tympanic cavity by three ligaments; the most significant is the anterior ligament of the malleus. The manubrium (handle) is attached to the tympanic membrane. The tendon of the tensor tympani muscle (see later) attaches to the upper portion of the manubrium.

**Incus (“Anvil”)**

The incus, or “anvil,” articulates medially with the malleus and through an inferior projection (that terminates in the lenticular process) with the stapes. It is suspended from the tympanic cavity by the posterior ligament of the incus.

**Stapes (“Stirrup”)**

The stapes, or “stirrup,” is the smallest bone in the human body. Its footplate attaches to the oval window of the cochlea by the annular ligament. The tendon of the stapedial muscle is attached to the neck of the stapes.

**Middle Ear Muscles** (see Figure 4-5; see also Figure 4-4 [p. 181])**Tensor Tympani**

The tensor tympani is a muscle contained within a bony canal above and running along the pharyngotympanic tube. Its tendon enters the tympanic cavity and attaches to the manubrium of the malleus near the tympanic membrane.

The tensor tympani is innervated by a branch of the mandibular division of the trigeminal nerve (cranial nerve V).

**Stapedial Muscle or Stapedius**

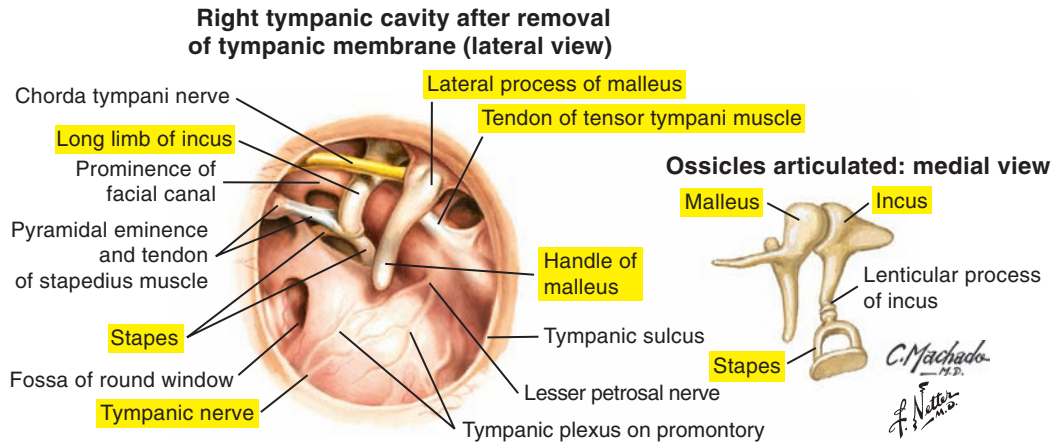
The stapedius is the smallest striated muscle in the body. Its tendon emerges from the pyramidal eminence to insert on the posterior surface of the neck of the stapes.

The stapedial muscle is innervated by the nerve to stapedius of the facial nerve (cranial nerve VII).

**Action of the Middle Ear Muscles**

Muscular contraction increases the stiffness of the ossicular chain. Reflex activation may provide some sound protection benefits against intense, low-frequency sounds (below 1 to 2 kHz). Protection against rapid-onset sounds is minimal because of reflex delays (approximately 60 to 120 ms). Activation may reduce sensitivity to self-generated vocalizations transmitted to the cochlea via bone conduction.

The acoustic reflex (AR) activation of the middle ear muscles is a diagnostic tool used in the practice of audiology to assess the function of middle ear and higher-order neural processes involved in hearing.



**Figure 4-5.** The middle ear ossicles.

**Pharyngotympanic (Auditory, Eustachian) Tube** (Figure 4-6; see also Figure 4-4 [p. 181])

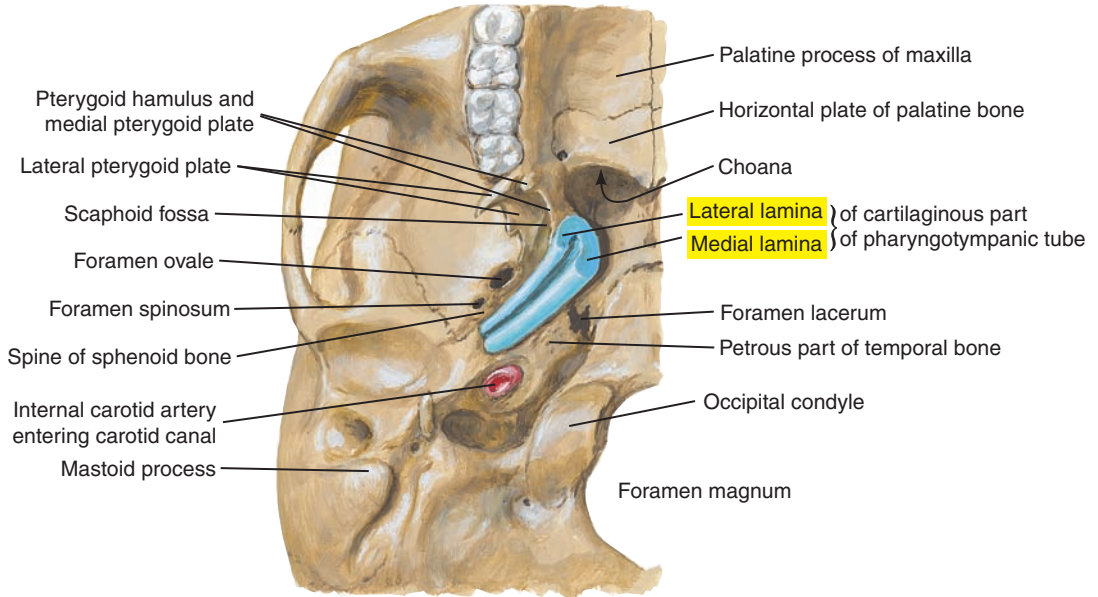
The pharyngotympanic tube is approximately 35 to 38 mm long and extends downward, forward, and medially from the tympanic cavity to the nasopharynx. The lateral portion is osseous, and the medial portion is composed of cartilage and other connective tissue. The pharyngotympanic tube is normally closed by elastic recoil forces (and potentially by tension provided by muscles such as the salpingopharyngeus) to protect the middle ear from pathogens.

The tube opens during swallowing and yawning, principally by action of the tensor veli palatini with potential contributions from the levator veli palatini and tensor tympani muscles. It equalizes pressure between the middle ear and external atmospheric pressure and allows the tympanic membrane to operate efficiently in a variety of atmospheric pressures. This tube also drains the middle ear cavity and aerates tissues. The pharyngotympanic tube is shorter and more horizontally placed in children and thus provides a more direct path for middle ear infections such as otitis media.

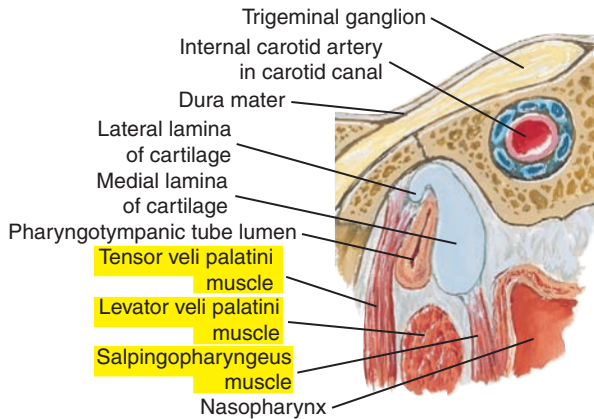


## Pharyngotympanic Tube

### Cartilaginous part of pharyngotympanic tube at base of skull: inferior view

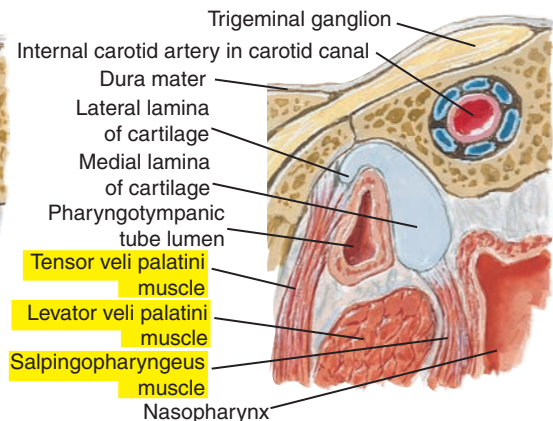


### Section through cartilaginous part of pharyngotympanic tube, with tube closed



Pharyngotympanic tube closed by elastic recoil of cartilage, tissue turgidity, and tension of salpingopharyngeus muscles.

### Section through cartilaginous part of pharyngotympanic tube, with tube open



Lumen opened chiefly when attachment of tensor veli palatini muscle pulls wall of tube laterally during swallowing.



**Figure 4-6.** The pharyngotympanic (auditory, eustachian) tube.

## Inner Ear: Cochlea and Vestibular System

The inner ear is composed of the organs of hearing and equilibrium. There are two labyrinthine (“mazelike”) systems: (1) the bony (osseous) outer labyrinth and (2) the internal membranous labyrinth.

**Osseous or Bony Labyrinth** (Figures 4-7, 4-8 [p. 188], and 4-9 [p. 189]; see also Figures 4-1 [p. 175])

The bony labyrinth is composed of a series of ducts and cavities within the petrous portion of the temporal bone. It contains the vestibule, the semicircular canals, and the coiled cochlea and is composed of tissue denser than the surrounding temporal bone. Imagine pouring wax into the bony labyrinth and chipping away the “mold” to reveal the harder bony “cast” of the cochlea.

### Semicircular Canals

The semicircular canals are the lateral-most portion of the bony labyrinth. Superior, posterior, and lateral canals are oriented approximately orthogonally. They are involved in balance and body orientation.

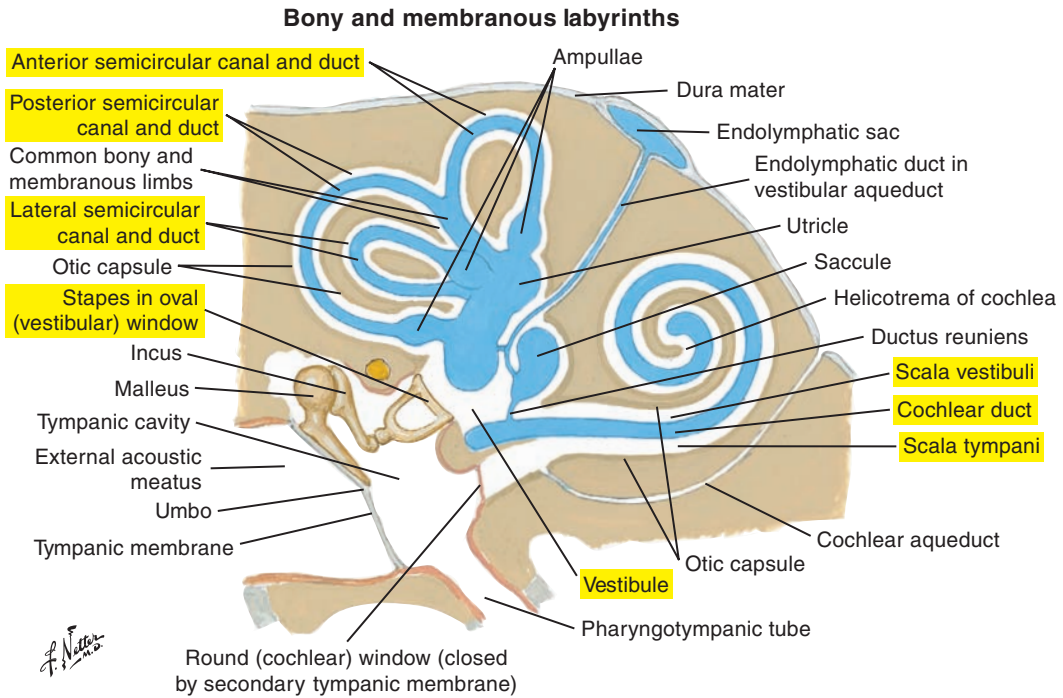
### Vestibule

The vestibule is interposed between the cochlea and the semicircular canals. The oval window is the entrance to the cochlea and point of attachment of the footplate of the stapes.

### Cochlea

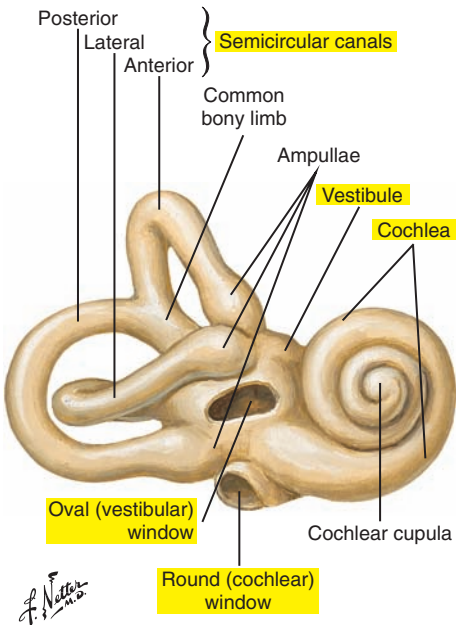
The cochlea is the medial-most portion of the bony labyrinth. This cavity is approximately 35 mm long and coiled around a central core of bone called the *modiolus*. It is approximately  $2\frac{3}{4}$  turns from the base (basal turn) to the apex.

Small perforations in the modiolus and projecting shelf (osseous spiral lamina) allow passage of auditory nerve fibers that innervate the sensory end organs of hearing. The round window has a membranous covering that provides a point of expansion for fluid movements within the cochlea.

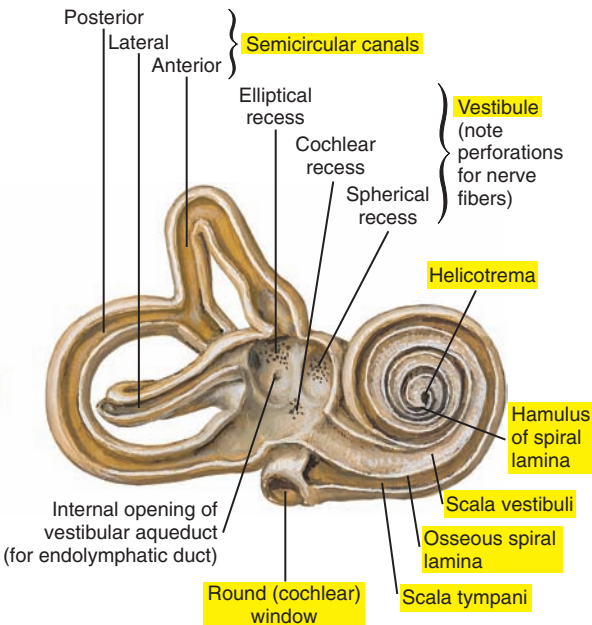


**Figure 4-7.** Schema of the bony and membranous labyrinths of the inner ear.

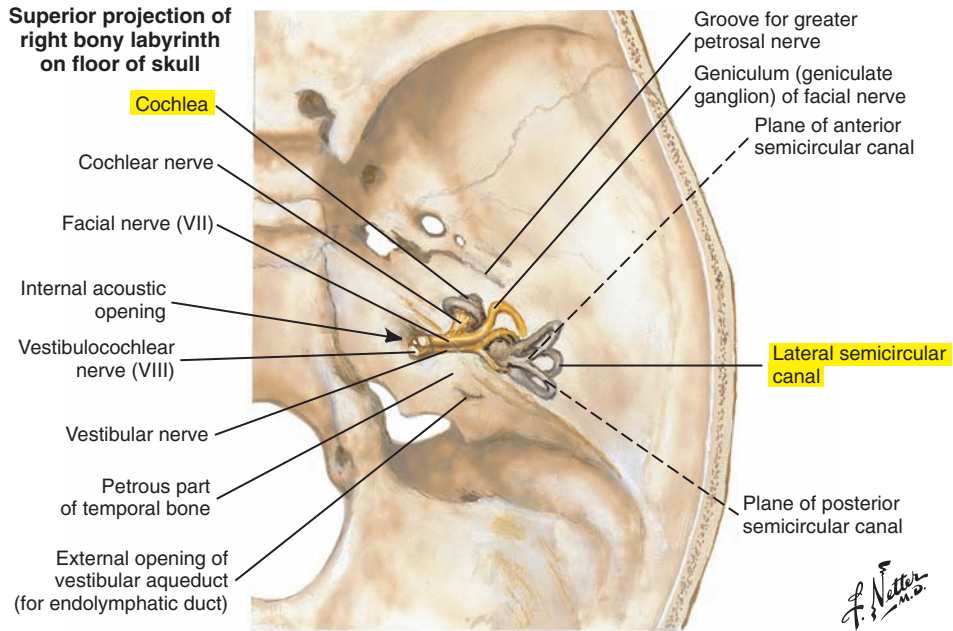
**Right bony labyrinth (otic capsule), anterolateral view: surrounding cancellous bone removed**



**Dissected right bony labyrinth (otic capsule): membranous labyrinth removed**



**Figure 4-8.** The right bony labyrinth of the inner ear.



**Figure 4-9.** Orientation of the bony labyrinth in the skull.

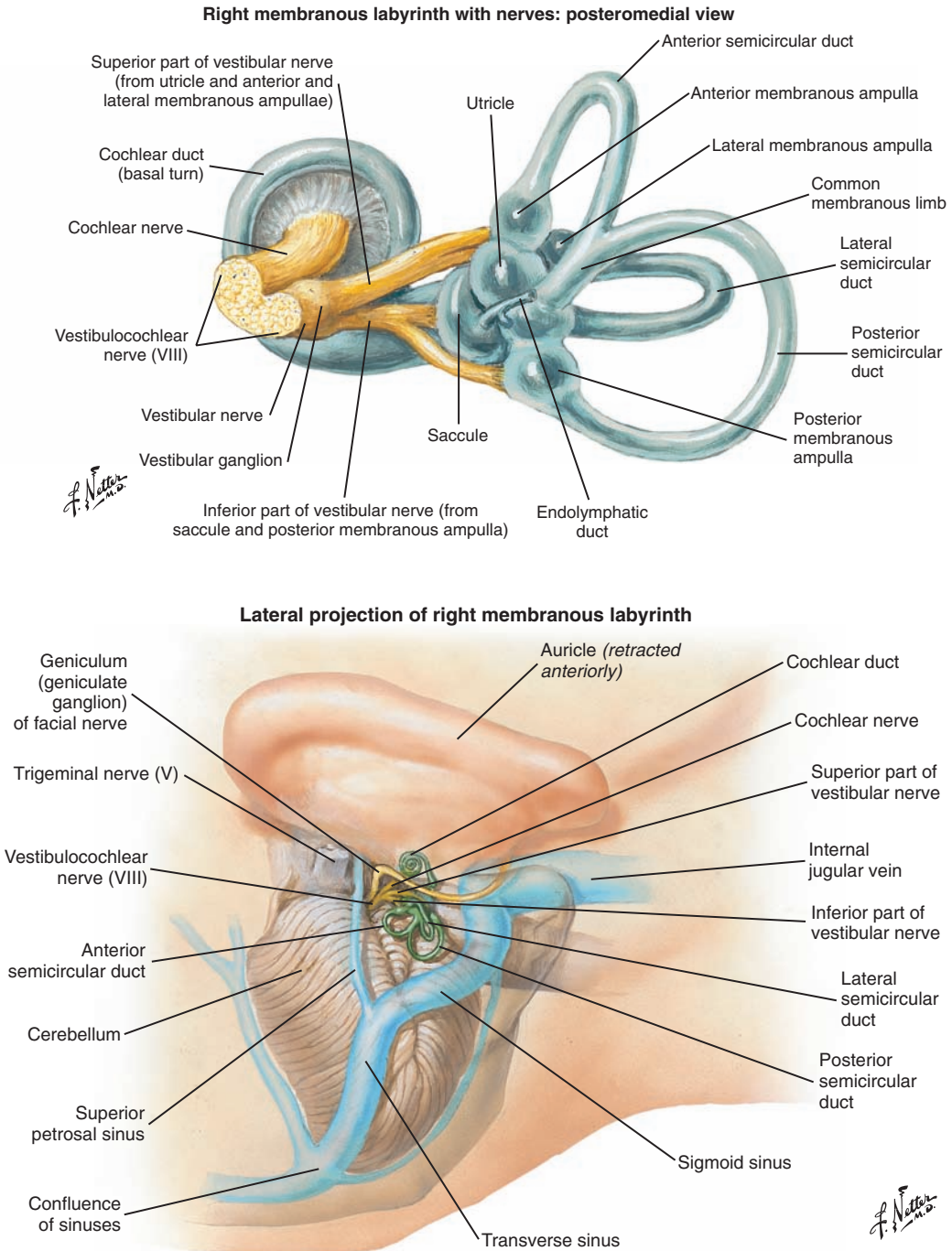


**Membranous Labyrinth** (Figures 4-10 and 4-11 [p.194]; see also Figure 4-7 [p. 187])

The membranous labyrinth is suspended within the osseous labyrinth and composed of the membranous semicircular canals, vestibule, and cochlea. Details are provided for the membranous cochlea.

**Membranous Cochlear Labyrinth**

The membranous cochlear labyrinth is a spirally arranged tube approximately 33 mm long and suspended in the osseous cochlea. The cochlear labyrinth includes three canals. The scala vestibuli is the only canal in direct contact with the vestibule (thus its name). The scala media, or cochlear duct, is enclosed between the scala vestibuli and scala tympani and contains the sensory end organ of hearing, the organ of Corti. The scala media contains endolymph, and the scala vestibuli and scala tympani contain perilymph. The cochlear labyrinth includes three canals. The scala vestibuli is the only canal in direct contact with the vestibule (thus its name). The scala media, or cochlear duct, is enclosed between the scala vestibuli and scala tympani and contains the sensory end organ of hearing, the organ of Corti. The scala media contains endolymph, and the scala vestibuli and scala tympani contain perilymph.



**Figure 4-10.** The membranous labyrinth of the inner ear and its orientation in the skull.

### Scala Media, or Cochlear Duct

The scala media is formed by the following two membranes:

1. Reissner's membrane
2. Basilar membrane

#### **Reissner's Membrane** (Figures 4-11 [p. 194] and 4-12 [p. 195])

Reissner's membrane extends obliquely from the osseous spiral lamina to the outer bony wall and above the basilar membrane. It joins the basilar membrane at the helicotrema at the apex of the cochlea. This membrane divides the scala vestibuli from the scala media.

#### **Basilar Membrane** (Figures 4-11 [p. 194] and 4-12 [p. 195])

The basilar membrane projects from the osseous spiral lamina and connects with the outer wall of the osseous cochlea via the spiral ligament. It divides the scala media from scala tympani. Although the cross-sectional area of the bony labyrinth, or canal, becomes smaller as the apex is reached, the basilar membrane becomes wider. Thus the basilar membrane is wider and more flaccid at the apical end and narrower and stiffer at the base, and this influences its resonant properties and frequency-response characteristics. Sitting on the basilar membrane is the organ of Corti, which contains hair cells (sensory cells) and supporting cells.

**Organ of Corti**

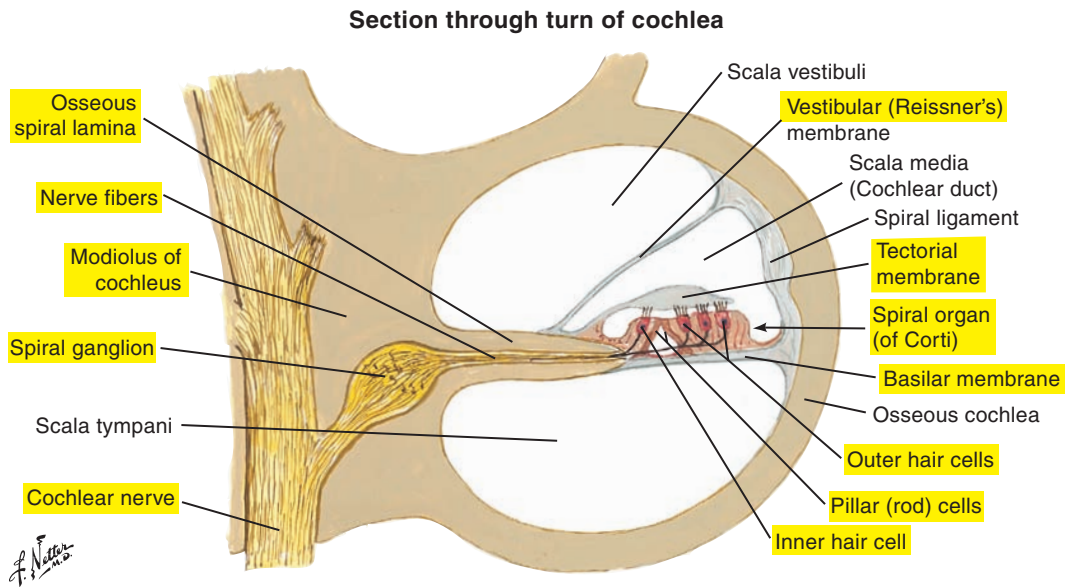
The organ of Corti contains sensory (hair) cells and supporting cells.

**Inner Hair Cells.** One row of approximately 3500 hair cells lies along the length of the cochlea on the inner side of the tunnel of Corti. Approximately 40 stereocilia (ciliated tops of the hair cells) on each cell are arranged in parallel rows of decreasing height toward the modiolus.

**Outer Hair Cells.** Three to five rows of approximately 12,000 cells are present. Approximately 150 stereocilia per hair cell are arranged in the form of a V or W, with the base of the letter pointing toward the spiral ligament and with decreasing height toward the modiolus side.

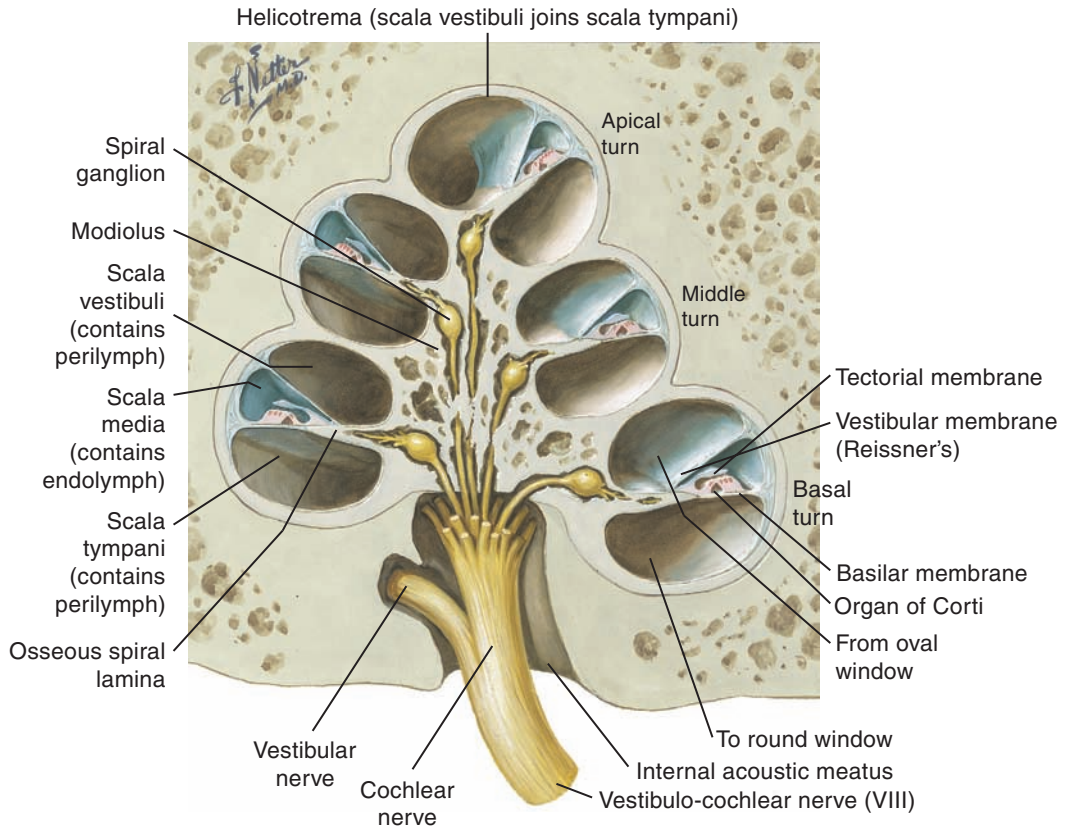
**Tectorial Membrane.** The tectorial membrane is semitransparent and gelatinous-like. Tips of the tallest row of outer hair cell stereocilia are in contact with the tectorial membrane, which extends over hair cells from the spiral limbus.

**Supporting Cells.** Hair cells and their stereocilia are held in place by several supporting cells, including the inner and outer pillars or rods of Corti (forming the inner tunnel of Corti) and the inner and outer phalangeal cells. A delicate reticular lamina holds the tops of the hair cells in place and allows for shearing forces on the stereocilia by the tectorial membrane.



**Figure 4-11.** Cross-section through a turn of the cochlea.





**Figure 4-12.** Cross-section of the entire cochlea. Note the scala media and cochlear nerve fibers.

## ■ COCHLEAR AFFERENT AND EFFERENT INNERVATION

---

### **Afferent Innervation**

The cochlea is innervated by more than 30,000 sensory neurons. These eighth cranial nerve afferents convey information from the cochlea to the central nervous system. Bipolar cells have their cell bodies in the spiral ganglion in the modiolus and send one process to synapse on the hair cells and a longer process (axon) to the cochlear nuclei.

The process innervating the hair cells passes underneath the cells through openings in the spiral lamina called *habenula perforata*. There are two types of cochlear afferents, as follows:

1. Inner radial, or type I, fibers
2. Outer spiral, or type II, fibers

### ***Inner Radial, or Type I, Fibers***

The inner radial, or type I, fibers represent 90% to 95% of all afferents and innervate the inner hair cells exclusively. Each inner radial cell goes to 1 inner hair cell, but each inner hair cell receives approximately 20 inner radial fibers; this is referred to as *many to one innervation*. These fibers are called radial fibers because they fan out in a radial direction.

### ***Outer Spiral, or Type II, Fibers***

The outer spiral, or type II, fibers cross the inner tunnel of Corti and “spiral” (run longitudinally) to synapse on multiple outer hair cells. One outer spiral cell goes to many (approximately 10) outer hair cells (*one to many innervation*).

**Afferent Central Auditory Pathway** (Figures 4-13 [p. 198] and 4-14 [p. 199])

Afferent nerve fibers (axons) carrying sensory information from the cochlea and the semicircular canals together form the vestibulocochlear (or auditory) nerve (cranial nerve VIII). This nerve travels through the internal acoustic meatus to enter the brainstem at the junction of the pons and medulla. Auditory nerve fibers from the cochlea first synapse onto their respective cochlear nuclei (dorsal or ventral) located at the pontomedullary junction. These are referred to as *primary* or *first-order fibers*.

Beyond this lies the central auditory pathway. Fiber pathways or tracts made up of communicating axons from each ear travel ipsilaterally (on the same side) and contralaterally (on the opposite side) to higher levels of the nervous system, thus ensuring a redundancy of auditory information in the event of disease or damage.

Along the way, auditory sensory information is relayed or processed by a series of brainstem nuclei (collections of nerve cell bodies). The auditory brainstem nuclei include the superior olivary complex (in the pons), the inferior colliculus (in the midbrain), the lateral lemniscus (in the pons), and the medial geniculate body or nucleus (thalamic auditory relay nuclei). From there, fibers are distributed (auditory radiations) to the primary auditory cortex located on the transverse temporal gyrus (Heschl's gyrus) on the superior surface of the temporal lobe of each hemisphere.

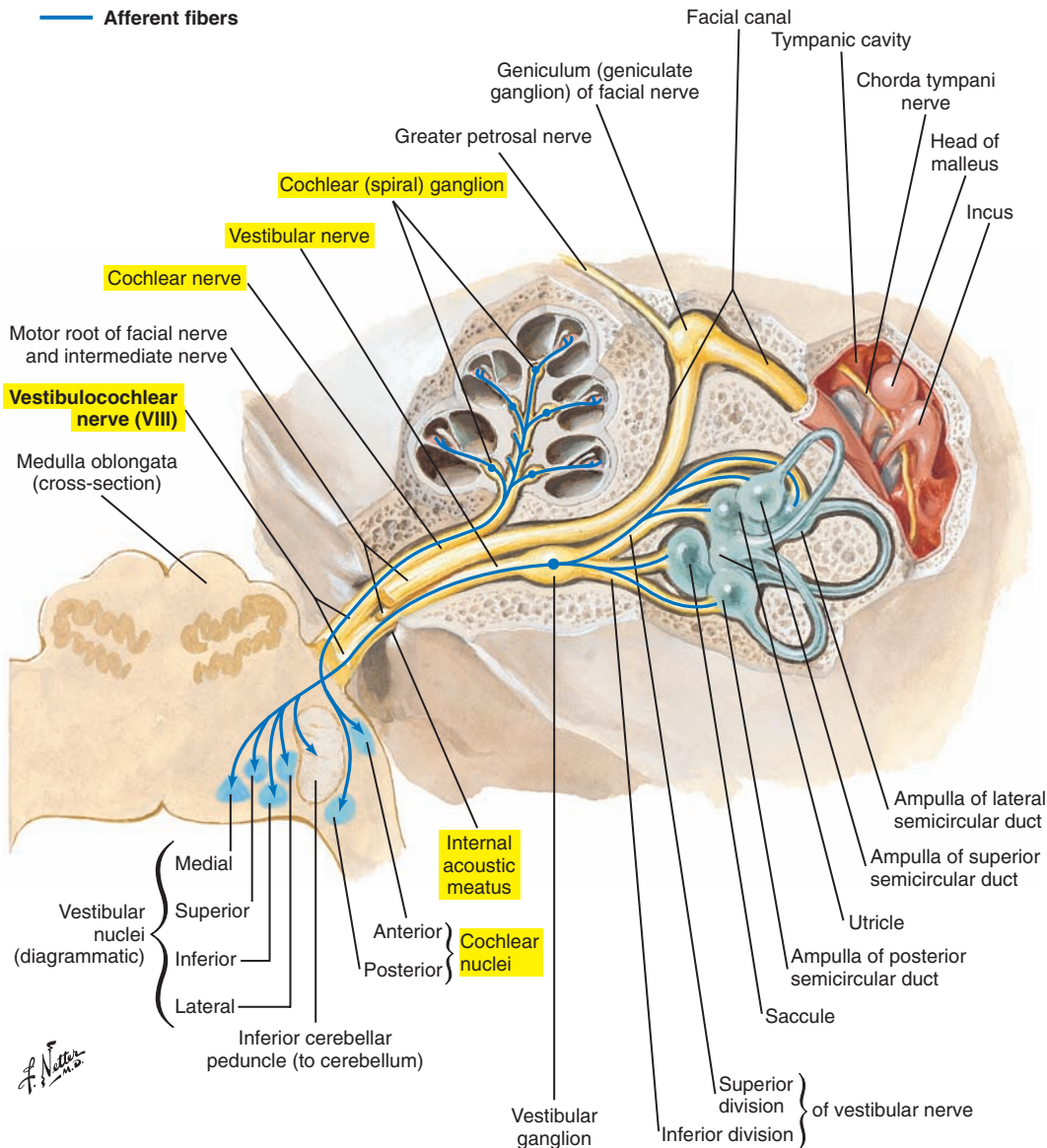


Figure 4-13. The vestibulocochlear nerve (cranial nerve VIII).

Afferent Auditory Pathways

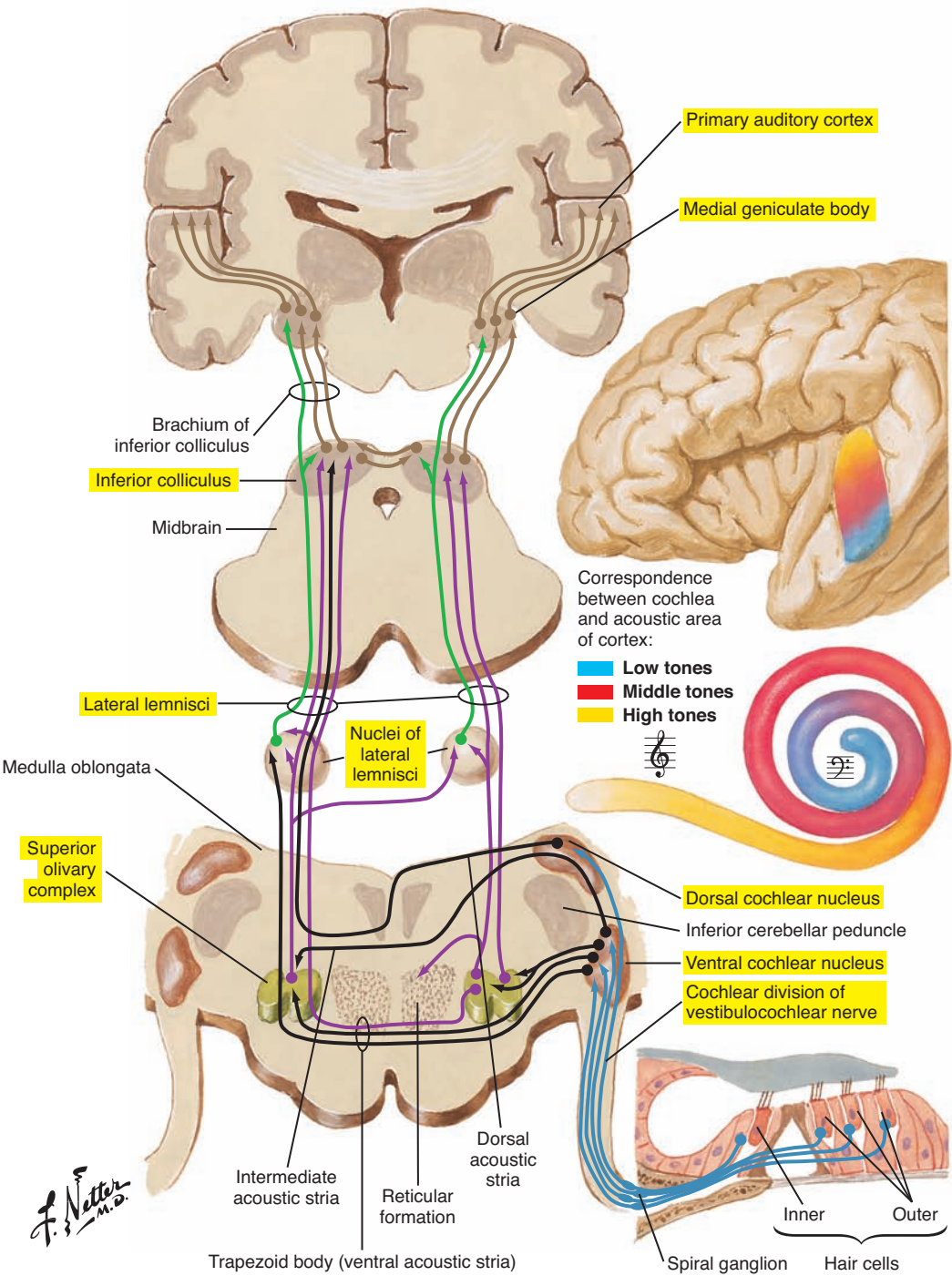


Figure 4-14. Afferent auditory pathways.

**Efferent Central Auditory Pathway (Auditory Centrifugal Pathway)**

A descending efferent pathway extends from the auditory cortex to the hair cells and affects the processing stages (nuclei) of the ascending system as previously described.

The most well-understood part of the efferent pathway is the olivocochlear bundle, which runs from the superior olivary complex back to the hair cells in the cochlea.

Medial olivocochlear bundle fibers innervate mainly outer hair cells and synapse directly on the base of the cell. This pathway may directly modulate the active process in the cochlea to sharpen perception and enhance auditory sensitivity to soft sounds.

Lateral olivocochlear bundle fibers innervate primarily inner cells and synapse on the afferent fibers rather than directly on the cell. The action of this pathway is not yet well understood.



# NERVOUS SYSTEM

## Overview, 203

## Neuroanatomical Terms of Direction, 204

## Telencephalon (Cerebral Hemispheres or Cerebrum and Basal Ganglia), 205

Surface Structures, 205

Internal Structures of the Cerebral

Hemispheres, 212

**Basal Ganglia, 212**

## Diencephalon (Thalamus, Hypothalamus, Epithalamus, and Subthalamus), 214

Characteristic Features, 214

**Importance for Speech and Swallowing, 214**

## Mesencephalon (Midbrain), 215

Characteristic Features, 215

**Importance for Speech and Swallowing, 215**

## Metencephalon (Pons and Cerebellum), 216

Characteristic Features, 216

**Importance for Speech and Swallowing, 216**

## Myelencephalon (Medulla Oblongata), 216

Characteristic Features, 216

Importance for Speech and Swallowing, 216

**Brainstem Pattern-Generating Circuitry, 216**

## Spinal Cord, 218

Characteristic Features, 218

**Internal Structures, 218**

## Cerebellum, 220

Meninges, 224

Dura Mater, 224

Arachnoid Mater, 224

**Pia Mater, 224**

## Cerebrospinal Fluid, 226

## Cerebral Vasculature, 229

## Cranial Nerves, 234

Types of Cranial Nerve Fibers, 236

I Olfactory (Sensory), 238

II Optic (Sensory), 238

III Oculomotor (Motor), 239

IV Trochlear (Motor), 239

V Trigeminal (Motor and Sensory), 240

VI Abducens (Motor), 242

VII Facial (Motor and Sensory), 242

VIII Vestibulocochlear (Sensory), 244

IX Glossopharyngeal (Motor and Sensory), 246

X Vagus, or Pneumogastric, Nerve (Motor and Sensory), 248

XI Spinal Accessory (Motor), 250

XII Hypoglossal (Motor), 252

This page intentionally left blank

## OVERVIEW

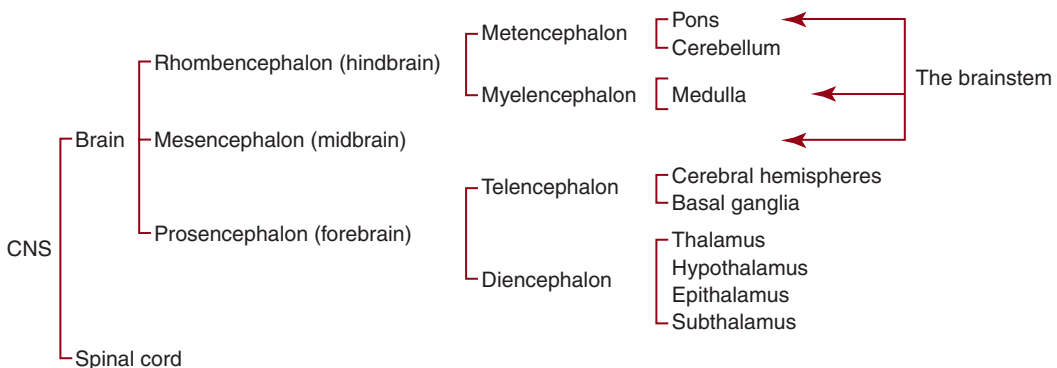
Speech production is an extremely complex sensorimotor behavior involving the coordinated action of numerous muscles distributed across several physiological systems, including the respiratory system, the laryngeal-phonatory system, and the oropharyngeal-articulatory system. Multiple control mechanisms are involved in the regulation of this complex system, including a higher-order motor control system, cognitive and linguistic components interacting with brainstem and cerebellum control systems, and a feedback-feedforward control system, which processes sensorimotor information arising from various sources.

Respiratory, laryngeal, and oropharyngeal structures are also involved in deglutition. Deglutition is important for both the transportation of food and saliva and the protection of the respiratory tract during wakefulness and sleep. Like speech production, deglutition is a complex behavior that involves several levels of neural control, including central pattern-generating circuitry interacting with sensory feedback and cortical control elements. Speech and deglutition appear to share common control elements.

The nervous system is divided into two parts: the central nervous system (brain and spinal cord) and the peripheral nervous system (spinal and cranial nerves). This chapter first examines the structures of the central nervous system and then examines the cranial nerves because of their importance to speech, hearing, and feeding.

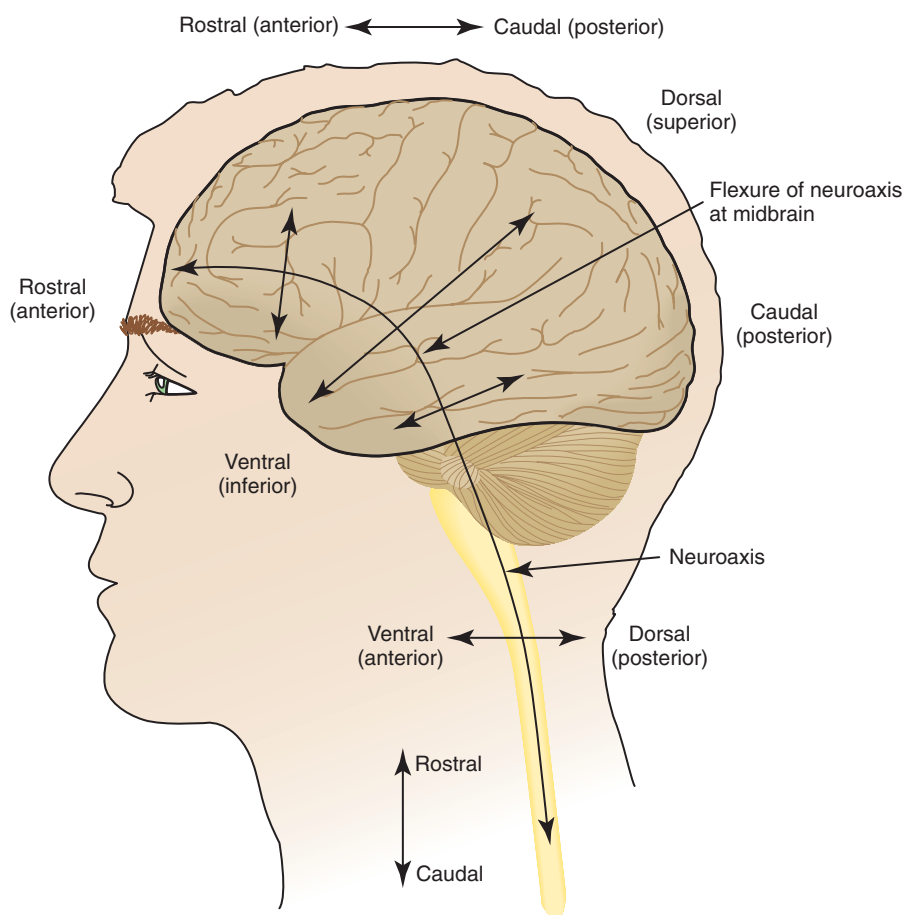
The brain develops from three primary structures: the rhombencephalon (or hindbrain), the mesencephalon (or midbrain), and the prosencephalon (or forebrain). The rhombencephalon in turn divides into the metencephalon (pons and cerebellum) and the myelencephalon (medulla). The prosencephalon divides into the telencephalon (cerebral hemispheres and basal ganglia) and the diencephalon (thalamus, hypothalamus, epithalamus, and subthalamus). The pons, medulla, and midbrain collectively form the *brainstem*.

**Developmental and Anatomical Divisions of the Central Nervous System (CNS)**



## ■ NEUROANATOMICAL TERMS OF DIRECTION (Figure 5-1)

When describing the location of structures in the brain, it is important to recognize that the neuroaxis flexes at the level of the midbrain during development. Thus, when speaking of the upper portions of the brainstem (above the diencephalon) and the cerebral hemispheres, *rostral* (or anterior) refers to the front of the brain and *caudal* (or posterior) refers to the back. *Dorsal* (or superior) is toward the top of the brain and *ventral* (or inferior) is away from the top. Because of the superior-inferior orientation of the spinal cord and the lower portions of the brainstem, the terms of direction described in the Introduction to this book apply.



**Figure 5-1.** Neuroanatomical terms of direction.

■ **TELENCEPHALON (CEREBRAL HEMISPHERES OR CEREBRUM AND BASAL GANGLIA)** (Figure 5-2 [p. 208], 5-3 [p. 209], 5-4 [p. 210], 5-5 [p. 211], and 5-6 [p. 213])

---

## Surface Structures

### Characteristic Features

The telencephalon is composed of the two cerebral hemispheres separated by the longitudinal fissure (see [Figure 5-4](#) [p. 210]). Each hemisphere is composed of numerous irregular gyri (convolutions) separated by sulci (or fissures). The cerebral hemispheres are made up of gray matter (cell bodies) and white matter (nerve fiber axons). White matter fiber tracts are categorized as to whether they project to other brain areas (projection fibers), connect different areas within a cerebral hemisphere (association fibers), or join the two cerebral hemispheres (commissural fibers).

The cerebral cortex is the external, thin layer of gray matter capping the white matter core of the cerebral hemispheres. The cortex is stratified into six cellular layers (numbered from I to VI, starting from the most superficial layer). The laminar organization of the cortex into layers varies from region to region and reflects functional differences.

The organization of the cortical motor areas (i.e., the primary motor area, the supplementary motor area, and the lateral premotor cortex) is characterized by poor layering, such as the absence of layer IV, which contains granular cells, and the presence in layer V of giant pyramidal cells called *Betz cells*. The organization of the motor areas is referred to as *agranular*. The nonprimary motor areas (the supplementary motor area and the lateral premotor cortex) contain fewer Betz cells than the primary motor areas. The pyramidal cells contribute to two important motor pathways: (1) the corticobulbar tracts projecting to the brainstem and cranial motoneurons and (2) the corticospinal tracts projecting to the spinal cord and spinal motoneurons. The neurons whose axons form these descending pathways are sometimes called *upper motoneurons*, whereas the cranial or spinal motoneurons they innervate are sometimes called *lower motoneurons*. Although there are other motor pathways, the corticobulbar and corticospinal tracts have privileged access to the motoneurons of the brainstem and spinal cord, respectively.

The primary sensory areas, located just caudal to the primary motor area, have an internal organization that is referred to as *granular*. Layering of these areas is also poor but different from the layering of the agranular (motor) areas. Granular areas contain few pyramidal cells and a large number of another type of neuron called *stellar cells*. Primary sensory areas process sensory feedback, including information related to speech, swallowing, and other movements.

**Important Sulci**

The telencephalon contains the following significant sulci:

- The longitudinal fissure is also referred to as the *sagittal fissure* or *longitudinal cerebral fissure*.
- The lateral sulcus is located on the lateral surface and is also known as the *sylvian fissure* or *fissure of Sylvius* (see [Figure 5-3](#) [p. 209]).
- The central sulcus is located on the lateral surface and is also known as the *rolandic fissure* or *fissure of Rolando* (see [Figure 5-3](#) [p. 209]).
- The parietooccipital sulcus is located on the medial surface (see [Figure 5-2](#) [p. 208]).
- The calcarine sulcus is located on the posteromedial surface (see [Figure 5-2](#) [p. 208] and [5-4](#) [p. 210]).

**Cerebral Lobes**

The sulci are important landmarks to locate the cerebral lobes. Each hemisphere contains the following four lobes (see [Figure 5-3](#) [p. 209]):

1. The frontal lobe is located rostral to the central sulcus and dorsal to the lateral sulcus.
2. The parietal lobe is caudal to the central sulcus. Its caudal limit is an imaginary extension on the lateral surface of the parietooccipital sulcus. The inferior limit is a posterior extension of the sylvian sulcus.
3. The occipital lobe is caudal to the posterior boundary of the parietal lobe, which is an extension of the parietooccipital sulcus.
4. The temporal lobe is inferior to the frontal and parietal lobes and rostral to the occipital lobe.



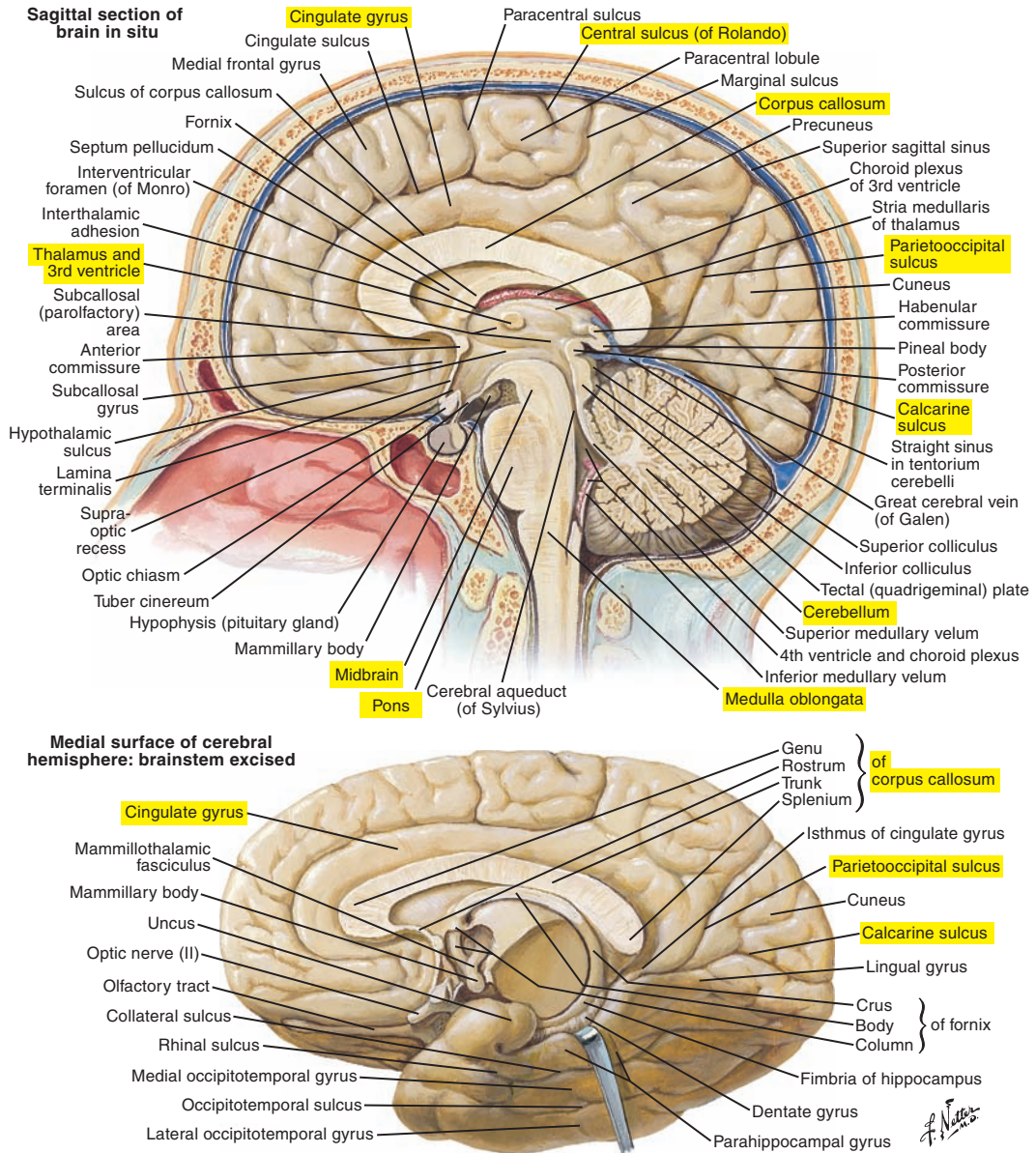
### Internal Surface

The third ventricle is part of the ventricular system, which is a series of ducts that are involved in the production and circulation of cerebrospinal fluid. The corpus callosum (see [Figure 5-6](#) [p. 213]) is composed of a collection of axons connecting the two hemispheres. The cingulate gyrus (or cingulum) is located above the corpus callosum (see [Figure 5-2](#) [p. 208]). The cingulate gyrus contains a number of anatomically and functionally distinct areas. The cingulate gyrus divides at the level of the anterior commissure into a caudal and a rostral (agranular) region; the latter is involved in movement preparation. Both regions (rostral and caudal) further divide into several functionally distinct areas.

### External Surface

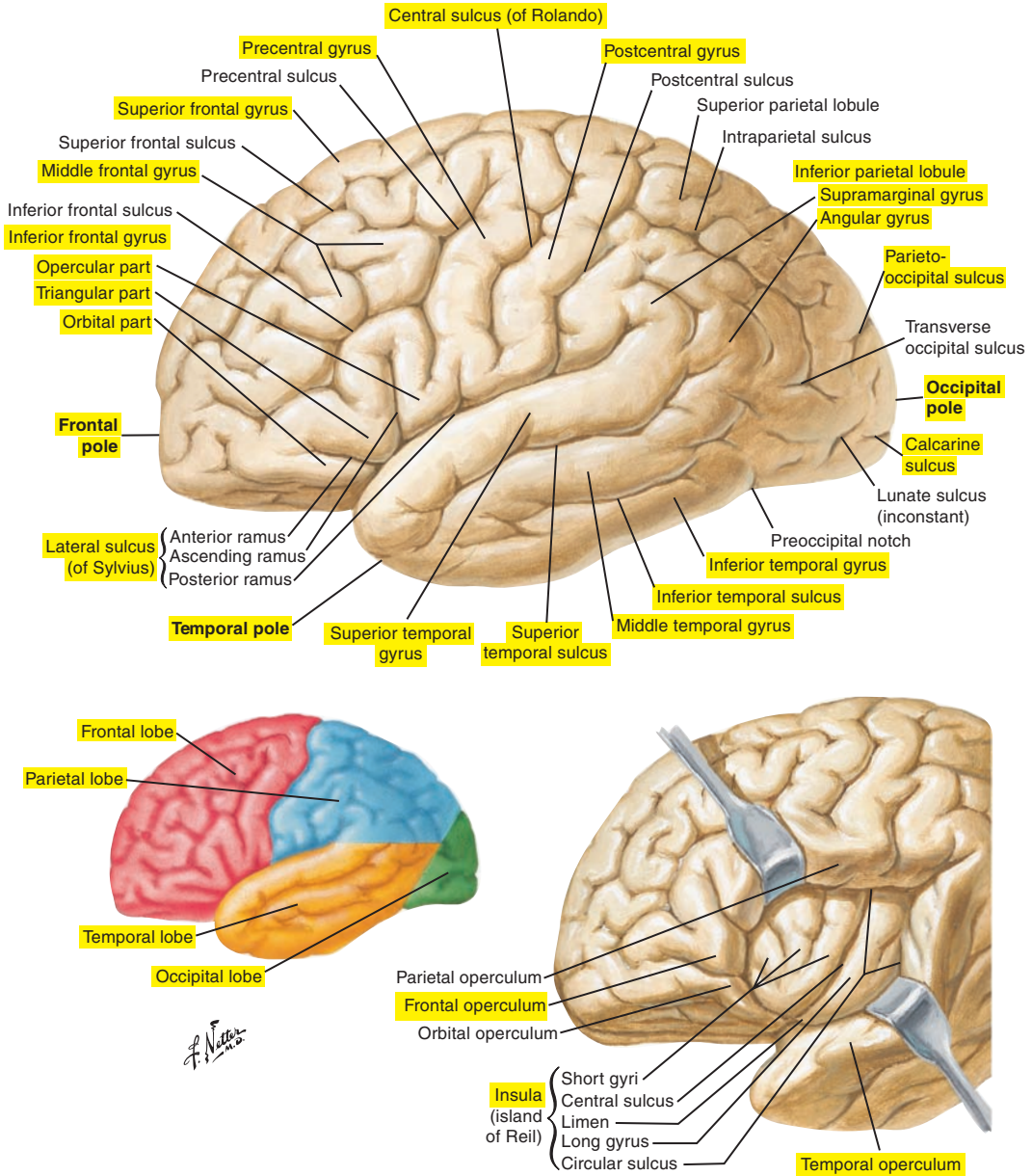
The following structures can be identified on the frontal lobe (see [Figure 5-3](#) [p. 209]):

- The medial segment of the superior frontal gyrus contains two important motor (agranular) areas that are collectively referred to as the supplementary motor complex: (1) the supplementary motor area proper and (2) a more rostral pre-supplementary motor area. These areas are somatotopically organized and are involved in the production of speech, swallowing, and other movements, especially for the selection, preparation, and initiation as well as the temporal sequencing of movement components.
- The caudal portion of the precentral gyrus is adjacent to the central sulcus and runs from the lateral sulcus to the mediosuperior surface of the frontal lobe. It contains the agranular primary motor cortex or area. The primary motor cortex is somatotopically organized with body parts often represented by a distorted body topographical map called a *homunculus*. The face, larynx, and pharynx have a large representation on the inferior portion of the gyrus (see [Figure 5-5](#) [p. 211]), reflecting the precision requirements of movements of these structures for speech and feeding/swallowing (and other orofacial movements).
- The anterior portion of the precentral gyrus, near the precentral sulcus, contains the premotor cortex (lateral premotor cortex). The premotor cortex divides into a ventral and a dorsal segment, approximately at the level of the inferior frontal sulcus. Both the ventral and the dorsal premotor area further divide into functionally distinct regions. The premotor cortex is involved in speech (both in production and in perception), swallowing, and other motor behaviors, particularly for the sensorimotor planning of movements, as well as more cognitive aspects of movement preparation such as response selection.
- The inferior frontal gyrus divides into a ventral orbital area (pars orbitalis), a triangular area (pars triangularis), and a caudal opercular area (pars opercularis). The opercular and triangular regions in the left hemisphere are collectively referred to as *Broca's area* and are involved in the planning and articulation of speech (opercular), as well as for language comprehension, including semantics and syntax (triangular). Brain imaging has revealed swallowing-related activity in Broca's area.



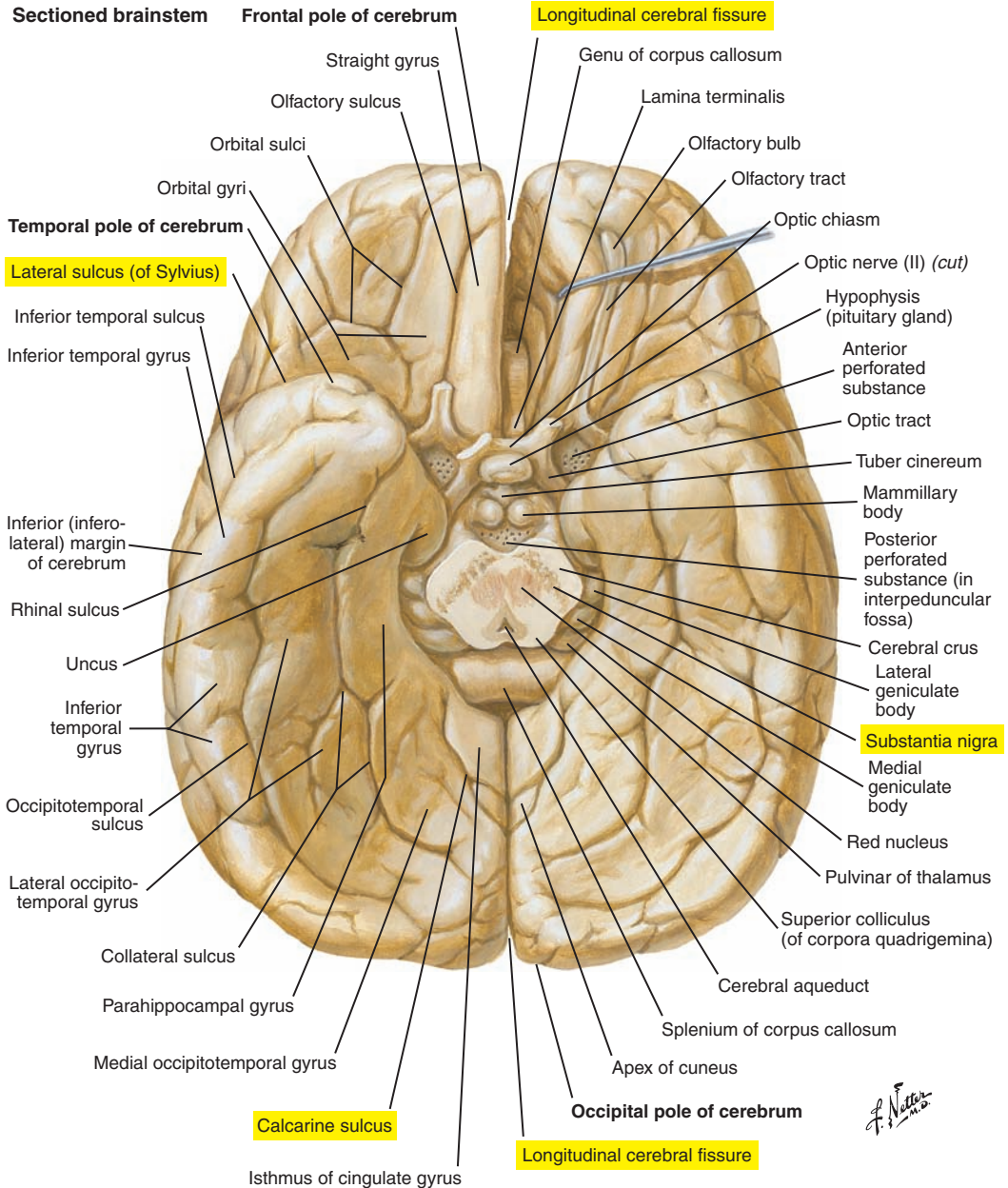
**Figure 5-2.** Medial views of the cerebrum.

Note: Labels of certain figures are highlighted in yellow to emphasize the related elements in the corresponding text.

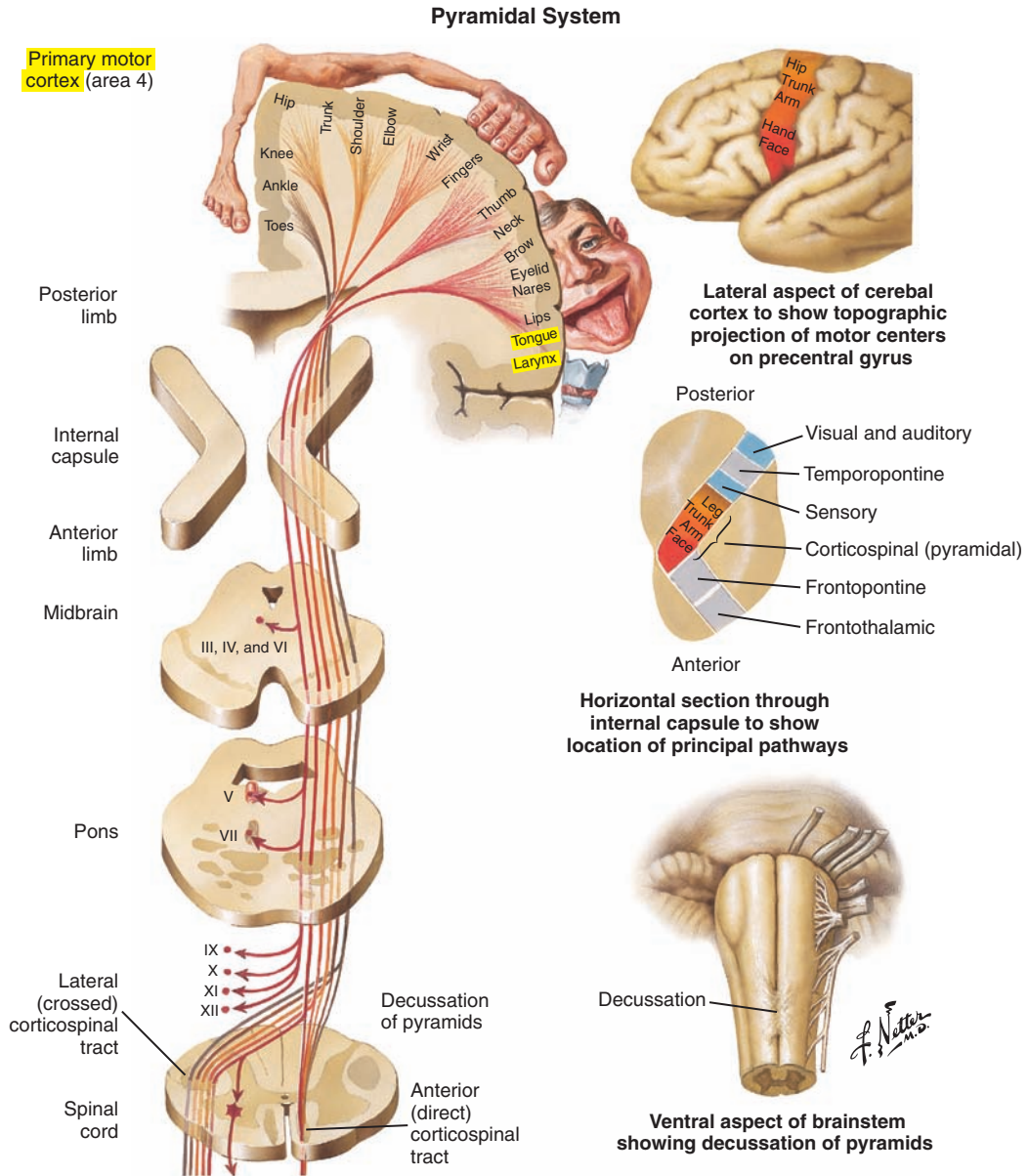


**Figure 5-3.** Lateral views of the cerebrum. Note the lobes of the cerebral hemispheres.





**Figure 5-4.** Inferior view of the cerebrum.



**Figure 5-5.** The pyramidal system, representing the parts of the body on the motor cortex.

The following structures can be identified on the parietal lobe (see [Figure 5-3](#) [p. 209]):

- The postcentral gyrus (located posterior or caudal to the central sulcus) is important for the processing of sensory information; thus it is called the *primary sensory (somatosensory) cortex* or *area*. Similar to the primary motor cortex, body parts are topographically represented in the primary sensory cortex.
- The supramarginal gyrus is located around the caudal border of the lateral fissure.
- The angular gyrus is located around the caudal border of the superior temporal sulcus.

These two areas, the supramarginal gyrus and the angular gyrus, receive auditory, visual, and somatosensory information. The supramarginal gyrus participates in phonological processing, and the angular gyrus is involved in semantic processing.

The following structures can be identified on the temporal lobe (see [Figure 5-3](#) [p. 209]):

- The superior, middle, and inferior temporal gyri are located here. The *temporal operculum* is formed by the superior temporal and transverse temporal gyri. Operculum means “lid,” and in this case it covers the insula.
- Heschl’s gyrus (not shown in [Figure 5-3](#)) is located deep within the lateral sulcus on the temporal operculum. Heschl’s gyrus contains the primary auditory cortex or area.
- The planum temporale is located on the temporal operculum, posterior to Heschl’s gyrus.
- Wernicke’s area is on the posterior half of the superior temporal gyrus of the left hemisphere and includes the planum temporale. This area is important for language, particularly for language comprehension.
- The gustatory cortex is located on the frontal operculum and anterior insular cortex. This area is involved in the integration of olfactory and gustatory sensory inputs for food ingestion.
- The insular cortex (insula) is located deep within the lateral sulcus and is composed of the anterior and posterior insular cortices. Brain imaging and electrical stimulation data have revealed activation of the insula for speech and swallowing movements.

### Internal Structures of the Cerebral Hemispheres

Underneath the cortex, the following structures can be found:

- White matter tracts connecting different parts of the cortex or traveling to or from the brainstem and spinal cord
- The hippocampal formation, the amygdala, and the basal ganglia

### Basal Ganglia

The basal ganglia contain the following (see [Figure 5-6](#)):

#### *Anatomic structures*

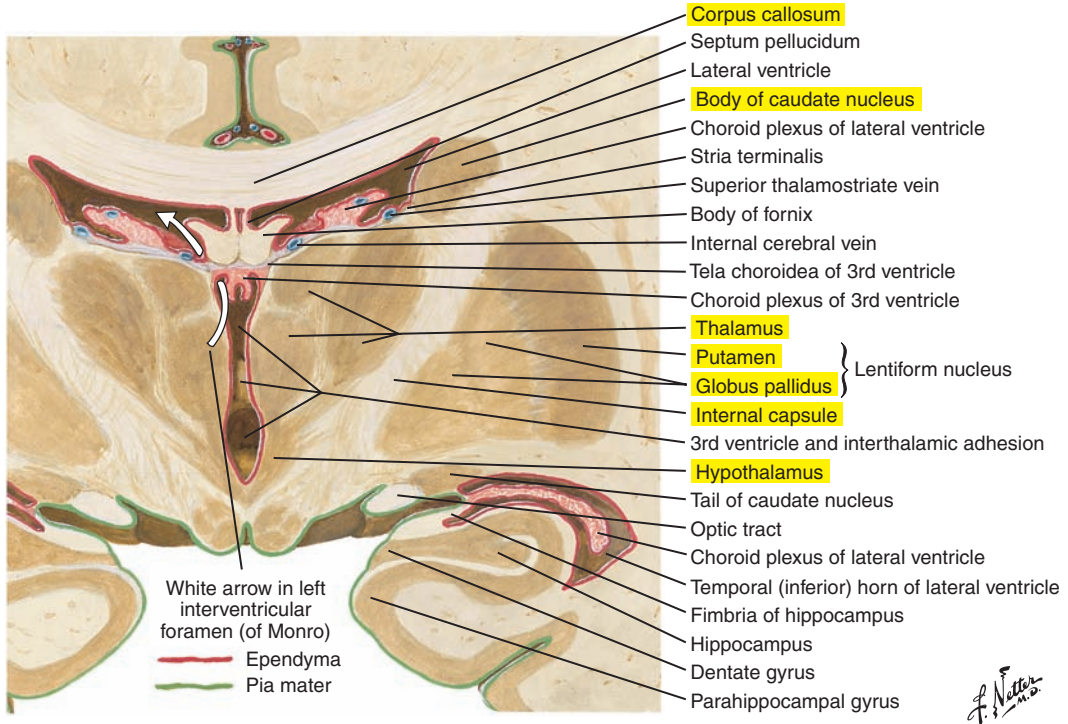
- Caudate nucleus
- Putamen
- Globus pallidus (external and internal segments)

#### *Functional components*

- Substantia nigra
- Subthalamic nucleus

The basal ganglia, which are located deep in the telencephalon, are also known as the *basal nuclei*. They participate in the control of body posture and muscle tone and in planning and initiating movements. The putamen and globus pallidus are collectively referred to as the *lentiform* or *lenticular nucleus*. The caudate nucleus and the putamen together form the *striate body* or the *corpus striatum*. The substantia nigra (midbrain) and subthalamic nuclei (diencephalon), although not anatomically located in the telencephalon, are often considered to be functional components of the basal ganglia.





**Coronal section of brain: posterior view**

**Figure 5-6.** A coronal section of the basal ganglia, thalamus, and associated structures.

## ■ DIENCEPHALON (THALAMUS, HYPOTHALAMUS, EPITHALAMUS, AND SUBTHALAMUS) (see [Figure 5-6](#) [p. 213])

---

### **Characteristic Features**

The diencephalon is located deep to and almost entirely encircled by the cerebral hemispheres. It contains the following structures: (1) thalamus, (2) hypothalamus, (3) epithalamus, and (4) subthalamus.

### **Importance for Speech and Swallowing**

The thalamus contains multiple nuclei that are part of motor, sensory, and associative pathways. The thalamus receives all sensory feedback, with the exception of olfactory feedback, and relays this information to the cortex. Because of this, it is often considered only as sensory relay nuclei. However, the thalamus has reciprocal connections with the cortex, receiving not only sensory feedback but also motor signals, indicating an additional role in movement production.

The ventrolateral nucleus and the ventroanterior nucleus connect the basal ganglia and cerebellum to their respective motor and premotor cortices and are consequently involved in motor planning and initiation of movement.

## ■ MESENCEPHALON (MIDBRAIN) (see [Figures 5-2](#) [p. 208] and [5-4](#) [p. 210])

---

### Characteristic Features

The mesencephalon is the smallest portion of the brainstem and is located just above the pons. It contains a number of nuclei, including the substantia nigra (part of the basal ganglia) and the inferior and superior colliculi, which are collectively referred to as the *corpora quadrigemina*. Inferior colliculi are important central auditory pathway nuclei, and superior colliculi are important central visual pathway nuclei.

Fibers from the corticospinal, corticobulbar, and corticopontine tracts pass through the mesencephalon. The base of the mesencephalon includes the superior cerebellar peduncles.

### Importance for Speech and Swallowing

The substantia nigra has an important role in regulating motor activity, particularly in initiating and terminating movements. The mesencephalon houses the nuclei of several cranial nerves (see section on Cranial Nerves). The inferior colliculi are important auditory relay and processing nuclei.

## ■ METENCEPHALON (PONS AND CEREBELLUM) (Figure 5-7; see also Figure 5-2 [p. 208])

---

### Characteristic Features

The metencephalon is composed of the pons and cerebellum (discussed in more detail later). The pons contains vertical and horizontal fibers. The horizontal fibers are located on the anterior surface of the pons and form the cerebellar peduncles, which connect the brainstem to the cerebellum. The vertical (longitudinal) fibers of the metencephalon are continuous with the myelencephalon longitudinal fibers and carry sensory and motor information.

### Importance for Speech and Swallowing

The pons contains the motor nuclei of two cranial nerves important for speech and swallowing: the trigeminal nerve (V) and the facial nerve (VII).

## ■ MYELENCEPHALON (MEDULLA OBLONGATA) (Figure 5-7; see also Figure 5-2 [p. 208])

---

### Characteristic Features

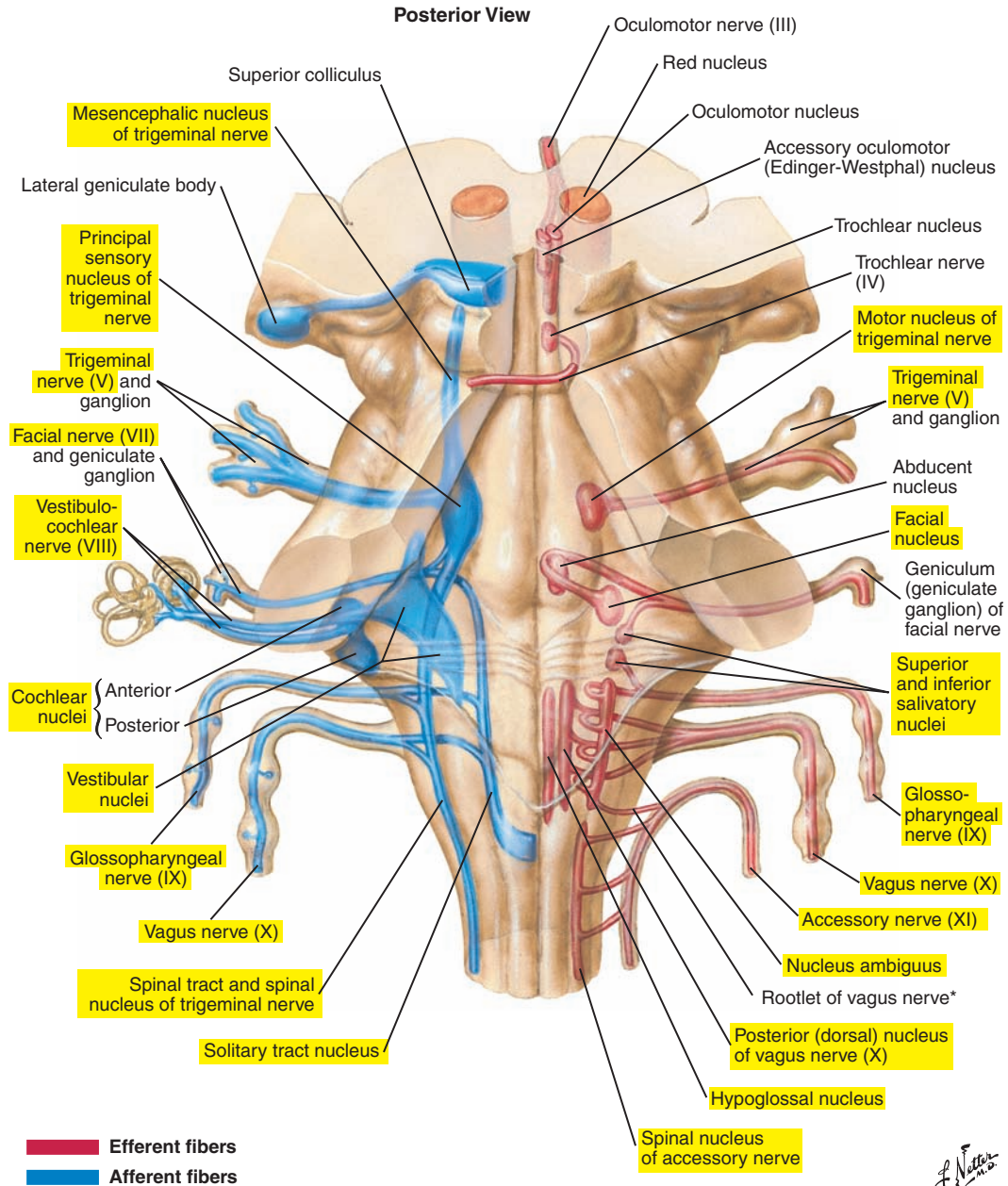
The medulla is the most caudal portion of the brainstem. It is located between the pons and the spinal cord, ventral to the cerebellum. The medulla resembles an enlargement of the spinal cord.

### Importance for Speech and Swallowing

The medulla contains the nucleus ambiguus, which contains the motor nuclei of cranial nerves important for speech and swallowing: the glossopharyngeal (IX) and the vagus (X). The nucleus ambiguus receives inputs primarily from the contralateral hemisphere.

### Brainstem Pattern-Generating Circuitry

The pons and medulla contain important pattern-generating nuclei, sometimes called brainstem *central pattern generators* (CPGs). This term is used because these collections of neurons contain the neural circuitry needed to generate some fundamental rhythmic and repetitive movements such as swallowing, mastication, respiration, and locomotion. The pattern generators for these movements may share multifunctional neurons that are biased to produce one or the other behavior (or coordinate the two, in the case of breathing and swallowing, for example). Although basic patterns can be generated by brainstem nuclei alone, adapting movements to changing external or internal environmental conditions (for example, different types of food boluses) requires sensory feedback and inputs from higher levels of the nervous system (e.g., cortical inputs). Thus, the CPGs are only a portion of the complex neural machinery controlling these complex behaviors. It has also been suggested that speech production uses or “fractionates” some of the brainstem circuitry for breathing, mastication, and swallowing for the production of speech.



\*This rootlet may travel a short distance with the spinal accessory to eventually rejoin the vagus.

**Figure 5-7.** The location of the cranial nerve nuclei and their afferent (*blue*) and efferent (*red*) fiber tracts in the brainstem.

## ■ SPINAL CORD (Figure 5-8)

---

### Characteristic Features

The spinal cord is the elongated, nearly cylindrical part of the central nervous system contained within the vertebral column. The superior boundary of the spinal cord is the base of the medulla, and its inferior boundary is the first or second lumbar vertebra. The spinal cord is protected by the vertebral column and the spinal meninges. It is divided into 31 segments, and each segment gives rise to a ventral root (efferent) and a dorsal root (afferent), which fuse to form a spinal nerve.

### Internal Structures

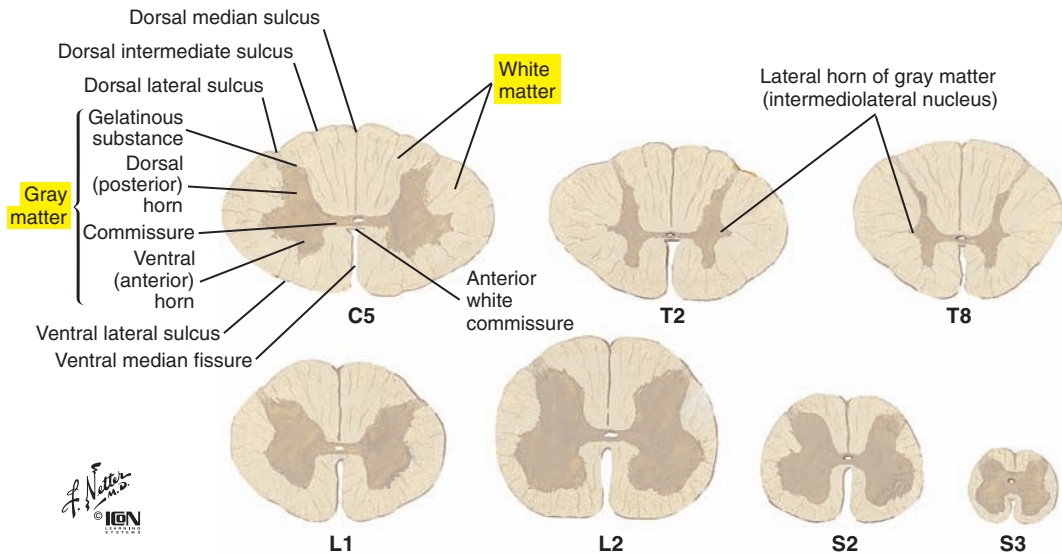
In a cross-section of the spinal cord, the following structures can be seen:

- The butterfly-shaped gray matter is located deep into the cord.
- The white matter surrounds the gray matter and contains ascending and descending pathways. The white matter pathways carry information from the brain to the periphery (motor) and from the periphery to the brain (sensory).



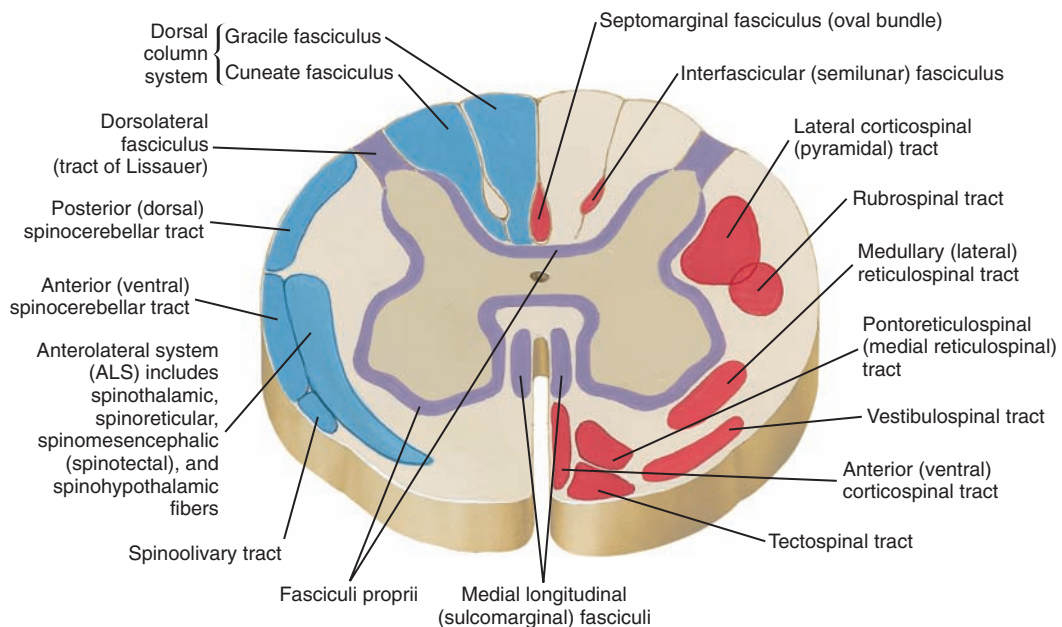
## Spinal Cord Cross-Sections: Fiber Tracts

Sections through spinal cord at various levels



### Principal fiber tracts of spinal cord

■ Ascending pathways  
■ Descending pathways  
■ Fibers passing in both directions



**Figure 5-8.** Fiber tracts of the spinal cord.

## ■ CEREBELLUM (Figures 5-9 and 5-10 [p. 222])

### Characteristic Features

The cerebellum (“small brain”) is a complex anatomical structure located posterior to the pons and medulla and inferior to the occipital lobe, which partially overlaps it. It is connected to the brainstem and to the rest of the brain through the inferior, middle, and superior peduncles that contain afferent and efferent fibers. We are still discovering the potential roles of the cerebellum in speech and swallowing, but like other complex movements, it is likely that it participates in movement planning and regulation as well as motor learning and memory.

The cerebellum is composed of an external layer (the cerebellar cortex) of gray matter, an internal core of white matter, and several deep nuclei including (from lateral to medial) the dentate, interposed (composed of the globose and emboliform nuclei), and fastigial nuclei. These act as relay nuclei for efferent and afferent cerebellar pathways. A sagittal section through the cerebellum (see [Figure 5-10](#) [p. 222]) reveals its treelike structure originally referred to as the *arbor vitae* or “tree of life.” Also apparent in transverse section is the complex surface structure of the cerebellar cortex that, unlike the gyri of the cerebral cortex, resembles “leaves” of a tree and are thus named folia.

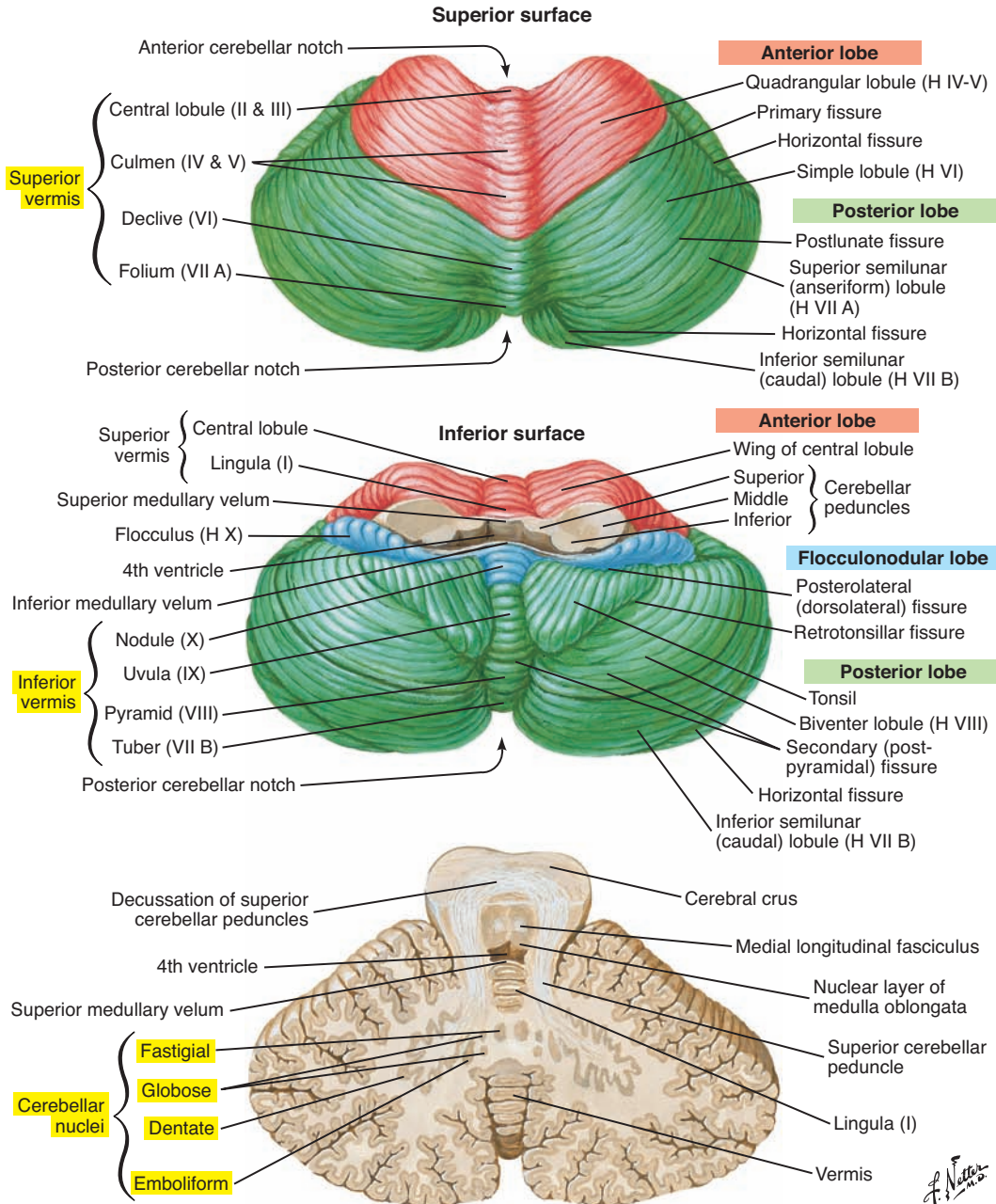
The cerebellum has a midline structure called the *vermis* that connects the two cerebellar hemispheres. Each hemisphere is divided into three lobes: anterior, posterior, and flocculonodular.

The cerebellum can be further divided into three functional and phylogenetic (from the evolutionary oldest to the most recent) regions ([Figure 5-11](#) [p. 223]): the vestibulocerebellum (or archicerebellum), which corresponds to the flocculonodular lobes; the spinocerebellum (or paleocerebellum), which includes the vermis and paravermis regions; and the cerebrocerebellum (or neocerebellum), which includes the lateral portions of both the anterior and posterior lobes.

The vestibulocerebellum, which receives inputs from and projects to the vestibular nuclei, is implicated in the regulation of posture and balance. Efferent pathways help coordinate eye, head, and body movements in response to information from the semicircular canals and otolith organs in the inner ear.

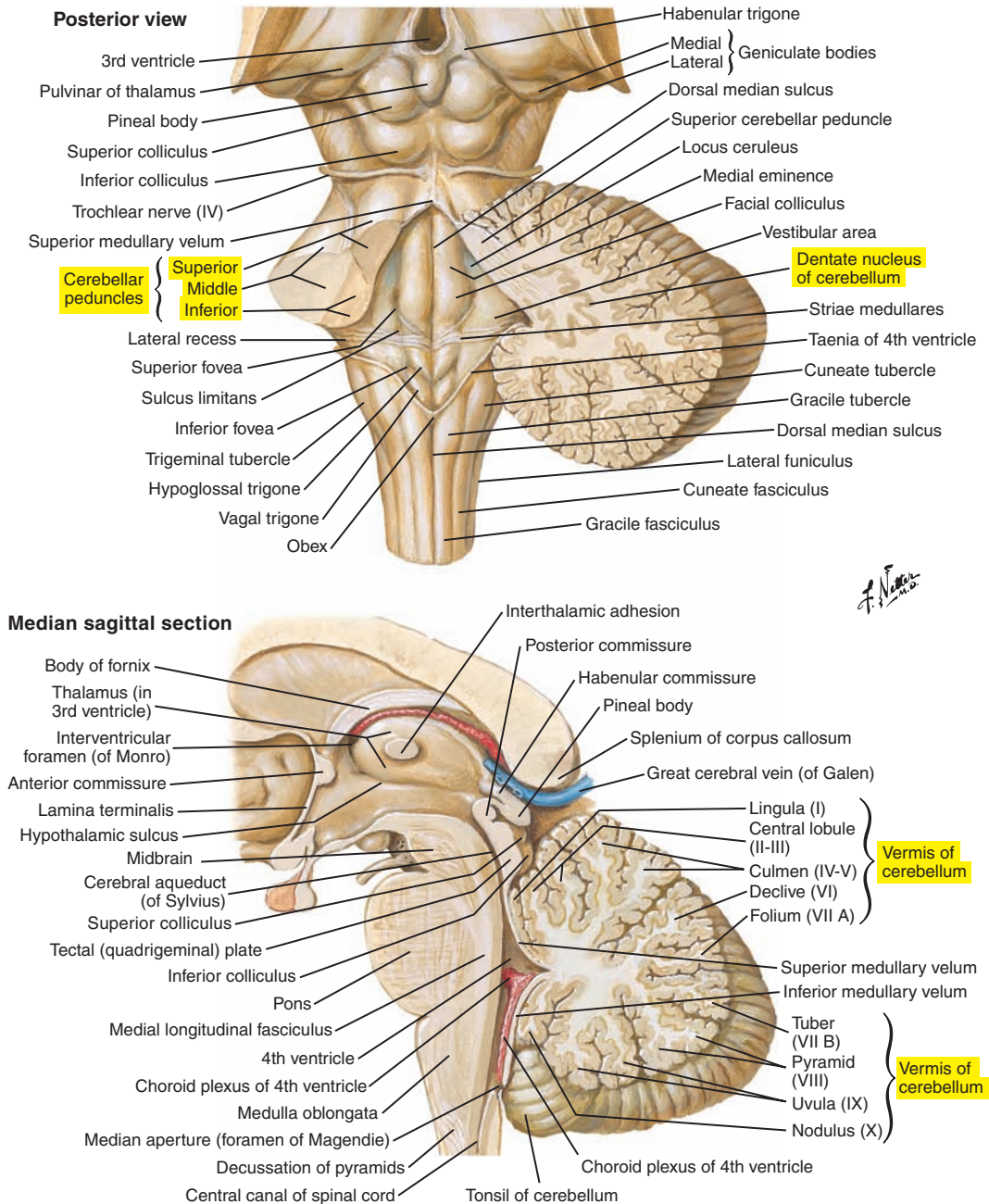
The spinocerebellum receives proprioceptive afferent inputs from the spinal cord and trigeminal system. Projections from cerebellar deep nuclei (interposed and fastigial) regulate muscle tone and posture via subcortical upper motor neuron pathways. Both motor outputs and sensory inputs are somatotopically organized in the spinocerebellum.

The cerebrocerebellum (or pontocerebellum) is involved in the planning, initiation, and regulation of skilled movements, including speech. The cerebrocerebellum receives input indirectly from the cerebral cortex and projects from the dentate nucleus to the premotor and association cortices of the frontal lobes via the thalamus.



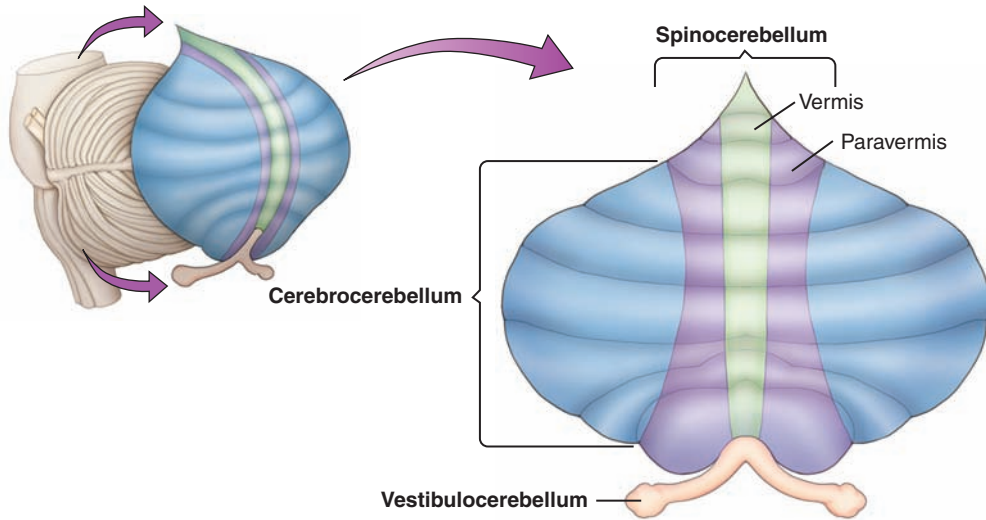
Section in plane of superior cerebellar peduncle

Figure 5-9. The cerebellum.



**Figure 5-10.** A sagittal section of the cerebellum and associated structures.





**Figure 5-11.** Flattening of the external surface of the cerebellum showing the vestibulocerebellum, spinocerebellum, and cerebrocerebellum (or pontocerebellum) regions. (Redrawn from Purves D, Augustine GJ, Fitzpatrick D, et al: *Neuroscience*, ed 5, Sunderland, MA, 2012, Sinauer Associates, Inc., Publishers.)

## ■ MENINGES (Figure 5-12)

---

The following three layers of protective coatings surround the brain (and spinal cord):

1. Dura mater
2. Arachnoid mater
3. Pia mater

### **Dura Mater**

The dura mater has a tough outer fibrous layer, which is actually two layers (inner meningeal and outer periosteal) that are contiguous except where they separate to accommodate the dural venous sinuses (e.g., superior sagittal sinus).

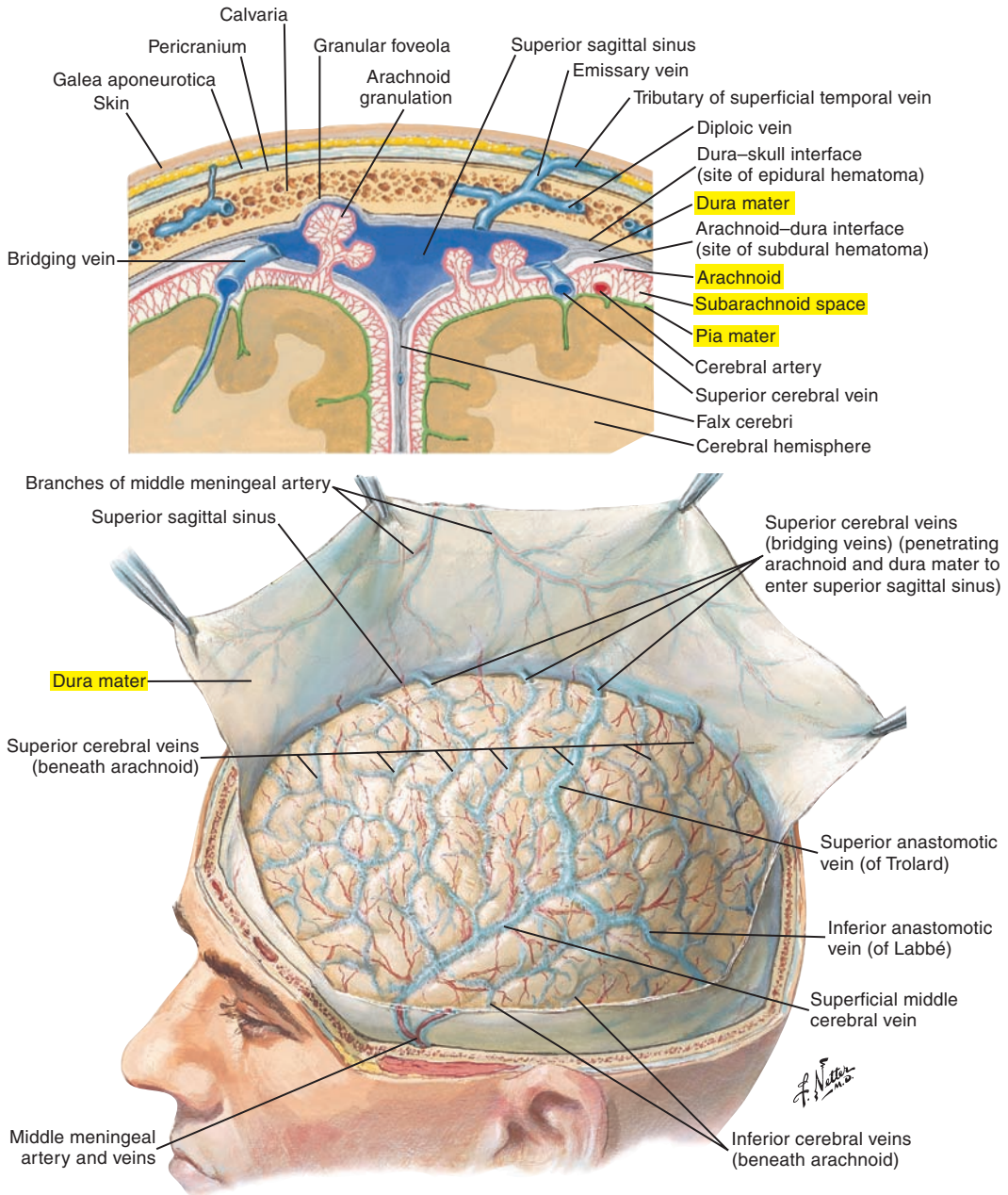
### **Arachnoid Mater**

The arachnoid mater is the medial layer and is much thinner than the dura mater. It follows the convolutions of the brain but not as closely as the pia mater. The subarachnoid space, located between the arachnoid and the pia mater, contains cerebrospinal fluid.

### **Pia Mater**

The pia mater is the deepest and extremely thin layer that closely follows the brain's surface and tightly covers fissures and sulci. The arachnoid and pia mater together are referred to as the *leptomeninges*.



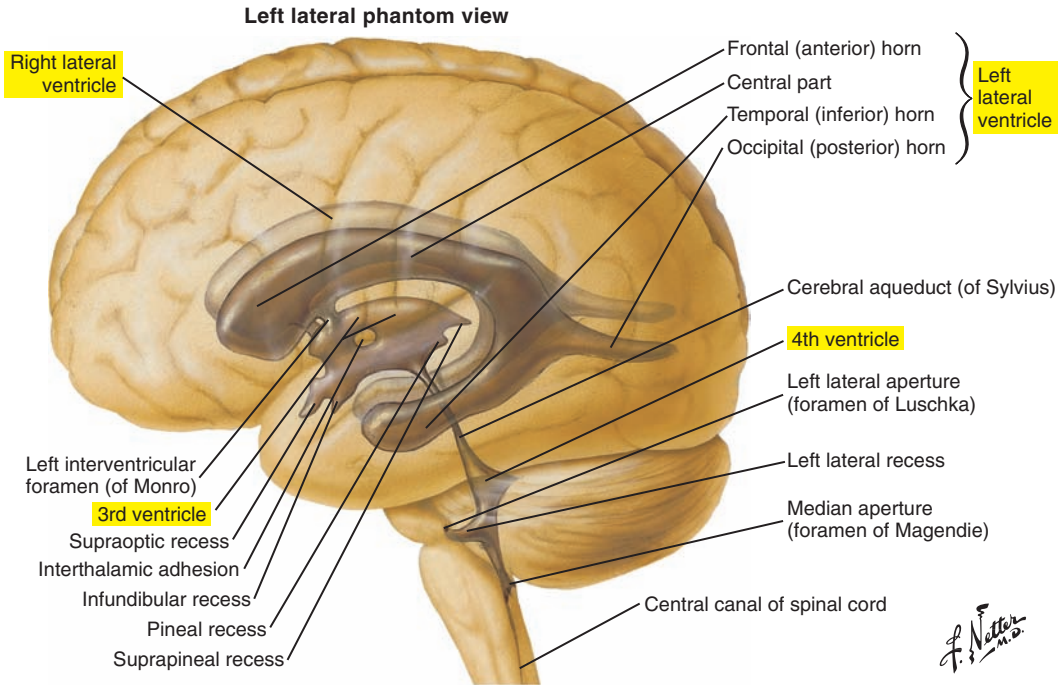


**Figure 5-12.** The meninges and superficial cerebral veins.

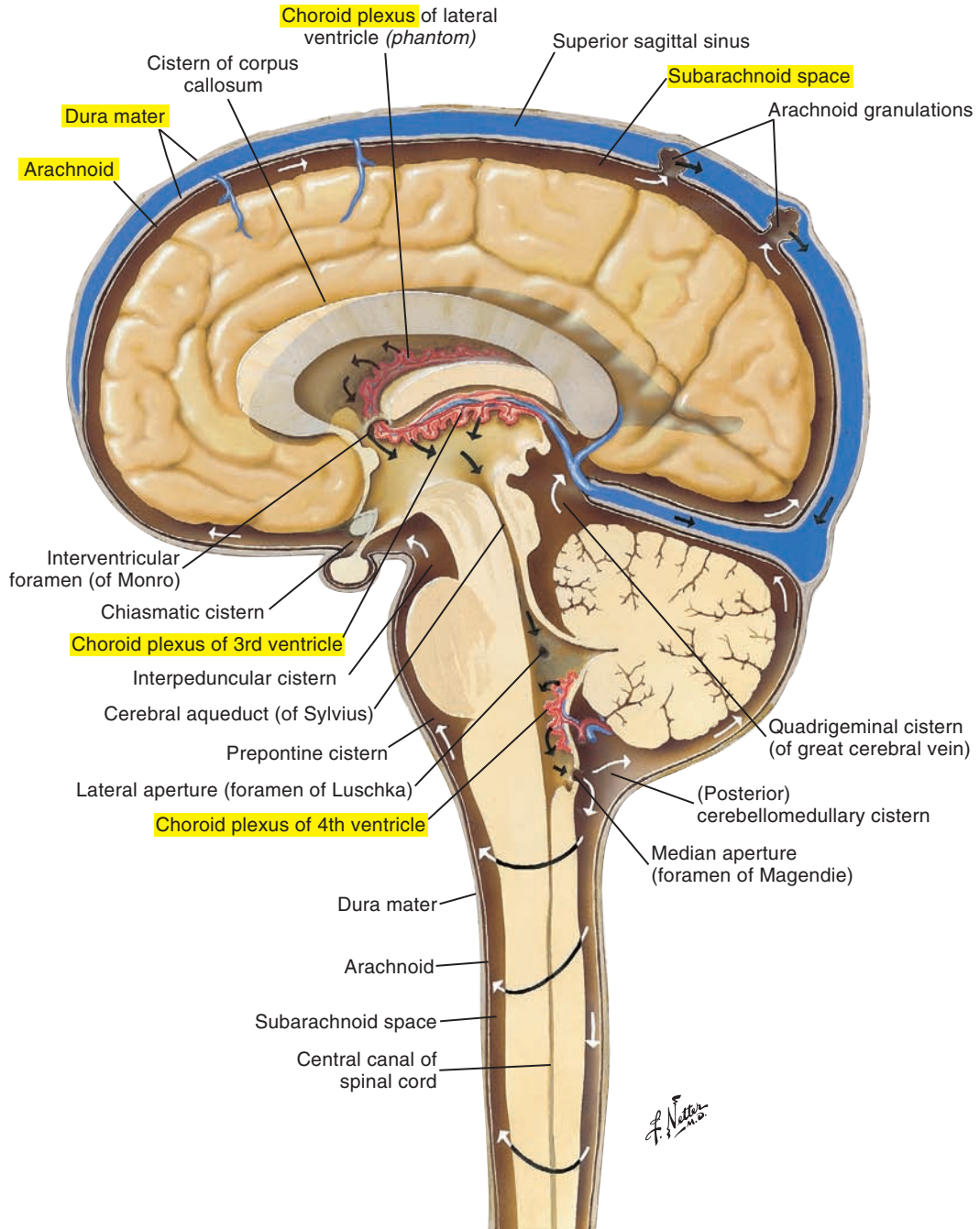
## ■ CEREBROSPINAL FLUID (Figures 5-13 and 5-14 [p. 228])

---

The principal source of cerebrospinal fluid is the choroid plexuses in the lateral ventricles, with contributions from other ventricular and extraventricular sites. Cerebrospinal fluid flows from the third and fourth ventricles into the subarachnoid space. It is reabsorbed into the dural venous sinuses and other sites and supports the weight of the brain and provides shock absorption against brain trauma. Cerebrospinal fluid transports nutrients and eliminates waste products.



**Figure 5-13.** Ventricles of the brain.



**Figure 5-14.** The circulation of cerebrospinal fluid.

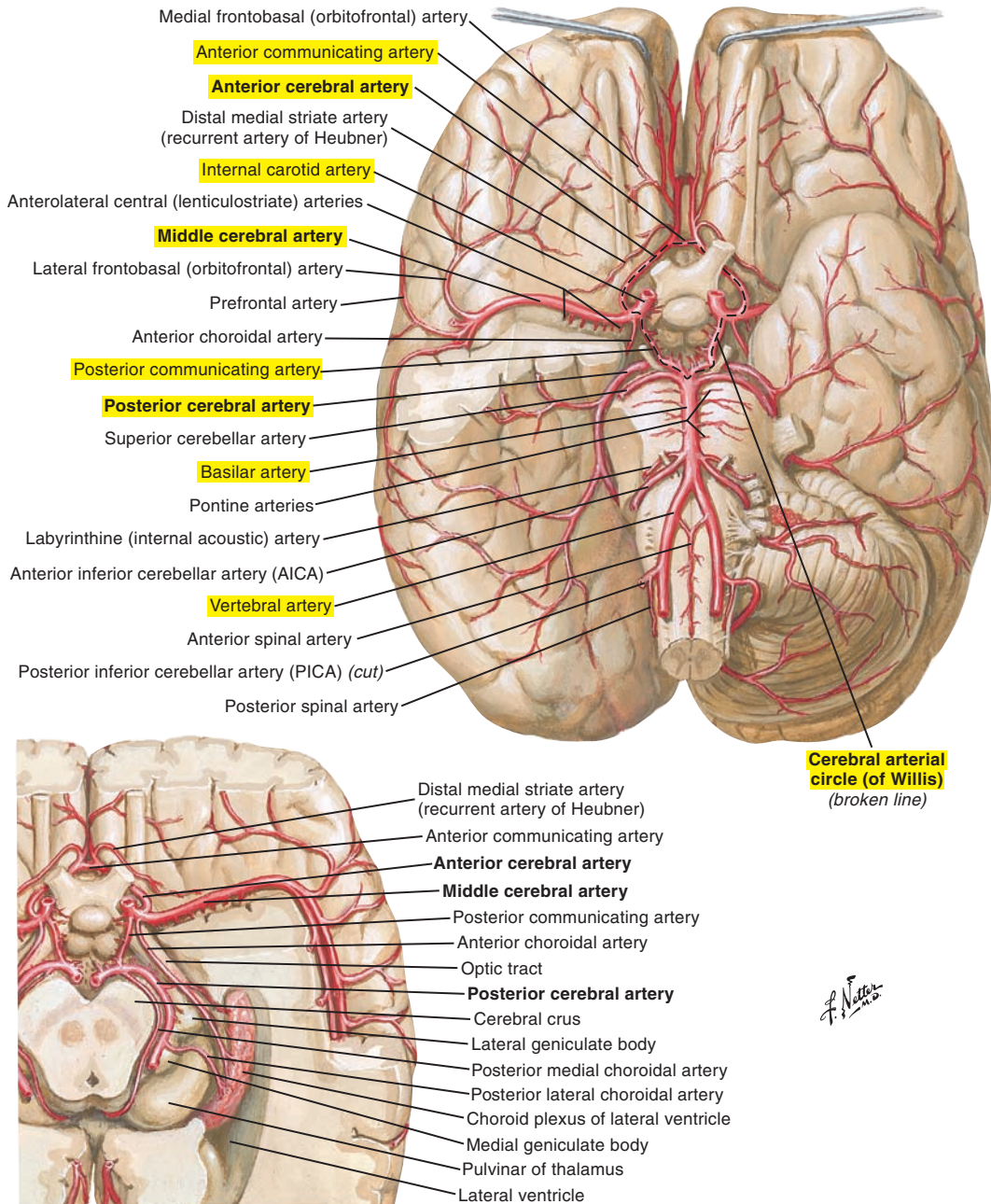
## ■ CEREBRAL VASCULATURE (Figures 5-15 [p. 230], 5-16 [p. 231], and 5-17 [p. 232])

Brain tissues have a high metabolic rate, and appropriate blood flow is crucial. The brain consumes approximately 20% of the oxygen supply of the body. Blood supply to the brain comes primarily from the *internal carotid arteries*, which arise from the common carotid, and the *vertebral arteries*, which arise from the subclavian arteries.

The two vertebral arteries, which join to become the basilar artery, supply the brainstem and cerebellum. The internal carotid arteries, through the anterior and middle cerebral arteries, and the basilar artery, through the posterior cerebral arteries, supply the cerebral cortex.

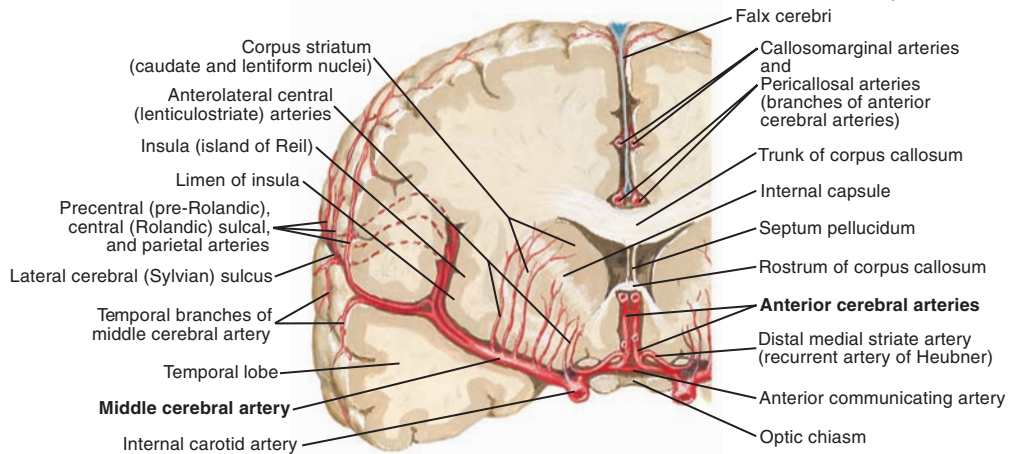
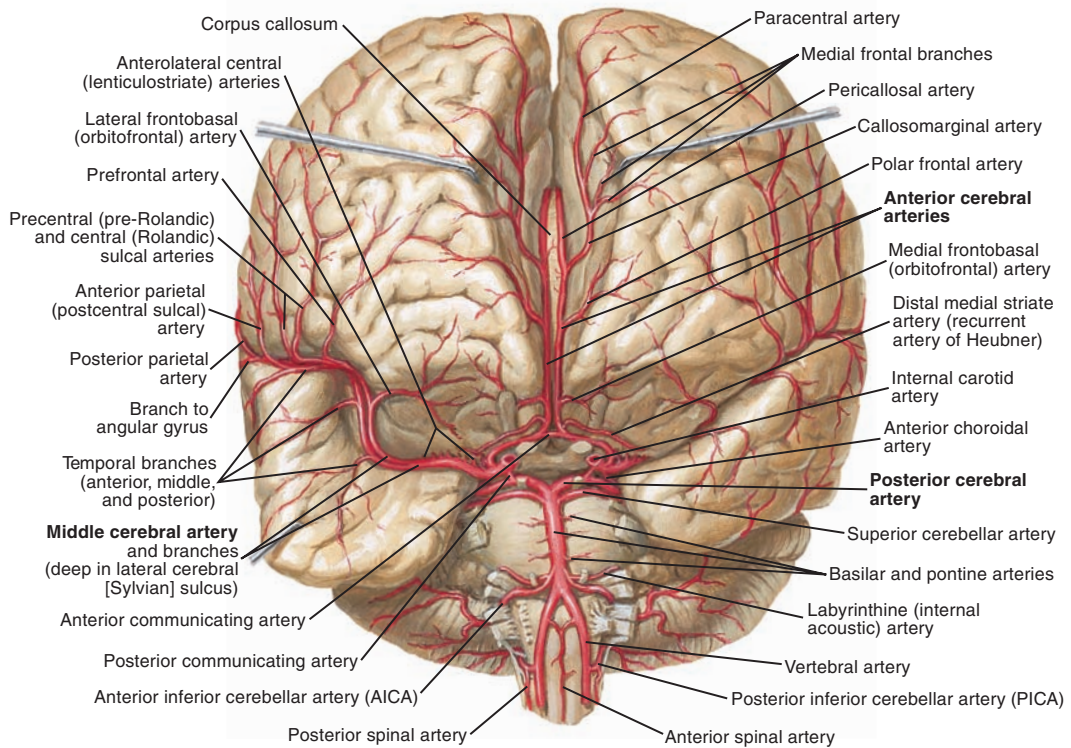
The *circle of Willis* (Figure 5-18 [p. 233]) is a key distribution network for blood to the brain. It is formed by the basilar artery, internal carotid arteries, middle cerebral arteries, anterior cerebral arteries, anterior communicating arteries that join the right and left anterior cerebral arteries, and the posterior cerebral arteries that join the internal carotids by the posterior communicating arteries. Thus, through the communicating arteries, this vasculature forms a circle of blood flow to the brain and allows for collateral blood flow in the event of interruptions to cerebral vasculature as the result of disease or damage (e.g., stroke). Most of the venous blood is drained from the venous dural sinuses through the internal jugular veins.



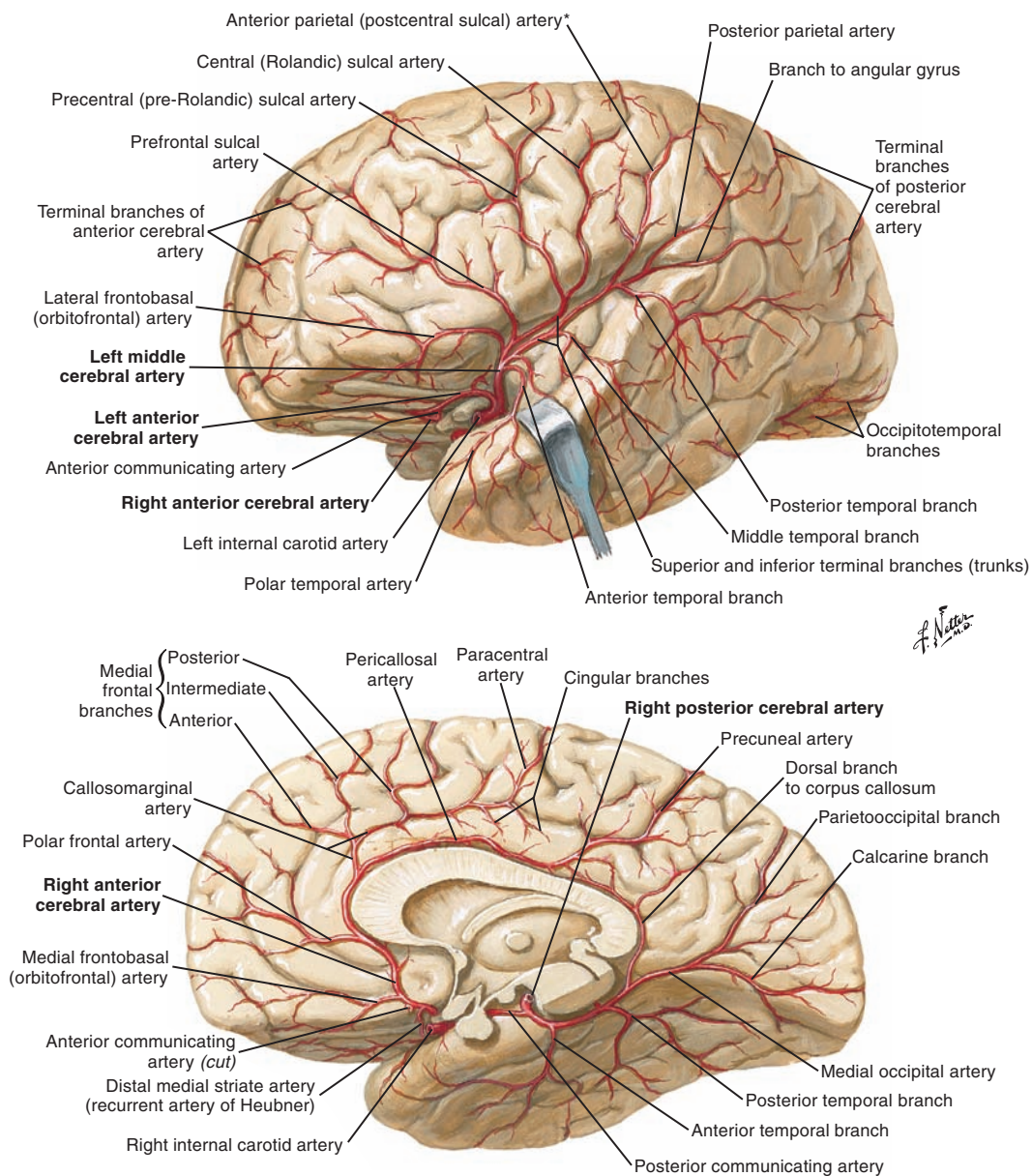


**Figure 5-15.** Inferior views of the arteries of the brain.



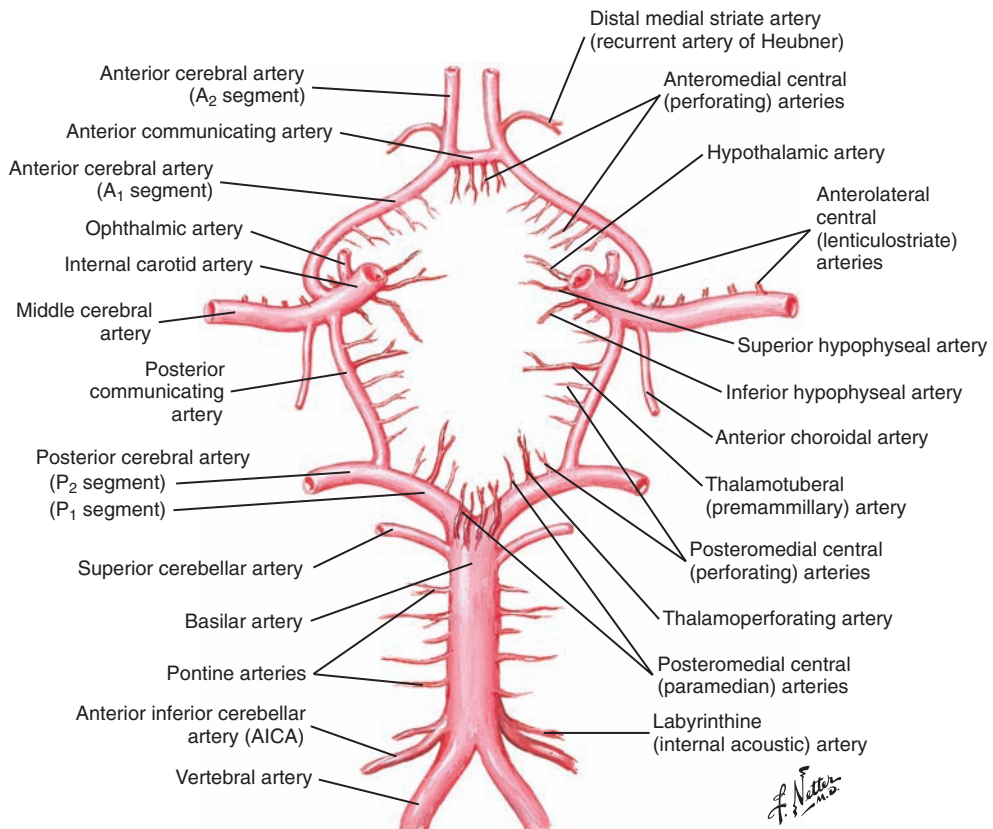


**Figure 5-16.** A frontal view and section of the arteries of the brain.



\*Note: Anterior parietal (postcentral sulcal) artery also occurs as separate anterior parietal and postcentral sulcal arteries.

**Figure 5-17.** Lateral and medial views of the arteries of the brain.

**Vessels dissected out: inferior view****Figure 5-18.** The cerebral arterial circle (of Willis).

## ■ CRANIAL NERVES (Figure 5-19 and 5-20 [p. 237]; see also Figure 5-7 [p. 217])

Twelve pairs of cranial nerves emerge from the brain, passing through different cranial foramina to innervate structures of the head and neck. Some of these nerves, like the vagus, also innervate structures other than the head and neck, such as the thoracic and abdominal cavities.

Cranial nerves are numbered using Roman numerals from I to XII according to their location, from rostral to caudal:

- I Olfactory
- II Optic
- III Oculomotor
- IV Trochlear
- V Trigeminal
- VI Abducens
- VII Facial
- VIII Vestibulocochlear
- IX Glossopharyngeal
- X Vagus
- XI Accessory
- XII Hypoglossal

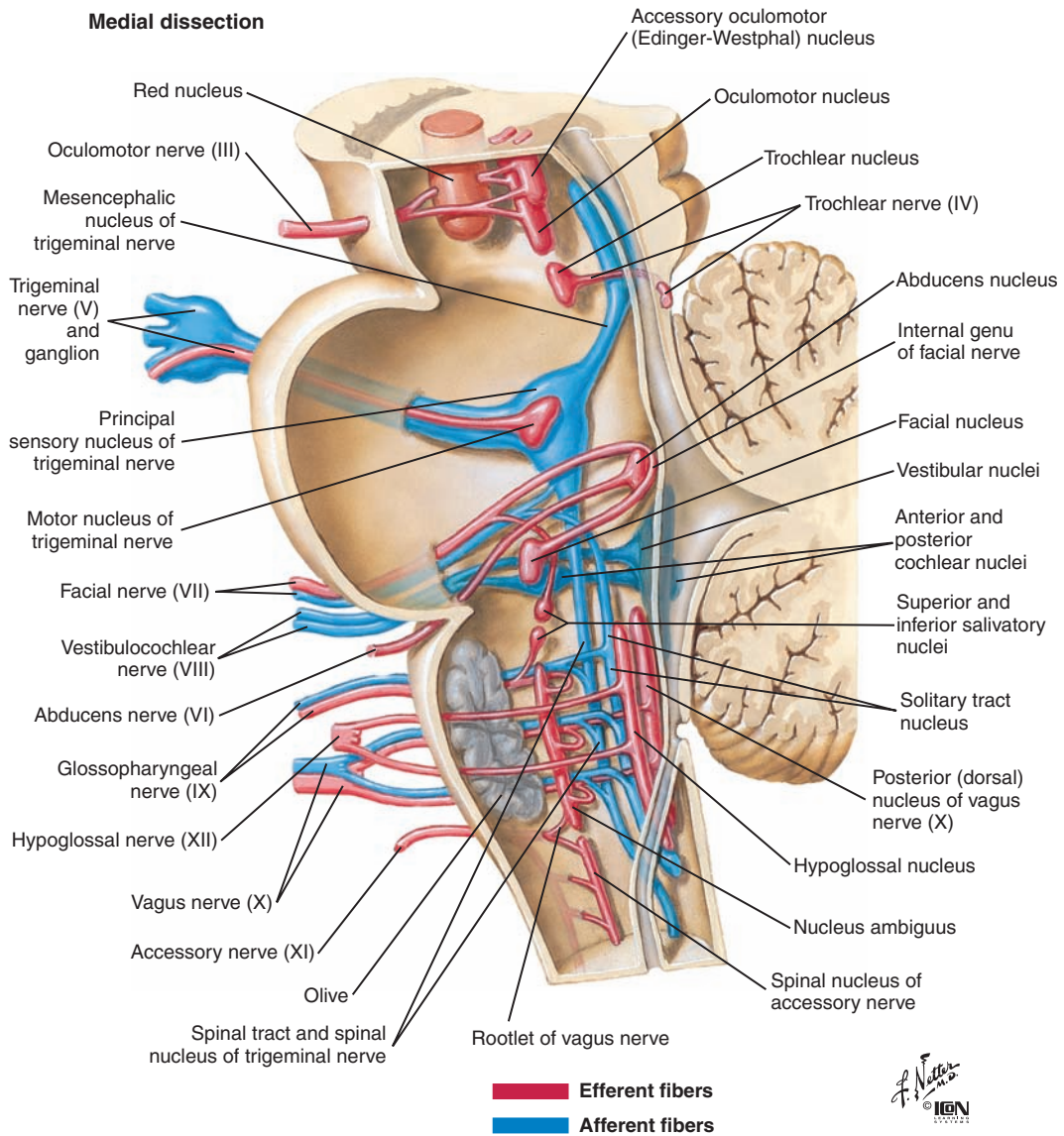
These nerves arise from the telencephalon (I), diencephalon (II), midbrain (III, IV), pons (V), pontomedullary junction (VI-VIII), and the medulla (IX-XII). Five (III, IV, VI, XI, XII) have a purely motor function; three (I, II, VIII) have a purely sensory function; and four (V, VII, IX, X) have a mixed function, both motor and sensory.

The cell bodies of first-order sensory neurons of cranial nerves (with the exception of nerves I and II) are collected in ganglia (e.g., trigeminal ganglion), and they synapse on second-order neurons within their respective brainstem cranial nerve nuclei. They next synapse on third-order sensory neurons in the thalamus. The cell bodies of the sensory neurons of cranial nerves I and II are located inside the organs that they innervate (nose and eyes).

With the exception of postganglionic visceral motor (parasympathetic) neurons, the cell bodies of all cranial nerve motor neurons are located in brainstem nuclei. Cranial nerve (and spinal nerve) motoneurons as well as their axons and the muscle fibers they innervate form important functional units called *motor units*. Motor units represent the “final common pathway” for the control of movement (as termed by Charles Sherrington, a pioneering neurophysiologist).



## Cranial Nerve Nuclei in Brainstem



**Figure 5-19.** Medial dissection of the brainstem cranial nerve nuclei and their efferent (red) and afferent (blue) fiber tracts.

### Types of Cranial Nerve Fibers

Cranial nerves can carry up to six functionally distinct types of fibers: three types of sensory fibers and three types of motor fibers. The terms *afferent* for sensory and *efferent* for motor are often used.

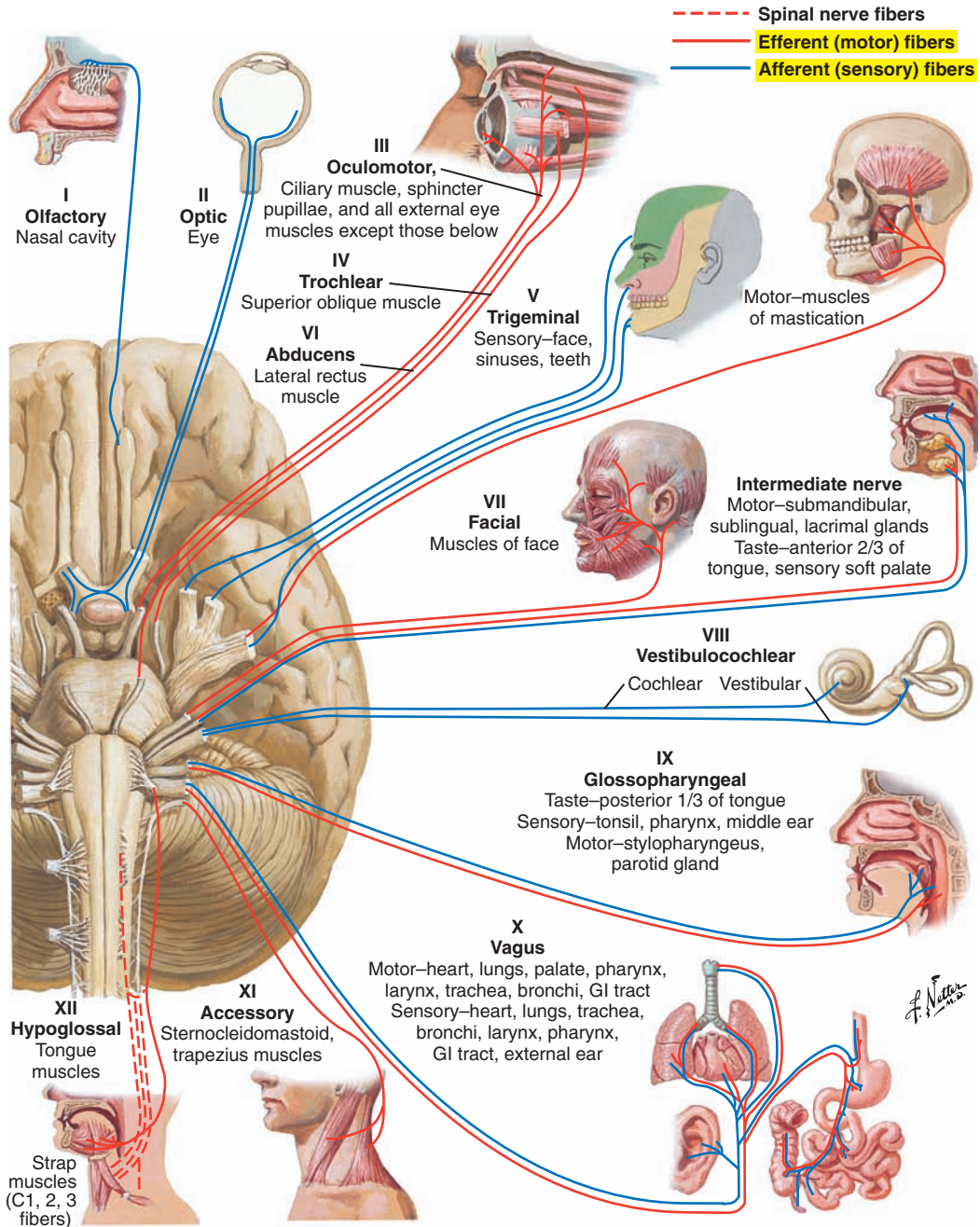
#### **Sensory**

- General sensory fibers carry touch, pain, temperature, and proprioception.
- Special sensory fibers carry hearing, balance, vision, taste, and smell; they are sometimes divided into special somatic (hearing, vision, and equilibrium) and special visceral (smell and taste).
- Visceral sensory fibers carry sensory information (except pain) from the viscera.

#### **Motor**

- Somatic motor fibers innervate somatic skeletal muscles.
- Branchial motor fibers innervate skeletal muscles that develop from the branchial arches (branchiomeric).
- Visceral motor (parasympathetic efferent) fibers innervate smooth muscle and glands.





**Figure 5-20.** Motor and sensory distribution of the cranial nerves.

## **I Olfactory (Sensory)**

The first-order olfactory neurons transmit signals from receptors in the region of the nasal mucosa through the cribriform plate of the ethmoid bone to synapse on second-order neurons in the olfactory bulb. Second-order olfactory fibers travel caudally through the olfactory tract, which runs underneath the frontal lobe; pass into the cerebral hemispheres; and terminate in the primary olfactory area, in the medial temporal lobe.

First-order neurons enter the cranial cavity through the cribriform plate of the ethmoid bone, and second-order neurons project to the cerebral cortex (telencephalon) through the olfactory tract. Function is special sensory: olfaction.

## **II Optic (Sensory)**

The optic nerve originates from the retina. Its fibers course within the optic canal, which is formed by the posterior portion of the sphenoid bone, and converge to form the optic chiasm. The fibers then diverge into the optic tracts, which course toward the thalamus, where the fibers synapse in the lateral geniculate nucleus. The nerve fibers leave the thalamus to travel to the primary visual area in the occipital cortex.

The optic nerve enters the cranial cavity through the optic canal and enters the brain at the thalamus (diencephalon). Function is special sensory: vision.

### III Oculomotor (Motor)

The oculomotor nerve emerges from the anterior mesencephalon (midbrain) and exits the cranial cavity through the superior orbital fissure of the sphenoid bone to enter into the orbit.

Function is as follows:

- Somatic motor: from the oculomotor nucleus located in the midbrain to the six extraocular eye muscles and the levator muscle of the upper eyelid
- Visceral motor: from the accessory oculomotor (Edinger-Westphal) nucleus located in the midbrain to the sphincter pupillae and ciliary muscles that are involved in the pupillary light and accommodation reflexes

### IV Trochlear (Motor)

The smallest cranial nerve originates from the trochlear nucleus located in the midbrain and emerges from the posterior mesencephalon at the level of the inferior colliculus. Its fibers circle around the brainstem and course forward toward the eye in the subarachnoid space. Cranial nerve IV exits the cranial cavity and enters the orbit through the superior orbital fissure. The function of this nerve is somatic motor to the superior oblique muscle in the orbit.

## **V Trigeminal (Motor and Sensory) (Figure 5-21)**

The trigeminal nerve is composed of three main divisions: ophthalmic, maxillary, and mandibular. These divisions converge at the level of the petrous portion of the temporal bone to form the trigeminal (or semilunar) ganglion. From the ganglion, the sensory fibers of the trigeminal nerve enter the brain at the metencephalon (pons) and terminate in the trigeminal sensory nucleus. The trigeminal sensory nucleus extends from the midbrain to the cervical spinal cord and is composed of three divisions: the mesencephalic nucleus, the principal sensory nucleus (located in the pons), and the spinal nucleus (located along the medulla and the upper portion of the cervical spinal cord). The motor component of the trigeminal originates from the motor nucleus of the trigeminal nerve located in the pons.

Special motor fibers (autonomic) from the facial and glossopharyngeal nerves terminate in ganglia (e.g., otic ganglion, submandibular ganglion, and pterygopalatine ganglion). The fibers originating from these ganglia that innervate the parotid, lacrimal, submandibular, and sublingual glands are part of the trigeminal nerve.

### ***Ophthalmic Nerve, or Division ( $V_1$ ) (Sensory)***

The cranial entry point of the ophthalmic nerve is the superior orbital fissure of the sphenoid bone.

The function is general sensory from the following areas: skin of the forehead, upper eyelid, and nose; mucous membranes of the anterior and superior portions of the nasal cavity and paranasal sinuses; and cornea of the eye.

### ***Maxillary Nerve, or Division ( $V_2$ ) (Sensory)***

The cranial entry point of the maxillary nerve is the foramen rotundum of the sphenoid bone. The function is general sensory from the following areas: skin of the side of the forehead, the anterior cheek and the side of the nose, lower eyelid, upper lip, upper teeth, maxilla, palate, nasal septum, posterior and inferior portions of nasal cavity, maxillary sinus, and gums and mucous membranes of the upper oral cavity.

### ***Mandibular Nerve, or Division ( $V_3$ ) (Sensory and Motor)***

The cranial entry and exit point of the mandibular nerve is the foramen ovale of the sphenoid bone.

Its function is as follows:

- General sensory: from the anterior two-thirds of the tongue, mucous membranes of the floor of the mouth and the cheek, the lower teeth, part of the external ear (anterior part of the auricle, external acoustic meatus, external surface of the tympanic membrane), skin of the lower lip, the chin, the cheek, and the temple
- Branchial motor: to the muscles of mastication (masseter, temporalis, medial and lateral pterygoid), mylohyoid, the anterior belly of digastric, the tensor tympani, and the tensor veli palatini

### ***Mesencephalic Trigeminal Pathway***

Primary sensory neurons carry proprioceptive sensory information from the masticatory muscles and project primarily to the trigeminal motor nucleus for reflex control of masticatory movements.

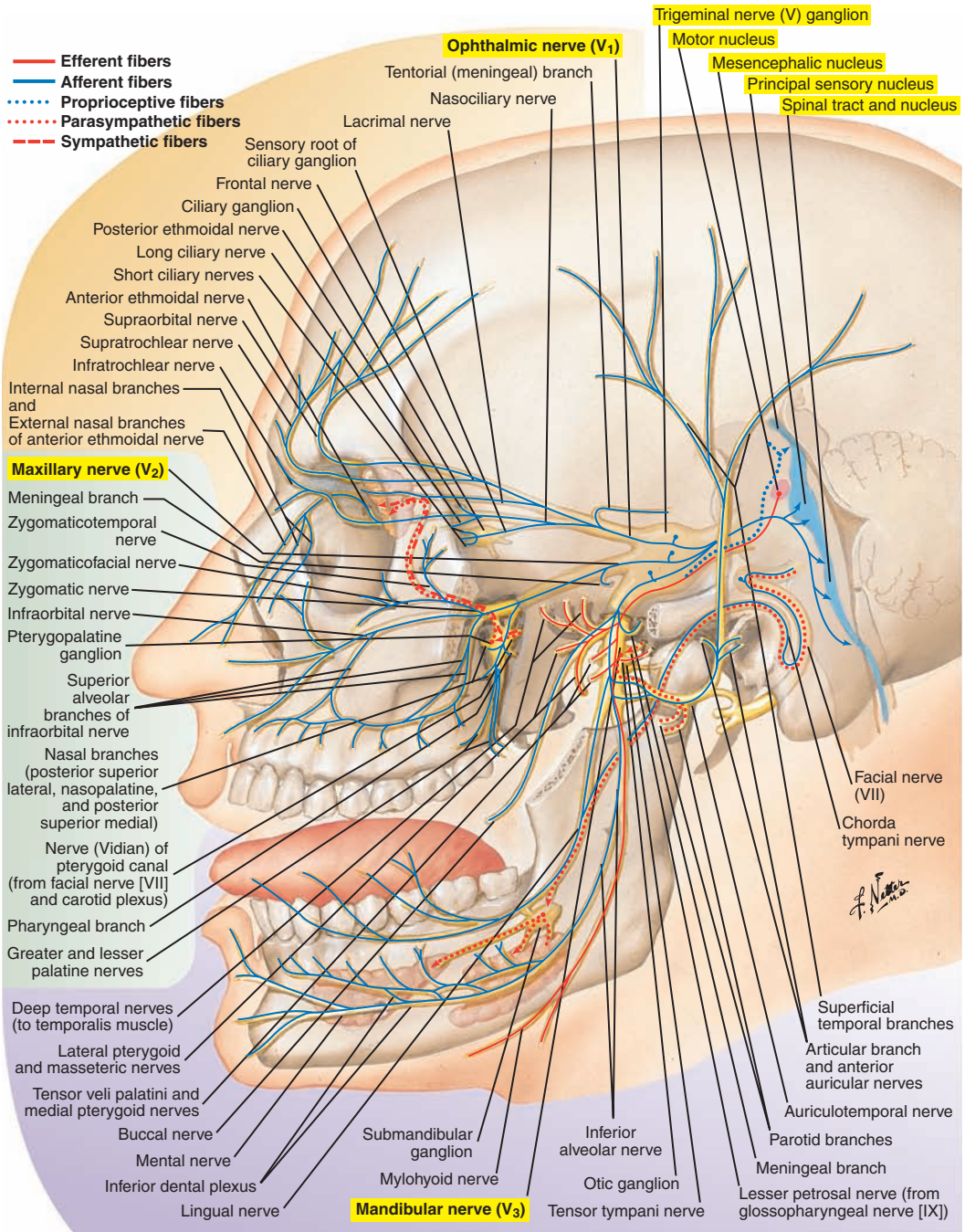


Figure 5-21. The trigeminal nerve (V).



## VI Abducens (Motor)

The abducens nerve, which originates from the abducens nucleus (located in the pons), emerges from the inferior part of the pons and enters the orbit to reach the eye. The brain exit point is the junction between the metencephalon (pons) and the myelencephalon (medulla), and the cranial exit point is the superior orbital fissure of the sphenoid bone.

Function is somatic motor: to the lateral rectus muscle of the ipsilateral orbit.

## VII Facial (Motor and Sensory) (Figure 5-22)

The facial nerve travels from the pons to enter the temporal bone and emerges from the cranium as five distinct branches. The brain exit point is the junction between the metencephalon (pons) and the myelencephalon (medulla). For the cranial exit point, the nerve runs in the internal acoustic meatus and the facial canal in the petrous part of the temporal bone and leaves the skull through the stylomastoid foramen.

Function is mixed, as follows:

- General sensory: from the skin of the concha of the auricle and external acoustic meatus to the spinal nucleus of the trigeminal nerve
- Special sensory: taste information from the anterior two-thirds of the tongue to the solitary tract nucleus located in the medulla
- Branchial motor: from the motor nucleus of the facial nerve (located in the pons) to the muscles of facial expression (excluding the primary muscles of mastication), the stylohyoid, the posterior belly of the digastric, and the stapedius muscle
- Visceral motor: from the superior salivatory nucleus (located in the pons) as preganglionic autonomic fibers to the mucous membranes of the hard and soft palate and nose, as well as lacrimal, submandibular, and sublingual glands

Several terminal branches of the facial nerves join to form the parotid plexus, which is located in the parotid salivary gland. The nerve passes into the gland and divides into several branches: temporal, zygomatic, buccal, mandibular, and cervical.

The motor component of the facial nerve contains two segments: one that originates from the superior portion of the facial nerve nuclei and innervates the superior portion of the face and one that originates from the inferior portion of the facial nerve nuclei and innervates the inferior portion of the face. The superior portions of the nerve that innervate the superior portions of the face receive input from both hemispheres. In contrast, the inferior portions that innervate the lower portion of the face receive only contralateral cortical input.

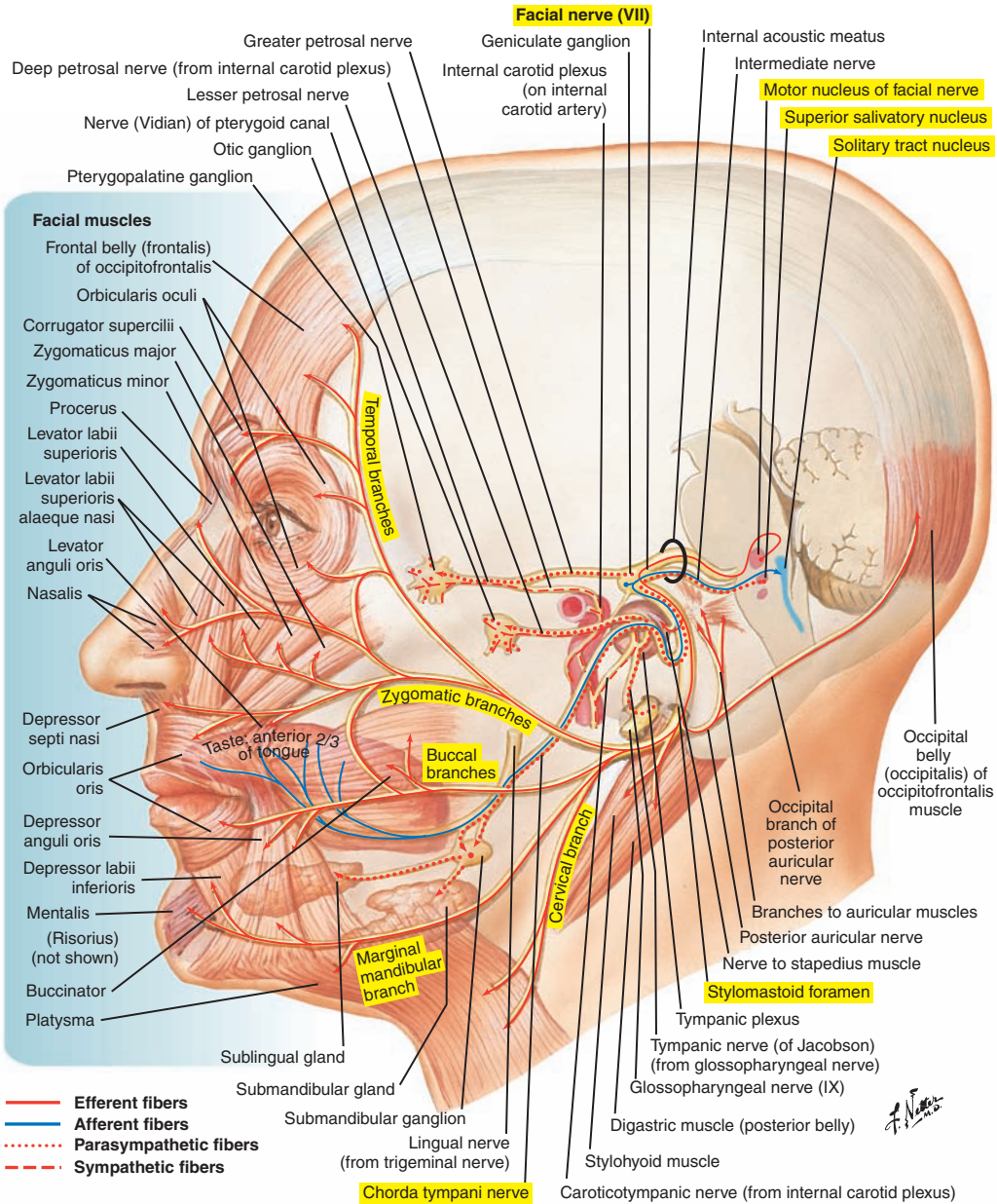
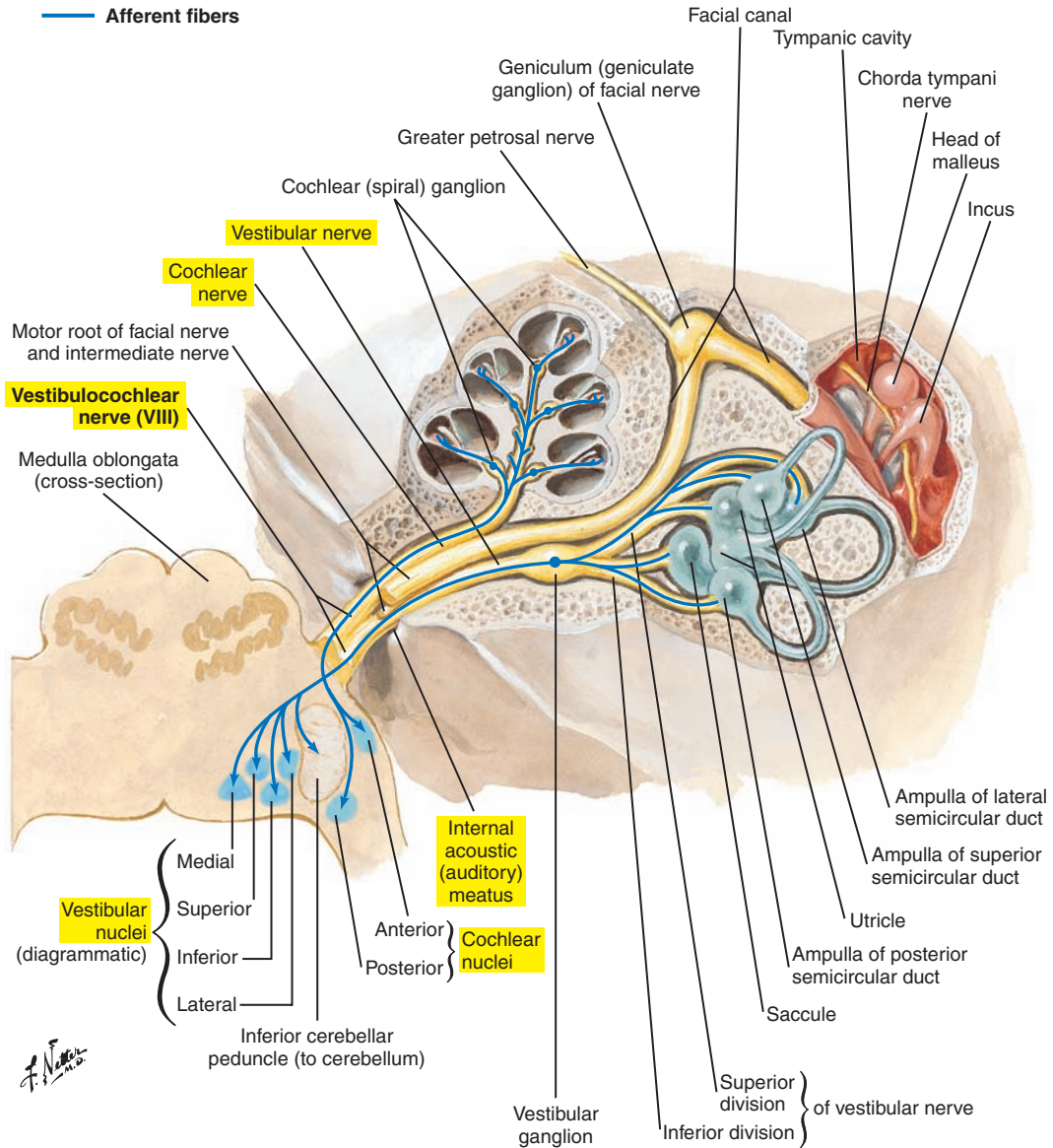


Figure 5-22. The facial nerve (VII).

**VIII Vestibulocochlear (Sensory)** (Figure 5-23)

The vestibulocochlear nerve originates from the internal ear, located in the temporal bone, runs through the internal acoustic meatus, enters in the brainstem at the level of the junction between the metencephalon (pons) and the myelencephalon (medulla), and terminates in the vestibular nuclei and cochlear nuclei (located in the pontomedullary junction). The nerve fibers originating from the auditory receptors in the cochlea form the cochlear nerve, and the nerve fibers originating from the equilibrium receptors in the semicircular canals and vestibule form the vestibular nerve. These two nerves fuse to form the vestibulocochlear nerve. The cranial entry point is the internal acoustic meatus and the brain entry point is the junction between the metencephalon (pons) and the myelencephalon (medulla).

Function is special sensory for audition, equilibrium, and body orientation.



**Figure 5-23.** The vestibulocochlear nerve (VIII).

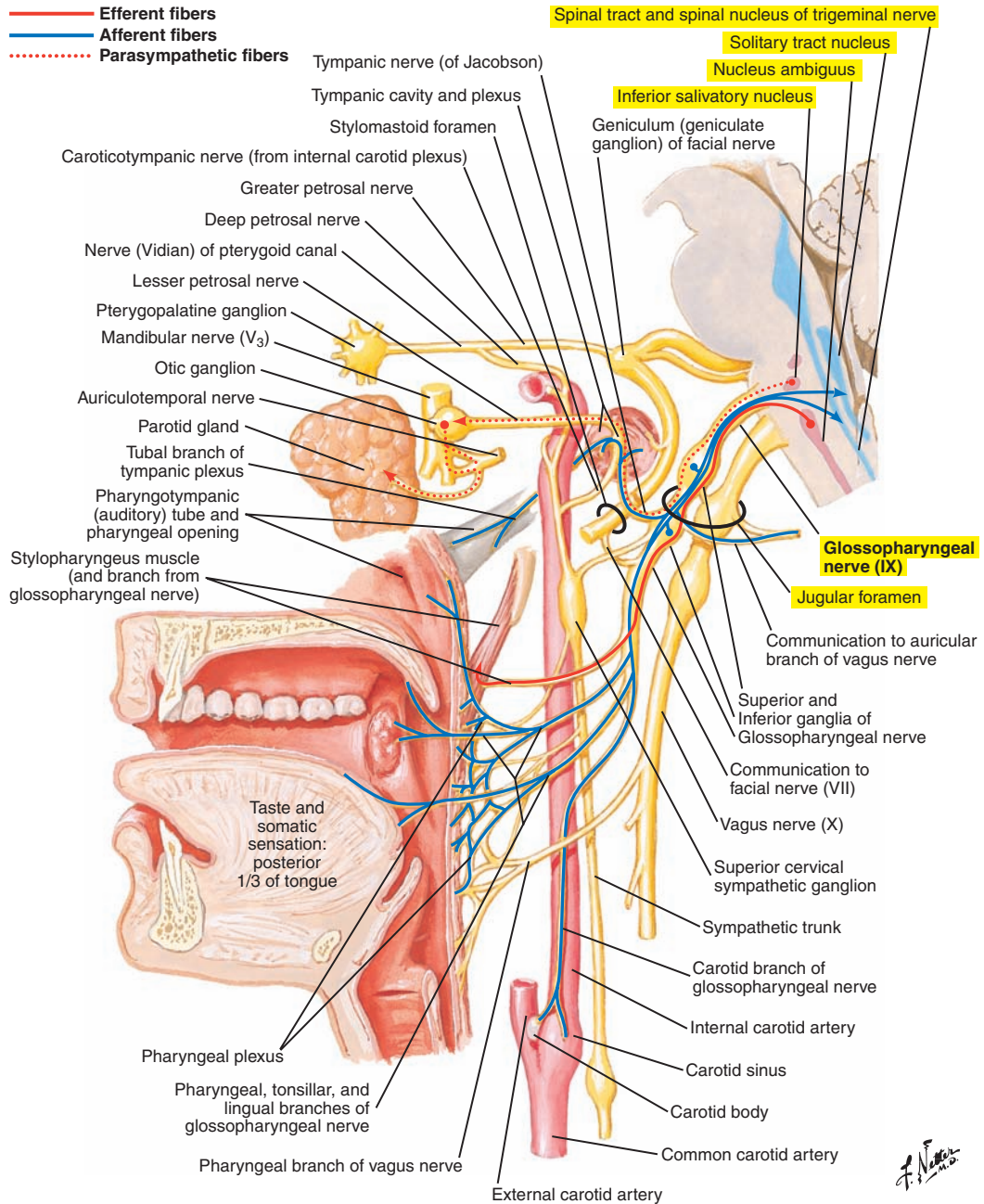
**IX Glossopharyngeal (Motor and Sensory)** (Figure 5-24)

The glossopharyngeal nerve emerges from the myelencephalon (medulla) and courses from the cranium to the pharynx. The brain exit point of cranial nerve IX is the myelencephalon (medulla), and the cranial exit point is the jugular foramen, between the temporal bone and the occipital bone.

Function is mixed, as follows:

- Branchial motor: from the nucleus ambiguus (located in the medulla) to the stylopharyngeus muscle
- Visceral motor: from the inferior salivatory nucleus (located in the medulla) as preganglionic autonomic fibers to the parotid gland
- General sensory: from the posterior one-third of the tongue, the tonsils, the pharynx, the tympanic membrane (internal surface), the tympanic cavity, and the pharyngotympanic tube to the spinal nucleus of the trigeminal nerve
- Visceral sensory: from the carotid body and sinus to the solitary tract nucleus
- Special sensory: taste from the posterior one-third of the tongue to the solitary tract nucleus.





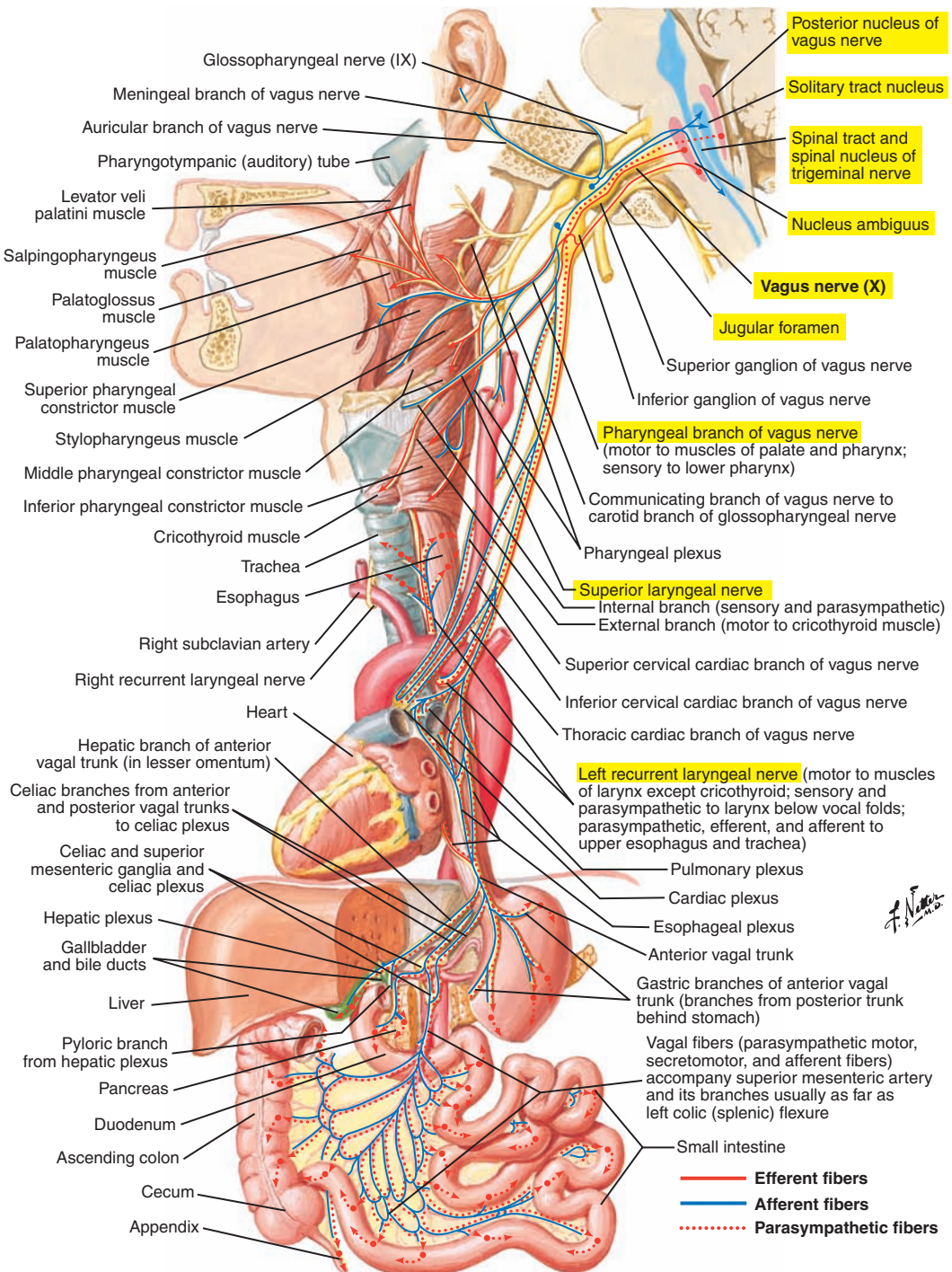
**Figure 5-24.** The glossopharyngeal nerve (IX).

**X Vagus, or Pneumogastric, Nerve (Motor and Sensory) (Figure 5-25)**

The vagus nerve emerges from the medulla; travels down to the jugular foramen; and continues its course down to the neck, thorax, and abdomen. The brain exit point is the myelencephalon (medulla), and the cranial exit point is the jugular foramen, between the temporal bone and the occipital bone.

Function is mixed, as follows:

- Branchial motor: from the nucleus ambiguus to the muscles of the pharynx (except the stylopharyngeus, which is innervated by the glossopharyngeal nerve), muscles of the larynx, and muscles of the soft palate (except the tensor veli palatini, which is innervated by the trigeminal nerve)
- Visceral motor: from the posterior (dorsal) nucleus (located in the medulla) to smooth muscle and glands of the pharynx, larynx, and viscera of the thorax and abdomen, including smooth muscle of the esophagus and cardiac muscle
- General sensory: from portions of the skin of the external ear and external acoustic meatus, part of the external surface of the tympanic membrane, the pharynx and larynx, and dura mater of the posterior cranial fossa to terminate in the spinal nucleus of the trigeminal nerve
- Visceral sensory: from the larynx (above and below the vocal folds), esophagus, trachea, heart, and thoracic and abdominal viscera (including the lungs and gastrointestinal tract) to the solitary tract nucleus
- Special sensory: taste information from the epiglottis and pharynx to the solitary tract nucleus

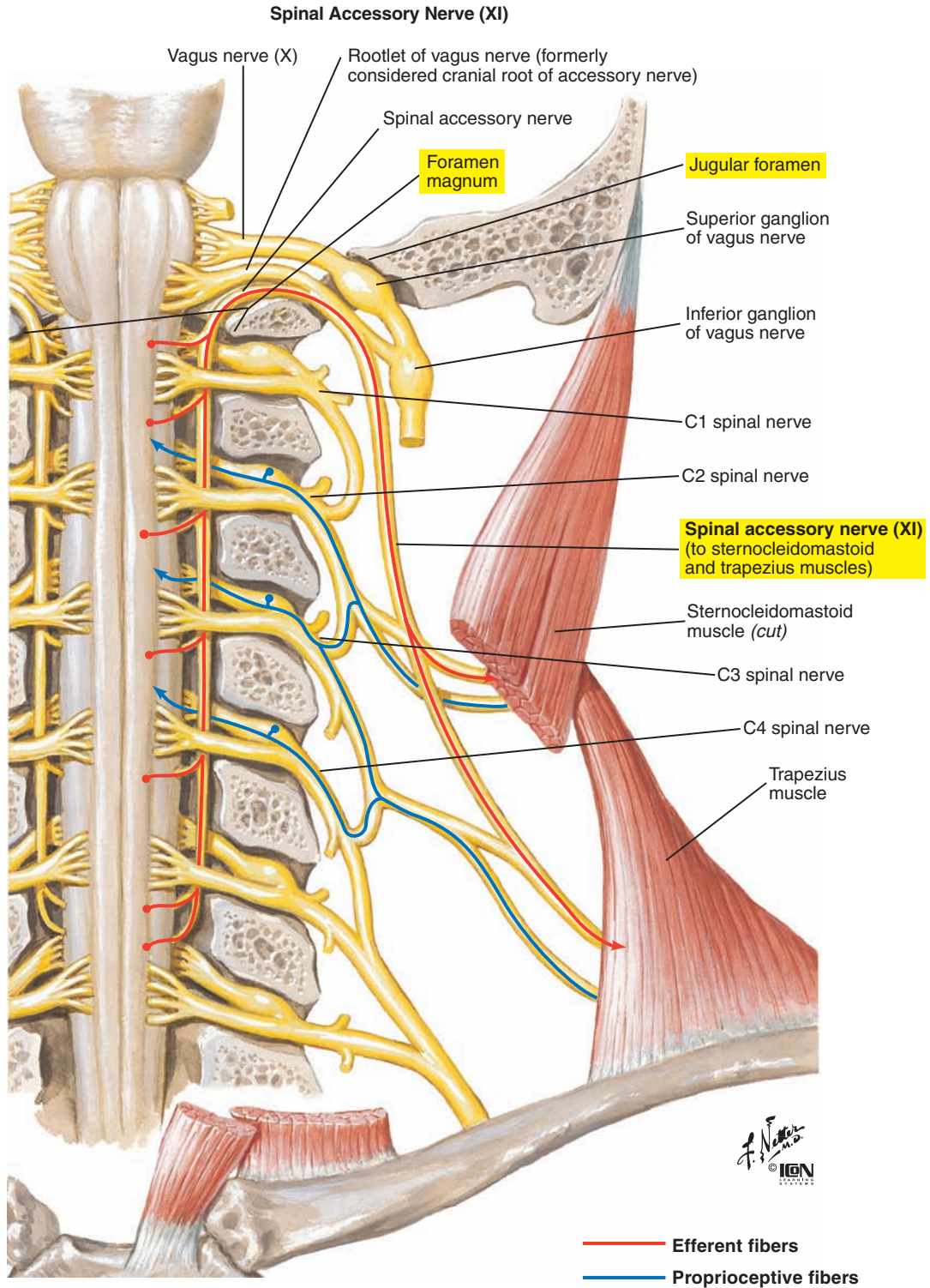
**Vagus Nerve (X)****Figure 5-25.** The vagus nerve (X).

**XI Spinal Accessory (Motor)** (Figure 5-26)

The spinal accessory nerve arises from the upper five or six cervical segments of the spinal cord (spinal nucleus of accessory nerve), and enters the skull through the foramen magnum. The nerve exits through the jugular foramen, between the temporal bone and the occipital bone.

Function is branchial motor: to the trapezius and sternocleidomastoid muscles.





**Figure 5-26.** The spinal accessory nerve (XI).

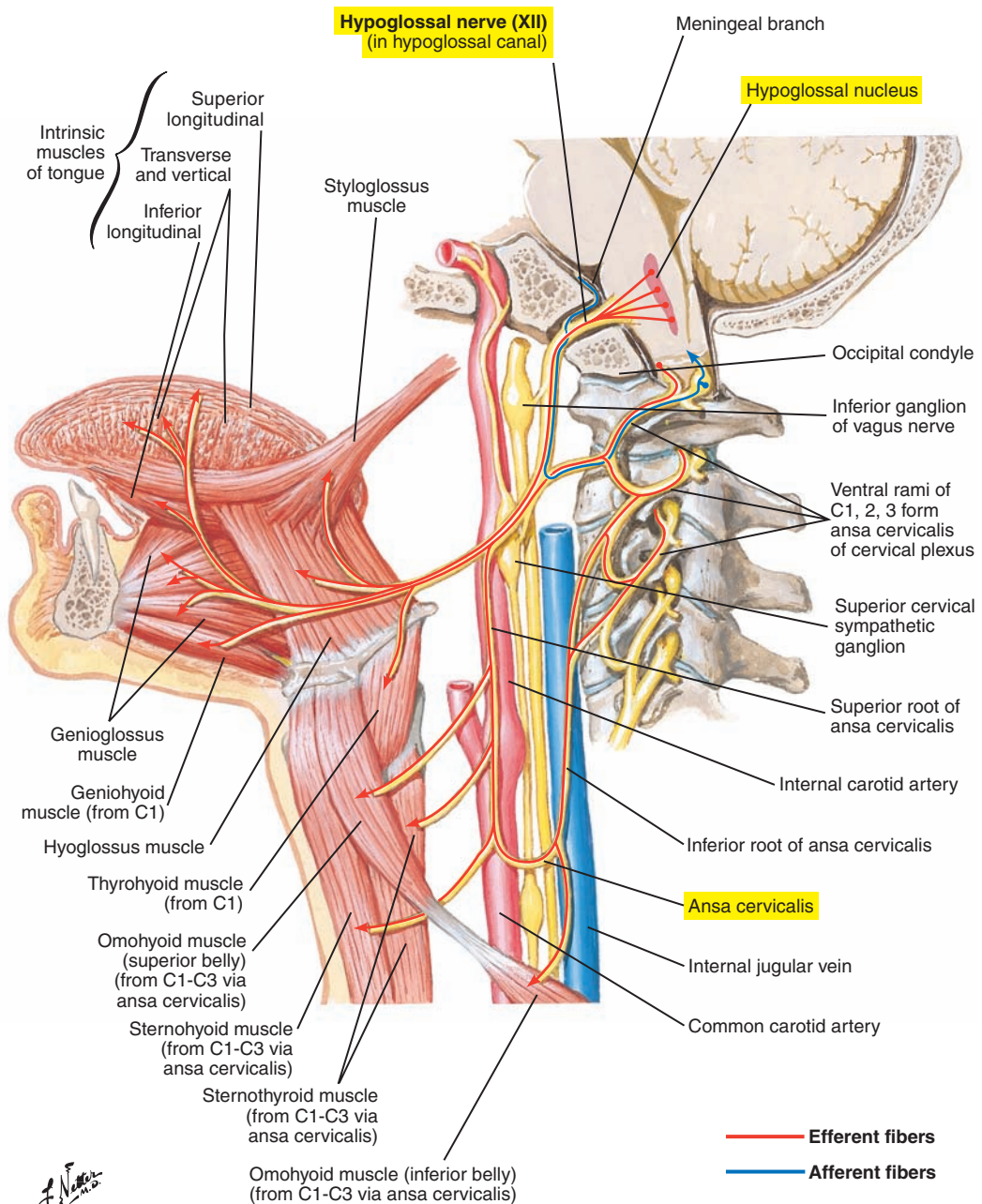


**XII Hypoglossal (Motor)** (Figure 5-27)

The hypoglossal nerve originates from the hypoglossal nucleus located in the medulla and innervates muscles of the tongue. The brain exit point of the hypoglossal is the myelencephalon (medulla), and the cranial exit point is the hypoglossal canal in the occipital bone.

Function is branchial motor: to all intrinsic muscles of the tongue and three of the four extrinsic muscles of the tongue—genioglossus, hyoglossus, and styloglossus. The fourth muscle, the palatoglossus, is supplied by the vagus nerve.

The omohyoid, sternohyoid, and sternothyroid muscles are innervated by cervical nerves C1-C3 (via the ansa hypoglossi or ansa cervicalis). The geniohyoid and thyrohyoid muscles are innervated by C1 nerves, not via ansa cervicalis. The nerve fibers to these muscles can be found coursing with the hypoglossal nerve.



**Figure 5-27.** The hypoglossal nerve (XII) and associated cervical spinal nerves C1-C3.

### Summary of Cranial Nerves Significant to Speech, Mastication/Swallowing, and Hearing

Cranial Nerve	Structure Supplied
<p>V Trigeminal (sensory/motor) (see <a href="#">Figure 5-21</a> [p. 241])</p> <p>Three divisions:</p> <ol style="list-style-type: none"> <li>1. Ophthalmic</li> <li>2. Maxillary</li> <li>3. Mandibular</li> </ol>	<p><i>Sensory:</i> from the face, mouth, palate, teeth, nasal cavity, and anterior two-thirds of the tongue</p> <p><i>Motor:</i> to the muscles of mastication (except the posterior belly of the digastric and geniohyoid), the mylohyoid, the tensor veli palatini, and the tensor tympani</p>
VII Facial (sensory/motor) (see <a href="#">Figure 5-22</a> [p. 243])	<p><i>Motor:</i> to muscles of facial expression and nasal muscles, posterior belly of the digastric, stylohyoid, and stapedius muscle; responsible for facial muscle tone</p> <p><i>Secretory:</i> for the lacrimal, submandibular, and sublingual glands and mucous membranes for palate and nose</p> <p><i>Taste:</i> from anterior two-thirds of the tongue</p>
VIII Vestibulocochlear (sensory) (see <a href="#">Figure 5-23</a> [p. 245])	<i>Sensory:</i> from auditory (cochlear branch) and equilibrium (vestibular branch) receptors
IX Glossopharyngeal (sensory/motor) (see <a href="#">Figure 5-24</a> [p. 247])	<p><i>Sensory:</i> from the posterior one-third of the tongue, pharynx, tonsils, internal surface of tympanic membrane, tympanic cavity, pharyngo-tympanic tube</p> <p><i>Motor:</i> to the stylopharyngeus muscle</p> <p><i>Secretory:</i> for the parotid gland</p> <p><i>Taste:</i> from the posterior one-third of the tongue</p>
X Vagus (sensory/motor) (see <a href="#">Figure 5-25</a> [p. 249])	<p><i>Sensory:</i> from larynx and pharynx, thorax, abdomen, external surface of tympanic membrane, part of external ear and external acoustic meatus</p> <p><i>Motor:</i> to intrinsic laryngeal, pharyngeal (except stylopharyngeus), soft palate (except tensor veli palatini), and esophageal muscles</p> <p><i>Taste:</i> from the epiglottic region and the root of the tongue</p>
XI Spinal accessory (motor) (see <a href="#">Figure 5-26</a> [p. 251])	<i>Motor:</i> to trapezius and sternocleidomastoid
XII Hypoglossal (motor) (see <a href="#">Figure 5-27</a> [p. 253])	<i>Motor:</i> to all intrinsic and most extrinsic muscles of the tongue (except the palatoglossus)

# INDEX

## A

Abdomen, bony framework of, 33f  
Abdominal muscles, 60f  
Abdominal wall, 60f, 64f, 68f  
Abducens (motor) nerves, 242  
Abduction  
    and adduction, 12  
    of vocal folds, 77, 88f  
Accessory muscles, of inspiration, 58, 59f, 66t  
Accessory (motor) nerves, 250, 251f, 254t  
Acoustic reflex (AR), of middle ear muscles,  
    activation of, 182  
Adduction  
    and abduction, 12  
    of vocal folds, 77  
Adipose connective tissue, 15  
Afferent and efferent innervation, cochlear, 196–200  
Afferent central auditory pathway, 197, 198f, 199f  
Afferent innervation, 196  
    inner radial, or type I, fibers, 196  
    outer spiral, or type II, fibers, 196  
Agranular cells, in motor areas, 205  
Airways, intrapulmonary, 41f  
Alveolar dead space, 72  
Alveolar ventilation, 72  
Anatomical dead space, 72  
Anatomical divisions, of ear, 174–193, 175f  
    inner ear and vestibular system, 186–190  
    middle ear, 180–184  
    outer ear, 175f, 176–178  
    scala media, or cochlear duct, 192–193, 194f, 195f  
Anatomical movement, 5f, 12  
Anatomical position, 3, 5f  
Anatomical terms, 5f, 6–10  
    anterior and posterior, 6, 8f  
    external, internal, and intermediate, 10  
    ipsilateral, contralateral, and bilateral, 10  
    medial, lateral, and median, 6, 9f  
    parietal and visceral, 10, 11f  
    prone and supine, 10  
    proximal and distal, 10  
    superior and inferior, 6, 7f  
Anatomy  
    clinical, 2  
    developmental, 2  
    functional, 2  
    nomenclature of, 3  
    regional, 2  
    systemic, 2  
    types of, 2  
    views and aspects of, 10  
    vocabulary specific to, 13  
Angular muscles, 136  
    depressor labii inferioris muscle, 135f, 136, 137f,  
        164–165t  
    levator labii superioris, 136, 137f, 164–165t  
    levator labii superioris alaeque nasi, 136, 137f,  
        164–165t  
    zygomaticus major, 136, 137f, 164–165t  
    zygomaticus minor, 136, 137f, 164–165t

Anterior and posterior views, 6, 8f  
Aortic hiatus, 49  
Apex, of lungs, 42  
Aponeuroses, 16  
Arachnoid mater, 224  
Arbor vitae, 220  
Arteries  
    of brain, 230f, 231f, 232f  
    internal carotid, 229  
    vertebral, 229  
Articulatory system. *see* Oropharyngeal-articulatory  
    system  
Arytenoid cartilages, 78, 80  
Arytenoid muscle. *see* Interarytenoid (arytenoid)  
    muscle  
Aspiration pneumonia, 46  
Auditory centrifugal pathway, 200  
Auditory system, 171–200  
    anatomical divisions of, 174–193, 175f  
    inner ear and vestibular system, 186–190  
    middle ear, 180–184  
    outer ear, 175f, 176–178  
    scala media, or cochlear duct, 192–193,  
        194f, 195f  
    cochlear afferent and efferent innervation,  
        196–200  
    afferent central auditory pathway, 197,  
        198f, 199f  
    afferent innervation, 196  
    efferent central auditory pathway (auditory  
        centrifugal pathway), 200  
    overview of, 173  
Auditory tube, 181f, 184, 185f  
Auricle or pinna, 175f, 176, 177f

## B

Back, muscles of, 53f, 63f, 71f  
Basal ganglia, 212, 213f  
Basal nuclei. *see* Basal ganglia  
Base, of lungs, 42  
Basilar membrane, 192–193  
Betz cell, 205  
Bilateral, ipsilateral, and contralateral views, 10  
Blood, 16  
    supply of, vocal fold relating to, 91  
Bones. *see also* Cranial anatomy  
    hyoid, 81f, 83  
    lacrimal, 114  
    nasal, 114  
    palatine, 114  
    terms relative to, 17–20  
        depressions, 12, 17, 17f, 18f, 19f  
        elevations, 17f, 18f, 20, 21f  
    zygomatic, 118  
Bony framework  
    of abdomen, 33f  
    of thorax, 31f  
Bony pelvis, 32, 33f  
Brain, arteries of, 230f, 231f, 232f  
Brainstem pattern-generating circuitry, 216

Broca's area, 207  
 Bronchi, 38, 39f, 40f  
 Bronchioles, respiratory, 41f  
 Bronchopulmonary segments, of lungs, 42  
 Buccinator muscle, 134, 135f, 164–165t

## C

Caninus muscle, 135f, 138  
 Capacities. *see* Respiratory capacities  
 Cardiac muscles, 16  
 Cartilage(s), 8f, 15–16, 30, 31f  
   aponeuroses, 16  
   arytenoid, 78, 80  
   corniculate (Santorini's), 78, 82  
   cricoid, 78, 80  
   cuneiform, 78, 82  
   elastic, 15, 78  
   epiglottis, 78, 82  
   fascia, 16  
   fibrocartilage, 15  
   hyaline, 15, 78  
   of larynx, 80–82, 81f  
   ligaments, 16  
   membranes, 16  
   of nasal cavities, 122  
   tendons, 16  
   thyroid, 78, 80  
   triteal (tritiate), 78, 82  
 Cavities. *see* Nasal cavities; Pharyngeal cavity;  
   Tympenic cavity; Tympenic cavity proper  
 Cells. *see* Organ of Corti  
 Central pattern generators (CPGs), 216  
 Cerebellum, 220, 221f, 222f, 223f. *see also*  
   Metencephalon (pons and cerebellum)  
   characteristic features of, 220  
   speech and swallowing, importance for, 220  
 Cerebral hemispheres. *see* Telencephalon (cerebral  
   hemispheres or cerebrum and basal ganglia)  
 Cerebral lobes, 206, 209f  
 Cerebral vasculature, 229, 230f, 231f, 232f  
 Cerebrocerebellum, 220  
 Cerebrospinal fluid, 226, 227f, 228f  
 Cerebrum. *see* Telencephalon (cerebral hemispheres  
   or cerebrum and basal ganglia)  
 Cingulate gyrus, 207  
 Cingulum. *see* Cingulate gyrus  
 Circle of Willis, 229, 233f  
 Class I malocclusion, 133  
 Class I neutral occlusion, 133  
 Class II ("overbite") malocclusion, 133  
 Class III ("underbite") malocclusion, 133  
 Clinical anatomy, 2  
 Coccygeal vertebrae, 28  
 Coccyx, 32  
 Cochlea, 186–190  
 Cochlear afferent and efferent innervation, 196–200  
   afferent central auditory pathway, 197, 198f, 199f  
   afferent innervation, 196  
   efferent central auditory pathway (auditory  
     centrifugal pathway), 200  
 Cochlear duct. *see* Scala media, or cochlear duct  
 Cochlear labyrinth, membranous, 187f, 190  
 Conchae, of nasal cavities, 122  
 Connective tissue, 14–16  
   blood, 16  
   osseous, 16  
   proper, 15  
   specialized, 8f, 15–16  
 Connective tissue proper, 15  
   adipose, 15  
   dense, 15  
   elastic, 15  
   loose, 15  
 Contralateral, ipsilateral, and bilateral views, 10  
 Conus elasticus, cricovocal, lateral cricothyroid  
   ligament or membrane, 84  
 Corniculate (Santorini's) cartilages, 78, 82  
 Coronal plane, 4  
 Corpora quadrigemina, 215  
 Costal part, of diaphragm, 49  
 Costochondral junctions, 52  
 Cranial anatomy, 110–118  
   cranium, 110, 111f, 112f, 113f  
     paired bones of, 110  
     unpaired bones of, 110  
   facial skeleton, 114–118, 115f, 116f, 117f  
     paired bones of, 114–118  
     unpaired bones of, 114  
   sinuses, 118  
 Cranial base, 110  
 Cranial nerve fibers, types of, 236, 237f  
   motor, 236  
   sensory, 236  
 Cranial nerves, 217f, 234–254, 235f, 237f, 241f, 253f  
   I olfactory (sensory), 238  
   II optic (sensory), 238  
   III oculomotor (motor), 239  
   IV trochlear (motor), 239  
   V trigeminal (motor and sensory), 240, 241f,  
     254t  
   VI abducens (motor), 242  
   VII facial (motor and sensory), 242, 243f, 254t  
   VIII vestibulocochlear (sensory), 244, 245f, 254t  
   IX glossopharyngeal (motor and sensory), 246,  
     247f, 254t  
   X vagus, or pneumogastric, nerve (motor and  
     sensory), 248, 249f, 254t  
   XI accessory (motor), 250, 251f, 254t  
   XII hypoglossal (motor), 252–254, 253f, 254t  
     speech, mastication/swallowing, hearing relating  
       to, 254t  
 Cranial vault, 110  
 Cranium, 110, 111f, 112f, 113f  
   paired bones of, 110  
   unpaired bones of, 110  
 Cricoarytenoid joints, 83  
 Cricoarytenoid muscle, 100t  
   lateral, 95  
   posterior, 94  
 Cricoid cartilages, 78, 80  
 Cricopharyngeal muscle, 98  
 Cricopharyngeal sphincter. *see* Upper esophageal,  
   or cricopharyngeal sphincter



Cricothyroid joints, 83  
 Cricothyroid muscle, 94  
 Cricotracheal membrane, 84  
 Cricovocal, conus elasticus, lateral cricothyroid ligament or membrane, 84  
 Crura, 49  
 Cuneiform cartilages, 78, 82

## D

Deep tissue layer, of vocal fold, 90  
 Deglutition, 203  
 Dense connective tissue, 15  
 Dental occlusion, 133  
 Depressions, 12, 17, 17f, 18f, 19f  
 Depressor anguli oris muscle, 135f, 137f, 138, 164–165t  
 Depressor labii inferioris muscle, 135f, 136, 137f, 164–165t  
 Depressor septi muscle, 164–165t  
 Developmental anatomy, 2  
 Diaphragm, 49, 50f, 51f  
   costal part, 49  
   lumbar, 49  
   sternal part, 49  
 Diencephalon (thalamus, hypothalamus, epithalamus, and subthalamus), 213f, 214  
   characteristic features of, 214  
   speech and swallowing, importance for, 214  
 Digastric muscle, 98, 99f, 102t, 148, 150f, 151f, 167t  
 Distal and proximal views, 10  
 Dura mater, 224

## E

Ear. *see* Auditory system  
 Ear canal or external auditory (acoustic) meatus, 178  
 Eardrum, 178, 179f  
 Efferent and afferent innervation, cochlear, 196–200  
 Efferent central auditory pathway (auditory centrifugal pathway), 200  
 Elastic cartilage, 15, 78  
 Elastic connective tissue, 15  
 Elevations, bones relating to, 17f, 18f, 20, 21f  
 Epiglottis, 78, 82  
 Epithalamus. *see* Diencephalon (thalamus, hypothalamus, epithalamus, and subthalamus)  
 Epithelial tissue, 14  
 Epithelium, of vocal fold, 90  
 Epitympanic recess, 180  
 Esophageal hiatus, 49  
 Esophagus, 160, 161f, 162f, 163f  
   lower esophageal sphincter, 160  
   primary esophageal peristalsis, 160  
   upper esophageal, or cricopharyngeal sphincter, 160  
 Eustachian tube, 181f, 184, 185f  
 Expiration, muscles of, 58–62, 60f, 69t  
   external oblique muscle, 54f, 62, 63f, 64f, 70f  
   internal (interosseous) intercostal muscles, 55f, 57f, 58, 61f

Expiration, muscles of (*Continued*)  
   internal oblique muscle, 54f, 59f, 62, 64f  
   rectus abdominis muscle, 54f, 58  
   transversus abdominis muscle, 57f, 59f, 62  
 Expiratory reserve volume, 72  
 Extension and flexion, 12  
 External, internal, and intermediate views, 10  
 External auditory (acoustic) meatus or ear canal, 178  
 External intercostal muscles, 52, 53f, 54f, 55f  
 External oblique muscle, 54f, 62, 63f, 64f, 69t, 70f  
 Extrinsic ligaments and membranes, of laryngeal-phonatory system, 84  
   cricotracheal membrane, 84  
   hyoepiglottic ligament, 84  
   thyrohyoid (hyothyroid) ligament, 84  
 Extrinsic muscles, of larynx, 96, 105f  
   cricopharyngeal, 98  
   infrahyoid, 96, 97f, 103t, 104f  
     omohyoid, 96  
     sternohyoid, 96  
     sternothyroid, 96  
     thyrohyoid, 96  
   suprahyoid or laryngeal elevators, 98, 99f, 102t, 104f  
     digastric, 98, 148, 150f, 151f  
     geniohyoid, 98, 149, 151f  
     hyoglossus, 151f  
     mylohyoid, 98, 149, 150f, 151f  
     stylohyoid, 98  
 Extrinsic muscles, of tongue, 142, 143f, 166t

## F

Facial expression and lips, muscles of, 134–138, 135f, 137f, 164–165t  
   angular, 136  
   orbicularis oris, 134  
   transverse, 134  
   vertical, 138  
 Facial (motor and sensory) nerves, 242, 243f, 254t  
 Facial skeleton, 114–118, 115f, 116f, 117f  
   paired bones of, 114–118  
   unpaired bones of, 114  
 Fascia, 16  
 Fibrocartilage, 15  
 Fissure of Rolando, 206, 209f  
 Fissure of Sylvius, 206, 209f  
 Flexion and extension, 12  
 Formant frequencies, 109  
 Frenulum, lingual, 126  
 Frontal or coronal plane, 4  
 Functional anatomy, 2  
 Functional residual capacity, 72

## G

Geniohyoid muscle, 98, 99f, 102t, 149, 151f, 167t  
 Girdle. *see* Skeletal support, for respiratory system  
 Glossopharyngeal (motor and sensory) nerves, 246, 247f, 254t  
 Glossus. *see* Tongue  
 Granular cells, in primary sensory areas, 205

**H**

- Habenula perforata, 196
- Hearing, speech and mastication/swallowing, cranial nerves relating to, 254t
- Heart in situ, 47f
- Heschl's gyrus, 212
- Hip bone, 32
- Homunculus, 207
- Horizontal or transverse plane, 4
- Hyaline cartilage, 15, 78
- Hyoepiglottic ligament, 84
- Hygoglossus muscle, 99f, 151f
- Hyoid bone, of laryngeal-phonatory system, 81f, 83
- Hypoglossal (motor) nerves, 252–254, 253f, 254t
- Hypothalamus. *see* Diencephalon (thalamus, hypothalamus, epithalamus, and subthalamus)

**I**

- Important sulci, 206, 208f, 209f, 210f
- Incus ("anvil"), 182
- Inferior and superior views, 6, 7f
- Inferior laryngeal nerve, 92
- Inferior nasal conchae, 118
- Inferior pharyngeal constrictor muscle, 155, 156f, 169t
- Infrahyoid muscles, 96, 97f, 103t, 104f
  - omohyoid, 96
  - sternohyoid, 96
  - sternothyroid, 96
  - thyrohyoid, 96
- Inner ear and vestibular system, 186–190
  - membranous cochlear labyrinth, 187f, 190
  - membranous labyrinth, 187f, 190, 191f, 194f
  - osseous or bony labyrinth, 175f, 181f, 186, 187f, 188f, 189f
- Inner hair cells, 193
- Inner radial, or type I, fibers, 196
- Innervation. *see also* Auditory system
  - cochlear afferent and efferent, 196–200
  - vocal fold relating to, 91
- Inspiration
  - accessory muscles of, 58, 59f, 66t
  - primary muscles of, 65t
  - principal muscles of, 49–56
- Inspiratory capacity, 72
- Inspiratory reserve volume, 72
- Interarytenoid (arytenoid) muscle, 95, 100t
- Interchondral intercostal muscle, 56, 57f
- Intermediate, external, and internal views, 10
- Intermediate tissue layer, of vocal fold, 90
- Internal, external, and intermediate views, 10
- Internal carotid arteries, 229
- Internal intercostal muscles
  - interosseous, 55f, 57f, 58, 61f, 69t
  - parasternal, 56, 57f, 61f, 64f
- Internal oblique muscle, 54f, 59f, 62, 64f, 69t
- Internal structures
  - of spinal cord, 218
  - of telencephalon, 212
- Interosseous intercostal muscles. *see* Internal intercostal muscles
- Intrapulmonary airways, 41f

- Intrinsic ligaments and membranes, of laryngeal-phonatory system, 84, 85f
  - conus elasticus, cricovocal, or lateral cricothyroid, 84
  - quadrangular membrane, 84

**Intrinsic muscles**

- of larynx, 87f, 92–95, 93f, 100t
    - cricothyroid, 94
    - interarytenoid (arytenoid), 95
    - lateral cricoarytenoid, 95
    - posterior cricoarytenoid, 94
    - thyroarytenoid, 92
  - of tongue, 140, 141f, 166t
- Ipsilateral, contralateral, and bilateral views, 10

**J**

- Jaw-closing muscles, 146, 166t, 167t
  - masseter, 135f, 146
  - medial (internal) pterygoid, 146, 147f
  - temporalis, 135f, 146
- Jaw depressors. *see* Jaw-opening muscles
- Jaw elevators. *see* Jaw-closing muscles
- Jaw-opening muscles, 148–149, 167t
  - digastric, 148, 150f, 151f
  - geniohyoid, 149, 151f
  - lateral (external) pterygoid, 147f, 148
  - mylohyoid, 149, 150f, 151f
- Joints
  - of laryngeal-phonatory system, 81f, 83
    - cricoarytenoid, 83
    - cricothyroid, 83
  - temporomandibular, 144, 145f

**L**

- Lacrimal bones, 114
- Lamina propria, 90
- Laryngeal elevators. *see* Suprahyoid muscles (laryngeal elevators)
- Laryngeal-phonatory system
  - hyoid bone of, 81f, 83
  - joints of, 81f, 83
  - larynx, 75–106
    - cartilages of, 80–82, 81f
    - ligaments and membranes of, 81f, 84
    - overview of, 77
    - vocal folds, 78, 86–91, 87f, 88f
      - tissue layers of, 86–90
- Laryngopharynx, 119
- Larynx, 78, 89f
  - cartilages of, 80–82, 81f
    - arytenoid, 78, 80
    - corniculate (Santorini's), 78, 82
    - cricoid, 78, 80
    - cuneiform, 78, 82
    - epiglottis, 78, 82
    - thyroid, 78, 80
    - triticeal (tritiante), 78, 82
  - muscles of, 92
    - extrinsic, 96, 105f
    - intrinsic, 87f, 92–95, 93f, 100t
  - phonatory system relating to, 75–106
  - position of, 79f
  - respiratory tract relating to, 34, 37f

Lateral, medial, and median views, 6, 9f  
 Lateral cricoarytenoid muscle, 95, 100t  
 Lateral (external) pterygoid muscle, 147f, 148, 167t  
 Lateral olivocochlear bundle fibers, 200  
 Latissimus dorsi muscle, 63f, 69t  
 Lenticular nucleus, 212  
 Lentiform nucleus, 212  
 Leptomeninges, 224  
 Levator anguli oris muscle, 135f, 138, 164–165t  
 Levator labii superioris alaeque nasi muscle, 136, 137f, 164–165t  
 Levator labii superioris muscle, 136, 137f, 164–165t  
 Levator veli palatini muscle, 152, 153f, 168t  
 Ligaments, 16  
   membranes and, of laryngeal-phonatory system, 81f, 84, 85f  
   extrinsic, 84  
   intrinsic, 84  
 Lingual frenulum, 126  
 Lips, 125f, 128  
   facial expression and, muscles of, 134–138, 135f, 137f, 164–165t  
   angular, 136  
   orbicularis oris, 134  
   transverse, 134  
   vertical, 138  
 Lobar bronchi, 38, 39f, 40f  
 Longitudinal cerebral fissure, 206  
 Loose connective tissue, 15  
 Lower esophageal sphincter, 160  
 Lumbar part, of diaphragm, 49  
 Lungs, 42, 43f, 45f  
   apex of, 42  
   base of, 42  
   bronchopulmonary segments of, 42  
   left, 42, 45f  
   mediastinum of, 42  
   right, 42, 45f  
   total capacities of, 72  
   volumes and subdivisions, 73f  
 Lungs-thorax unit, 46

## M

Malleus (“hammer”), 182  
 Mandible, 114  
 Mandibular (sensory and motor) nerves, 240  
 Masseter muscle, 135f, 146, 167t  
 Mastication, muscles of, 144–149  
   jaw-closing, 146, 167t  
   jaw-opening, 148–149, 167t  
   temporomandibular joint, 144, 145f  
 Mastication/swallowing, speech, hearing, cranial nerves relating to, 254t  
 Maxilla, 114  
 Maxillary (sensory) nerves, 240  
 Medial, lateral, and median views, 6, 9f  
 Medial (internal) pterygoid muscle, 146, 147f, 167t  
 Medial olivocochlear bundle fibers, 200  
 Median, lateral, and medial views, 6, 9f  
 Mediastinum, 42  
 Medulla oblongata. *see* Myelencephalon (medulla oblongata)  
 Membranes, 16  
   basilar, 192–193  
   cricotracheal, 84  
   ligaments and, of laryngeal-phonatory system, 81f, 84  
   quadrangular, 84, 85f  
   Reissner’s, 192  
   tectorial, 193  
   tympanic, 178, 179f  
 Membranous cochlear labyrinth, 187f, 190  
 Membranous labyrinth, 187f, 190, 191f, 194f  
 Meninges, 224, 225f  
   arachnoid mater, 224  
   dura mater, 224  
   pia mater, 224  
 Mentalis muscle, 135f, 137f, 138, 164–165t  
 Mesencephalic trigeminal pathway, 240  
 Mesencephalon (midbrain), 208f, 210f, 215  
   characteristic features of, 215  
   speech and swallowing, importance for, 215  
 Metencephalon (pons and cerebellum), 208f, 216, 217f  
   characteristic features of, 216  
   speech and swallowing, importance for, 216  
 Midbrain. *see* Mesencephalon (midbrain)  
 Middle ear, 180–184  
   muscles of, 181f, 182, 183f  
   action of, 182  
   stapedial muscle or stapedius, 182  
   tensor tympani, 182  
   pharyngotympanic (Eustachian, auditory) tube, 181f, 184, 185f  
   tympanic cavity, 175f, 179f, 180–182, 181f  
 Middle ear ossicles, 181f, 182, 183f  
   incus (“anvil”), 182  
   malleus (“hammer”), 182  
   stapes (“stirrup”), 182  
 Middle pharyngeal constrictor muscle, 155, 156f, 169t  
 Minute ventilation, 72  
 Modiolus, 186  
 Motoneurons  
   lower, 205  
   upper, 205  
 Motor cortex, primary, 207  
 Motor nerve fibers, 236  
 Motor nerves. *see* Cranial nerves  
 Motor units, 234  
 Muscles. *see also* Respiratory muscles  
   of back, 53f, 63f, 71f  
   buccinator, 134, 135f  
   depressor anguli oris, 135f, 137f, 138  
   depressor labii inferioris, 135f, 136, 137f  
   fibers, 52, 53f, 54f  
   of larynx, 92, 97f  
   extrinsic, 96, 102t, 103t, 105f  
   intrinsic, 87f, 92–95, 93f, 100t  
   levator anguli oris, 135f, 138  
   levator labii superioris, 136, 137f  
   levator labii superioris alaeque nasi, 136, 137f  
   of lips and facial expression, 134–138, 135f, 137f, 164–165t  
   angular, 136

**Muscles** (*Continued*)

- orbicularis oris, 134
- transverse, 134
- vertical, 138
- masseter, 135f, 146
- of mastication, 144–149, 167t
  - jaw-closing, 146
  - jaw-opening, 148–149
  - temporomandibular joint, 144, 145f
- mentalis, 135f, 137f, 138
- of neck, 139
- palatopharyngeus, 153f, 154
- of pharynx, 155–157, 169t
  - inferior pharyngeal constrictor, 155, 156f
  - middle pharyngeal constrictor, 155, 156f
  - salpingopharyngeus, 157, 158f
  - stylopharyngeus, 156f, 157, 159f
  - superior pharyngeal constrictor, 155, 156f
  - velopharyngeal mechanism, 157
- platysma, 137f, 139
- pterygoid
  - lateral (external), 147f, 148
  - medial (internal), 146, 147f
- risorius, 134, 137f
- of soft palate, 152–154, 153f, 168t
  - levator veli palatini, 152, 153f
  - palatoglossus (glossopalatine), 153f, 154
  - palatopharyngeus, 153f, 154
  - tensor veli palatini, 152, 153f
  - uvular, 153f, 154
- temporalis, 135f, 146
- thyroarytenoid, 90
- of tongue, 127f, 140–142, 166t
  - extrinsic, 142, 143f
  - intrinsic, 140, 141f
- zygomaticus
  - major, 136, 137f
  - minor, 136, 137f
- Muscular tissue, 16
  - cardiac, 16
  - skeletal, 16
  - smooth, 16
- Musculus uvulae. *see* Uvular muscle
- Myelencephalon (medulla oblongata), 208f, 216, 217f
  - brainstem pattern-generating circuitry, 216
  - characteristic features of, 216
  - speech and swallowing, importance for, 216
- Mylohyoid muscle, 98, 99f, 102t, 149, 150f, 151f, 167t

**N**

- Nasal bones, 114
- Nasal cavities
  - cartilages of, 122
  - of respiratory tract, 34, 35f
  - of vocal tract, 122, 123f
- Nasalis compressor naris muscle, 164–165t
- Nasalis dilator naris muscle, 164–165t
- Nasopharynx, 119
- Neck, muscles of, 139, 164–165t
  - platysma, 137f, 139

**Nerves.** *see* also Cranial nerves

- mandibular, 240, 254t
- maxillary, 240, 254t
- ophthalmic, 240, 254t
- recurrent laryngeal, 91
- vestibulocochlear, 198f
- Nervous system, 201–254
  - cerebellum, 220, 221f, 222f, 223f
  - cerebral vasculature, 229, 230f, 231f, 232f
  - cerebrospinal fluid, 226, 227f, 228f
  - cranial nerves, 217f, 234–254, 235f, 237f, 241f, 253f
  - diencephalon (thalamus, hypothalamus, epithalamus, and subthalamus), 213f, 214
  - meninges, 224, 225f
  - mesencephalon (midbrain), 208f, 210f, 215
  - metencephalon (pons and cerebellum), 208f, 216, 217f
  - myelencephalon (medulla oblongata), 208f, 216, 217f
  - neuroanatomical terms of direction, 204, 204f
  - overview of, 203, 203f
  - spinal cord, 218, 219f
  - telencephalon (cerebral hemispheres or cerebrum and basal ganglia), 205–212
- Nervous tissue, 16
- Neuroanatomical terms of direction, 204, 204f
- Nomenclature, of anatomy, 3
- Nose, muscles of, 164–165t

**O**

- Oculomotor (motor) nerves, 239
- Olfactory (sensory) nerves, 238
- Omoxyoid muscle, 96, 97f, 103t
- Ophthalmic (sensory) nerves, 240
- Optic (sensory) nerves, 238
- Oral cavity, 34, 124, 125f
- Orbicularis oris muscle, 134, 164–165t
- Organ of Corti, 193
  - inner hair cells, 193
  - outer hair cells, 193
  - supporting cells, 193
  - tectorial membrane, 193
- Oropharyngeal-articulatory system, 107–170
  - cranial anatomy, 110–118
  - esophagus, 160, 161f, 162f, 163f
  - muscles
    - of lips and facial expression, 134–138, 135f, 137f, 164–165t
    - of mastication, 144–149, 167t
    - of neck, 139
    - of pharynx, 155–157, 169t
    - of soft palate, 152–154, 153f, 168t
    - of tongue, 127f, 140–142, 166t
  - overview of, 109
  - vocal tract, 119–133
- Oropharynx, 119
- Osseous or bony labyrinth, 175f, 181f, 186, 187f, 188f, 189f
  - cochlea, 186
  - semicircular canals, 186
  - vestibule, 186

Osseous tissue, 16  
 Outer ear, 175f, 176–178  
   auricle or pinna, 175f, 176, 177f  
   external auditory (acoustic) meatus or ear canal, 178  
   tympanic membrane, tympanum, or eardrum, 178, 179f  
 Outer hair cells, 193  
 Outer spiral, or type II, fibers, 196

## P

Paired bones  
   of cranium, 110  
   of facial skeleton, 114–118  
 Palate, 120f, 126  
 Palatine bones, 114  
 Palatoglossus (glossopalatine) muscle, 153f, 154, 166t, 168t  
 Palatopharyngeus muscle, 153f, 154, 168t  
 Parietal and visceral views, 10, 11f  
 Pectoral, scapular, or shoulder girdle, 30, 31f  
 Pectoralis major muscle, 54f, 66t  
 Pectoralis minor muscle, 57f, 66t  
 Pelvic girdle or bony pelvis, 32, 33f  
 Pelvis, bony, 32, 33f  
 Pharyngeal cavity, 119, 120f, 121f  
   laryngopharynx, 119  
   nasopharynx, 119  
   oropharynx, 119  
 Pharyngotympanic (eustachian, auditory) tube, 181f, 184, 185f  
 Pharynx, 34, 36f  
   muscles of, 155–157, 169t  
     inferior pharyngeal constrictor, 155, 156f  
     middle pharyngeal constrictor, 155, 156f  
     salpingopharyngeus, 157, 158f  
     stylopharyngeus, 156f, 157, 159f  
     superior pharyngeal constrictor, 155, 156f  
     velopharyngeal mechanism, 157  
 Phonatory system. *see* Laryngeal-phonatory system  
 Phrenic nerve, 44f  
 Physiological dead space, 72  
 Pia mater, 224  
 Pinna or auricle, 175f, 176, 177f  
 Planes and sections, 4, 5f  
   frontal or coronal, 4  
   sagittal, 4  
   transverse or horizontal, 4  
 Platysma muscle, 137f, 139, 164–165t  
 Pleura, 44f, 46, 47f  
 Pleural space, 46  
 Pleurisy, 46  
 Pneumonia, 46  
 Pneumothorax, 46  
 Pons. *see* Metencephalon (pons and cerebellum)  
 Pontocerebellum. *see* Cerebrocerebellum  
 Posterior and anterior views, 6, 8f  
 Posterior cricoarytenoid muscle, 94, 100t  
 Premotor cortex, 207  
 Primary esophageal peristalsis, 160  
 Primary muscles, of inspiration, 65t  
 Primary or first-order fibers, 197  
 Primary sensory area, 212

Primary sensory cortex, 212  
 Primary tissues, 14–16  
   connective, 14–16  
   epithelial, 14  
   muscular, 16  
   nervous, 16  
 Principal muscles, of inspiration, 49–56  
   diaphragm, 49, 50f, 51f  
   external intercostal muscles, 52, 53f, 54f, 55f  
   internal parasternal intercostal muscles, 56, 57f, 61f, 64f  
 Pronation and supination, 12  
 Prone and supine views, 10  
 Protrusion and retrusion, 12  
 Proximal and distal views, 10  
 Pulmonary disorders, 46  
   pleurisy, 46  
   pneumonia, 46  
   pneumothorax, 46

## Q

Quadrangular membrane, 84, 85f  
 Quadratus lumborum muscle, 53f, 66t

## R

Rectus abdominis muscle, 54f, 58, 68f, 69t  
 Rectus sheath, 70f  
 Recurrent laryngeal nerves, 91  
 Regional anatomy, 2  
 Reinke's space. *see* Superficial layer (Reinke's space), of vocal fold  
 Reissner's membrane, 192  
 Residual volume, 72  
 Respiratory bronchioles, 41f  
 Respiratory capacities, 72  
   functional residuals, 72  
   inspiratory, 72  
   total lung, 72  
   vital, 72  
 Respiratory muscles, 48–62, 59f  
   expiration, 58–62, 60f, 69t  
     external oblique muscle, 54f, 62, 63f, 64f, 70f  
     internal (interosseous) intercostal muscles, 55f, 57f, 58, 61f  
     internal oblique muscle, 54f, 59f, 62, 64f  
     rectus abdominis muscle, 54f, 58  
     transversus abdominis muscle, 57f, 59f, 62  
   inspiration  
     accessory muscles of, 58, 59f, 66t  
     primary muscles of, 65t  
     principal muscles of, 49–56  
 Respiratory system, 23–74  
   muscles, 48–62, 59f  
   overview of, 25  
   skeletal support for, 26–32, 31f, 33f  
     pectoral, scapular, or shoulder girdle, 30, 31f  
     pelvic girdle or bony pelvis, 32, 33f  
     rib cage, 30, 31f  
     vertebral column, 26–28, 27f  
   speech production relating to, 25  
   swallowing relating to, 25



Respiratory tract, 34–46  
 bronchi, 38, 39f, 40f  
 larynx, 34, 37f  
 lungs, 42, 43f  
 nasal cavities, 34, 35f  
 oral cavity, 34  
 pharynx, 34, 36f  
 pleura, 46, 47f  
 trachea, 38, 39f  
 Respiratory volumes, 72, 73f  
 expiratory reserve, 72  
 inspiratory reserve, 72  
 residual, 72  
 tidal, 72  
 Retrusion and protrusion, 12  
 Rib cage, 30, 31f  
 Risorius muscle, 134, 137f, 164–165t  
 Rolandic fissure, 206, 209f  
 Rotation, associated with temporomandibular joint, 144

## S

Sacrum, 32  
 Sagittal fissure, 206  
 Sagittal planes, 4  
 Salivary glands, 128, 129f  
 Salpingopharyngeus muscle, 157, 158f, 169t  
 Santorini's cartilages. *see* Corniculate (Santorini's) cartilages  
 Scala media, or cochlear duct, 192–193, 194f, 195f  
 basilar membrane, 192–193  
 Reissner's membrane, 192  
 Scalene muscles, 66t, 67f  
 Scapular girdle, 30, 31f  
 Segmental bronchi, 38, 39f, 40f  
 Semicircular canals, 186  
 Sensory nerve fibers, 236  
 Sensory nerves. *see* Cranial nerves  
 Serratus anterior muscle, 54f, 66t  
 Shoulder girdle, 30, 31f  
 Sinuses, 118  
 Skeletal muscles, 16  
 Skeletal support, for respiratory system, 26–32  
 pectoral, scapular, or shoulder girdle, 30, 31f  
 pelvic girdle or bony pelvis, 32, 33f  
 rib cage, 30, 31f  
 vertebral column, 26–28, 27f  
 Skeleton, facial. *see* Facial skeleton  
 Skull, 110  
 Smooth muscles, 16  
 Soft palate, muscles of, 152–154, 153f, 168t  
 levator veli palatini, 152, 153f  
 palatoglossus (glossopalatine), 153f, 154  
 palatopharyngeus, 153f, 154  
 tensor veli palatini, 152, 153f  
 uvular, 153f, 154  
 Somatosensory area, 212  
 Somatosensory cortex, 212  
 Specialized connective tissues, 8f, 15–16  
 Speech  
 mastication/swallowing, hearing and, cranial nerves relating to, 254t

Speech (*Continued*)  
 swallowing and  
 cerebellum relating to, 220  
 diencephalon relating to, 214  
 mesencephalon relating to, 215  
 metencephalon relating to, 216  
 myelencephalon relating to, 216  
 Speech production, respiratory system relating to, 25  
 Spinal cord, 218, 219f  
 characteristic features of, 218  
 internal structures of, 218  
 Spirometry, 73f  
 Stapedial muscle or stapedius, 182  
 Stapes (“stirrup”), 182  
 Stellar cells, 205  
 Sternal part, of diaphragm, 49  
 Sternocleidomastoid muscle, 54f, 66t, 67f  
 Sternohyoid muscle, 96, 97f, 103t  
 Sternothyroid muscle, 96, 97f, 103t  
 Sternum, 30, 31f  
 Stylohyoid muscle, 98, 99f, 102t  
 Stylopharyngeus muscle, 156f, 157, 159f, 169t  
 Subthalamus. *see* Diencephalon (thalamus, hypothalamus, epithalamus, and subthalamus)  
 Superficial layer (Reinke's space), of vocal fold, 90  
 Superior and inferior views, 6, 7f  
 Superior pharyngeal constrictor muscle, 155, 156f, 169t  
 Supination and pronation, 12  
 Supine and prone views, 10  
 Supporting cells, of organ of Corti, 193  
 Suprahyoid muscles (laryngeal elevators), 98, 99f, 102t, 104f  
 Supralaryngeal vocal tract, 109  
 Surface structures, of telencephalon (cerebral hemispheres or cerebrum and basal ganglia), 205–212  
 cerebral lobes, 206, 209f  
 characteristic features of, 205, 210f  
 external surface, 207–212, 209f, 210f, 211f  
 important sulci, 206, 208f, 209f, 210f  
 internal surface, 207, 208f, 213f  
 Swallowing  
 respiratory system relating to, 25  
 speech and  
 cerebellum relating to, 220  
 cranial nerves relating to, 254t  
 diencephalon relating to, 214  
 mesencephalon relating to, 215  
 metencephalon relating to, 216  
 myelencephalon relating to, 216  
 Sylvian fissure, 206, 209f  
 Systemic anatomy, 2

## T

Tectorial membrane, 193  
 Teeth, 130–133, 131f, 132f  
 Tegmen tympani, 180  
 Telencephalon (cerebral hemispheres or cerebrum and basal ganglia), 205–212  
 basal ganglia, 212, 213f  
 internal structures of, 212  
 surface structures of, 205–212  
 cerebral lobes, 206, 209f

Telencephalon (*Continued*)

- characteristic features of, 205, 210f
- external surface, 207–212, 209f, 210f, 211f
- important sulci, 206, 208f, 209f, 210f
- internal surface, 207, 208f, 213f

Temporal operculum, 212

Temporalis muscle, 135f, 146, 167t

Temporomandibular joint, 144, 145f

Tendons, 16

Tensor tympani, 182

Tensor veli palatini muscle, 152, 153f, 168t

Terminal bronchioles, 38, 39f, 40f

Thalamus. *see* Diencephalon (thalamus, hypothalamus, epithalamus, and subthalamus)

Thoracic vertebrae, 29f

Thoracic walls, 54f, 55f, 57f, 61f

Thorax, bony framework of, 31f

Thyroarytenoid muscle, 90, 100t

- body of, 90

- cover of, 90

- transition of, 90

Thyrohyoid (hyothyroid) ligament, 84

Thyrohyoid muscle, 96, 97f, 103t

Thyroid cartilages, 78, 80

Tidal volume, 72

Tissue layers, of vocal folds, 86–90

- blood supply, 91

- deep, 90

- epithelium, 90

- innervation of, 91

- intermediate, 90

- superficial (Reinke's Space), 90

- thyroarytenoid muscle, 90

- visual representation of classifications of, 91f

Tongue, 126, 127f, 129f

- muscles of, 127f, 140–142, 166t

- extrinsic, 142, 143f

- intrinsic, 140, 141f

Tonsils, 120f, 126

Total lung capacity, 72

Trachea, 38, 39f

Translation, associated with temporomandibular joint, 144

Transverse muscles, 134

- buccinator, 134, 135f, 164–165t

- risorius, 134, 137f, 164–165t

Transverse or horizontal plane, 4

Transverse thoracis muscle, 61f, 69t

Transversus abdominis muscle, 57f, 59f, 62, 69t, 71f

Trigeminal (motor and sensory) nerves, 240, 241f, 254t

- mandibular (sensory and motor), 240

- maxillary (sensory), 240

- mesencephalic trigeminal pathway, 240

- ophthalmic (sensory), 240

Triticeal (tritiate) cartilages, 78, 82

Trochlear (motor) nerves, 239

Tube. *see* Auditory tube; Eustachian tube

Tympanic cavity, 175f, 179f, 180–182, 181f

Tympanic cavity proper, 180

Tympanic membrane, tympanum, or eardrum, 178, 179f

Tympanum, 178, 179f

**U**

Umbo, 178

Unpaired bones

- of cranium, 110

- of facial skeleton, 114

Upper esophageal, or cricopharyngeal sphincter, 160

Uvular muscle, 153f, 154, 168t

**V**

Vagus, or pneumogastric, nerve (motor and sensory), 248, 249f, 254t

Velopharyngeal closure. *see* Velopharyngeal mechanism

Velopharyngeal mechanism, 157

Velum, 152

Vena cava foramen, 49

Ventricles, of brain, 227f

Vermis, 220

Vertebrae, thoracic, 29f

Vertebral arteries, 229

Vertebral column, 26–28, 27f

Vertical muscles, 138

- depressor anguli oris, 135f, 137f, 138, 164–165t

- levator anguli oris, 135f, 138, 164–165t

- mentalis, 135f, 137f, 138, 164–165t

Vestibular system. *see* Inner ear and vestibular system

Vestibule, 186

Vestibulocochlear nerve, 198f

Vestibulocochlear (sensory) nerves, 244, 245f, 254t

Visceral and parietal views, 10, 11f

Vital capacity, 72

Vocal folds, 78, 86–91, 87f, 88f, 89f, 93f

- tissue layers of, 86–90

- visual representation of classifications of, 91f

Vocal tract, 77, 119–133

- lips, 125f, 128

- nasal cavities, 122, 123f

- oral cavity, 124, 125f

- palate, 120f, 126

- pharyngeal cavity, 119, 120f, 121f

- salivary glands, 128, 129f

- teeth, 130–133, 131f, 132f

- tongue, 126, 127f, 129f

- tonsils, 120f, 126

Volume. *see* Respiratory volumes

Vomer, 114

**W**

Waldeyer's tonsillar ring, 126

Wernicke's area, 212

Wisdom teeth, 130

**Z**

Zygomatic bones, 118

Zygomaticus muscle

- major, 136, 137f, 164–165t

- minor, 136, 137f, 164–165t

This page intentionally left blank