

Elie M. Ferneini  
Michael T. Goupil  
Margaret A. McNulty  
Christine E. Niekrash *Editors*

# Applied Head and Neck Anatomy for the Facial Cosmetic Surgeon



Springer

---

## Applied Head and Neck Anatomy for the Facial Cosmetic Surgeon

---

Elie M. Ferneini • Michael T. Goupil  
Margaret A. McNulty  
Christine E. Niekrash  
Editors

# Applied Head and Neck Anatomy for the Facial Cosmetic Surgeon

*Editors*

Elie M. Ferneini  
Beau Visage Med Spa, Greater Waterbury OMS  
Cheshire, CT  
USA

Division of Oral and Maxillofacial Surgery  
University of Connecticut School of Dental  
Medicine  
Farmington, CT  
USA

Department of Surgery, Frank H Netter MD  
School of Medicine, Quinnipiac University  
Hamden, CT  
USA

Margaret A. McNulty  
Indiana University School of Medicine  
Indianapolis, IN  
USA

Michael T. Goupil  
Division of Oral and Maxillofacial Surgery,  
University of Connecticut School of Dental  
Medicine  
Farmington, CT  
USA

Consultant in Oral and Maxillofacial Surgery  
Carmel, Indiana  
USA

Christine E. Niekraśh  
Frank H Netter MD School of Medicine  
Quinnipiac University  
Hamden, CT  
USA

ISBN 978-3-030-57930-2      ISBN 978-3-030-57931-9 (eBook)  
<https://doi.org/10.1007/978-3-030-57931-9>

© Springer Nature Switzerland AG 2021

This work is subject to copyright. All rights are reserved by the Publisher, whether the whole or part of the material is concerned, specifically the rights of translation, reprinting, reuse of illustrations, recitation, broadcasting, reproduction on microfilms or in any other physical way, and transmission or information storage and retrieval, electronic adaptation, computer software, or by similar or dissimilar methodology now known or hereafter developed.

The use of general descriptive names, registered names, trademarks, service marks, etc. in this publication does not imply, even in the absence of a specific statement, that such names are exempt from the relevant protective laws and regulations and therefore free for general use.

The publisher, the authors, and the editors are safe to assume that the advice and information in this book are believed to be true and accurate at the date of publication. Neither the publisher nor the authors or the editors give a warranty, expressed or implied, with respect to the material contained herein or for any errors or omissions that may have been made. The publisher remains neutral with regard to jurisdictional claims in published maps and institutional affiliations.

This Springer imprint is published by the registered company Springer Nature Switzerland AG  
The registered company address is: Gewerbestrasse 11, 6330 Cham, Switzerland



---

## Foreword

The number of cosmetic and aesthetic procedures increases year after year. According to statistics compiled by the American Society of Plastic Surgeons, 17.7 million cosmetic procedures were performed in the United States in 2018. Of these 1.8 million were surgical, while 15.9 million involved the use of minimally invasive procedures (e.g., botulinum toxin injections, fillers and dermabrasion). Not surprisingly, many of these procedures are performed on the head and neck, with rhinoplasty and blepharoplasty together accounting for more than 400,000 cosmetic procedures. Given the rising number of procedures, the authors of this book have created a detailed resource for practitioners. While the book focuses on the anatomy of the head and neck, it is tailored to the surgical and minimally invasive procedures currently in use. The book is organized into three sections; local anesthesia, regional anatomy and surgical anatomy. The authors bring decades of clinical practice and teaching together in creating this textbook. It is an excellent resource for all practitioners and especially trainees.

Bruce M. Koeppen, MD, PhD  
Founding Dean, Frank H. Netter MD School of Medicine,  
Quinnipiac University, Hamden, CT, USA

---

# Contents

## Part I Local Anesthesia for Cosmetic Procedures

<b>1 Overview of Local Anesthesia</b> . . . . .	3
Kyle J. Kramer, Cara J. Riley, and Jason W. Brady	
<b>2 Intraoral Maxillary Local Anesthesia Techniques</b> . . . . .	17
Steven Halepas, Leslie A. Hoffman, and Michael T. Goupil	
<b>3 Intraoral Local Mandibular Anesthesia</b> . . . . .	25
Benjamin Anderson and Chandler L. Walker	
<b>4 Transfacial Local Anesthesia Techniques</b> . . . . .	31
Jessica N. Byram, Derek Decloux, Christopher Haxhi, and Michael T. Goupil	
<b>5 Cervical (Neck) Local Anesthesia Techniques</b> . . . . .	41
Hannah Herriott, Kyle Robertson, and Benjamin Noblitt	
<b>6 Management of Local Anesthetic Complications</b> . . . . .	53
Ross Camiel, Samuel Roh, and Christy Lottinger	

## Part II Regional Anatomy

<b>7 Anatomy of the Integumentary System</b> . . . . .	65
Bruce M. Koeppen and Christine E. Niekrash	
<b>8 Anatomy of the Periorbital Region</b> . . . . .	73
Christine E. Niekrash	
<b>9 Anatomy of the Nose and Paranasal Sinuses</b> . . . . .	79
Christine E. Niekrash	
<b>10 Anatomy of the External Ear</b> . . . . .	85
Christine E. Niekrash	
<b>11 Anatomy of the Perioral Region</b> . . . . .	91
Christine E. Niekrash	
<b>12 Anatomy of the Neck</b> . . . . .	95
Christine E. Niekrash	
<b>13 Anatomy of the Superficial Face: Muscles of Face and Scalp, Superficial Vessels and Nerves, Major Salivary Glands</b> . . . . .	109
Christine E. Niekrash	
<b>14 Muscles of Mastication and the Temporomandibular Joint</b> . . . . .	117
Christine E. Niekrash	

### Part III Surgical Anatomy

<b>15 Neuromodulators (Botox)</b> .....	123
Mathew Goldschmidt and Justin B. Clemow	
<b>16 Facial Fillers</b> .....	131
Steven Halepas, Eric Ress, and Elie M. Ferneini	
<b>17 Facial Resurfacing</b> .....	143
Damon R. T. McIntire, Frank Paletta, and Douglas Lee Johnson	
<b>18 Forehead and Eyebrow Lift Techniques</b> .....	149
Angelo Cuzalina and Andrew Sohn	
<b>19 Facelift</b> .....	167
Brian Wong Won, Neel S. Joshi, Walter Jongbloed, and Charles L. Castiglione	
<b>20 Applied Anatomy in Blepharoplasty</b> .....	175
Steven Halepas, Xun J. Chen, and Mohammad Banki	
<b>21 Otoplasty</b> .....	183
Neel S. Joshi, Brian Wong Won, Walter Jongbloed, and Charles L. Castiglione	
<b>22 Chin Augmentation</b> .....	191
Steven Halepas, Alia Koch, and Elie M. Ferneini	
<b>23 Neck Lift</b> .....	199
Erik J. Nuveen	
<b>24 Hair Restoration</b> .....	205
Jon D. Perenack	
<b>Appendix 1</b> .....	215
<b>Appendix 2</b> .....	225
<b>Appendix 3</b> .....	229
<b>Appendix 4</b> .....	231
<b>Appendix 5</b> .....	233
<b>Appendix 6</b> .....	239
<b>Appendix 7</b> .....	241
<b>Appendix 8</b> .....	243
<b>Appendix 9</b> .....	245
<b>Appendix 10</b> .....	247
<b>Index</b> .....	249

---

## Contributors

**Benjamin Anderson, DDS** Department of Advanced Prosthodontics, Indiana University School of Dentistry, Indianapolis, IN, USA

**Mohammad Banki, MD, DMD, FACS** Clinical Faculty, Department of Surgery, The Warren Alpert Medical School of Brown University, Providence, RI, USA

Clinical Faculty, Department of Craniofacial Sciences, Division of Oral & Maxillofacial Surgery, University of CT, Warwick, RI, USA

**Jason W. Brady, DMD** Indiana University School of Dentistry, Department of Oral Surgery and Hospital Dentistry, Indianapolis, IN, USA

**Jessica N. Byram, PhD** Indiana University, Indianapolis, IN, USA

**Ross Camiel, DMD** Department of Oral and Maxillofacial Surgery, University of Connecticut School of Dental Medicine, Farmington, CT, USA

Department of Oral and Maxillofacial Surgery, Boston Medical Center, Boston University Henry M. Goldman School of Dental Medicine, Boston, MA, USA

**Charles L. Castiglione, MD, MBA, FACS** UCONN School of Medicine, Hartford Hospital, Connecticut Children's Medical Center, Farmington, CT, USA

**Xun J. Chen, DMD, MD** Department of Oral and Maxillofacial Surgery, New York Presbyterian/Columbia University Medical Center, New York, NY, USA

**Justin B. Clemow, DMD, MD** Metrohealth Medical Center, Cleveland, OH, USA

**Angelo Cuzalina, MD, DDS** Tulsa Surgical Arts, PC, AACS Cosmetic Surgery Fellowship, Tulsa, OK, USA

**Derek Decloux, DDS, MSc Dent Anes** University of Toronto, Toronto, ON, Canada

**Elie M. Ferneini, MD, DMD, MHS, MBA, FACS, FACD** Beau Visage Med Spa, Greater Waterbury OMS, Cheshire, CT, USA

Division of Oral and Maxillofacial Surgery, University of Connecticut School of Dental Medicine, Farmington, CT, USA

Department of Surgery, Frank H Netter MD School of Medicine, Quinnipiac University, Hamden, CT, USA

**Mathew Goldschmidt, MD, DMD** Private Practice, Independence, OH, USA

**Michael T. Goupil, DDS, MEd, MBA, FACD** Division of Oral and Maxillofacial Surgery, University of Connecticut School of Dental Medicine, Farmington, CT, USA

Consultant in Oral and Maxillofacial Surgery, Carmel, Indiana, USA

**Steven Halepas, DMD** New York-Presbyterian/Columbia University Medical Center, New York, NY, USA

**Christopher Haxhi, DMD, MD** University of California Los Angeles, Los Angeles, CA, USA

**Hannah Herriott, PhD** Department of Anatomy, Cell Biology, & Physiology, Indiana University School of Medicine, Indianapolis, IN, USA

**Leslie A. Hoffman, PhD** Department of Anatomy, Cell Biology, & Physiology, Indiana University School of Medicine, Indiana, IN, USA

**Douglas Lee Johnson, DMD** University of Florida, Saint Augustine, FL, USA

**Walter Jongbloed, BS** UCONN School of Medicine, Farmington, CT, USA

**Neel S. Joshi, MD** UCONN Integrated Surgical Residency Program, Farmington, CT, USA

**Alia Koch, DDS, MD, FACS** Department of Oral and Maxillofacial Surgery, NewYork-Presbyterian/Columbia University Medical Center, New York, NY, USA

**Bruce M. Koeppen, MD, PhD** Founding Dean, Frank H. Netter MD School of Medicine, Quinnipiac University, Hamden, CT, USA

**Kyle J. Kramer, DDS, MS** Indiana University School of Dentistry, Department of Oral Surgery and Hospital Dentistry, Indianapolis, IN, USA

**Christy Lottinger, DDS** Department of Oral and Maxillofacial Surgery, University of Connecticut School of Dental Medicine, Farmington, CT, USA

**Damon R. T. McIntire, MD** Division of Plastic and Reconstructive Surgery, The Warren Alpert Medical School of Brown University, Providence, RI, USA

**Margaret A. McNulty** Indiana University School of Medicine, Indianapolis, IN, USA

**Christine E. Niekrash, DMD, MDentSC** Frank H. Netter MD School of Medicine, Quinnipiac University, Hamden, CT, USA

**Benjamin Noblitt, DMD** Private Practice, MSL Facial and Oral Surgery, Marysville, WA, USA

**Erik J. Nuveen, MD, DMD, FAACS** Department of Oral and Maxillofacial Surgery, The University of Oklahoma Health Science Center, The University of Oklahoma College of Dentistry, Cosmetic Surgery Affiliates, Oklahoma, OK, USA

**Frank Paletta, MD, DMD, FACS** MSL Facial & Oral Surgery, Warwick, RI, USA  
Department of Surgery, Warren Alpert Medical School of Brown University, Providence, RI, USA

**Jon D. Perenack, MD, DDS** Louisiana State University Oral and Maxillofacial Surgery, Williamson Cosmetic Center, and Perenack Aesthetic Surgery, Baton Rouge, LA, USA

**Eric Ress, DMD** University of Florida, Jacksonville, FL, USA

**Cara J. Riley, DMD, MS** Children's Hospital Colorado, Department of Anesthesiology, Aurora, CO, USA

**Kyle Robertson, MS PhD Student** Department of Anatomy, Cell Biology, & Physiology, Indiana University School of Medicine, Indianapolis, IN, USA

**Samuel Roh, DMD** Department of Oral and Maxillofacial Surgery, University of Connecticut School of Dental Medicine, Farmington, CT, USA

**Andrew Sohn, MD, DMD** Fellow, Tulsa Surgical Arts, Tulsa, OK, USA

**Chandler L. Walker, PhD** Department of Biomedical Sciences and Comprehensive Care, Indiana University School of Dentistry, Indianapolis, IN, USA

**Brian Wong Won, MD** UCONN Integrated Surgical Residency Program, Farmington, CT, USA

---

## Part I

# Local Anesthesia for Cosmetic Procedures

**Michael T. Goupil**

Division of Oral and Maxillofacial  
Surgery, University of  
Connecticut School of Dental  
Medicine, Farmington, CT, USA

Consultant in Oral and  
Maxillofacial Surgery,  
Carmel, Indiana, USA

**Margaret A. McNulty**

Indiana University  
School of Medicine,  
Indianapolis, IN, USA

# Overview of Local Anesthesia

# 1

Kyle J. Kramer, Cara J. Riley, and Jason W. Brady

## Introduction

Local anesthesia is commonly defined as a loss of sensation in a limited or regional area of the body following the injection or application of a drug which prevents the generation or conduction of an impulse along a peripheral nerve [1, 2]. As opposed to general anesthesia, local anesthesia does not impact the entire body and does not require loss of consciousness. While local anesthesia can be induced in several ways, only those agents that act temporarily (i.e., not permanent) have value clinically. Local anesthetic agents used today impair peripheral nerve conduction which results in an efferent sensory blockade and the absence of pain sensation. These local anesthetics specifically function by binding to receptors within the sodium ion channels located in the neuronal membrane and blocking the influx of sodium ions, thereby impairing nerve conductance and preventing further signals from reaching the brain [3]. Utilization of a local anesthetic agent effectively anesthetizes the areas approximating or distal to the site of injection or application permitting invasive surgical procedures to be completed while the patient remains conscious and free of noxious painful sensations.

## History of Local Anesthetics

The use of modern local anesthetics dates back to 1856 when cocaine was first extracted from the coca leaf. In 1884, Carl Kohler demonstrated the ability of cocaine to anesthetize the

corneal surface of the eye. The field of local anesthesia rapidly expanded following the invention and widespread availability of the hypodermic syringe in the early 1900s, allowing for subcutaneous injection of the local anesthetic agents. Drs. Halsted and Hall are regarded as pioneers for local anesthesia in dentistry upon reporting the use of injected cocaine for inferior alveolar and lingual nerve blocks in 1884 [4]. The toxicity and addictive properties of cocaine soon led to the development of other local anesthetics including procaine (Novocain®), a synthetic ester local anesthetic, which was the standard agent soon after its arrival in 1904 until the introduction of lidocaine in 1948 [5]. Since that time, multiple other local anesthetics have been developed with favorable clinical effects (i.e., faster onset, longer duration of action) such as articaine, bupivacaine, mepivacaine, and prilocaine.

## Rationale for Local Anesthetic Use

Effective intraoperative and postoperative pain control using local anesthetics is an essential component in numerous fields of medicine and dentistry. Indications for the use of a local anesthetic are expansive, but primarily revolve around the ablation of pain permitting the completion of invasive procedures that cause noxious stimulation. Local anesthetics are administered topically, as a spray, gel, or cream, or as an injected solution, with additional doses given as needed to ensure adequate numbness. Local anesthesia is most commonly utilized in minor surgical procedures that do not require concurrent muscle relaxation or for the patient to be unconscious. Additionally, local anesthesia is quite often a main foundational component of any sedative anesthetic plan, serving to further reduce patient stress and anxiety and promote cardiopulmonary stability. Inadequate pain management can trigger a multitude of undesirable effects. The stress associated with pain causes an increase in cardiovascular tone, most notably evident as hypertension and tachy-

---

K. J. Kramer (✉)  
Indiana University School of Dentistry, Department of Oral  
Surgery and Hospital Dentistry, Indianapolis, IN, USA  
e-mail: [kjkramer@iu.edu](mailto:kjkramer@iu.edu)

C. J. Riley  
Children's Hospital Colorado, Department of Anesthesiology,  
Aurora, CO, USA

J. W. Brady  
NYU Langone, Dental Medicine, Gilbert, AZ, USA

cardia. In medically compromised patients, these effects may ultimately lead to more serious complications including cerebrovascular accident and myocardial infarction. Even in medical and dental procedures performed under general anesthesia, many providers choose to supplement with local anesthesia. Commonly cited benefits supporting the concurrent use of local anesthesia during general anesthesia include increased stabilization of vital signs, reduced anesthetic requirements leading to lower quantities of anesthetic agents, and decreased postoperative pain [6].

## Side Effects and Complications

Side effects and complications associated with the use of local anesthesia are rare and usually minor. Common side effects include temporary headaches, altered sensation (i.e., “pins and needles”) and weakness, and modest tachycardia. The latter is generally attributable to either patient anxiety or a direct effect of the vasoconstrictor that is included with many local anesthetic formulations. Local anesthetic agents can cause systemic toxicity if administered inappropriately in excessive quantities, with adverse effects potentially impacting all excitable tissues such as the cardiovascular and central nervous systems. Signs of systemic toxicity are dose-dependent and typically follow a cascade of clinical signs and symptoms as blood plasma levels increase. Commonly patients experiencing a local anesthetic overdose will report perioral numbness, primarily due to the extensive blood supply of the head and neck. This is followed by CNS excitation and depression, as manifested by dizziness, disorientation, tinnitus, altered mental status, convulsions, and unconsciousness, cardiovascular collapse, and death. Local anesthetic agents act within the cardiovascular system to cause hypotension, bradycardia, and conduction defects. While rare, injection of a local anesthetic can cause a direct mechanical or chemical injury to the nerve which can result in prolonged or permanent anesthesia, paresthesia, or dysesthesia. The primary goal in administering local anesthesia is to achieve a balance of effectively blocking pain sensations without causing untoward effects in the patient. As such, it is essential to follow dosing recommendations or guidelines while also taking into account specific factors related to the individual patient’s medical history and the intended surgical procedure.

## Local Anesthetics: Pharmacology

### Mechanism of Action

As discussed above, local anesthetics act on neurons within the somatosensory pathways to inhibit the generation and conduction of nerve impulses. The patient perceives the sensation of pain once the neuronal impulses generated follow-

ing stimulation of peripheral nociceptors are transmitted along the length of primary afferent neurons, synapsing in the spinal cord and higher processing centers in the brain via secondary and tertiary afferent neurons respectively. Local anesthetics temporarily block normal neuronal conduction thereby preventing the noxious painful signal from ever reaching the brain. So even though tissue damage has occurred, the patient never experiences the sensation of pain.

On a molecular level, local anesthetics reversibly bind to specific receptor sites located within the sodium ion channels found within neuronal membranes. These sodium channels are usually in the closed resting state, and in this configuration, sodium is not able to flow down its concentration gradient and enter the interior of the nerve cell which has a  $-70$  mV charge. However, when an adequate stimulus excites the neuron, the sodium ion channels open, allowing sodium ions to diffuse inward causing the internal charge of the neuron to become more positive. If the change in charge reaches the firing threshold of  $-55$  mV, the remaining sodium ion channels open. The resulting change in charge stemming from the massive influx of positively charged sodium ions initiates further neuronal depolarization and generation of an action potential that propagates down the length of the nerve. The repolarization phase begins immediately after the end of this depolarization phase. The sodium ion channels enter an inactivated state, again disallowing the passive influx of sodium. At the same time, potassium ion channels open allowing positively charged potassium ions to flow down their concentration gradients. Concurrently active transporters ( $\text{Na}^+/\text{K}^+$  pumps) begin moving sodium and potassium ions respectively against their natural concentration gradients. This repolarization process concludes with the interior charge of the neuron returning to its resting state and an internal charge of  $-70$  mV. When bound to their receptor sites within the sodium ion channels, local anesthetics effectively prevent the influx of sodium ions, even when there is an appropriately sized stimulus to initiate depolarization [7]. This causes a progressive decrease in the rate and level of depolarization, and therefore, a slowing of nerve conduction [8]. Local anesthetics have greater affinity for sodium channels in their activated and inactivated states than in their resting state. In other words, local anesthetics bind during action potentials and dissociate during membrane repolarization. An increased frequency of neuron stimulation and more positive (depolarized) membrane potential leads to a higher degree of blockade by local anesthetics [7, 9]. This phenomenon is known as use-dependent or frequency-dependent conduction block [8]. Practically speaking, this means rapidly firing neurons are more susceptible to local anesthetic blockade.

The diameter of the nerve fiber also affects susceptibility. Sensitivity to local anesthetic blockade increases with decreasing fiber size, most likely because smaller fibers naturally have fewer sodium channels to block [7]. For myelin-



ated nerves in which action potentials move in a saltatory manner, skipping from one node of Ranvier to the next, smaller fibers again are more susceptible because their nodes are in closer proximity to each other [8]. The critical number of ion channels and corresponding nodes to block is therefore easier to reach with a given volume of local anesthetic [9]. It appears that three consecutive nodes (~10–15 mm of the neuron) must be blocked for impulse transmission to be inhibited [8]. Local anesthetics can block impulse propagation along any type of nerve fiber, including motor, autonomic, and sensory. These various types of nerves tend to be different sizes and therefore exhibit differential sensitivity to local anesthetic activity. In keeping with this idea, small autonomic nerve fibers are most sensitive to local anesthetic action; followed by unmyelinated C fibers (pain) and small myelinated A-delta fibers (pain and temperature); and finally the larger myelinated A-gamma, A-beta, and A-alpha fibers (postural, touch, pressure, and motor information) [9]. As such, when patients recover from local anesthesia, they first regain motor function, then sensation, and finally local autonomic control. Within the sensory realm, since sensory nerves themselves vary greatly in terms of diameter and rate of activation, patients may experience discomfort from pressure even while pain is thoroughly inhibited [7, 9]. The more susceptible a fiber is to local anesthetic activity, the more quickly it is blocked and the more slowly it recovers.

## Molecular Structure

Local anesthetics contain three main structural components: (1) lipophilic aromatic ring, (2) intermediate ester or amide linkage, and (3) hydrophilic terminal amine. The differences in these parts determine the particular characteristics of each local anesthetic agent. The intermediate linkage determines the drug class (ester vs. amide) and the manner by which the agent is metabolized. It is important that local anesthetics intended for parenteral use possess both lipophilic and hydrophilic components. Water solubility allows the medication to be in aqueous solution and to avoid precipitation upon injection into tissues; lipid solubility allows the drug to move through anatomic structures (i.e., cell membrane) to the site of action [8]. Benzocaine is of particular note as it is unique among local anesthetics in lacking a terminal amine component. It does not possess the ability to alternate between lipophilicity and hydrophilicity as described above and is therefore relegated to topical use only.

## Potency

The potency of a local anesthetic agent is primarily determined by *lipid solubility (hydrophobicity)*, which in turn is

determined by the aromatic ring and its substitutions as well as those upon the tertiary amine. A more lipid-soluble molecule is better able to diffuse through nerve sheaths and neural membranes and is therefore more potent. A more potent local anesthetic is able to be formulated in a lower concentration (bupivacaine 0.5% and ropivacaine 0.2% versus lidocaine 2%, for example) [7]. Articaine possesses a similar but lower lipid solubility relative to lidocaine. The two are comparably efficacious, but as articaine has a wider therapeutic range, it can be formulated in a higher concentration (4%) than other amide local anesthetics [10].

## Onset

Onset time is determined largely by the state of the terminal amine component of local anesthetic molecule. The amine can exist in a tertiary uncharged base form (B) that is lipid-soluble or in a quaternary charged conjugate acid form (BH<sup>+</sup>) that is water-soluble. The uncharged free base form (B) allows local anesthetics to penetrate nerve membranes, while the charged conjugate acid form (BH<sup>+</sup>) engages the receptors in the sodium ion channel and blocks the influx of sodium ions; both forms are essential to the function of local anesthetics. By way of this substituted amino group, most local anesthetics naturally exist as weak bases. In this state, local anesthetics are ineffectual as they degrade too quickly and are poorly soluble in water to be of clinical use as an injectable agent. To mitigate this and promote stability in aqueous media, the local anesthetic base is combined with hydrochloric acid to form a hydrochloride salt which can then be dissolved freely in a slightly acidic aqueous solution. Due to the acidity and decreased pH of the solution, most of the local anesthetic molecules exist in the water-soluble conjugate acid form (BH<sup>+</sup>) while a much smaller percentage exist in the lipid-soluble free base state (B). Only those molecules in free base state (B) are capable of penetrating the lipid-rich neuronal membrane to be available for conversion back into the conjugate acid form (BH<sup>+</sup>) and subsequently engage the receptor binding site. *The time to onset, then, is related to how many molecules convert from the quaternary (BH<sup>+</sup>) to the tertiary (B) structure upon injection into the tissue.* Conversion between the quaternary and tertiary forms (i.e., conjugate acid “BH<sup>+</sup>” vs. free base “B”) is determined by the *ionization or dissociation constant (pKa)* for the specific local anesthetic agent, as well as the pH of the injection site. The higher the pKa, the fewer molecules exist in the lipid-soluble (B) form and the longer the onset time. The injectable local anesthetics available have pKas ranging from 7.5 to 9.0, which is higher than the normal physiologic pH (7.4) of the bodily tissues. Upon injection into those tissues, fewer than 50% of the local anesthetic molecules exist in the tertiary uncharged free base (B) form. It should be mentioned

again that the water-soluble formation of local anesthetic ( $BH^+$ ) is that which exerts effects on the sodium channel: once the local anesthetic has penetrated the neuron, it is re-ionized to the quaternary state, enters the sodium channel, and blocks nerve conduction [7].

Importantly, tissue inflammation lowers the pH of the local environment below 7.4, favoring the conversion into the water-soluble state ( $BH^+$ ). This may account for the difficulty encountered when anesthetizing inflamed or infected tissues. In such cases, choosing an anesthetic with a lower pKa is advisable (mepivacaine with pKa 7.6, for example) [7]. Tissue inflammation is also associated with increased blood flow locally and decreased responsiveness to vasopressors, both of which can cause an increase in systemic absorption of local anesthetics.

One method by which onset time is decreased is by buffering the local anesthetic solution. As mentioned before, the tertiary form of local anesthetic (B) permits crossing of the neuronal membrane and increasing the proportion of drug in the tertiary state speeds onset. To increase this proportion, the pH of the local anesthetic solution (which is mildly acidic, especially when a vasopressor is also added) can be increased to physiological pH prior to administration, often by the addition of sodium bicarbonate. This also has the effect of rendering the injection more comfortable as a more acidic solution will tend to be more painful and cause a burning sensation for the patient. To be truly effective, buffering should render the pH of the local anesthetic solution equal to the pH of the tissues (7.4). The pH of the buffer must be exact and the solution stable to reliably target 7.4 otherwise it may accidentally precipitate. There are mixed opinions as to whether buffering offers any practical advantage with regards to onset and comfort, but the theory behind the practice is sound [11].

There is a misconception that greater lipid solubility leads to a faster onset time. While this may be true in vitro as more lipid-soluble molecules diffuse through membranes more easily, in vivo the opposite has been shown to be true. In a

patient, there are aggravating factors effecting onset, such as the amount of vasodilation produced by the local anesthetic, the opportunity for a highly lipid-soluble molecule to be sequestered by fatty tissues rather than the targeted neuronal tissues, and the difficulty of a lipid-soluble molecule to travel through tissue fluids. Therefore, the greater the lipid solubility, generally the slower the onset. Using a higher concentration anesthetic can help mitigate this effect [7] (See Table 1.1).

## Duration of Action

The duration of action is determined by the *protein affinity or strength of protein binding* of the local anesthetic. Sodium channels contain proteins, and as the degree of a local anesthetic's protein binding increases, so too does the length of time that local anesthetic occupies the receptor within the sodium ion channel and sustains ion blockade. The percentage of plasma protein binding that an anesthetic demonstrates can be used as a surrogate to determine this affinity. For example, bupivacaine and mepivacaine demonstrate 95% and 55% plasma protein binding respectively, and bupivacaine is a longer-acting local anesthetic [7]. Sequestration of a local anesthetic within the sodium ion channel furthermore serves to decrease the rate of drug metabolism by plasma esterases and/or hepatic enzymes [9].

The degree of vasodilation locally produced by a particular anesthetic is another factor that contributes to the duration of action of a local anesthetic. Vasodilation increases blood flow to the targeted area and effectively allowing the local anesthetic to be “washed” away from the neuron, decreasing the drug concentration and duration of action. Vasopressors (e.g., epinephrine, levonordefrin) are often added to local anesthetics to mitigate this vasodilatory activity, delay systemic absorption, and prolong activity. All local anesthetics produce some degree of vasodilation with the major exception of cocaine. Concerning the commonly used anesthetics, the amount of dilation produced is greatest for

**Table 1.1** Onset and duration of commonly used local anesthetics

Agent	Onset (min)	Elimination half-life (h)	Approximate duration (min)			
			Infiltration: soft-tissue	Infiltration: pulpal	Block: soft-tissue	Block: pulpal
Mepivacaine/Levonordefrin	1.5–2	1.9	40–130	40–50	180–300	60–90
Mepivacaine Plain			20–90	20–25	120–180	40–60
Lidocaine/Epinephrine	2–3	1.6	60–170	50–60	180–300	60–90
Prilocaine/Epinephrine	2–4	1.6	40–140	30–40	180–480	50–90
Prilocaine Plain			90–120	10–20	120–240	40–60
Articaine/Epinephrine	1–2	0.4	60–170	45–60	120–300	60–90
Ropivacaine Plain	2–4	1.9	120–340	N/A	N/A	N/A
Bupivacaine/Epinephrine	5–8	3.5	120–340	40–90	240–720	90–360
Benzocaine	0.5–1	Duration after topical application: 5–20 min				

lidocaine, followed by bupivacaine, and finally mepivacaine. In a formulation without a vasopressor, lidocaine can be utilized only for brief procedures via infiltration; success for longer procedures and efficacy for nerve blocks is poor [7]. Indeed, the mechanism of the local anesthetic reversal agent, phentolamine (OraVerse™), is to increase vasodilation of submucosal tissues. When injected into the same site where the local anesthetic was initially administered, this  $\alpha$ -1 blocker causes subsequent dilation of vasculature, which increases absorption of the local anesthetic into the bloodstream and shortens the duration of action by approximately 50% (See Table 1.2).

## Metabolism and Elimination

Local anesthetics are classified as either amides (–NCHO–) or esters (–COO–) based on the intermediate linkage between the aromatic ring and terminal amine. These linkages impart differences in allergenicity and also determine how the local is metabolized. Amides undergo biotransformation via enzymatic degradation in the liver and renal elimination via the urine. Esters, on the other hand, are hydrolyzed by plasma esterases, primarily via the enzyme pseudocholinesterase, as well as to some extent in the tissues. They may then undergo further metabolism in the liver prior to elimination via the urine [8]. Articaine is a unique local anesthetic in that it contains both an amide intermediate linkage and an ester side chain on its aromatic ring. Hydrolysis of the ester side chain occurs in the blood via plasma esterases rendering the articaine molecule ineffective, so while articaine is considered an amide, it is metabolized like an ester. The result is that articaine has a shortened elimination half-life (20–40 min) compared to other amides, such as lidocaine (90 min), that undergo hepatic metabolism [7]. Elimination half-life can vary significantly between individuals, so while articaine may be chosen for its shorter duration, caution is advised before considering the administration of additional doses. Indeed, individuality in the effectiveness of biotransformation is of great practical relevance. Patients with genetically based deficiencies in pseudocholinesterase activity are unusually sensitive to ester local anesthetics, whereas those with severe hepatic dysfunction are more sensitive to both esters and amides, since pseudocholinesterase itself is pro-

duced by the liver and the amide anesthetics are primarily hepatically metabolized. It should be noted that hepatic function does not affect the duration of action of anesthetics, which is dictated primarily by redistribution away from the site of injection rather than drug metabolism; the concern is with the total dose of anesthetic, which should be limited in those with severe liver disease [12].

The metabolism of local anesthetics is clinically important as toxicity depends largely on the balance between their absorption into, elimination from, and resulting total concentration in the systemic circulation. Some local anesthetics produce pharmacologically active metabolites; the deethylated metabolites of lidocaine are an example [8]. Other metabolites can cause adverse effects, the most problematic originate from the esters. Procaine, an ester local anesthetic used historically in dentistry, produces para-amino benzoic acid (PABA) upon metabolism, which notably causes a high incidence of allergic reactions in sensitive individuals. The plasma concentration of local anesthetic is also influenced by plasma protein binding. Amide local anesthetics are between 55% and 95% bound to plasma proteins, namely  $\alpha$ -1 glycoprotein [9]. Factors that alter the amount of this protein will secondarily alter the level of free unbound local anesthetic molecules available to neurons, the liver, and other tissues. Oral contraceptives, for example, decrease  $\alpha$ -1 glycoprotein concentration, thereby increasing unbound fraction of amide local anesthetics in the blood [9]. Redistribution to peripheral tissues is an additional factor in decreasing the concentration of local anesthetics in the blood, especially for the amides and longer-acting esters [8].

While the desired effect of local anesthetics is to block neuronal conduction in the peripheral nervous system, they can interfere with any tissues in which such transmission occurs. Local anesthetics can, therefore, act within the central nervous system, the autonomic ganglia, the neuromuscular junction, and in muscle, including the myocardium. Local anesthetic action at these undesired locations is proportional to the concentration of the drug found in the systemic circulation. In local anesthetics with chiral centers, the *S*-enantiomer is less toxic than the *R*-enantiomer [9]. For example, bupivacaine and ropivacaine are structurally related. Bupivacaine is a racemic mixture of its two stereoisomers whereas ropivacaine is a pure *S*-enantiomer purposefully developed for reducing systemic toxicity [13].

**Table 1.2** Properties of local anesthetics

Agent	pK <sub>a</sub> (36 °C)	Relative lipid solubility	Protein binding (%)	Relative vasodilating activity
Mepivacaine	7.6	++	75	+ / ++
Lidocaine	7.7	++	65	++
Prilocaine	7.7	++	55	+
Articaine	7.8	++	95	++
Ropivacaine	8.1	+++	94	–
Bupivacaine	8.1	++++	95	++ / +++

## Topical Anesthesia

Local anesthesia of mucous membranes, such as those present in the nose, mouth, throat, and trachea, can be accomplished using topical applications of lidocaine (2–10%), tetracaine (2%), cocaine (1–4%), benzocaine (5–20%), or combinations thereof. Formulations vary, consisting of gels, ointments, solutions, sprays, lozenges, and others [9]. Topical anesthetics work in the same manner as injectable local anesthetics, by reversibly binding to receptors within sodium ion channels, blocking the influx of sodium ions in neurons. Benzocaine, used only in topical preparations, is perhaps the most commonly found ester local anesthetic. It is thought that benzocaine perturbs the structure of the cell membrane, perhaps by expansion or other deformation, leading to a change in the structural conformation of the sodium ion channel and a decrease in sodium ion permeability. Benzocaine is rather unique due to its lack of a tertiary amine as well as its low pKa of 2.51 at 25 °C. As such, it exists as an uncharged free base form (B) at physiologic pH of 7.4 and does not directly engage the receptor within the sodium ion channel as other local anesthetics do [14, 15]. Benzocaine is poorly soluble in aqueous fluid which allows it to remain mainly at the site of application and prevents its use as an injectable anesthetic and its ready absorption into the systemic circulation [8]. Benzocaine is quite effective in decreasing discomfort from injections, sore throats, minor traumas, dental defects, transesophageal echocardiography, and awake intubation procedures. The pKa of benzocaine is comparatively low and it has a rapid onset [16]. While benzocaine offers a low risk of systemic toxicity, it can cause methemoglobinemia, and dosing guidelines should be respected.

Cocaine is another ester that has decreased in popularity over time due to its potential for toxicity and abuse. In current practice, it is primarily used for certain otolaryngologic procedures where its unique ability to produce vasoconstriction aids in decreasing surgical bleeding. Tetracaine is an ester local anesthetic that is long-acting. It has a relatively slow onset and increased potential for toxicity and is therefore mostly relegated for use as a topical anesthetic. While cocaine provides inherent vasoconstrictive activity, the addition of a vasoconstrictor such as phenylephrine (0.005%) can achieve a similar effect when used in combination with other topical local anesthetics. Epinephrine is ineffective when applied topically due to its poor penetrance. Cocaine and lidocaine are similar in time to peak effect (3–5 min) and duration of action (30–45 min) when applied topically, whereas tetracaine has a slightly prolonged onset and duration of action [9]. Benzocaine, on the other hand, has a rapid onset (<1 min) and an effective duration of action approximating 5–15 min [17]. These local anesthetics work only superficially when used in this manner. Local anesthetic applied to mucous membranes (or denuded skin) is absorbed

rapidly into the systemic circulation increasing the risk of toxicity. Absorption from the tracheobronchial tree causes subsequent concentrations of local anesthetic in the blood nearly equal to those found after intravenous injection [9].

For topical anesthesia of deeper structures up to a depth of 5 mm, eutectic mixtures are often employed. Eutectic formulations are combinations of local anesthetics with a melting point lower than that of either anesthetic alone. This allows the topical to exist as an oil at room temperature that can penetrate intact skin. These mixtures are applied to the skin and often left covered with an occlusive dressing 30–60 min prior to the planned procedure. Such topicals are frequently utilized for vascular access, skin graft harvest, and dermatological procedures. Systemic toxicity is a possibility and using these mixtures on mucous membranes or broken skin should be avoided. Examples of such mixtures include EMLA® cream (lidocaine 2.5% and prilocaine 2.5%), Pliaglis® cream (lidocaine 7% and tetracaine 7%), and Synera® (lidocaine 70 mg and tetracaine 70 mg in a topical patch form). The latter was created to generate heat upon exposure to air to increase delivery of local anesthetic into the skin and speed onset time (20–30 min) [9]. It should be mentioned that prilocaine, as found in EMLA cream, is an oxidizing drug and its metabolite can produce methemoglobinemia.

---

## Vasoconstrictors: Pharmacology

### Benefits of Vasoconstrictors

With one notable exception, local anesthetics all cause some degree of vasodilation which increases the rate of absorption into the systemic circulation, reduces the concentration in the tissues locally, and increases surgical bleeding. The degree of vasodilation caused by the local anesthetics themselves is not consistent across all agents. Mepivacaine and prilocaine are two agents with notably weak vasodilatory action. As such, these two agents in particular are often utilized in plain concentrations without the inclusion of any vasoconstrictive agents. The other outlier is cocaine, which inherently acts as a peripheral vasoconstrictor primarily attributed to its sympathomimetic activity and reuptake inhibition of norepinephrine and epinephrine. These three examples aside, the net result of the local anesthetic vasodilatory effects is a shorter duration and decreased depth of local anesthetic activity, both of which likely oppose any clinician's goals when considering the use of local anesthesia. Vasoconstrictive agents are used concurrently with local anesthetic to directly combat the aforementioned effects. Constriction of the blood vessels located in the immediate vicinity of the local anesthetic and vasoconstrictor administration site acts essentially as a chemical tourniquet. The resulting vasoconstriction causes a decrease in blood flow



locally, leading to a reduction in movement of the local anesthesia into the systemic circulation. This effectively maintains a higher concentration of local anesthetic in the tissues locally, prolongs duration of anesthetic activity, increases the depth of anesthetic blockade, and reduces surgical bleeding. The benefits of administering local anesthetic agents along with a vasoconstrictor greatly outweigh the risks; there exist relatively few situations where strict avoidance of a vasoconstrictor is warranted.

The vasoconstrictive effects discussed above are produced via increased activity of the sympathetic nervous system by substances that mimic the actions of the body's endogenous catecholamine neurotransmitters, such as epinephrine, norepinephrine, and dopamine. The term "sympathomimetic" is universally used to describe such activity. Sympathomimetic drugs can be categorized in several ways, including by their molecular structure (catecholamine versus noncatecholamine), mode of action (direct-acting, indirect-acting, or mixed-acting), or method of synthesis (naturally occurring or synthetic). While vasoconstriction may be a common effect produced by many sympathomimetic agents, not all are capable of producing clinically relevant vasoconstriction and some may not be acceptable alternatives due to a high risk of side effects.

## Risks of Vasoconstrictors

The main drawback to using vasoconstrictive agents with local anesthetics is their potential for systemic effects, which chiefly involve augmentation of the cardiovascular system. Tachycardia and hypertension are commonly reported sequelae, with accompanying risks of increased myocardial oxygen consumption and decreased oxygen delivery leading to hypoxia. While the vast majority of patients are able to tolerate minor or modest increases in sympathetic activity without issue, higher-risk patients may be significantly impacted, such as elderly, infirmed patients, or those with cardiovascular comorbidities. The use of vasoconstrictors is considered safe for virtually all patients, although the use of a reduced dose may be warranted depending on the individual patient. In such patients, a reduction or withholding of the vasoconstrictor may be warranted. An additional consideration related to the administration of vasoconstrictors is the impact of vasoconstriction, reduced blood flow, and potential for hypoxia on the tissues locally. This was historically considered a major concern precluding the use of epinephrine during local anesthetic blockade of the digits, nose, and ears; however, numerous studies have since demonstrated that vasoconstrictors can safely be used in terminal regions [18, 19]. Furthermore, this potential risk is rendered more remote when considering the head and neck region due to its substantial increased blood flow compared to other anatomic sites.

## Vasoconstrictor Agents and Preparation

While there are multiple pharmacologic agents available that could function as effective vasoconstrictive agents for concurrent use with local anesthetics, such as phenylephrine, there are two main variants commercially available in North America: epinephrine and levonordefrin. Epinephrine is by far the most popular option and is available in a wide variety of concentrations (Table 1.1). Levonordefrin is utilized as a vasoconstrictor alternative to epinephrine due to its more favorable cardiovascular profile. Because of its preferential binding of alpha versus beta adrenoreceptors, it tends to cause less tachycardia than epinephrine. Felypressin, a synthetic analogue of vasopressin, is another potent vasoconstrictor utilized in many countries; however, it is not currently available in the United States.

The addition of vasoconstrictor to the injectable local anesthetic necessitates acidification of the solution since an antioxidant is required to ensure long-term stability of the vasoconstrictive agent. Plain local anesthetic agents do not require the addition of an antioxidant and are not acidified to the same degree. The resulting decrease in pH of the solution containing the vasoconstrictor leads to several less than desirable effects, including slowed local anesthetic onset time and increased patient discomfort. Notably, injection of acidified vasoconstrictor-containing local anesthetics generally causes a burning sensation due to the lower pH; this effect is significantly reduced with the use of plain local anesthetics. For comparison, the pH of lidocaine with epinephrine approximates 4.5 while that of plain lidocaine approximates 6.0. An additional issue with such stabilizing additives is the potential for allergic reactions. The most common antioxidant utilized in dental cartridges is sodium metabisulfite, which may be problematic for patients with a history of sulfite allergies. Methylparaben, a preservative that provides antioxidant, bacteriostatic, and fungistatic properties, is another substance with allergic potential. It should be noted that methylparaben is commonly used in multidose vials, not in dental cartridges. Strict avoidance of vasoconstrictors is warranted for patients with the requisite allergy history, such as signs or symptoms suggestive of an anaphylactic reaction following administration of a local anesthetic with vasoconstrictor. Use of plain local anesthetics (i.e., no vasoconstrictors) and avoiding multidose vials (no methylparaben) are recommended for patients who report such allergies.

## Vasoconstrictor Concentrations

Unlike local anesthetics which use percentage (%) to describe the concentration of a particular solution, vasoconstrictors have historically reported concentration as a ratio

(i.e., 1:100,000 or 1:200,000). This ratio describes the number of grams of a drug contained within a particular number of milliliters or volume of solution. For example, a 1:100,000 concentration of epinephrine contains 1 g of epinephrine dissolved into 100,000 mL of solution. This can be fractionally written as 1 g/100,000 mL, equating to 1000 mg/100,000 mL or 1,000,000 mcg/100,000 mL respectively, and further simplified as 0.01 mg/mL or 10 mcg/mL (see Table 1.3). After determining the vasoconstrictor concentration, any subsequent dosing calculations would only involve multiplication of the concentration (i.e., mg/mL or mcg/mL) and the volume (total # of mL) of solution administered. Recently, a shift in vasoconstrictor labeling has occurred due to concerns regarding drug errors and dosage miscalculations. Drug manufacturers have begun including dosage values (mg/mL) on drug labels for simplification purposes, although it must be noted that this practice has not yet been extended to include dental cartridges.

## Pharmacodynamics

### Epinephrine

Epinephrine is a catecholamine neurotransmitter primarily produced endogenously from the methylation of norepinephrine within the chromaffin cells of the adrenal medulla [20]. While exogenous epinephrine was initially obtained by purifying the extract of ground sheep or bovine adrenal glands, today it is generally obtained via synthetic means. As a direct-acting nonselective adrenergic agonist, epinephrine engages and stimulates ( $\alpha_1$ ,  $\alpha_2$ ,  $\beta_1$ , and  $\beta_2$ ) receptors. The most common clinical effect observed following routine intraoral administration of local anesthetics containing epinephrine is a modest, transient increase in heart rate ( $\beta_1$ ). This has been coined the “epinephrine reaction” which many patients mistake for an allergic-type reaction. Inadvertent intravascular administration of epinephrine causes a more substantial tachycardic effect in addition to a modest blood pressure elevation ( $\alpha_1$ ), and potentially bronchodilation ( $\beta_2$ ) as well. Interestingly, epinephrine demonstrates dose-dependent preferential adrenergic receptor binding as doses move from high to low:  $\alpha_1 > \beta_1 > \beta_2$ . This

selectivity is utilized during ACLS cardiac resuscitation with extremely high concentrations of epinephrine (1 gram via 10 mL of a 1:10,000 or 0.1 mg/mL solution) being administered intravenously to provide systemic vasoconstriction ( $\alpha_1$ ) to improve perfusion pressure to the brain and heart during chest compressions. The normal vasoconstrictive purposes for including epinephrine with a local anesthetic are directly attributed to these  $\alpha_1$  actions on blood vessels. The vessels within mucous membranes, such as those found intraorally, primarily have  $\alpha_1$  receptors and lack the additional  $\beta_2$  receptors found within the blood vessels supplying skeletal muscle. Isolated alpha stimulation leads to effective vasoconstrictive action following epinephrine administration. In contrast, blood vessels with both  $\alpha_1$  and  $\beta_2$  receptors (such as in skeletal muscle) respond to epinephrine by vasoconstriction initially, shifting toward vasodilation as the epinephrine concentration falls and the  $\beta_2$  activity predominates.

The vasoconstrictive impact of epinephrine is beneficial for increasing hemostasis as well as prolonging local anesthetic activity and decreasing the potential for systemic toxicity. Local infiltration into the target tissues is essential to ensure hemostatic effects. The use of more concentrated solutions of epinephrine, such as 1:50,000 or 1:80,000, is considered more effective for producing hemostasis than more dilute forms, such as 1:100,000 or 1:200,000 [21]. It follows that these higher concentrations of epinephrine have a higher potential for negative systemic sequelae, particularly if the patient is medically compromised or has a history of cardiovascular disease. The recommended maximum dosing for epinephrine is listed in Table 1.4; however, it must be appreciated that these doses can potentially be safely exceeded if the patient is in an environment where blood pressure and heart rate are continuously monitored. The use of the lowest clinically effective dose is recommended to reduce the risk of potential complications.

### Levonordefrin

Similar to epinephrine, levonordefrin is a direct-acting sympathomimetic catecholamine, although it is purely a synthetic agent. Levonordefrin has a higher binding preference (75% compared to 25%) for  $\alpha$ -adrenergic receptors than  $\beta$ -adrenergic receptors leading to a more favorable cardiovascular profile (less tachycardia) when administered concurrently with local anesthetics [24]. The vasoconstriction produced is similar to that observed with epinephrine in terms of prolonging the local anesthetic action, although the degree of hemostasis is likely to be less significant. Levonordefrin is roughly 15–20% as potent a sympathomimetic agent as epinephrine. However, this lack of potency is mitigated by increasing the concentration of levonordefrin (1:20,000 or 0.5 mg/mL), effectively creating equipotent concentrations for clinical use. Unlike epinephrine, which is

**Table 1.3** Epinephrine concentrations

Concentration (g:mL)	mg/mL	mcg/mL
1:1000 <sup>a</sup>	1	1000
1:10,000 <sup>b</sup>	0.1	100
1:50,000	0.02	20
1:80,000	0.0125	12.5
1:100,000	0.01	10
1:200,000	0.005	5

<sup>a</sup>Indicated for IM use

<sup>b</sup>Indicated for IV use

**Table 1.4** Epinephrine max doses 0.04 and 0.2 per dental appointment [22, 23]

Maximum recommended dose – epinephrine					
	Total dose per dental appointment		Number of dental cartridges using		
	Epinephrine (mg)	Epinephrine (mcg)			
Adult patient – healthy	0.2	0.04	5.5	11.1	22.2 <sup>a</sup>
Adult patient – cardiovascular risk	200	40	1.1	2.2	4.4

<sup>a</sup>Limited by local anesthetic MRD

available in combination with several different local anesthetic agents, levonordefrin is only available with mepivacaine in dental cartridges.

**Pharmacokinetics**

**Epinephrine and Levonordefrin**

The clinical actions produced by epinephrine and levonordefrin cease as drug concentrations within the junctional cleft fall and subsequent disengagement from the adrenergic receptors occurs. Inactivation upon reuptake into the local presynaptic nerve terminal accounts for the majority of this cessation of activity for most endogenous catecholamines. However, hepatic metabolism primarily accounts for the inactivation of exogenous sympathomimetics [25]. Two key enzymes involved in the breakdown of many sympathomimetics are catechol-O-methyltransferase (COMT) and monoamine oxidase (MAO), both of which are quite abundant in the liver. COMT is chiefly responsible for the enzymatic metabolism of catecholamines, including epinephrine and levonordefrin. Epinephrine is metabolized rather extensively with approximately 80% of a parenteral dose being excreted renally as metanephrine and vanillylmandelic acid (VMA), and only a small fraction excreted unchanged.

An account of the metabolic pathways of epinephrine and levonordefrin provides clarity regarding historical concerns for interactions with certain psychoactive drugs, such as monoamine oxidase inhibitors (MAOIs) and selective serotonin reuptake inhibitors (SSRIs). These drug classes are unlikely to potentiate the clinical activity of the aforementioned vasoconstrictors due to the selective metabolism via COMT. However, drugs that inhibit norepinephrine reuptake can cause prolongation and elevation of clinical effects when epinephrine or levonordefrin is administered. While patients treated with drugs such as serotonin-norepinephrine reuptake inhibitors (SNRIs), selective norepinephrine reuptake inhibitors (sNRIs), and tricyclic antidepressants may still be administered local anesthetics with vasoconstrictors, care should be taken to avoid excessive dosing resulting in cardiovascular difficulties. Similarly, central nervous system stimulants used to manage attention-deficit and attention-deficit/hyperactivity disorders also increase the concentration of norepinephrine in

the synaptic cleft. These drugs, such as methylphenidate (Ritalin® and Concerta®) and amphetamines (Vyvanse® and Adderall XR®), also carry the potential for adverse cardiovascular stimulation. Judicious use, combined with continuous cardiovascular monitoring (blood pressure/heart rate), is warranted to reduce the risk of complications.

**Common Local Anesthetic Agents**

There are many factors to consider when selecting a local anesthetic, including invasiveness and duration of the planned procedure, and desired potency and onset of the anesthetic agent. The patient’s possible drug interactions and unique pharmacokinetic concerns should also be evaluated. The most widely used local anesthetics in dentistry are lidocaine, articaine, bupivacaine, mepivacaine, and prilocaine, all of which are in the amide family and will be discussed in greater detail below.

**Lidocaine**

Lidocaine was the first amino amide-type local anesthetic and is the most widely used local anesthetic. Known for its rapid onset of action, it typically begins working within 3–5 min when used as an injectable. Topical lidocaine is available in many formulations including creams and transdermal patches. Absent a vasopressor, lidocaine produces the greatest degree of vasodilation of the commonly used anesthetics, and thus is limited for use as a plain formulation (i.e., no vasoconstrictor) for brief procedures via infiltration [7]. Lidocaine has biphasic elimination; the pharmacologically active metabolites have a longer half-life than lidocaine but are less potent sodium channel blockers. The total half-life in most patients is 90–120 min. It is one of the least irritating local anesthetic injections in comparative studies [26].

**Articaine**

Articaine solutions have demonstrated some of the highest levels of anesthetic potency with the lowest systemic toxic-

ity. Its potency is due to its high lipid solubility and increased concentration of molecules available at the injection site, factors that likely make it successful for mandibular anesthesia [7]. Fast metabolism via both the liver and the blood serum makes articaine a beneficial choice for patients with inflammation, hepatic disorders, and renal impairment [27]. Elimination half-life times for articaine are the fastest among amide anesthetics with an average of 20 min. It is available in a 4% concentration, an advantage that cannot be replicated in lidocaine due to the risk of systemic toxicity. However, at this concentration there is an increased risk of permanent paresthesia when administered via nerve blocks [28]. Articaine has shown to be equally safe and effective as lidocaine in simple and complex dental procedures [29].

## Bupivacaine

Bupivacaine is a potent long-acting local anesthetic. It has the highest percent of plasma protein binding and is the longest-acting local anesthetic available in dental cartridges. It is also the most common agent used in epidural anesthesia during labor, cited for its exceptional sensory anesthesia with minimal impairment of motor function [30]. In dentistry, bupivacaine is a common choice for longer and more invasive procedures such as third molar extractions, soft tissue grafts, and endodontic procedures where postoperative pain is expected. Bupivacaine's prolonged duration of action has been shown to limit postoperative pain. The serum half-life averages 300 min [7]. Because of its high lipid solubility, bupivacaine is prepared as a 0.5% concentration rather than the more common 2% concentration. The pKa of bupivacaine (8.1) is the highest of the common local anesthetic agents, giving it a very slow onset and often rendering it less effective in inflamed or infected tissues that favor agents with a lower pKa. Bupivacaine's delayed onset and lower pH, which approximates 5.65 and may cause increased discomfort during injection, as compared to several other plain local anesthetics has prompted many clinicians to administer bupivacaine after initially anesthetizing the patient with a faster-acting agent [31, 32]. Additionally, in stark contrast to other agents, bupivacaine toxicity tends to involve cardiac complications (i.e., bradycardia, ectopic rhythms) prior to CNS manifestations.

## Mepivacaine

Mepivacaine's onset is reasonably rapid, but it has a shorter duration of action than some of the more widely used local anesthetics with a vasoconstrictor, especially when it is administered without a vasoconstrictor. Mepivacaine demonstrates the lowest tendency to bind with plasma proteins, correlating to its relatively short duration of action.

Additionally, mepivacaine has reduced vasodilator activity and as such is commonly used as a plain solution. The lack of added epinephrine or levonordefrin makes it a beneficial choice for patients with significant cardiovascular disease, particularly ischemic heart disease, and in patients that may have harmful drug interactions with nonselective beta blockers and tricyclic antidepressants [8]. The combination of mepivacaine and bupivacaine is quite popular for regional anesthesia techniques due to mepivacaine's rapid onset and bupivacaine's prolonged duration of action. Mepivacaine is commonly utilized in patients who have reported allergic reactions following local anesthetic use as many of the reported reactions may have been caused by the vasoconstrictors. Mepivacaine is also often the preferred choice for local anesthesia in inflamed or infected tissues as it has the lowest pKa (7.6) of all the common local anesthetics, with the acidic environment present in tissues with inflammation favoring low pKa agents.

## Prilocaine

Prilocaine in its injectable form is used in dentistry, neuraxial anesthesia, and intravenous regional anesthesia. It has a relatively fast onset and intermediate duration of action. Plain prilocaine has weak vasodilatory action and is thus another acceptable alternative to those with cardiovascular concerns or allergic reactions to vasoconstrictors. In clinical comparisons of local anesthetics, it ranks as one of the least irritating agents [26]. Prilocaine is less cardiotoxic than other amides, but its metabolite, *o*-toluidine, is associated with methemoglobinemia. It is often mixed with lidocaine in equal quantities by weight for topical application. This combination of prilocaine and lidocaine forms a eutectic mixture with a lower melting point than either component has individually, enhancing its penetration and rendering it capable of maintaining higher concentrations without the need for a solvent. The mixture is commonly used in dermal anesthesia, skin grafts, and laser surgery, and is also used to anesthetize the skin before intravenous access or injection of local anesthetic.

---

## Advances in Local Anesthesia

Perpetual progress in the realm of local anesthesia has occurred ever since the isolation of cocaine by Neimann in 1860 and the early days of Drs. Koller, Halsted, and Hall. Scientific and technological advances have included the discovery of new anesthetic agents, techniques, and armamentarium. Examples of more recent developments include the local anesthetics articaine and ropivacaine, local anesthesia delivery systems specifically designed for intraosseous



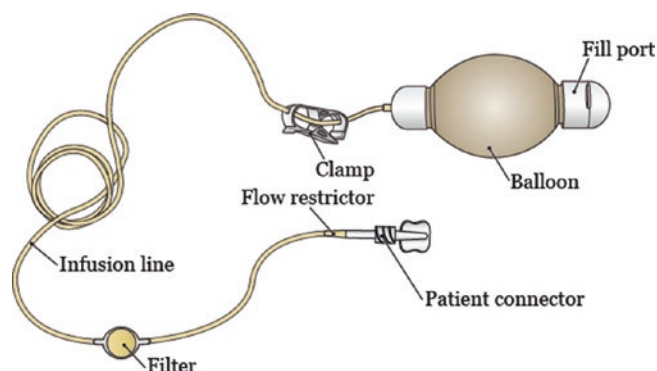
administration (Stabident® and X-tip® systems), and computer-controlled local anesthetic delivery devices (The Wand®). Despite the many advances, identification of the ideal local anesthetic devoid of any imperfections remains elusive. The following section will discuss in greater detail several of the current novel approaches involving the clinical application of local anesthesia.

## Ultrasound Guidance

Sonography is the use of high-frequency sound waves (ultrasound) to produce real-time visual images of the body's hard and soft anatomical structures. Diagnostic sonography has had a long successful track record in medicine. Its use has also been coupled with various medical and dental procedures including real-time guidance during needle insertion to help ensure accurate delivery of local anesthetics. Regional anesthesia utilizing ultrasound guidance is commonplace prior to many surgical interventions, particularly orthopedic procedures involving the limbs. This practice has continued to expand especially in light of concerns over the ongoing opioid epidemic. Several case reports and a few scientific studies have discussed ultrasound-guided regional blocks of the head and neck, particularly for maxillary or V-2 nerve blocks [33, 34]. Based on the positive results, this area likely warrants continued assessment for potential benefit of future patients.

## Elastomeric Infusion Pumps

Another area of interest is the use of an imbedded catheter combined with a pump system to provide continuous delivery of local anesthetic solution directly into the surgical site. The general concepts involved with this technique are identical to those used for an epidural, with the key differences being the use of a multi-ported catheter, placement along the peripheral wound rather than in the epidural space, and use of a non-electric elastomeric pain pump to facilitate ease of ambulation. The small elastomeric or balloon pump, roughly the size of a 12 oz. can of soda, contains a reservoir that can be filled with various local anesthetics or even other parenteral analgesics providing continuous delivery of the solution via the imbedded catheter (Fig. 1.1). The elastomeric pump and tubing can be carried in a small pouch, like a hip bag or "fanny pack," allowing patients to ambulate without being tethered down. A long-acting local anesthetic, such as bupivacaine or ropivacaine, is commonly selected. Many of the available systems permit adjustment of the infusion rate granting the ability to tailor delivery to the individual patient; however, patients must be counseled against making any unsupervised adjustments. Additionally, clinical staff and

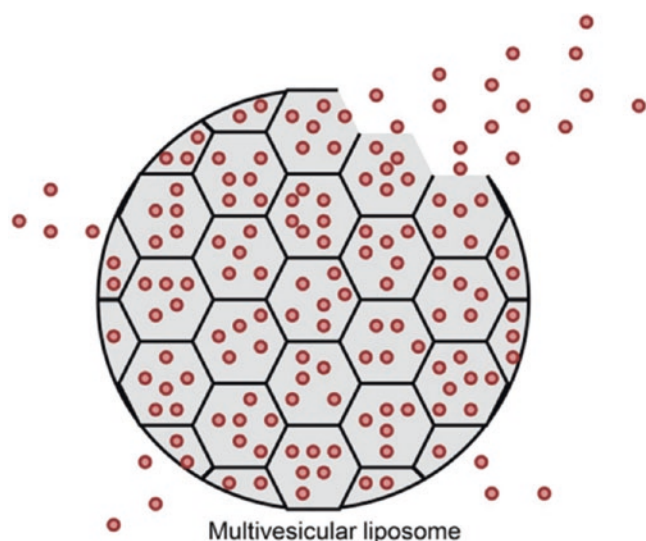


**Fig. 1.1** Local anesthetic infusion pump

clinicians must receive appropriate training on the individual pump system selected for use to ensure a thorough understanding of the settings and to prevent inadvertent overdose, which has been observed when used incorrectly. Patients can easily remove the catheter once the pump reservoir is empty and dispose of the entire system at home. While the use of these portable elastomeric pumps has predominantly involved postoperative pain management following peripheral orthopedic-type procedures, they have also been used with success for various surgical interventions involving the head and neck. This area presents yet another potential avenue for opioid-free postoperative analgesia that may be quite beneficial in high-risk populations such as patients with severe sleep apnea or morbid obesity.

## Liposomal-Encapsulated Bupivacaine (Exparel®)

While many approaches have tried to address ways to prolong the activity of local anesthetics, the use of liposomal encapsulation of local anesthetics represents a potential bright spot in the hunt for effective postoperative pain management. Exparel® combines the use of multivesicular liposomes (DepoFoam technology, Pacira Pharmaceuticals Inc., San Diego, Calif) with bupivacaine to provide long-lasting local anesthetic activity capable of extending up to 72 h (Fig. 1.2). This relatively novel agent is designed for use as an infiltrative agent only, not to be used for regional blocks. Recommended intraoral use following surgical removal of third molars included infiltrating both sides of the surgical incision. Additionally, this agent is not indicated as the primary local anesthetic due to the prolonged onset. However, it can be used safely with other injectable local anesthetics as long there is sufficient time (>20 min) between the administration of the local anesthetic agents. This concern is notably absent if bupivacaine is used initially; however, such an approach may be rendered ineffective due to the slow clinical onset of bupivacaine.



**Fig. 1.2** Liposomal-encapsulated bupivacaine

Exparel® has been used successfully as an effective component of an opioid-free postoperative pain management plan following a variety of surgical procedures including many head and neck surgical interventions. Due to the prolonged duration of action, many patients are able to experience a comfortable, relatively pain-free recovery without the need for opioid agonists, especially if combined with NSAIDs and acetaminophen. It is likely that Exparel® will grow to be a major tool in the fight against the overuse and abuse of opioids as clinicians look toward incorporating opioid-free alternatives into their practices. Currently, there is no generic alternative to Exparel® and few insurance companies provide reimbursement or coverage for use of this agent. With the cost in 2020 approximating \$300 per 20 mL vial, it is financially unfeasible for many patients.

### Kovanaze™

Marketed as a needle-free alternative, Kovanaze™ is a combination of 3% tetracaine with 0.05% oxymetazoline packaged as a single-use intranasal spray. The touted benefits of this combination include regional anesthesia of the anterior maxilla and associated teeth. It has been used to provide local anesthesia for dental procedures in adults extending posteriorly to the premolars and molars in older children, although supplemental use of more traditional injections may be needed depending on the planned surgical intervention [35]. This may be a potentially useful alternative for patients with extreme needle phobias; however, the narrow anatomic area anesthetized is a potential limiting factor for widespread use. It can also be difficult for patients to tolerate the intranasal delivery.

## References

1. Malamed SF. Handbook of local anesthesia. 7th ed. St. Louis: Elsevier; 2019. pages cm p.
2. Covino BG. Pharmacology of local anaesthetic agents. *Br J Anaesth*. 1986;58(7):701–16.
3. Ogle OE, Mahjoubi G. Local anesthesia: agents, techniques, and complications. *Dent Clin N Am*. 2012;56(1):133–48, ix.
4. López-Valverde A, de Vicente Buendia J, Cutando A. The surgeons Halsted and Hall, cocaine and the discovery of dental anesthesia by nerve blocking. *Br Dent J*. 2011;211:485–7.
5. Ruetsch YA, Boni T, Borgeat A. From cocaine to ropivacaine: the history of local anesthetic drugs. *Curr Top Med Chem*. 2001;1(3):175–82.
6. Townsend JA, Hagan JL, Smiley M. Use of local anesthesia during dental rehabilitation with general anesthesia: a survey of dentist anesthesiologists. *Anesth Prog*. 2014;61(1):11–7.
7. Becker DE, Reed KL. Local anesthetics: review of pharmacological considerations. *Anesth Prog*. 2012;59(2):90–101; quiz 2–3.
8. Haas DA, Quinn CL. Local anesthetics. In: Dowd FJ, Johnson BS, Mariotti AJ, editors. *Pharmacology and therapeutics for dentistry*. 7th ed. St. Louis: Elsevier; 2017. p. 206–20.
9. Catterall WA, Mackie K. Local anesthetics. In: Goodman LS, Brunton LL, Chabner B, Knollmann BC, editors. *Goodman & Gilman's the pharmacological basis of therapeutics*. 12th ed. New York: McGraw-Hill; 2011. p. 565–82.
10. Oertel R, Rahn R, Kirch W. Clinical pharmacokinetics of articaine. *Clin Pharmacokinet*. 1997;33(6):417–25.
11. Reed KL, Malamed SF, Fonner AM. Local anesthesia part 2: technical considerations. *Anesth Prog*. 2012;59(3):127–36; quiz 37.
12. Haas DA. An update on local anesthetics in dentistry. *J Can Dent Assoc*. 2002;68(9):546–51.
13. Kuthiala G, Chaudhary G. Ropivacaine: a review of its pharmacology and clinical use. *Indian J Anaesth*. 2011;55(2):104–10.
14. Choi S, Oh S, Lee J. Effects of lidocaine-HCl salt and benzocaine on the expansion of lipid monolayers employed as biomimicking cell membrane. *Colloids Surf B Biointerfaces*. 2001;20(3):239–44.
15. Mangiapi G, Gvaramia M, Kuhrts L, Teixeira J, Koutsoubas A, Soltwedel O, et al. Effect of benzocaine and propranolol on phospholipid-based bilayers. *Phys Chem Chem Phys*. 2017;19(47):32057–71.
16. Singh R, Al Khalili Y. Benzocaine. Treasure Island: StatPearls; 2020.
17. Artine CA, Sanchez A. Preparation of the patient for awake intubation. In: Benumof J, Hagberg CA, editors. *Benumof and Hagberg's airway management*. 3rd ed. Philadelphia: Elsevier/Saunders; 2013. p. 243–64.
18. Hafner HM, Rocken M, Breuninger H. Epinephrine-supplemented local anesthetics for ear and nose surgery: clinical use without complications in more than 10,000 surgical procedures. *J Dtsch Dermatol Ges*. 2005;3(3):195–9.
19. Ilicki J. Safety of epinephrine in digital nerve blocks: a literature review. *J Emerg Med*. 2015;49(5):799–809.
20. Rogers K. Epinephrine: Encyclopædia Britannica, inc.; 2018 updated March 16, 2018. Available from: <https://www.britannica.com/science/epinephrine>
21. Buckley JA, Ciancio SG, McMullen JA. Efficacy of epinephrine concentration in local anesthesia during periodontal surgery. *J Periodontol*. 1984;55(11):653–7.
22. Use of epinephrine in connection with procaine in dental procedures. *J Am Med Assoc*. 1955;157(10):854.
23. Margaix Munoz M, Jimenez Soriano Y, Poveda Roda R, Sarrion G. Cardiovascular diseases in dental practice. Practical considerations. *Med Oral Patol Oral Cir Bucal*. 2008;13(5):E296–302.

24. Lawaty I, Drum M, Reader A, Nusstein J. A prospective, randomized, double-blind comparison of 2% mepivacaine with 1: 20,000 levonordefrin versus 2% lidocaine with 1: 100,000 epinephrine for maxillary infiltrations. *Anesth Prog.* 2010;57(4):139–44.
25. Hoffman BB. Catecholamines, sympathomimetic drugs, and adrenergic receptor antagonists. In: Goodman LS, Hardman JG, Limbird LE, Gilman AG, editors. *Goodman & Gilman's the pharmacological basis of therapeutics*. 10th ed. New York: McGraw-Hill; 2001. p. 215–68.
26. Morris R, McKay W, Mushlin P. Comparison of pain associated with intradermal and subcutaneous infiltration with various local anesthetic solutions. *Anesth Analg.* 1987;66(11):1180–2.
27. Nizharadze N, Mamaladze M, Chipashvili N, Vadachkoria D. Articaine - the best choice of local anesthetic in contemporary dentistry. *Georgian Med News.* 2011;190:15–23.
28. Haas DA, Lennon D. A 21 year retrospective study of reports of paresthesia following local anesthetic administration. *J Can Dent Assoc.* 1995;61(4):319–20, 23–6, 29–30.
29. Malamed SF, Gagnon S, Leblanc D. A comparison between articaine HCl and lidocaine HCl in pediatric dental patients. *Pediatr Dent.* 2000;22(4):307–11.
30. Brownridge P, Plummer J, Mitchell J, Marshall P. An evaluation of epidural bupivacaine with and without meperidine in labor. *Reg Anesth.* 1992;17(1):15–21.
31. McMorland GH, Douglas MJ, Jeffery WK, Ross PL, Axelson JE, Kim JH, et al. Effect of pH-adjustment of bupivacaine on onset and duration of epidural analgesia in parturients. *Can Anaesth Soc J.* 1986;33(5):537–41.
32. Frank SG, Lalonde DH. How acidic is the lidocaine we are injecting, and how much bicarbonate should we add? *Can J Plast Surg.* 2012;20(2):71–3.
33. Sola C, Raux O, Savath L, Macq C, Capdevila X, Dadure C. Ultrasound guidance characteristics and efficiency of suprazygomatic maxillary nerve blocks in infants: a descriptive prospective study. *Paediatr Anaesth.* 2012;22(9):841–6.
34. Kim SM, Seo MH, Myoung H, Lee JH. Regional anesthesia for maxillofacial surgery in developing countries. *J Dent Anesth Pain Med.* 2016;16(4):245–52.
35. Capetillo J, Drum M, Reader A, Fowler S, Nusstein J, Beck M. Anesthetic efficacy of intranasal 3% tetracaine plus 0.05% oxymetazoline (Kovanaze) in maxillary teeth. *J Endod.* 2019;45(3):257–62.

# Intraoral Maxillary Local Anesthesia Techniques

# 2

Steven Halepas, Leslie A. Hoffman, and Michael T. Goupil

## Introduction

Intraoral maxillary local anesthesia injections are routine among the dental profession but are less common among many other surgical subspecialties. The use of intraoral maxillary injections can be useful in many cosmetic procedures of the midface. In procedures involving the lower eyelid, zygomatic area, and upper lip, a maxillary injection may be warranted, and the use of intraoral injections may pose a benefit.

Local infiltration is the application of local anesthesia to the area of interest, an example being the site of an incision. A field block is a technique used to anesthetize nerves just proximally to the site they innervate, often utilized to minimize any anatomical distortion. A nerve block is using a local anesthetic to anesthetize an entire nerve branch such as an inferior alveolar nerve block.

## Armamentarium

The three main components needed for local anesthesia are the syringe, the needle, and the local anesthetic. Most commonly used in the dental office is the side loading dental

syringes, but some carry the base-loading dental syringes. Often in a hospital setting, providers will use basic single-use disposable syringes in either 3 or 10 cc sizes. The dental syringes are generally metal and can be placed in sterilization autoclaves. The dental syringes have a harpoon that engages the stopper at the end of the cartridge allowing for aspiration. Dental cartridges are typically made of glass and generally come in 1.7 or 1.8 cc of anesthetic solution. Local anesthetics outside of dentistry come in small vials that are often single-use and need to be drawn up. A larger needle is used to draw up the solution from the vials. The needles used for injection are typically a 25 or 27 gauge with a beveled edge. Smaller than a 27-gauge needle poses risk of being unable to properly aspirate. Patients do not have an increased level of pain with the larger 25-gauge size, especially when topical anesthesia is applied [1].

## Basic Injection Techniques

With intraoral injections, the provider must understand the regional anatomy in order to properly anesthetize the area as well as minimize any potential complications. When preparing to inject, the needle should be placed in the proper anatomical position for the intended type of injection and ideally in a 90-degree angle from the oral mucosa to facilitate an atraumatic entry point. The needle should then be positioned in the correct plane for the type of injection planned. It is important to aspirate, pull back on the syringe plunger, before injecting to determine if any blood is aspirated into the syringe. If the aspiration is negative, meaning no blood entered the chamber, then it is safe to inject the local anesthetic. If the aspiration is positive, the provider should remove the needle and reinsert at a slightly different angle and aspirate again [2].

S. Halepas  
New York-Presbyterian/Columbia University Medical Center,  
New York, NY, USA  
e-mail: [sh3808@cumc.columbia.edu](mailto:sh3808@cumc.columbia.edu)

L. A. Hoffman  
Department of Anatomy, Cell Biology, & Physiology, Indiana  
University School of Medicine, Indiana, IN, USA  
e-mail: [lesahoff@iu.edu](mailto:lesahoff@iu.edu)

M. T. Goupil (✉)  
Division of Oral and Maxillofacial Surgery, University of  
Connecticut School of Dental Medicine, Farmington, CT, USA  
Consultant in Oral and Maxillofacial Surgery,  
Carmel, Indiana, USA  
e-mail: [mtgoupil@comcast.net](mailto:mtgoupil@comcast.net)

## Anatomy of the Maxillary Division (V<sub>2</sub>) of the Trigeminal Nerve

The maxillary division (V<sub>2</sub>) of the trigeminal nerve arises from the trigeminal ganglion (also called the semilunar ganglion, Gasserian ganglion, or Gasser's ganglion) within a pocket of dura called Meckel's cave. Meckel's cave is located on the floor of the middle cranial fossa near the apex of the petrous part of the temporal bone posterior to foramen lacerum. The maxillary division is a purely sensory nerve that supplies the mid-face, maxillary teeth and gingiva, nasal cavity, and nasopharynx.

The first branch of the maxillary division is the middle meningeal nerve, which arises within the cranial vault and supplies sensation to the dura mater. The maxillary nerve then courses along the lateral wall of the cavernous sinus before passing through foramen rotundum to enter the pterygopalatine fossa.

The maxillary nerve gives off several branches within the pterygopalatine fossa before passing through the inferior orbital fissure to enter the floor of the orbit, at which point it becomes the infraorbital nerve. The infraorbital nerve crosses the floor of the orbit to enter the infraorbital canal and emerges onto the face at the infraorbital foramen. The infraorbital nerve supplies sensory innervation to the cheek, inferior eyelid, lateral aspect of the nose, and upper lip.

The zygomatic nerve branches off the maxillary nerve within the pterygopalatine fossa and enters the orbit via the inferior orbital fissure where it divides into two branches: the zygomaticotemporal and the zygomaticofacial nerves. The zygomaticotemporal nerve enters the zygomatic bone and emerges in the temporal fossa where it ascends a short distance deep to temporalis muscle before piercing the temporalis fascia to supply the skin of the temple. The zygomaticotemporal branch also carries postganglionic parasympathetic fibers from the pterygopalatine ganglion to the lacrimal nerve via a communicating branch. The zygomaticofacial nerve traverses the zygomatic bone and emerges via the zygomaticofacial foramen deep to the orbicularis oculi muscle. It pierces this muscle to supply the skin over the prominence of the cheek.

The posterior superior alveolar nerve arises from the maxillary nerve within the pterygopalatine fossa just distal to the pterygopalatine ganglion. It traverses the pterygomaxillary fissure to enter the infratemporal fossa and travels inferiorly on the infratemporal surface of the maxilla toward the maxillary tuberosity. The nerve enters the maxilla via the posterior superior alveolar foramina and supplies sensation to the maxillary molars.

The remaining branches of the maxillary nerve arise from the pterygopalatine ganglion within the pterygopalatine fossa. The nasopalatine nerve passes through the sphenopal-

atine foramen and crosses the posterior aspect of the nasal cavity to reach the nasal septum. The nerve travels anteriorly along the nasal septum to reach the incisive canal in the hard palate to enter the roof of the oral cavity. The nasopalatine nerve supplies the posteroinferior portion of the nasal septum and the anterior hard palate. Posterior superior nasal nerves also pass through the sphenopalatine foramen to reach the lateral wall of the nasal cavity where they supply the posterior aspect of the superior and middle nasal conchae.

The greater and lesser palatine nerves arise from the pterygopalatine ganglion inferiorly and then descend through the greater palatine canal toward the hard palate. The greater palatine nerve emerges via the greater palatine foramen and travels anteriorly to supply sensation to the hard palate. The lesser palatine nerve emerges via the lesser palatine foramen and passes posteriorly to supply sensation to the soft palate. While in the palatine canal, the greater palatine nerve can often give off the posterior inferior nasal branches, which supply sensation to the inferior concha. The pharyngeal nerve arises from the pterygopalatine ganglion posteriorly and enters the palatovaginal canal to supply sensation to the superior aspect of the nasopharynx.

---

## Supraperiosteal Injection

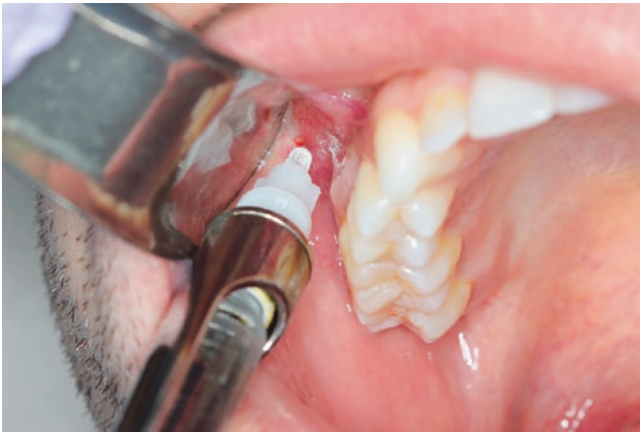Supraperiosteal injection is often called local infiltration in the dental field. Local infiltration is often used whenever a limited area needs anesthesia. This is often the case in single tooth extractions for maxillary teeth. In this technique, the needle is positioned just laterally to the tooth that is to be anesthetized. The needle passes through the mucosa at the mucobuccal fold aiming for what would be the tooth root apex. Once the bone is contacted, the needle is retracted and 0.5–1 cc of local anesthetic delivered.

---

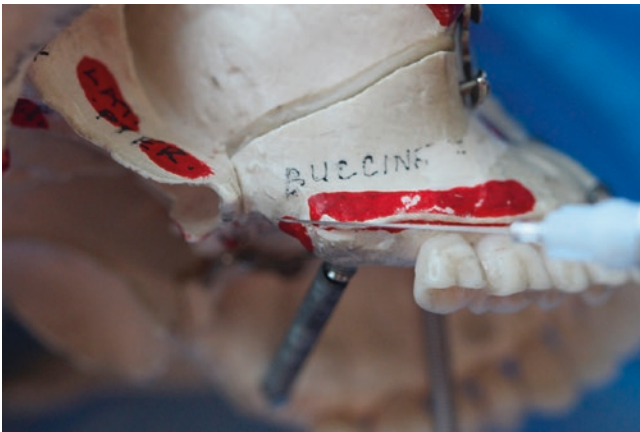## Posterior Alveolar Nerve Block

It is recommended to use a 25-gauge long needle for a posterior superior alveolar nerve block. Topical anesthetic can be applied to the oral mucosa. Using a Minnesota retractor, pull back on the buccal mucosa so the mucobuccal fold becomes taut. The needle should be inserted at the mucobuccal fold just distal to the maxillary tuberosity (Fig. 2.1). As the needle is advanced it should be directed in a superior direction generally at about a 45-degree angle to the occlusal plane of the maxillary teeth to a depth of about 1 cm (Fig. 2.2). The needle should pass through the oral mucosa and then hit the periosteum along the posterior aspect of the maxillary tuberosity. It is important to aspirate before injecting. Generally, about 1–2 cc of local anesthesia is injected. Some providers “bend





**Fig. 2.1** For a posterior alveolar nerve block, the needle is inserted at the mucobuccal fold just distal to the maxillary tuberosity



**Fig. 2.2** For a posterior alveolar nerve block, the needle is inserted at a 45-degree angle to all three facial planes

the needle” in order to achieve the steep angle in this tight area of the mouth. While the authors do not encourage this technique, if one is to bend the needle ensure that it is along the shaft of the needle and not at the end. Bending the needle as it inserts into the plastic connection (the hub) is the weakest point. A bent needle at the hub can break and be lost in the mucosa.

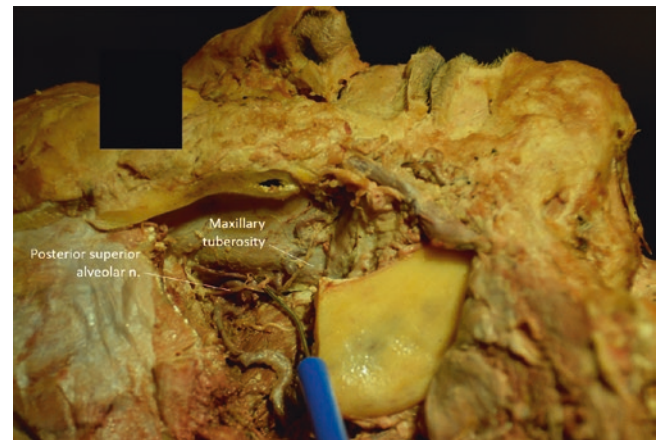
The posterior superior alveolar nerve arises from the maxillary nerve within the pterygopalatine fossa just distal to the pterygopalatine ganglion (Fig. 2.3). It traverses the pterygomaxillary fissure to enter the infratemporal fossa and courses inferiorly on the posterolateral (i.e., infratemporal) surface of the maxilla toward the maxillary tuberosity. Near the center of the infratemporal surface of the maxilla are 2–3 alveolar foramina which transmit the posterior superior alveolar nerves. The nerves are accompanied by branches of the posterior superior alveolar artery, which arise from the maxillary artery within the pterygopalatine fossa. The posterior superior alveolar nerve supplies sensation to the maxillary

second and third molars and two of the three roots of the maxillary first molar usually sparing the mesiobuccal root.

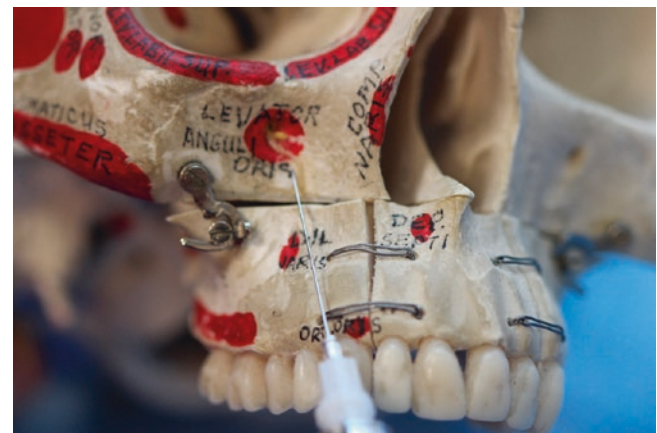### Infraorbital Nerve Block

Place the patient in a seated upright position where the occlusal plane is about 45 degrees from the floor. Topical anesthesia can be placed on the overlying mucosa. Using a Minnesota retractor, hold the buccal mucosa taut so the mucobuccal fold is well defined. The needle should be inserted at the apex of the mucobuccal vestibule at the level between the first and second premolar (Figs. 2.4 and 2.5). The needle is advanced superiorly and parallel to the root axis of the second premolar. Again, it is important to aspirate to ensure the needle is not intravascular. About 1–2 cc of local anesthesia will generally effectively achieve local anesthesia [3–5].

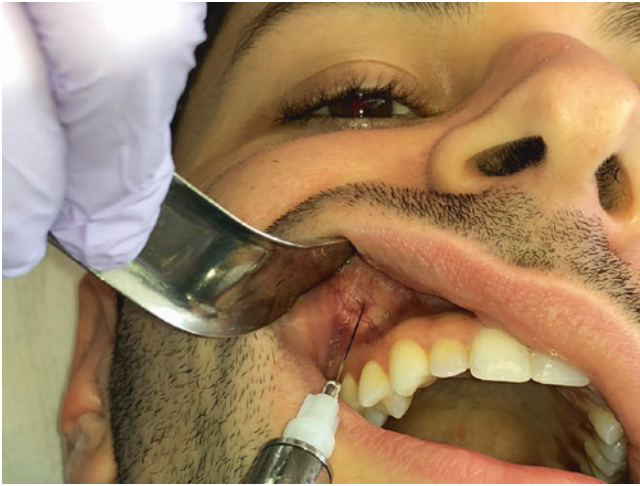The infraorbital nerve is the direct continuation of the maxillary nerve after passing through the pterygopalatine



**Fig. 2.3** Posterior superior alveolar nerve located on the infratemporal surface of maxilla. (Photo credit: Jamaica Westfall-Snyder)



**Fig. 2.4** For an infraorbital nerve block, the anesthetic needle is directed parallel to the bicuspid teeth superiorly to the infraorbital fossa

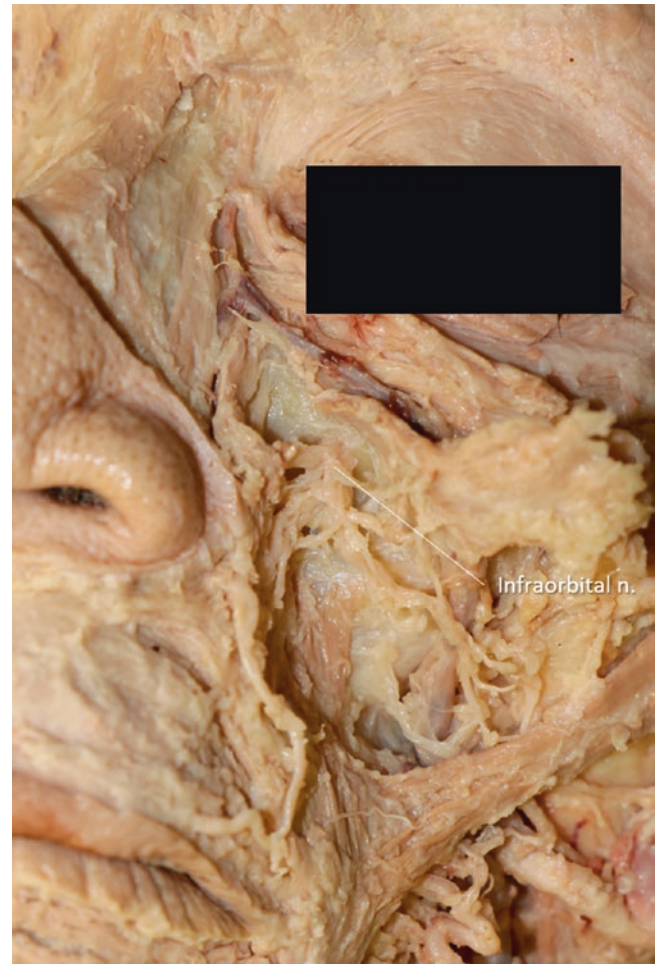


**Fig. 2.5** For an infraorbital nerve block, the anesthetic needle is inserted at the depth of the mucobuccal fold in the region of the bicuspid teeth

fossa and traversing the inferior orbital fissure to enter the floor of the orbit. About halfway between the apex of the orbit and the anterior orbital margin, the nerve enters the infraorbital canal. As the infraorbital nerve courses through the infraorbital canal, it gives off the anterior and middle superior alveolar nerves which supply sensation to the anterior maxillary teeth and associated gingiva. The infraorbital nerve then emerges on the anterior aspect of the maxilla via the infraorbital foramen, which is located approximately 1 cm below the inferior orbital margin, between the origins of the levatorlabii superioris and levatorangulioris muscles (Fig. 2.6). Levatorlabii superioris muscle arises just superior to the infraorbital foramen from the inferior margin of the orbit, and levatorangulioris arises from the canine fossa just inferior to the infraorbital foramen. In terms of external landmarks, the infraorbital foramen is most often located along a line connecting the lateral edge of the ala of the nose with the lateral palpebral commissure [3]. The infraorbital nerve gives off palpebral, nasal, and superior labial branches. The palpebral branches ascend to supply the skin of the lower eyelid, and nasal branches supply the side of the nose. Several superior labial branches descend deep to levator labii superioris muscle and supply the skin of the anterior cheek and upper lip.

### Greater Palatine Nerve Block

The greater palatine foramen is located just palatally to the second molar on either side of the maxilla (Fig. 2.7). The position can vary anywhere from opposite the second molar to distal to the third molar. A cotton tip applicator can be used to apply pressure adjacent to the greater palatine foramen or be used to find the depression signifying you have



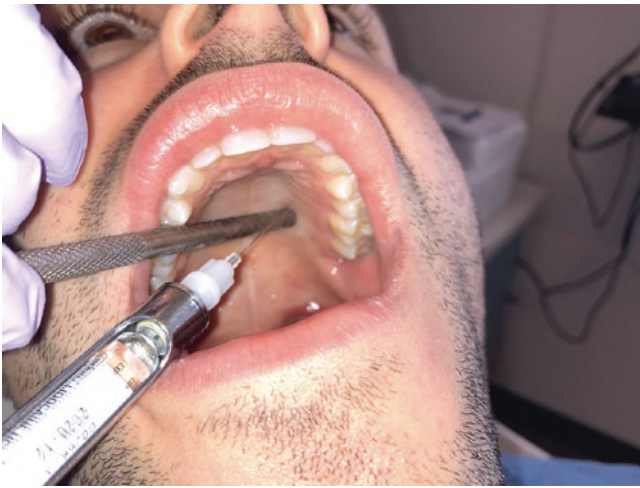**Fig. 2.6** Infraorbital nerve emerging from the infraorbital foramen



**Fig. 2.7** For greater palatine nerve block, the anesthetic is deposited in the area of the greater palatine foramen

correctly located the foramen. The syringe should be placed from the opposite side from the nerve you are injecting (Fig. 2.8). The needle is then advanced through the mucosa just about 2 mm anterior to that of the greater palatine foramen.





**Fig. 2.8** For the greater palatine nerve block, the anesthetic needle is inserted from the opposite side of the oral cavity

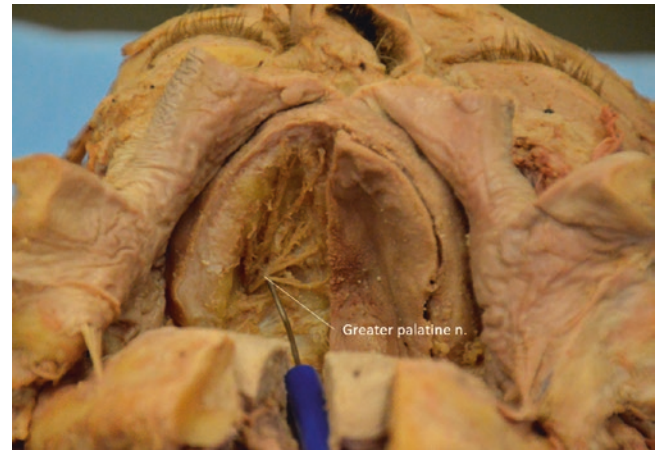
men. A small amount of anesthetic (0.3 cc) can be delivered to note the blanching of the tissues. The needle can then be uprighted and advanced into the canal or until the bone is contacted. Depending on the provider's angle, entrance into the canal may be difficult but depositing just adjacent to the foramen often achieves an anesthetic block. Aspiration should then be performed and more anesthetic (0.5 cc) delivered if aspiration is negative [6–9].

The greater palatine nerve arises from the pterygopalatine ganglion within the pterygopalatine fossa and descends through the greater palatine canal. The canal is formed by a vertical groove on the maxillary surface of the palatine bone and the adjacent part of the maxilla that articulates there. The greater palatine canal opens on the hard palate through the greater palatine foramen, which is most often located opposite the third maxillary molar, although its position can vary between the second and third molars or, occasionally, distal to the third molar [10]. After emerging from the greater palatine foramen, the greater palatine nerve travels anteriorly within a groove near the alveolar border of the hard palate (Fig. 2.9). The hard palate is covered by a thick mucosa that is tightly attached to the underlying periosteum, and, in the lateral regions also includes a submucosa that contains the neurovascular bundle. The greater palatine artery accompanies the greater palatine nerve within the greater palatine canal and on the hard palate. The greater palatine nerve supplies sensory innervation to the mucosa of the hard palate as far anteriorly as the incisors. It communicates with terminal branches of the nasopalatine nerve, which supplies the anteriormost part of the hard palate just posterior to the incisors.

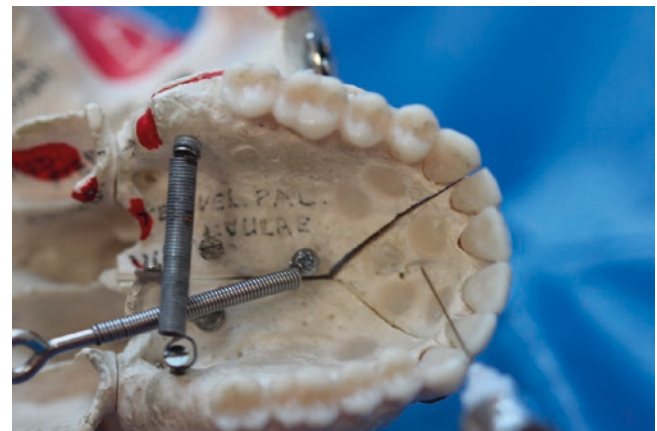## Nasopalatine Nerve Block

A nasopalatine nerve block is performed by injecting posterior to the maxillary midline between the two central incisors (Fig. 2.10). The needle is inserted about 6–7 mm posterior from the incisal edges of the central incisors at the anatomical location of the incisive foramen (Fig. 2.11). The needle is advanced into the incisive foramen and a slow deposit of anesthetic solution about 0.5 cc is used [11–13].

The nasopalatine nerve leaves the pterygopalatine fossa via the sphenopalatine foramen and enters the nasal cavity where it crosses the posterior wall to reach the nasal septum. The nerve travels anteriorly and inferiorly within a groove on the vomer and then descends into the incisive canal, which opens inferiorly onto the hard palate via the incisive foramina within the incisive fossa (Fig. 2.12). The incisive fossa is

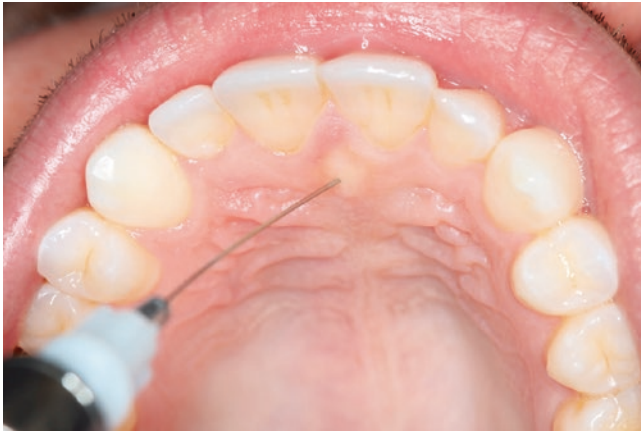

**Fig. 2.9** Greater palatine nerve emerging from the greater palatine foramen. (Photo credit: Jamaica Westfall-Snyder)

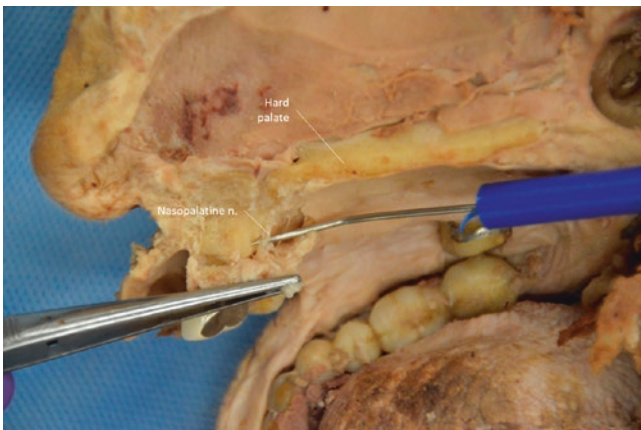


**Fig. 2.10** The nasopalatine foramen is located behind the maxillary central incisors





**Fig. 2.11** For a nasopalatine nerve block, the anesthetic needle is inserted through the incisive papilla into the incisive canal



**Fig. 2.12** Nasopalatine nerve emerging from the incisive canal. (Photo credit: Jamaica Westfall-Snyder)

located in the midline just posterior to the incisors. In the midline of the hard palate, the mucosa forms a narrow ridge, the palatine raphe, which ends anteriorly at a prominence called the incisive papilla just posterior to the central incisors. The incisive papilla overlies the incisive fossa, where the nasopalatine nerve emerges onto the hard palate. After emerging from the incisive canal, the nasopalatine nerve supplies sensory innervation to the anterior aspect of the hard palate posterior to the incisors.

## Maxillary Nerve Block

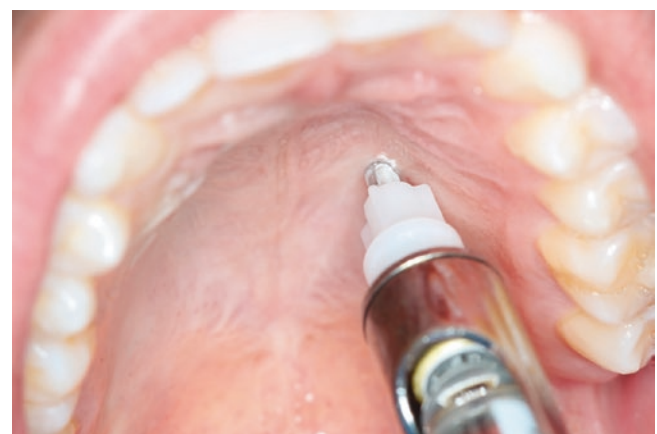A cotton tip applicator can be used to apply pressure adjacent to the greater palatine foramen as described earlier. The greater palatine foramen can be located either in the middle of the maxillary second molar to the middle of the maxillary third molar. The optimal angle of insertion into the greater palatine canal is about 45 degrees from the horizontal plane

of the hard palate. The needle should be slowly advanced until the hub is reached (about 32 mm). Aspiration should be performed and 1.7 cc should be delivered [14] (Fig. 2.13).

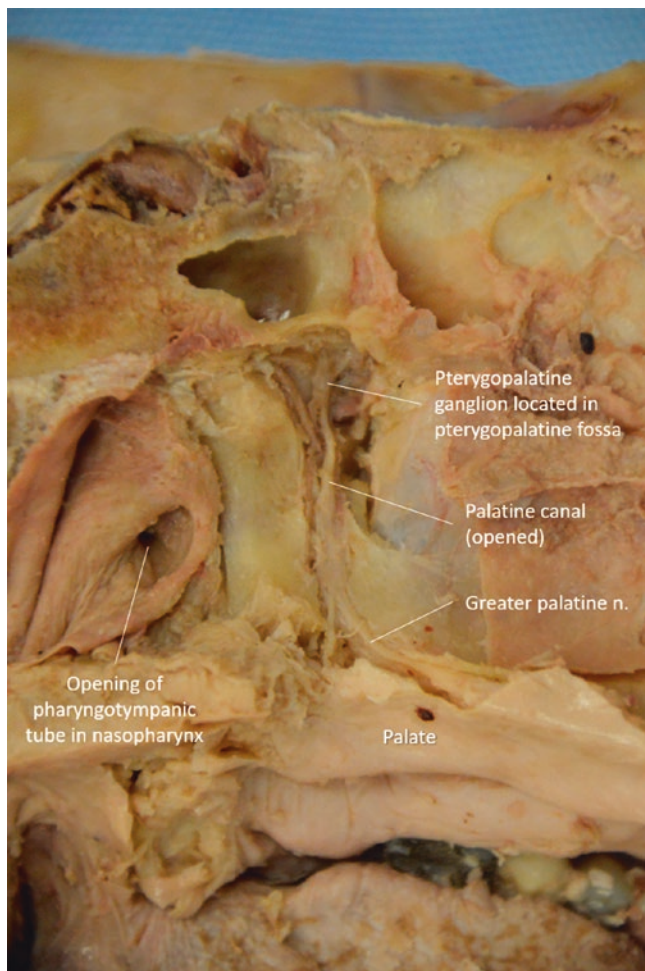
As previously described, the maxillary nerve travels through the pterygopalatine fossa where it gives rise to many branches that are distributed to other regions in the head and face. The pterygopalatine fossa is a small, pyramidal space located below the apex of the orbit between the maxilla and the pterygoid process of the sphenoid bone. There are seven openings by which structures can pass into and out of the pterygopalatine fossa. Posteriorly, the pterygopalatine fossa communicates with the middle cranial fossa via foramen rotundum and the pterygoid canal, and with the nasopharynx via the palatovaginal canal. Anteriorly, the inferior orbital fissure opens into the orbit. The sphenopalatine foramen on the medial wall of the fossa opens into the nasal cavity. The pterygomaxillary fissure communicates laterally with the infratemporal fossa, and the greater palatine canal opens inferiorly into the oral cavity.

The pterygopalatine fossa houses the pterygopalatine ganglion, which is connected to the maxillary nerve via two ganglionic branches (Fig. 2.14). Many branches of the maxillary nerve arise from the ganglion but are not functionally associated with it. The pterygopalatine ganglion receives preganglionic parasympathetic fibers from the greater petrosal nerve, a branch of the facial nerve (CN VII), which joins the deep petrosal nerve to form the nerve of the pterygoid canal (Vidian nerve). This nerve traverses the pterygoid canal to reach the ganglion within the pterygopalatine fossa. Also located within the pterygopalatine fossa is the third part of the maxillary artery, which gives rise to several branches, many of which are distributed with branches of the maxillary nerve.

The entire maxillary nerve can be anesthetized within the pterygopalatine fossa resulting in anesthesia of the



**Fig. 2.13** For a maxillary second division nerve block, the anesthetic needle is directed superiorly through the greater palatine nerve canal to the pterygopalatine fossa



**Fig. 2.14** Anatomy of the palatine canal and pterygopalatine fossa. (Photo credit: Jamaica Westfall-Snyder)

entire hemi-maxilla, including the maxillary teeth and gingiva, mucosa of the hard and soft palate, maxillary sinus, nasal cavity, and skin of the mid-face. The pterygopalatine fossa can be accessed via the greater palatine canal, which begins inferiorly at the greater palatine foramen on the hard palate and opens superiorly into the pterygopalatine fossa.

## Summary

Knowledge of regional anatomy allows the surgeon to select an appropriate anesthetic technique to provide both anesthesia and hemostasis to the area of interest. This knowledge is necessary to provide anesthesia in a safe and effective manner.

## References

1. Fuller NP, Menke RA, Meyers WJ. Perception of pain to three different intraoral penetrations of needles. *J Am Dent Assoc.* 1979;99:822–4.
2. Reed KL, Malamed SF, Fonner AM. Local anesthesia part 2: technical considerations. *Anesth Prog.* 2012;59:127–36; quiz 137.
3. Ercikti N, Apaydin N, Kirici Y. Location of the infraorbital foramen with reference to soft tissue landmarks. *Surg Radiol Anat.* 2017;39:11–5.
4. Zdilla MJ, Russell ML, Koons AW. Infraorbital foramen location in the pediatric population: a guide for infraorbital nerve block. *Paediatr Anaesth.* 2018;28:697–702.
5. Aggarwal A, et al. Anatomical study of the infraorbital foramen: a basis for successful infraorbital nerve block. *Clin Anat.* 2015;28:753–60.
6. Hafeez NS, et al. Ultrasound-guided greater palatine nerve block: a case series of anatomical descriptions and clinical evaluations. *Anesth Analg.* 2014;119:726–30.
7. Iwanaga J, et al. New supplemental landmark for the greater palatine foramen as found deep to soft tissue: application for the greater palatine nerve block. *Surg Radiol Anat.* 2017;39:981–4.
8. Chrcanovic BR, Custódio AL. Anatomical variation in the position of the greater palatine foramen. *J Oral Sci.* 2010;52:109–13.
9. Ajmani ML. Anatomical variation in position of the greater palatine foramen in the adult human skull. *J Anat.* 1994;184(Pt 3):635–7.
10. Tomaszewska IM, et al. Anatomical landmarks for the localization of the greater palatine foramen—a study of 1200 head CTs, 150 dry skulls, systematic review of literature and meta-analysis. *J Anat.* 2014;225:419–35.
11. Thakur AR, Burde K, Guttal K, Naikmasur VG. Anatomy and morphology of the nasopalatine canal using cone-beam computed tomography. *Imaging Sci Dent.* 2013;43:273–81.
12. Lake S, et al. The incisive canal: a comprehensive review. *Cureus.* 2018;10:e3069.
13. Soumya P, Koppolu P, Pathakota KR, Chappidi V. Maxillary incisive canal characteristics: a radiographic study using cone beam computerized tomography. *Radiol Res Pract.* 2019;2019:6151253.
14. Malamed SF, Trieger N. Intraoral maxillary nerve block: an anatomical and clinical study. *Anesth Prog.* 1983;30:44–8.

# Intraoral Local Mandibular Anesthesia

# 3

Benjamin Anderson and Chandler L. Walker

## Introduction

With regard to intraoral local anesthesia, the mandibular arch can represent a more formidable challenge than the maxilla (see Chap. 2). The procedures are not only technically difficult, but also challenging and demanding from a patient management perspective. Patients consistently determine the competence of their provider by the comfort and efficacy of local anesthesia delivery. If you can deliver painless, profound local anesthesia consistently, you are well on your way to earning the confidence of your patients [1]. The objective of this chapter is to give the healthcare provider clear technical, anatomical, and pharmacological information, substantiated by research and experience, with the aim of developing successful, consistent local anesthesia of the mandibular arch.

*For a description of the anatomy of the mandibular branch of the trigeminal nerve see section “Mental Nerve Block”.*

Traditionally, there are three primary techniques for achieving unilateral anesthesia of the mandible: (1) the inferior alveolar nerve (IAN) block (Halstead Block), (2) Gow-Gates block, and (3) Vazirani-Akinosi block [2]. Cases of irreversible pulpitis, and patients who experience difficulties achieving the desired anesthetic effect may necessitate additional techniques such as intraosseous delivery or intrapulpal of anesthesia, which will also be discussed. Supplemental nerve blocks are another important aspect of providing profound anesthesia. For example, the long buccal block is used

regularly with the IAN block to anesthetize the buccal mucosa and accessory innervation to the molars [3]. Similarly, the mylohyoid block can be important when extracting posterior mandibular molars or performing endodontic therapy.

## General Injection Principles

### Anesthesia Basics

- Aspirate prior to anesthetic injection
- Obtain a thorough patient medical history
- Document vital functions of the patient before injection
- Do not bend the needle at the hub during injection
- Do not inject the needle all the way to the hub
- Wait for a sufficient time period for adequate anesthesia before re-injecting
- Do not anesthetize the mandibular arch with articaine
- If intraoral tissue balloons upon injection (indicating shallow injection), withdraw and reinsert the syringe needle deeper into the tissue at the given location

### Improving Patient Comfort

- Inject anesthesia slowly (38 mg/30s+)
- Use a new, sharp needle for the injection
- Ensure the tissue designated for injection is stretched taut
- Distract tissues by shaking mucosa or using syringe vibrator
- Topical anesthesia should be placed on dried mucosa 5 min prior to injection
- Warm the local anesthesia cartridge or syringe before injection

B. Anderson  
Department of Advanced Prosthodontics, Indiana University  
School of Dentistry, Indianapolis, IN, USA  
e-mail: [habander@iu.edu](mailto:habander@iu.edu)

C. L. Walker (✉)  
Department of Biomedical Sciences and Comprehensive Care,  
Indiana University School of Dentistry, Indianapolis, IN, USA  
e-mail: [chalwalk@iu.edu](mailto:chalwalk@iu.edu)



- Mix Sodium bicarbonate with local anesthetic (LA) (not typical cartridge delivery)
- Use a smaller needle diameter
- Avoid bilateral mandibular anesthesia when possible
- Initial injection with less acidic LA, followed by primary LA, for example, lidocaine and articaine
- If local anesthetic drips into patient's tongue area, quickly remove with saliva ejector as it is very bitter

Complications can arise and the provider must be prepared for such an eventuality; however, every effort must be made to prevent them. Prevention is accomplished by making a thorough health history and obeying a few simple principles. Below are a few common complications and how to avoid them:

- Intravascular Injection:** (1) Study your anatomy and needle placement, (2) ALWAYS aspirate before injecting
- Paresthesia, Permanent Anesthesia, Dyesthesia:** (1) Relocate needle BEFORE injection if patient experiences "electrical shock" sensation, (2) avoid anesthetics associated with nerve toxicity on IAN blocks
- Needle Separation:** (1) Do not bend needle at hub, (2) Do not insert needle to hub, (3) Select larger diameter gauge needle (27+) for deeper injections
- Overdose:** (1) Weigh the children and calculate appropriate max dose using 2.2 mg/kg (max. 4.4 mg/kg) [4], (2) Maximum 11 carpules of 2% lidocaine with 1:100,000 epinephrine for adults (7 mg/kg max) [4]

**Cardiac Event:**

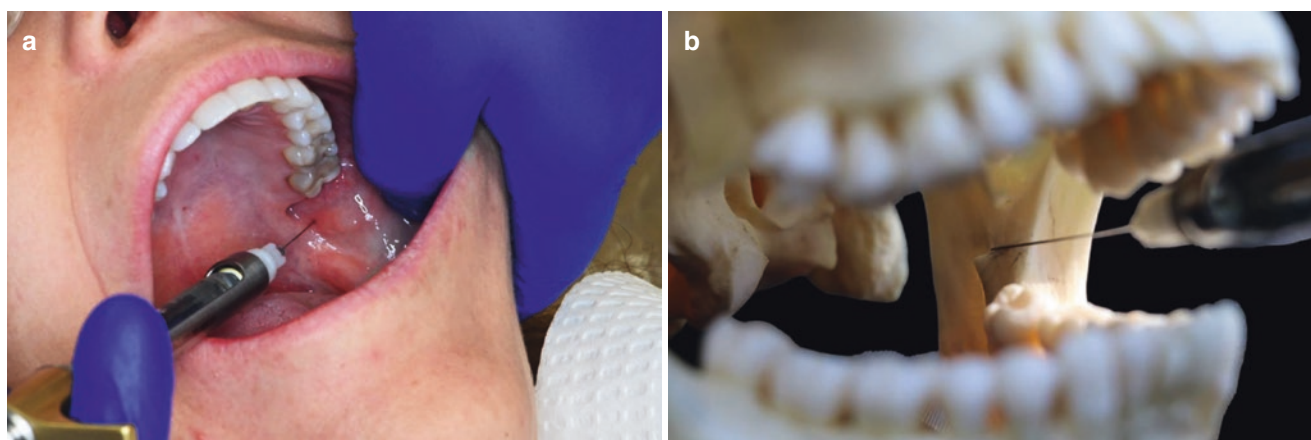
- (1) Limit epinephrine to the equivalent of two carpules of LA of 2% lidocaine with 1:100,000 epi in patients with hypertension, and following myocardial infarction (MI), (2) Review medications that are contraindicated and have adverse effects with epinephrine [5–7]

## Mandibular Block Techniques

### Inferior Alveolar Nerve Block (IANB) [3, 5]

**Technique:**

1. If right-handed, place left thumb on the coronoid notch (see Fig. 3.1) and the index finger on posterior aspect of ramus as a reference.
2. Identify Needle Penetration Site:
  - (a) Vertical Position (relative to patient): Visualize the pterygomandibular raphe and follow it upward until it curves vertically toward the maxilla. If you imagine a line from your thumb to this point it should be roughly parallel with and 1 cm superior to the mandibular plane of occlusion. This approximates your height of injection.
  - (b) Anteroposterior Position: Determine the position approximately three quarters from the anterior of the ramus or halfway between your thumb (in coronoid notch) and the posterior border of the ramus (also visually approximated by the pterygomandibular raphe (Fig. 3.1a, b).

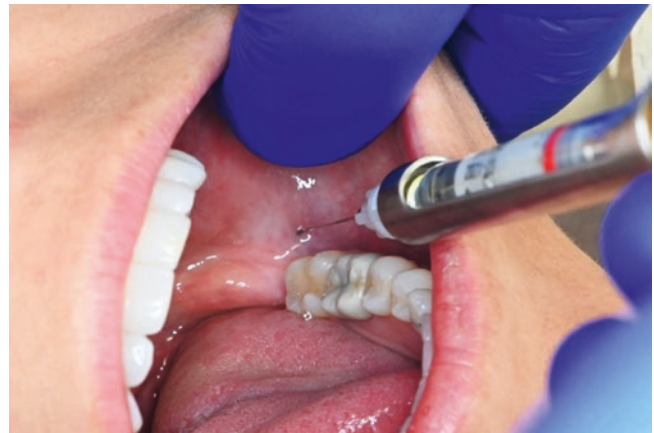

**Fig. 3.1** (a) Anatomic location for proper reference identification and needle placement for the inferior alveolar nerve block (IANB). (b) Osteology location for proper reference identification and needle placement for the inferior alveolar nerve block (IANB)

3. Holding syringe in other hand, obtain a finger rest with ring finger and pinky, position barrel at contralateral commissure and aim a long needle (27 gauge or larger) at the intersection point identified in step 2.
4. While pulling the buccal mucosa taut with your thumb, gently push the needle through the mucosa until you contact the bone.
5. Advance the needle posteriorly, maintaining contact with the medial ramus, until about two-thirds to three-fourths of the needle is inserted. The needle tip should be just posterior and superior to the lingula.
6. Aspirate. If positive, reposition the needle without completely withdrawing and repeat aspiration until negative. If cartridge contains too much blood to distinguish between future positive/negative aspiration, withdraw and replace cartridge.
7. Once negative aspiration is achieved, slowly deposit most of the local anesthetic (approximately 1.5 mL of the 1.7 mL cartridge), withdraw until one-fourth of the syringe remains inserted, aspirate and if negative, deposit remaining local anesthetic (approximately 0.2 mL) in order to also anesthetize lingual nerve.
8. Withdraw the needle and syringe from mouth, reassure the patient that they did well, and recap the needle using one-hand-scoop technique.
9. Wait for at least 5 min. Either you or a trained personnel should remain with the patient as local anesthesia takes effect as most cardiac and syncopal events will occur during this window of time.
10. Determine profound lip and tongue anesthesia by asking the patient whether their lips and tongue “feel tingly or thick” [5].

### Long Buccal Nerve Block (Supplemental to IANB)

1. If right-handed, use the left index finger to pull the buccal mucosa taut lateral to the mandibular third molar
2. With bevel down and syringe parallel to plane of occlusion, penetrate the buccal mucosa distal and buccal to the last molar (Fig. 3.2)
3. Advance the needle until the periosteum is *gently* contacted
4. Aspirate. Depth of penetration should only be 1–2 mm, maximum of 4 mm
5. Slowly inject about one-fifth of cartridge contents (0.3 mL)
6. Withdraw needle and recap using one-hand-scoop technique
7. Wait for at least 1 min before starting the dental procedure

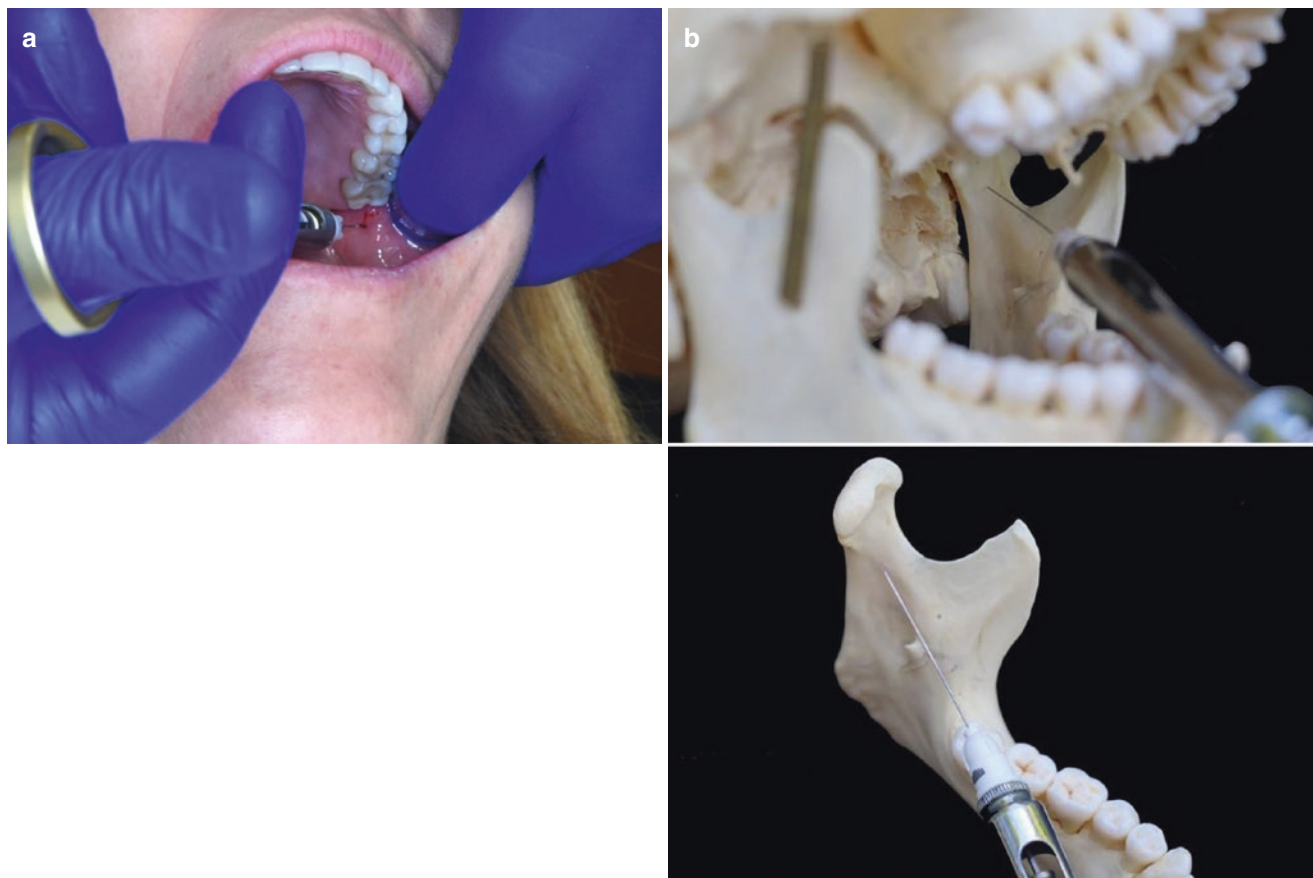


**Fig. 3.2** Anatomic location for administration of a long buccal nerve block as a supplement to IANB

### Gow-Gates Mandibular Nerve Block

#### Technique and Position

1. Positioning: Place the patient in a supine position. Using a 27 to 25 gauge needle, and sitting at the patient's 8 o'clock position for a right-side block, or a 10 o'clock position for a left-side block, orient the needle intraorally toward the condyle, pointed toward the inferior most part of the tragus on that side, while the barrel of the syringe is at the opposite corner of the mouth. It is often helpful before positioning the needle to palpate and determine the position of the coronoid notch and aim just posterior and slightly superior to reach the appropriate target on the anterior part of condyle. Intraorally, if the patient is edentate, the needle should pass just inferior to the mesiolingual cusp of the maxillary second molar and enter the mucosa just distal to the second molar (or third molar if erupted).
2. After identifying landmarks and appropriate position, ensure the patient is opening widely without closure and slowly advance the needle until contact is made with the bone. Generally, if positioned appropriately, the needle will penetrate the tissue at about 25 mm by the time it hits the bone, roughly equivalent to that of the IANB. If the bone is not contacted, pull the needle out slightly, examine your landmarks and consider repositioning laterally. Once you have determined why you missed the bone, readvance toward the condyle (Fig. 3.3a, b).
3. Withdraw the needle by 1-mm, aspirate; if negative, slowly deposit local anesthesia. If positive, pull it out slightly and reposition the needle more superiorly and try again.
4. Withdraw needle and syringe from mouth, reassure patient they did well, and recap needle using one-hand-scoop technique.



**Fig. 3.3** (a) Anatomic location for administration of a Gow-Gates mandibular nerve block. (b) Osteology location for administration of a Gow-Gates mandibular nerve block

5. Malamed suggests that the patient remain open for 1–2 min after injection to permit appropriate diffusion of the bolus. If you do this, offer something to the patient to make them comfortable such as a bite block.
6. Make the patient sit upward and wait for a minimum of 3–5 min, then ask the patient whether their tongue and lip feel “thick” or “tingly.” Generally, if both feel “thick” both the IAN and the lingual nerve are adequately anesthetized to proceed. If only “tingly,” wait for a few minutes and ask again. In many instances, the difference between profound anesthesia and discomfort is not more LA, it is patience [5].

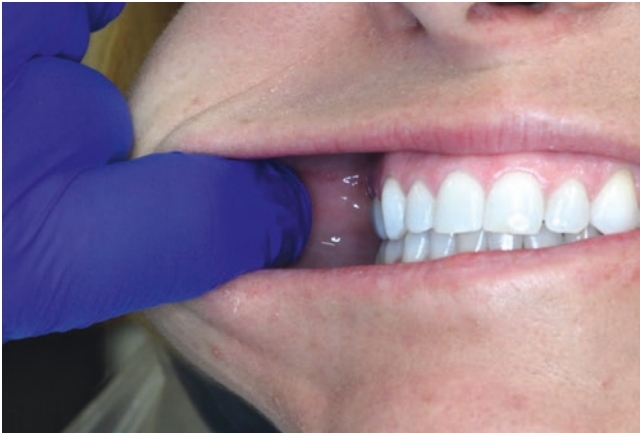### Vazirani-Akinosi Nerve Block

The Vazirani-Akinosi nerve block, often just called the “Akinosi Nerve Block” is an important technique in that it allows the provider to deliver local anesthesia to a patient with limited mouth opening. If the patient’s limited mouth opening is related to trauma, infection, or postinjection trismus, this is indeed very helpful to allow for subsequent opening and treatment.

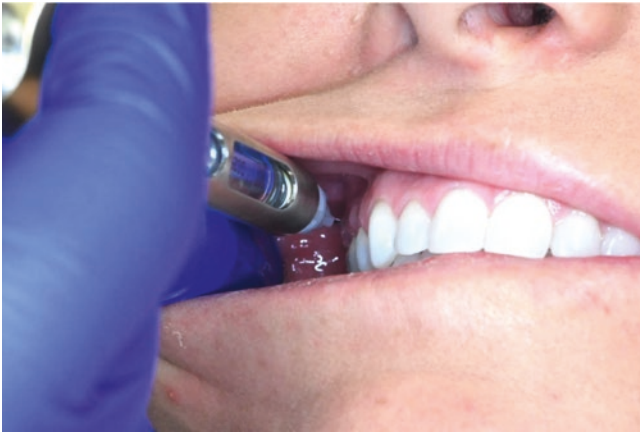### Technique

1. Sit at 8 o’clock position for either left or right block with patient in supine position.
2. Ask the patient to occlude the teeth, relax the cheeks as you retract soft tissue. Visualize landmarks:
  - (a) Mucogingival junction of most posterior maxillary molar, maxillary tuberosity
  - (b) With thumb in coronoid notch, reflect soft tissue from medial ramus laterally (Fig. 3.4)
3. A 25- to 27-gauge long needle with bevel facing midline (pointed side lateral) is advanced between the cheek and the maxillary teeth at the level of the mucogingival junction, while keeping the syringe parallel to the maxillary plane of occlusion (Fig. 3.5).
4. Penetrate mucosa just medial to ramus (kept tight by retraction) approximately 25 mm with the maxillary tuberosity as your reference point (Fig. 3.6).
5. Aspirate, if negative, deposit the bolus over 60 s. If positive, examine landmarks and reposition.
6. Withdraw needle and syringe from mouth, reassure patient they did well, and recap needle using one-hand-scoop technique.

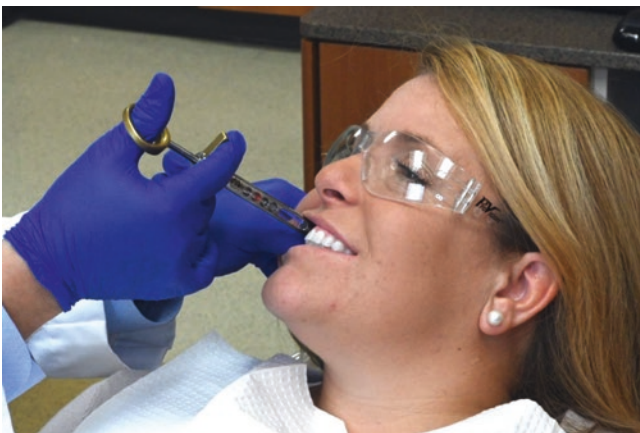



**Fig. 3.4** Lateral reflection of soft tissue from the medial ramus (Fig. 4) in preparation for the Vazirani-Akinosi nerve block



**Fig. 3.5** Syringe placement between the cheek and the maxillary teeth at the level of the mucogingival junction for the Vazirani-Akinosi nerve block



**Fig. 3.6** Profile view depicting the angle of syringe placement for Vazirani-Akinosi nerve block

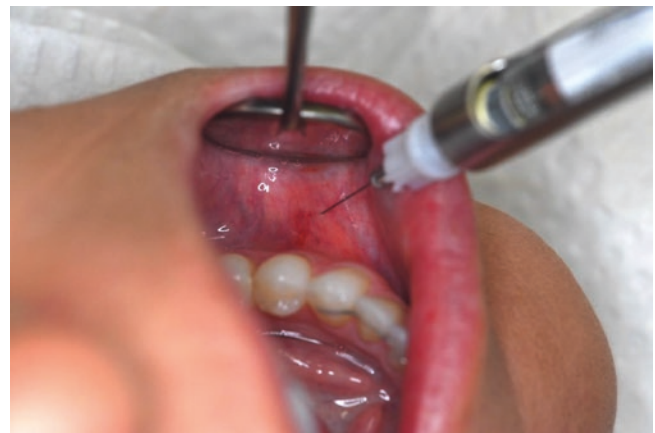7. Wait at least 5 min. Either you or a trained personnel should remain with patient as local anesthesia takes effect as most cardiac and syncopal events will occur during this window of time.
8. Determine profound lip and tongue anesthesia by asking patient whether their lips and tongue “feel tingly or thick” [5].

## Accessory Mandibular Nerve Blocks

### Incisive Nerve Block

Often inappropriately called the “mental” nerve block, the incisive nerve block is a very useful and easy block to obtain anesthesia of the pulp, bone, and buccal soft tissue of mandibular premolars forward.

1. Position the patient in a supine or semi-supine position.
2. Palpate the mental foramen, which should feel like a concave indentation on the buccal bone between the roots of the mandibular premolars.
3. Pulling the buccal mucosa tautly and using a short 27- or 30-gauge needle with the bevel toward the bone, place the tip of the needle at the mucobuccal fold or just anterior to the mental foramen (Fig. 3.7).
4. Slowly advance the needle to a depth of 5 mm. Entering the mental foramen is unnecessary and can introduce complications and should be avoided.
5. Aspirate. If negative, continue. If positive, pull out, reposition, and try again.
6. Slowly inject about a 0.6 mL of local anesthesia. The distended tissue should only slightly bulge.



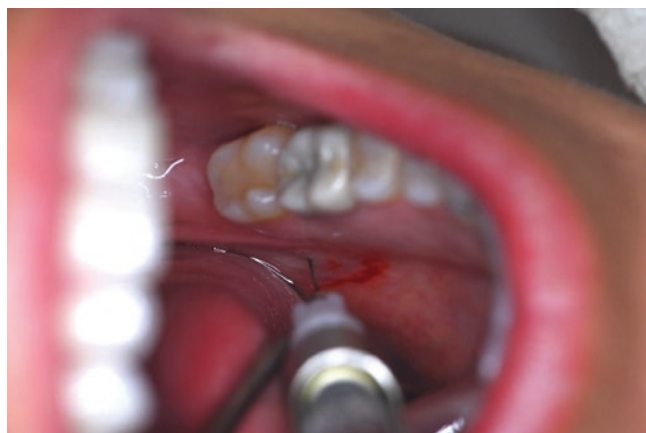**Fig. 3.7** Anatomic placement of the syringe needle at the mucobuccal fold or just anterior to the mental foramen for proper administration incisive nerve block

7. Withdraw needle and syringe from mouth, reassure patient they did well, and recap needle using one-hand-scoop technique.
8. Wait for 3–5 min. Either you or a trained personnel should remain with patient as local anesthesia takes effect as most cardiac and syncopal events will occur during this window of time.
9. Determine profound lip and tongue anesthesia by asking the patient whether their lip is “feeling tingly or thick.” Remember, this block does not anesthetize the patient’s tongue, so an additional block maybe necessary for more invasive procedures [5].
6. Slowly inject about a one-third carpule of local anesthesia. The distended tissue should only slightly bulge.
7. Withdraw needle and syringe from mouth, reassure patient they did well, and recap needle using one-hand-scoop technique.
8. Wait for 3–5 min. Either you or a trained personnel should remain with patient as local anesthesia takes effect as most cardiac and syncopal events will occur during this window of time.
9. Determine profound tongue anesthesia by asking patient whether their tongue is “feeling tingly or thick” [5].

## Mylohyoid Block

This is most often used to help achieve lingual anesthesia when IANB was too low and/or did not achieve lingual anesthesia due to potential cervical accessory nerves. It is not infrequently needed when extracting third molars.

1. Position the patient in a supine or semi-supine position.
2. Palpate the mental foramen, which should feel like a concave indentation on the buccal bone between the roots of the mandibular premolars.
3. Retract tongue with mouth mirror and make mucosa of floor of mouth taut, insert long 27-gauge needle one tooth posterior to the one to be treated, around its apex (Fig. 3.8).
4. Slowly advance the needle until it touches the bone, gently pull back slightly.
5. Aspirate. If negative, continue. If positive, pull out, reposition and try again.



**Fig. 3.8** Syringe placement for effective administration of a mylohyoid block

## Intraosseous

Various techniques have been advanced by Stabident, X-Tip, and TuttleNumbNow, each with proprietary instructions. Intraosseous anesthesia can be highly effective and predictable but requires additional instrumentation. The major benefit of intraosseous anesthesia is nearly immediate numbness, which facilitates a shorter operating time for both patient and practitioner.

## Summary

Thorough knowledge of the regional anatomy and adherence to recognized techniques makes local anesthesia of the mandible both predictable and safe. When anesthesia is unsuccessful, it is usually due to a variation of the patient’s anatomy or improper technique. Regardless of the cause when attempting to re-anesthetize the area, the provider should not exceed the recommended anesthetic doses.

## References

1. Lipp M, Daubländer M, Fuder H. Local anesthesia in dentistry. Chicago: Quintessence Pub. Co.; 1993. 164 pp.
2. Meechan JG. Practical dental local anaesthesia. In: Wilson NHF, editor. London: Quintessence; 2002.
3. Lee CR, Yang HJ. Alternative techniques for failure of conventional inferior alveolar nerve block. *J Dent Anesth Pain Med.* 2019;19(3):125–34.
4. Malamed SF. Handbook of local anesthesia. 6th ed. St. Louis: Elsevier/Mosby; 2013.
5. Malamed SF. Handbook of local anesthesia. 5th ed. St. Louis: Elsevier/Mosby; 2004. xiii, 399 pp.
6. Ogle OE, Mahjoubi G. Local anesthesia: agents, techniques, and complications. *Dent Clin N Am.* 2012;56(1):133–48, ix.
7. Tentindo G, Rosenberg M. Methemoglobinemia and local anesthesia: what every dentist should know. *J Mass Dent Soc.* 2010;59(2):18–20.



# Transfacial Local Anesthesia Techniques

# 4

Jessica N. Byram, Derek Decloux, Christopher Haxhi,  
and Michael T. Goupil

## Introduction

The *Trigeminal nerve* (cranial nerve V) provides the vast majority of the sensory innervation to the face. Each of the three nerves pass through the skull via their respective foramina to innervate the face segmentally and are named according to the regions they terminate: the eye, maxilla, and mandible. Each nerve has at least one principal sensory branch that pass through foramina of skull bilaterally at the mid-pupillary line via the supraorbital, infraorbital, and mental foramina. The first branch, the ophthalmic nerve ( $V_1$ ), passes through the superior orbit to innervate the anterior scalp, forehead, upper eyelid, and dorsum of the nose. The second branch, the maxillary nerve ( $V_2$ ), innervates the lateral nose, upper lip, lower eyelid, superior cheek, and anterior temple. The third branch of the trigeminal nerve is the mandibular nerve ( $V_3$ ). The mandibular nerve is a mixed sensory and motor nerve where its sensory branches supply the temporal region of the scalp, anterior ear, inferior cheek, chin, and lower lip (Fig. 4.1).

While the majority of the sensory innervation to the face is provided by the Trigeminal nerve and its branches, the *great auricular nerve* provides the remaining innervation. The great auricular nerve originates from the anterior rami of the cervical plexus and innervates the skin of the posterior aspect of the external ear and angle of the mandible.

J. N. Byram (✉)  
Indiana University, Indianapolis, IN, USA  
e-mail: [jbyram@iu.edu](mailto:jbyram@iu.edu)

D. Decloux  
University of Toronto, Toronto, ON, Canada

C. Haxhi  
University of California Los Angeles, Los Angeles, CA, USA

M. T. Goupil  
Division of Oral and Maxillofacial Surgery, University of  
Connecticut School of Dental Medicine, Farmington, CT, USA

Consultant in Oral and Maxillofacial Surgery,  
Carmel, Indiana, USA

## Ophthalmic Nerve ( $V_1$ ) Blocks

The *ophthalmic nerve* ( $V_1$ ) exits the skull via the superior orbital fissure. As it passes through the superior orbit, it gives off several cutaneous branches that will innervate the superior portions of the face: the supraorbital, supratrochlear, infratrochlear, external nasal, and lacrimal nerves. The principal sensory branch of  $V_1$  is the *supraorbital nerve* which exits the orbit via the supraorbital notch or foramen and notches superiorly over the orbital rim to the forehead (Fig. 4.2). It innervates the middle part of the upper eyelid, and the anterolateral forehead and scalp to the vertex.

The *supratrochlear nerve* is a smaller branch that bifurcates with the supraorbital nerve and travels to the superomedial orbit to ascend the forehead. It innervates the medial part of the upper eyelid and the medial forehead. Travelling within the medial orbit inferior to the trochlea is the *infratrochlear nerve*. This nerve innervates the skin of the medial canthus and the lateral root of the nose. The *external nasal nerve* is a terminal branch of the anterior ethmoidal nerve that emerges from the nasal cavity between the nasal bone and the lateral nasal cartilage. It provides innervation to the skin of the dorsum of the nose to the apex. Finally, the *lacrimal nerve* runs superolaterally through the orbit and innervates a small area of skin in the lateral upper eyelid.

## Technique

Note: Refer to Fig. 4.3 to review the sensory distribution of the supraorbital and supratrochlear nerves and Fig. 4.4 for the location of the nerves and the anesthetic needle entry point.

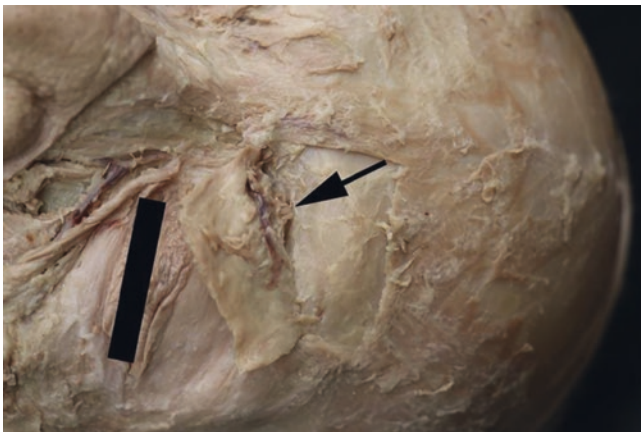
### Supraorbital and Supratrochlear Nerve Blocks

1. Have the patient seated in a comfortable position with the facial muscles relaxed.



**Fig. 4.1** Cutaneous distribution of the trigeminal nerve from anterior (left) and lateral (right). The Ophthalmic nerve supplies the anterior scalp, forehead, dorsum of the nose, and upper eyelid (red). The maxillary nerve supplies the lateral nose, lower eyelid, upper lip, anterior

cheek, and temple (orange). The mandibular nerve supplies the lower lip, chin, inferior cheek, anterior ear, and the temporal region of the scalp (yellow)

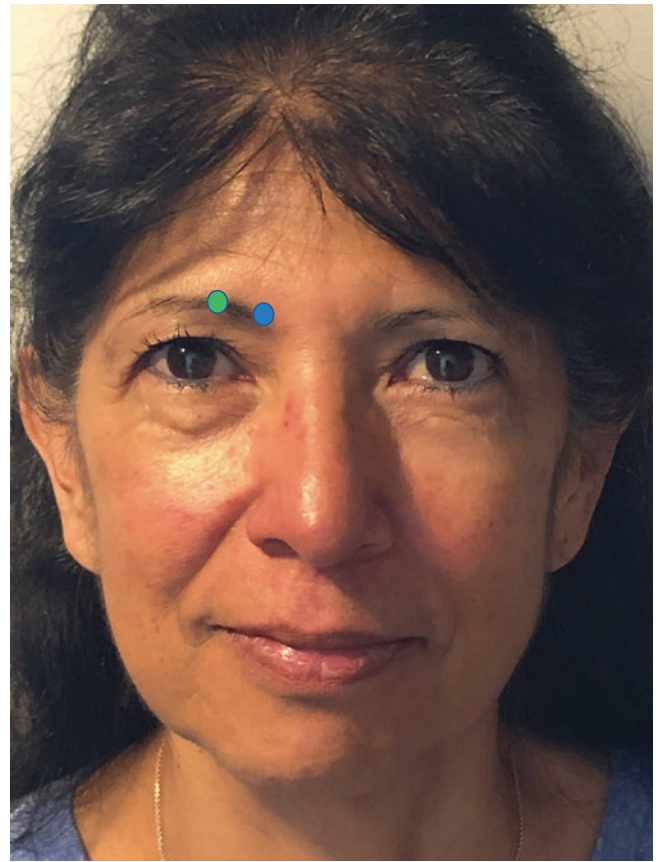

**Fig. 4.2** Supraorbital nerve. Exits the orbit through the supraorbital notch or foramen near the mid-pupillary line (arrow). It ascends to innervate the skin of the forehead and medial upper eyelid

2. Palpate the superior orbital rim to locate the superior orbital rim or notch. This should be approximately 2.2 cm from the facial midline [1].
3. Once the foramen or notch is located, clean the medial eyebrow with an alcohol prep pad. Allow an adequate amount of time for the alcohol to dry.
4. Using a 25–30 gauge anesthetic needle, enter the skin overlying the notch. Take care to direct the needle medially. The medial angulation of entry prevents the needle from entering the foramen directly and avoids injury to the nerve [2].
5. Advance the needle to the periosteum.
6. Aspirate the syringe to ensure the needle is not intravascular.
7. Deposit 1–2 mL to achieve anesthesia of the supraorbital nerve.
8. An additional 2 mL of anesthetic can be injected in an attempt to block the supratrochlear nerve.
9. Alternatively, the above procedure can be repeated to block the supratrochlear nerve but instead enter the skin 1 cm more medially.
10. If after a few minutes, adequate anesthesia has not been achieved, follow the same procedures outlined above, but enter the skin both medially and laterally to the original point of entry.



**Fig. 4.3** The sensory distribution of both the supraorbital nerve (green) and supratrochlear nerve (blue)

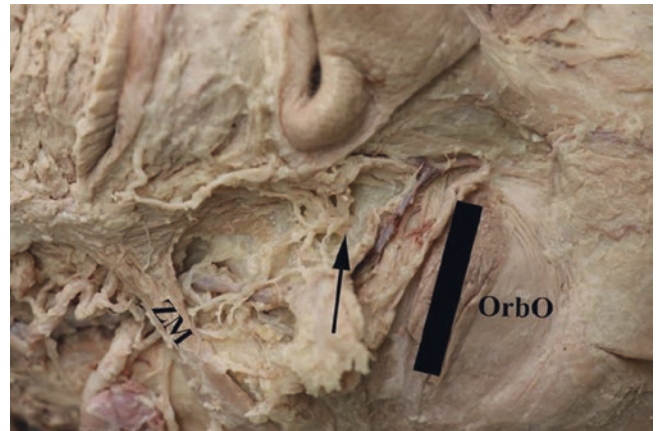


**Fig. 4.4** The approximate locations of the supraorbital nerve (green) and supratrochlear nerve (blue)

### Maxillary Nerve ( $V_2$ ) Blocks

The *maxillary nerve* ( $V_2$ ) exits the cranium via the foramen rotundum. It passes through the pterygopalatine fossa and continues anteriorly to enter the orbit through the inferior orbital fissure where it gives off two primary branches: infraorbital and zygomatic nerves. The principle sensory branch of  $V_2$  is the *infraorbital nerve* which passes through the infraorbital groove in the floor of the orbit and exits the skull through the infraorbital foramen of the maxilla (Fig. 4.5). The infraorbital nerve supplies the skin of the lower eyelid, lateral nose, anterior cheek, and upper lip.

The *zygomatic nerve* runs along the lateral wall of the orbit and gives rise to two cutaneous branches: zygomaticofacial and zygomaticotemporal nerves. The *zygomaticofacial nerve* is the smaller of the two branches which exits the skull through a small foramen in the body of the zygomatic bone.



**Fig. 4.5** Infraorbital nerve. Exits the maxilla through the infraorbital foramen near the mid-pupillary line (arrow). It innervates the skin of the lower eyelid, lateral nose, anterior cheek, and upper lip. ZM zygomaticus major muscle, OrbO orbicularis oculi muscle



It innervates the skin at the prominence of the cheek. The *zygomaticotemporal nerve* exits through a foramen on the posterolateral aspect of the zygomatic bone and ascends toward the temple. It innervates the hairless region of the anterior temple.

## Technique

Note: These nerves are routinely anesthetized intraorally by dental professionals via similar techniques, only that they are completed inside the mouth, and are described elsewhere in this textbook.

### Maxillary Nerve Block

Traditionally, an inferozygomatic approach was described to anesthetize the maxillary nerve. There are noteworthy complications with the approach that include arterial puncture, puncture of the pharyngeal wall, and injection into the orbit. As such, both the suprazygomatic and infrazygomatic approach will be described so to allow practitioners to weigh the advantages and disadvantages of each before proceeding.

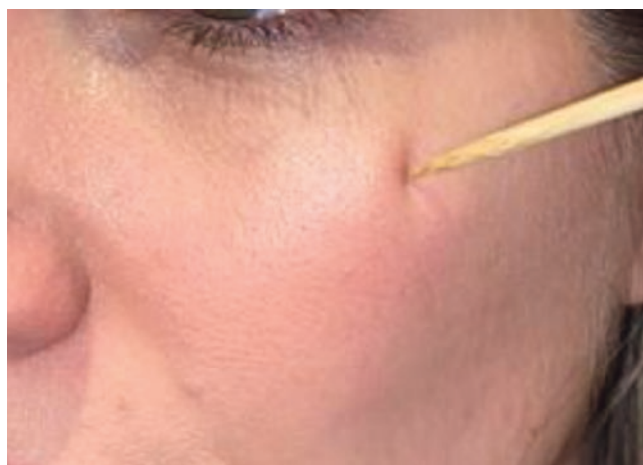
### Infrazygomatic Approach to Maxillary Nerve Blockade

1. Position the patient supine or semi-supine.
2. Have the patient open their mouth slightly (incisal edge of maxillary incisors to incisal edge of mandibular incisors ~1 cm).
3. The clinician is aiming to pass the needle tip through an imaginary half-ovoid shape bound superiorly by the zygomatic arch, inferiorly by the mandibular notch (superior border of the ramus), anteriorly by the coronoid process, and posteriorly by the condylar process. These borders should be palpated to appreciate their location. The tragus can act as a surrogate approximation of the condylar head.
4. In order to reduce risk of arterial puncture, needle puncture the skin as superiorly as the zygomatic arch will permit. The point of puncture should be centered on the mandibular notch.
5. Following perpendicular skin puncture with a 22- or 25-gauge needle, the needle is advanced medially without superior angulation approximately 2–4 cm depth until it contacts the lateral pterygoid plate.
6. Once the lateral pterygoid plate is contacted, withdraw the needle slightly and angle the needle antero-superiorly toward the pterygopalatine fossa.
7. Once a paresthesia is elicited, an aspiration maneuver can occur to ensure the tip of the needle is not in a vascular structure.

8. Following a negative aspiration, slowly deposit up to 5 mL of local anesthesia.
9. A successful block will have the patient experience numbness/tingling of the ipsilateral lower eyelid, upper lip, and lateral nose.

### Suprazygomatic Approach to Maxillary Nerve Blockade

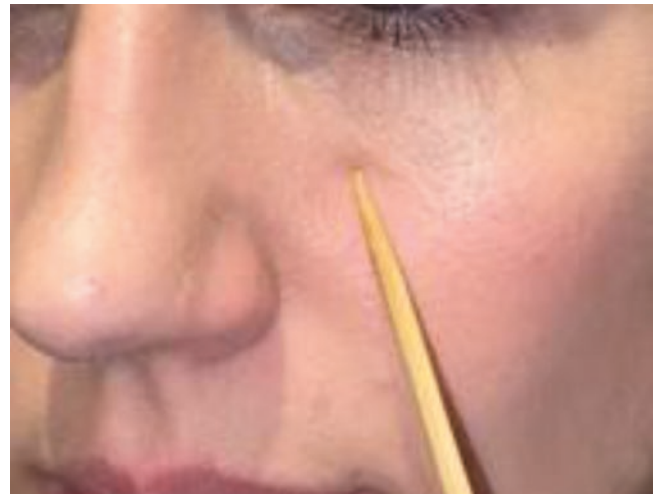1. Position the patient supine.
2. With your index finger, palpate and denote (or mark) the superior border of the zygomatic arch – this is the first landmark.
3. With your index finger, palpate and denote (or mark) the posterior border of the orbital rim – this is the second landmark.
4. With a 22- or 25-gauge needle, puncture the skin perpendicular to where these two landmarks intersect and advance the needle 1–1.5 cm until the sphenoid bone is contacted (Fig. 4.6).
10. Once the sphenoid bone is contacted, withdraw the needle slightly and angle the needle inferoposteriorly and advance the needle and additional 3–5 cm toward the pterygopalatine fossa.
11. Once a paresthesia is elicited, an aspiration maneuver can occur to ensure the tip of the needle is not in a vascular structure.
12. Following a negative aspiration, slowly deposit up to 5 mL of local anesthesia.
13. A successful block will have the patient experience numbness/tingling of the ipsilateral lower eyelid, upper lip, and lateral nose.



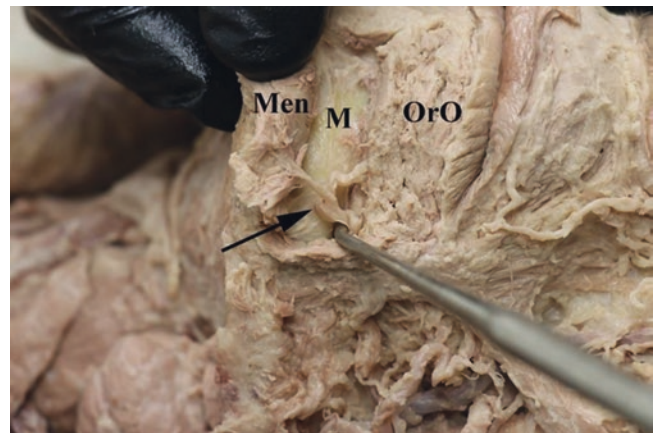
**Fig. 4.6** Entry point for a suprazygomatic approach to maxillary nerve blockade

### Anterior Superior Alveolar Nerve Block (Also Known as the Infraorbital Nerve Block)

1. Position the patient supine or semi-supine.
2. With your index finger, palpate extraorally the patient's infraorbital ridge inferior to the globe until a small depression is appreciated (generally mediolaterally centered with the patient's pupil) – this is the infraorbital notch.
3. Palpate immediately inferior to the infraorbital notch where, after your finger transverses a convex bony prominence (the lower border of the orbit), a concave surface is felt. It is in this bony depression which the infraorbital foramen is located. This may feel slightly uncomfortable for the patient.
4. Once the infraorbital foramen is located, either maintain a finger or mark the skin on its position.
5. Given that the infraorbital foramen is angulated supero-laterally, the barrel of the anesthetic syringe should be inferolateral to the infraorbital foramen such that the needle tip is facing in a superomedial direction in order to advance the needle in a perpendicular direction to the foramen; this is to prevent over-insertion of the needle into the foramen and potential puncture of the orbit.
6. With a 25- or 27-gauge needle, puncture the skin and advance the needle until the needle touches the bone. The bevel should be facing the infraorbital foramen and the needle tip should be touching the roof of the infraorbital foramen.
7. Perform an aspiration maneuver to ensure that the tip of the needle is not intravascular.
8. Following a negative aspiration maneuver, deposit 1–1.5 mL of local anesthetic into the foramen over a minimum of 30 s while concurrently applying digital pressure on the foramen. This pressure should be maintained for a minimum of 1 min and both prevents hematoma formation and may aid in the propagation of local anesthetic further into the foramen.
9. Wait a minimum of 3 min before observing whether the patient is experiencing subjective signs of anesthesia (e.g., tingling/numbness in the area of the ipsilateral lower eyelid, lateral nose, and upper lip). (Fig. 4.7).



**Fig. 4.7** Entry point for infraorbital nerve block

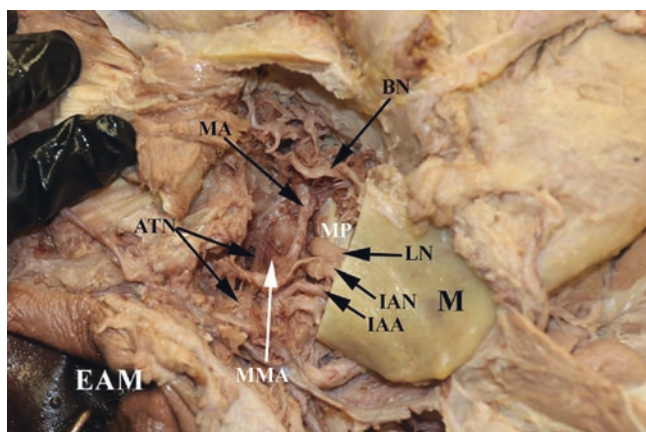


**Fig. 4.8** Mental nerve. Exits the mandible through the mental foramen inferior to the second premolar (arrow). It innervates the skin of the lower lip and chin. M mandible, OrO orbicularis oris muscle, Men mentalis muscle (reflected)

### Mandibular Nerve ( $V_3$ ) Blocks

The *mandibular nerve* ( $V_3$ ) exits the cranium through the foramen ovale. It traverses through the infratemporal fossa where it gives off three cutaneous branches: mental, auriculotemporal, and buccal nerves. The first principle sensory branch of  $V_3$  is the mental nerve. The *mental nerve* travels within the mandibular canal and exits the mandible through the mental foramen located inferior to the second premolar tooth (Fig. 4.8). The mental nerve supplies the skin of the chin and lower lip.

The *auriculotemporal nerve* is the second principle sensory branch of  $V_3$ . It passes posteriorly to the ramus of the mandible and temporomandibular joint to ascend toward the temporal bone (Fig. 4.5). As it passes between the external acoustic meatus and neck of the mandible, it innervates the skin anterior to the ear, tragus, and anterior helix of the external ear. As it travels superiorly with the superficial temporal artery and vein, it innervates the skin of the posterior temporal region. The *buccal nerve* travels anterior to the masseter muscle and runs on the surface of the buccinator muscle on its way to innervate the skin of the cheek as far as the corner of the mouth. Takezawa and colleagues (2019) [3] report that the buccal nerve forms a plexus with infraorbital and mental nerves to collectively innervate the skin at the corner of the mouth and lateral lips (Fig. 4.9).



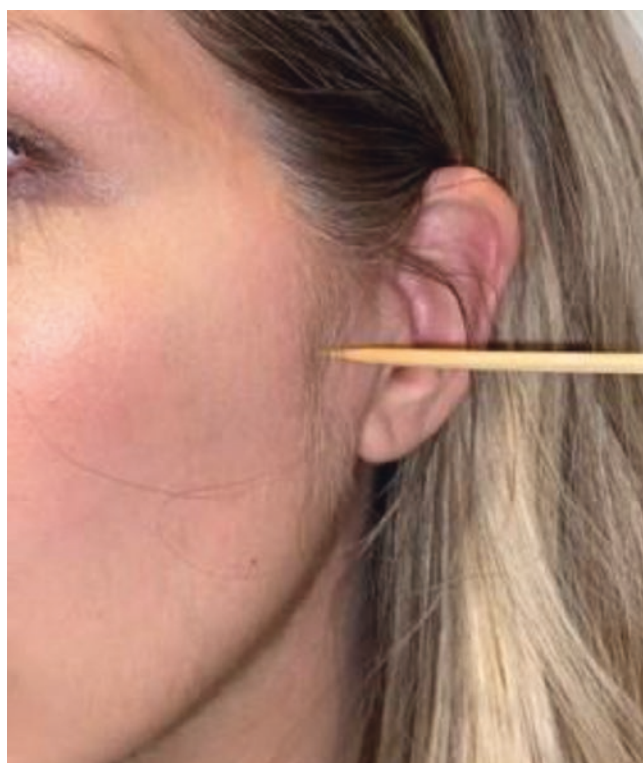**Fig. 4.9** Auriculotemporal and buccal nerves. The mandibular nerve exits the through the foramen ovale to enter the infratemporal fossa. The auriculotemporal nerve (ATN) passes laterally between the neck of the mandible (M) and external acoustic meatus (EAM) to ascend with the superficial temporal vessels. It innervates the skin anterior to the ear, temporal region of the scalp, tragus, and anterior helix of the external ear. The buccal nerve (BN) exits the infratemporal nerve anterior to the masseter on the surface of buccinator to innervate the skin of the cheek. MA maxillary artery, MP medial pterygoid muscle, LN lingual nerve, IAN inferior alveolar nerve, IAA inferior alveolar artery, MMA middle meningeal artery

## Technique

### Mandibular Nerve Block

There are several established methods of extra-oral delivery of local anesthesia to branches of the mandibular nerve such as the inferior alveolar nerve, lingual nerve, or mental nerve but these techniques primarily anesthetize individual branches or a combination of branches only once they have separated from the entire mandibular nerve. As such, only a traditional landmarked approach of the mandibular nerve itself block will be reviewed:

1. Position the patient supine or semi-supine.
2. Have the patient open their mouth slightly (incisal edge of maxillary to incisal edge of mandibular incisors ~1 cm).
3. The clinician is aiming to pass the need tip through an imaginary half-ovoid shape bound superiorly by the zygomatic arch, inferiorly by the mandibular notch (superior border of the ramus), anteriorly by the coronoid process, and posteriorly by the condylar process. These borders should be palpated to appreciate their location. The tragus can act as a surrogate approximation of the condylar head.
4. In order to reduce risk of arterial puncture, needle puncture the skin as superiorly as the zygomatic arch will permit. The point of puncture should be centered on the mandibular notch (Fig. 4.10).
5. Following perpendicular skin puncture with a 22- or 25-gauge needle, the needle is advanced medially without



**Fig. 4.10** Entry point for a mandibular nerve block and an infrazygomatic approach for a maxillary nerve block

superior angulation approximately 2–4 cm depth until it contacts the lateral pterygoid plate.

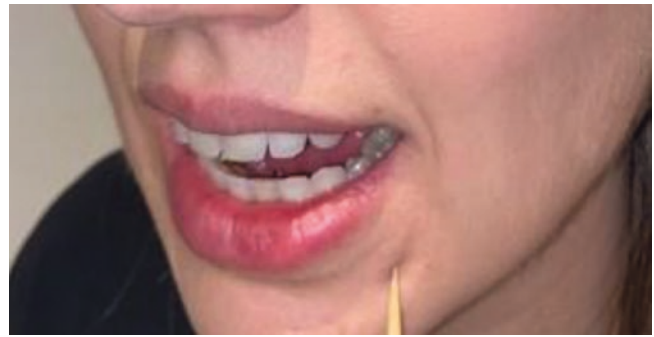6. Once the lateral pterygoid plate is contacted, withdraw the needle slightly and angle the needle posteriorly toward the ear (not more than 6 cm). A slight inferior angulation may be necessary proportional to how superior the skin puncture occurred relative to the zygoma.
7. Once a paresthesia is elicited or there is an elevation twitch from the mandible, an aspiration maneuver can occur to ensure that the tip of the needle is not in a vascular structure.
8. Following a negative aspiration, slowly deposit up to 5 mL of local anesthesia.
9. A successful block will have the patient experience numbness/tingling of the ipsilateral lower lip and anterior two-thirds of the tongue.

### Mental Nerve Block

1. Position the patient supine or semi-supine.
2. Have the patient open his/her mouth so that the patient's premolar teeth, if present, are appreciated. These teeth generally do not have as notable a cusp tip as the patient's canine/eye tooth, nor are they as wide anteroposteriorly as the patient's molar teeth. The mental foramen is generally inferior to these premolar teeth.



3. With your thumb, palpate the inferior border of the mandible starting posteriorly toward the angle of the mandible and working your way anteriomedially toward the patient's chin. As you approach the chin and detect a small bony convexity, you have reached the mental tubercle. The mental foramen is posterolateral to this landmark.
4. Should you wish, extraorally palpate the anterior portion of the ramus and move your digit inferiorly to follow the linear bony protuberance called the oblique line which runs along the body of the mandible. The mental foramen is anterior to this landmark.
5. With your index finger, palpate extraorally along the body of the mandible such that you are directly inferior to the premolar teeth, posterolateral to the mental tubercle, anterior to the oblique line, and approximately midline to the patient's pupil. You may feel a small convexity and some bone irregularity – these are consistent with the texture of the mental foramen. This may feel slightly uncomfortable for the patient as the mental nerve is compressed.
6. Once the mental foramen is located, either maintain a finger or mark the skin on its position.
7. Given that the mental foramen is angulated anteroinferiorly, the barrel and needle of the anesthetic syringe should be anterolateral to the mental foramen in order to advance the needle in a perpendicular direction to the foramen; this is to prevent over-insertion of the needle into the foramen.
8. With a 25- or 27-gauge needle, puncture the skin and advance the needle until the needle touches the bone. The bevel should be facing the mental foramen and the needle tip should be touching the body of the mandible immediately adjacent to the mental foramen (Fig. 4.11).
9. Perform an aspiration maneuver to ensure that the tip of the needle is not intravascular.
10. Following a negative aspiration maneuver, deposit 0.5–1 mL of local anesthetic into the foramen over a minimum of 30 s while concurrently applying digital pressure on the foramen. This pressure should be maintained for a minimum of 1 min and both prevents hematoma formation and may aid in the propagation of local anesthetic further into the foramen.
11. Wait for a minimum of 3 min before observing whether the patient is experiencing subjective signs of anesthesia (tingling/numbness of the anterior portion of the ipsilateral lip).



**Fig. 4.11** Entry point for mental nerve block

### Field Block for the Ear

The ear receives cutaneous innervation from multiple sources with the primary supply coming from the great auricular and auriculotemporal nerves. The *great auricular nerve* originates from anterior rami of spinal nerves C2,3. As it ascends toward the ear it crosses the sternocleidomastoid muscle and angle of the mandible toward the inferior ear. The great auricular nerve innervates the skin over the angle of the mandible, the medial surface (“back”) of the ear, and the lobule, helix, and antihelix of the lateral surface (“front”) of the ear. The *auriculotemporal nerve* is a branch of V<sub>3</sub> that supplies the skin of the tragus and concha at the anterior ear.

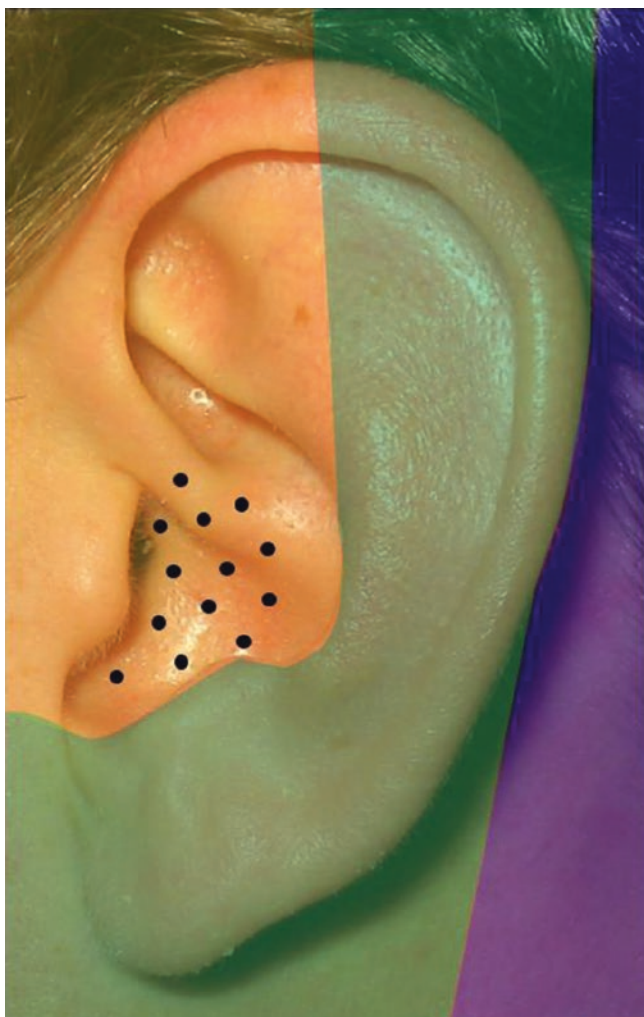The skin of the concha and external acoustic meatus is innervated by the auricular branch of vagus (cranial nerve X) with contributions from the facial nerve (cranial nerve VII) (Fig. 4.12).

The concept of field block is to provide circumferential doses of local anesthetic with the intent of blocking multiple nerves at once [4]. As such, a larger area around the structure in question, in this case the ear, will need to be prepared with an alcohol or prep pad. The local anesthetic should be deposited subcutaneously in a diamond pattern around the ear (Fig. 4.13), making sure to aspirate with each injection. Care should be taken to ensure that the injections anterior to the ear, in the pretragal area, should be subdermal to avoid injury to the facial nerve [5].

### Field Block for the Nose

Most of the skin of the external nose is innervated by branches of V<sub>1</sub>. *External nasal nerve* supplies the dorsum of the nose to the apex while the *infratrochlear nerve* supplies

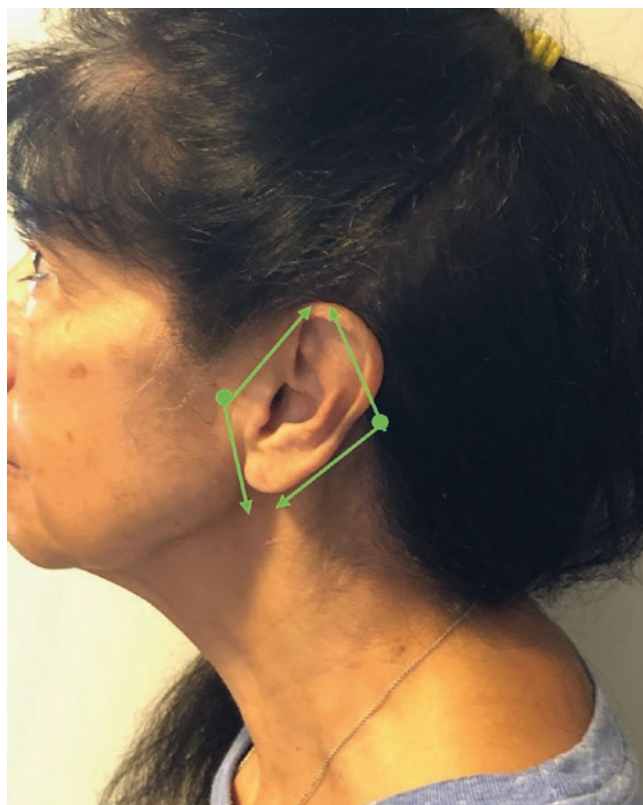



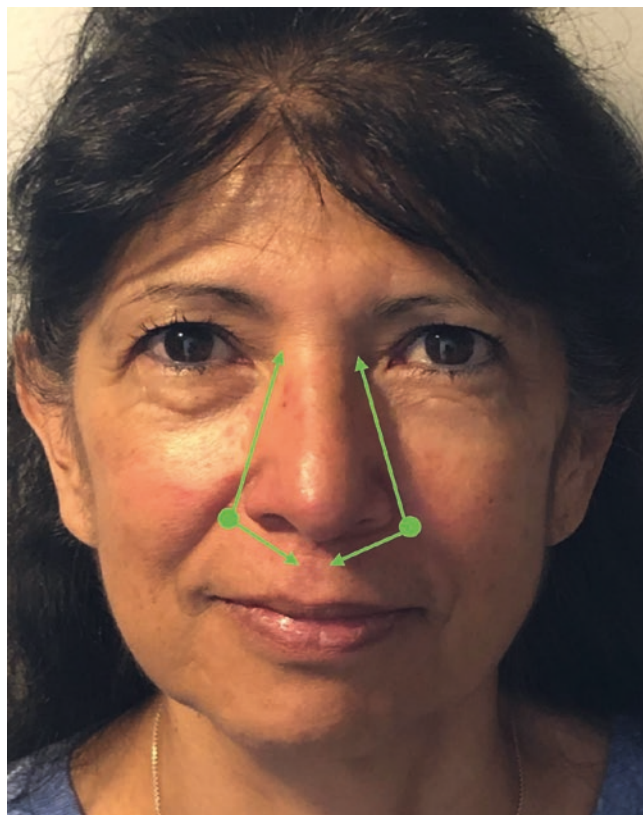**Fig. 4.12** Innervation to the skin of the external ear. The auriculotemporal nerve innervates the tragus and the anterior aspect of the concha and helix (yellow). The great auricular nerve innervates skin of the medial surface of the ear, the lobule, and posterior aspect of the helix (green). The lesser occipital nerve supplies the skin behind the ear (blue) and the auricular branch of vagus and facial nerve contribute to sensation to the skin of the concha (black dots)

the root. The skin of the lateral nose and nares are innervated by nasal branches of the *infraorbital nerve*, a branch of  $V_2$  (Fig. 4.1).

Prepare the field with an alcohol prep pad in the area around the nose. In order to perform a nasal field block, begin by injecting the area of the nasiolabial fold lateral to the ala on one side, noted by the dot on Fig. 4.14. Continue injecting, aspirating before each injection, superiorly to the bridge of the nose and inferiorly from the initial point to the philtrum and terminate just before the midline. Repeat the same process on the contralateral side. The outline form is triangular (Fig. 4.14). The tip of the nose will usually require a separate direct injection and anesthetic without vasoconstrictor must be used for this area [4].



**Fig. 4.13** Field block for the ear



**Fig. 4.14** Field block for the nose

## Summary

Knowledge of regional anatomy allows the healthcare practitioner to provide local anesthesia in a safe and effective manner. Many of these techniques can be performed transfacially as described above or via intra-oral techniques described elsewhere in this section. To reduce the chance of infection, the skin should be prepped prior to any injection.

---

## References

1. Ashwini L, Mohandas Rao K, Saran S, Somayaji S. Morphological and morphometric analysis of supraorbital foramen and supraorbital notch: a study on dry human skulls. *Oman Med J*. 2012;27(2):129–33. <https://doi.org/10.5001/omj.2012.27>.
2. Silverman S. Periorbital nerve blocks (supraorbital, supratrochlear, and infraorbital nerves). In: Diwan S, Staats PS, editors. *Atlas of pain medicine procedures*. New York: McGraw-Hill; 2015.
3. Takezawa K, Ghabriel M, Townsend G. The course and distribution of the buccal nerve: clinical relevance in dentistry. *Aust Dent J*. 2018;61(1):66–71.
4. Tsai T, Gadsden J, Connery C. Chapter 12. Local infiltration anesthesia. In: Hadzic A, editor. *NYSORA textbook of regional anesthesia and acute pain management*. New York: McGraw-Hill; 2007.
5. Zuber T, Mayeaux E. *Atlas of primary care procedures*. 2nd ed. Philadelphia: Lippincott Williams & Wilkins; 2004. p. 167–9.

# Cervical (Neck) Local Anesthesia Techniques

# 5

Hannah Herriott, Kyle Robertson, and Benjamin Noblitt

## Introduction

Many cosmetic procedures are performed in the office setting with or without a light sedation. These procedures cannot be performed without local anesthesia, thus making local anesthesia critical to the clinician. Fortunately, local anesthesia of the neck can be a very straightforward process. The majority of cosmetic procedures involving the neck revolve around the skin and its associated superficial structures. This makes anesthetizing it rather easy if the practitioner has a basic understanding of the anatomy and a familiarity with local anesthesia techniques.

## Armamentarium

- Sterile towels
- 4-in. × 4-in. gauze pads
- 20-mL syringe
- Sterile gloves
- Marking pen
- 1.5 or 2 inch (5 cm) 25 gauge hypodermic needle
- Local anesthetic of choice (to be discussed later in this chapter)

H. Herriott · K. Robertson  
Department of Anatomy, Cell Biology, & Physiology, Indiana University School of Medicine, Indianapolis, IN, USA  
e-mail: [Kyanrobe@iupui.edu](mailto:Kyanrobe@iupui.edu)

B. Noblitt (✉)  
Private Practice, MSL Facial and Oral Surgery,  
Marysville, WA, USA

## Superficial Cervical (C2, C3) Block

### Anatomy of the Cervical Plexus and Dermatome Distribution

The cervical plexus is comprised of the anterior primary rami of cervical spinal nerves C1–C4. After exiting the intervertebral foramina, the anterior primary rami (C2–4) pass posterior to the vertebral artery and vein within the gutter formed by the anterior and posterior tubercles of the corresponding transverse processes. The first cervical spinal nerve (C1) passes inferior to the vertebral artery as it emerges between the occipital bone and C1 vertebra (atlas). As the C2–4 anterior primary rami continue their course, they emerge between prevertebral muscles. The prevertebral muscles which are located anterior to the nerves to which attach to the anterior tubercle are the longus colli, longus capitis, anterior scalene, rectus capitis anterior, and rectus capitis lateralis. The prevertebral muscles which are located posterior and attach to the posterior tubercle are the levator scapulae, longissimus cervicis, and middle scalene. The prevertebral fascia investing the muscles and tendons creates a perineural sheath around the plexus, which facilitates the anatomic relationship for nerve block to this area. This prevertebral fascia is the structure which the superficial branches pierce to provide sensory innervation to the respective dermatomes.

The anterior rami from spinal levels C2–4 divide into ascending and descending branches, which then unite with an adjacent spinal nerve to form loops of the cervical plexus. The C1 spinal nerve does not usually exhibit ascending and descending branching. These loops give rise to both anterior and deep branches. The superficial branches of the loops are cutaneous (sensory) branches to their respective dermatome. The deep branches are motor branches which include the nerve roots of the phrenic nerve and the ansacervicalis, which supplies the infrahyoid muscles. This anatomic division of the superficial and deep branches is what allows for



selective blocking of the superficial cutaneous branches without blockade of the deep motor branches.

The superficial (cutaneous) branches of the cervical plexus course posterior of the internal jugular vein and deep to the sternocleidomastoid (SCM) muscle before piercing the deep fascia and emerging at the posterior edge, approximately one-third the length down the sternocleidomastoid muscle, at the midpoint between the mastoid process and clavicle. This area termed the sensory nerve point of the neck (Erb's point) is approximately at the level of the transverse process of the C5 vertebra. The superficial branches include the lesser occipital (C2), great auricular nerves (C2–3), transverse cervical nerves (C2–3), and the supraclavicular nerves (C3–4) (Fig. 5.1).

The lesser occipital nerve courses superiorly from the nerve point of the neck along the posterior border of sternocleidomastoid in a direction toward the external occipital protuberance, supplying the skin of the neck and scalp posterior and superior of the auricle. The great auricular nerve, the largest of the ascending branches, courses vertically at an oblique angle across the sternocleidomastoid muscle toward

the inferior aspect of the parotid gland deep to the platysma muscle, where it innervates the skin over the parotid, mastoid process and posterior auricle. The transverse cervical nerve curves around the sternocleidomastoid muscle passing anteriorly and horizontal as well as deep to both the external jugular vein and the platysma muscle supplying the anterior cervical region. There has been documentation of anastomosis between the branches or the transverse cervical nerve and branches of the facial nerve, specifically the cervical and marginal mandibular branches of the facial nerve. The supraclavicular nerves emerge from the nerve point of the neck as a common trunk and descend deep to the platysma in an inferior lateral direction toward the clavicle. Often it will branch into three major branches supplying skin overlying the shoulder, clavicle, and the superior aspect of the chest (Fig. 5.1).

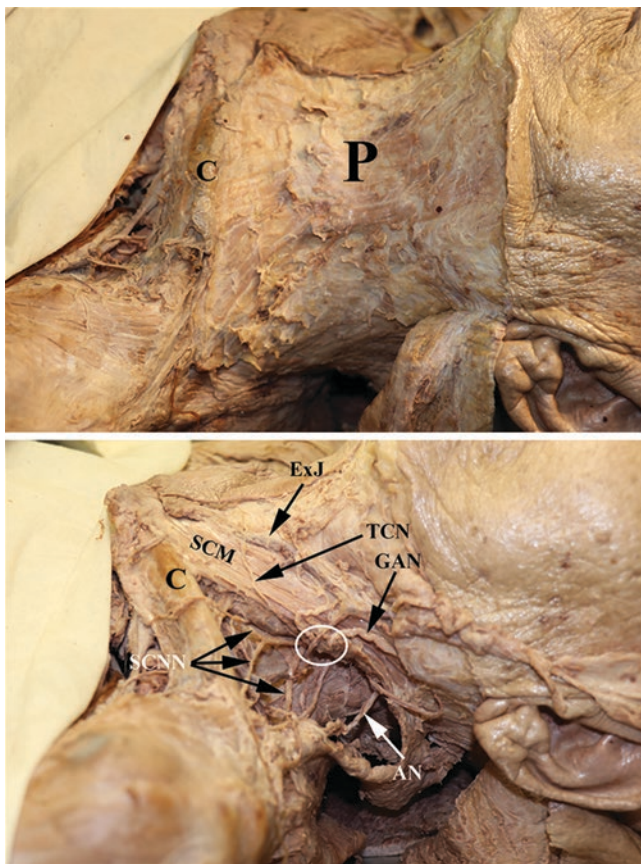
The motor branches of the cervical plexus are located deep to the prevertebral fascia, in contrast to the cutaneous branches, which pierce this fascia and are thus superficial. As spinal nerve C1 is motor only, it courses with the hypoglossal nerve through the lateral cervical region to innervate both the geniohyoid and thyrohyoid muscles and continues as the superior root of the ansacervicalis. The inferior root of the ansacervicalis is formed by contributions of C2–3, thus forming a loop, which lies either embedded within or just on the anterior surface of the carotid sheath. The remaining infrahyoid muscles, the omohyoid, sternohyoid, and sternothyroid, are innervated by the ansacervicalis. Additionally, the deep motor branches also supply innervation to the aforementioned muscles attaching to the anterior and posterior tubercles of the cervical vertebra transverse processes (Fig. 5.2).

The spinal accessory nerve (CN XI), although not a part of the cervical plexus, is a motor nerve that innervates both the SCM and the trapezius and must be mentioned due to its relationship with the cervical plexus. Its course through the lateral cervical region is in a posterior-inferior direction deep to the SCM and often emerging just superior of the nerve point of the neck. The spinal accessory nerve is often located within or deep to the investing layer of the deep cervical fascia (Fig. 5.3).

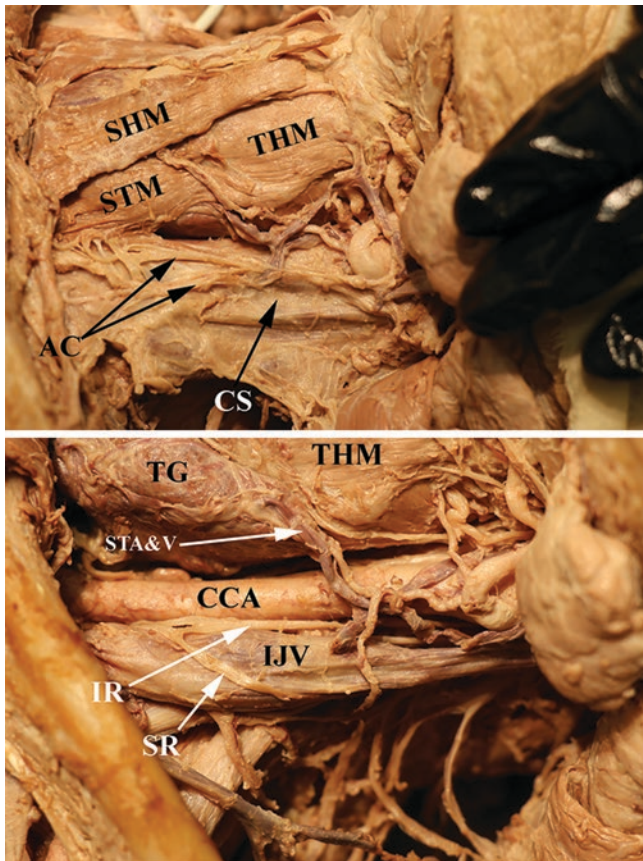
### Technique for Superficial Cervical Block

The superficial cervical nerve block is a widely used technique for anesthetizing the superficial neck and associated structures. It is commonly used for superficial biopsies, scar revisions, etc. As implied by the name, the superficial approach only anesthetizes the superficial structures of the neck. A deep approach to the cervical plexus is not often needed for superficial cosmetic procedures and thus is not covered in this chapter [1, 2].

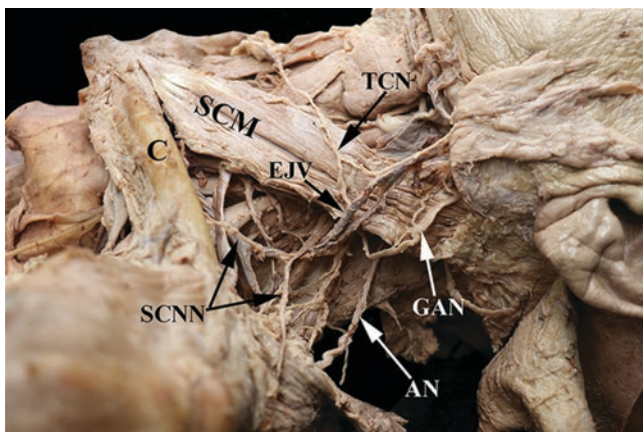
Historically, there are two general approaches, the deep and the lateral. The lateral approach is safe, effective, and



**Fig. 5.1** Sensory nerves of the neck. Anterior is toward the top of both images and the oval indicates the sensory nerve point of the neck (Erb's point). P platysma, C clavicle, SCM sternocleidomastoid muscle, ExJ external jugular vein, TCN transverse cervical nerve, GAN great auricular nerve, SCNN supraclavicular nerves, and AN accessory nerve



**Fig. 5.2** Anatomy of the ansacervicalis. View is from the left side, anterior is toward the top of both images. SHM sternohyoid muscle, STM sternothyroid muscle, THM thyrohyoid muscle, AC ansacervicalis, CS carotid sheath, TG thyroid gland, STA&V superior thyroid artery and vein, CCA common carotid artery, IR inferior root of ansacervicalis, SR superior root of ansacervicalis, and IJV internal jugular vein



**Fig. 5.3** Relationship of the spinal accessory nerve (CN XI) to the sensory nerves of the neck. SCM sternocleidomastoid muscle, C clavicle, TCN transverse cervical nerve, EJV external jugular vein, SCNN supraclavicular nerves, GAN great auricular nerve, and AN spinal accessory nerve (CN XI)

well tolerated and thus will be the approach discussed here. The superficial cervical block can also be performed with ultrasound or based on anatomical landmarks. Data have shown that both the ultrasound and the landmark approaches are equally effective with no delay in surgical or anesthesia time. Consequently, this chapter will focus on the landmark-based approach [3–6].

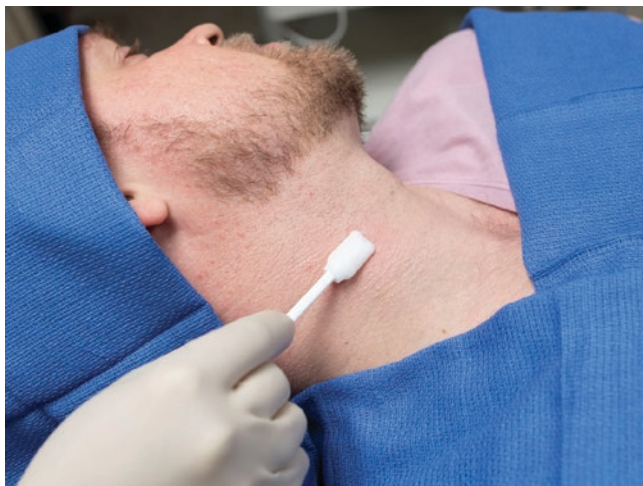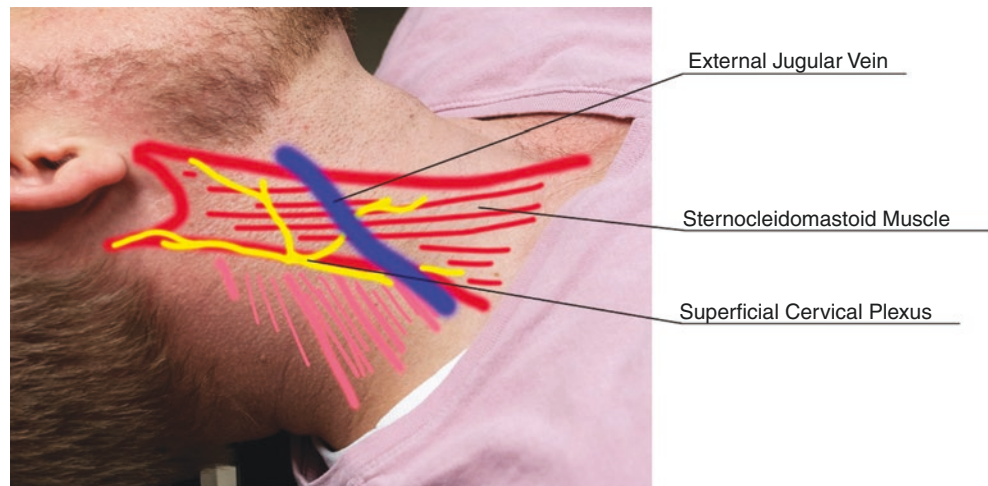
1. Lay the patient supine and turn their head away from the side being blocked (Fig. 5.4).
2. Prep the skin with any skin prep of your choice – e.g., alcohol pad and chlorhexidine. Be sure to prep in the center and work your way out using the standard sterilization technique. After preparation, drape the patient (Fig. 5.5).
3. Palpate and mark the mastoid process. The process is wide and bony hard. It is sometimes easier to palpate when the patient is slightly lifting their head. This will allow you to follow the path of the SCM to its insertion to the mastoid process (Fig. 5.6).
4. Palpate and mark Chassaignac's tubercle. Chassaignac's tubercle is the prominent transverse process of the sixth cervical vertebra (C6). This is found by palpating lateral and posterior to the clavicular head of the sternocleidomastoid muscle at the level just below the cricoid cartilage (Fig. 5.7).

Mark the midpoint between these landmarks. This is where the four nerves (lesser occipital, greater auricular nerve, transverse cervical nerve, and the supraclavicular nerves) emerge from behind the sternocleidomastoid muscle and thus will be the injection site (Fig. 5.8).

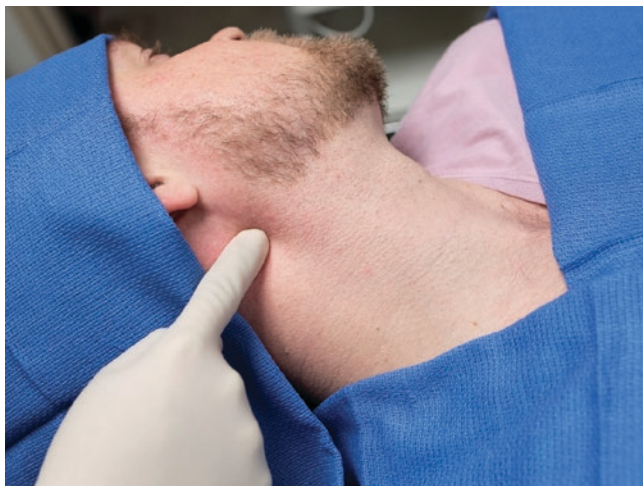5. Note the area of the jugular vein and try to avoid it. Inject 4–5 mL at a depth of half the width of the sternocleidomastoid muscle or approximately 2 cm. Next, withdraw the needle and then inject another 3–5 mL in a subcutaneous plane at a depth of about 3–4 cm aiming caudad along the posterior border of the muscle. Follow this by injecting another 3–5 mL in a subcutaneous plane at a depth of about 3–4 cm aiming cephalad along the posterior border of the muscle. These injections form a fan pattern to ensure that all four main nerves are adequately anesthetized. As always, aspirate prior to injecting (Figs. 5.9, 5.10, and 5.11).
6. Place Pressure over the injection site for hemostasis and dress as needed.
7. Monitor the patient for appropriate block and if the patient does not exhibit anesthesia, consider repeating the procedure as needed.



**Fig. 5.4** The anatomical landmarks: The sternocleidomastoid muscle (SCM), external jugular vein (EJ), and the superficial cervical plexus



**Fig. 5.5** Sterile preparation of the skin. Note that site preparation should be performed prior to draping the patient. The drapes were placed here in order illustrate this aspect of the procedure



**Fig. 5.6** The mastoid process being palpated

#### Tips:

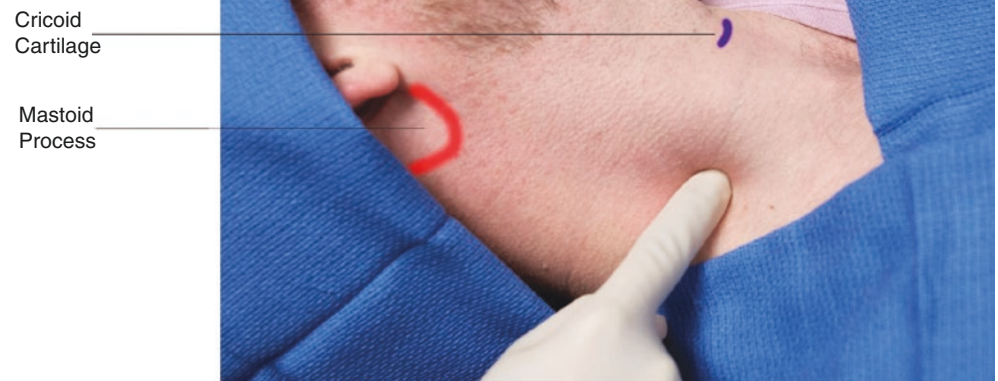- Always consider this a sterile process. When prepping the skin, be sure to prep wider than you think you will need to be. Also consider using sterile blue towels to drape the area to allow you to rest your hands in the field for more stable and controlled injections.
- Laying the patient flat helps with identifying the jugular vein as well as allowing for more controlled injection. When aiming caudad, be sure to aspirate while advancing the needle as not to inject the external jugular vein.
- Remember, this is aimed at blocking sensation, not motor function so the patient will still be able to raise their head [2, 3, 7].

## Mental Nerve Block

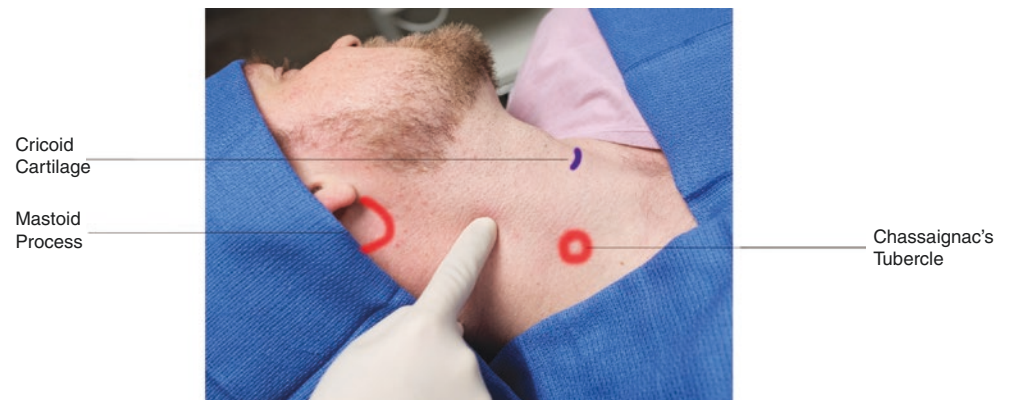
### Anatomy of the Trigeminal Nerve (CN V)

The largest and most complex of the cranial nerves, the trigeminal nerve (CN V), contains sensory and efferent motor fibers as well as aiding in the distribution of the autonomic nervous system, specifically the parasympathetic division to head and neck structures. Somatic afferent fibers relay information of pain, temperature, and light touch from the skin of the face, mucosal linings of the nose and mouth, teeth, and the anterior two-thirds of the tongue. The visceral motor fibers innervate derivatives of the first pharyngeal arch structures as well as carry proprioceptive impulses to aid in the process of mastication. As parasympathetic fibers arise from the oculomotor (CN III), facial (CN VII), and glossopharyngeal (CN IX) nerves, the respective fibers will travel with

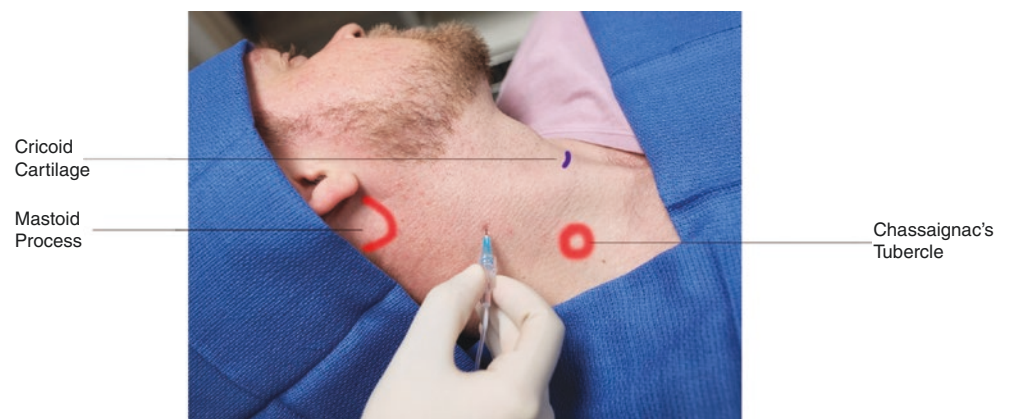
**Fig. 5.7** The location of the mastoid process and cricoid cartilage are shown to help in locating Chassaignac's tubercle (transverse process of C6)



**Fig. 5.8** Location of the injection point based on the anatomical landmarks of the neck

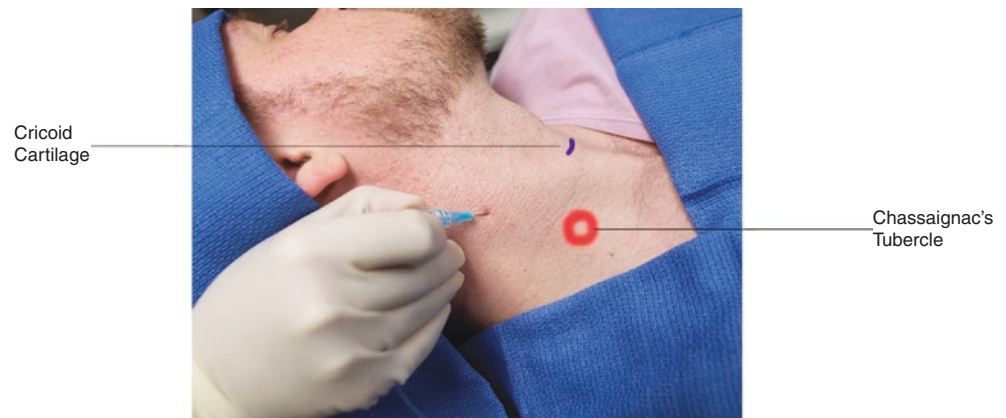

**Fig. 5.9** Injection into the main stem of the superficial cervical plexus

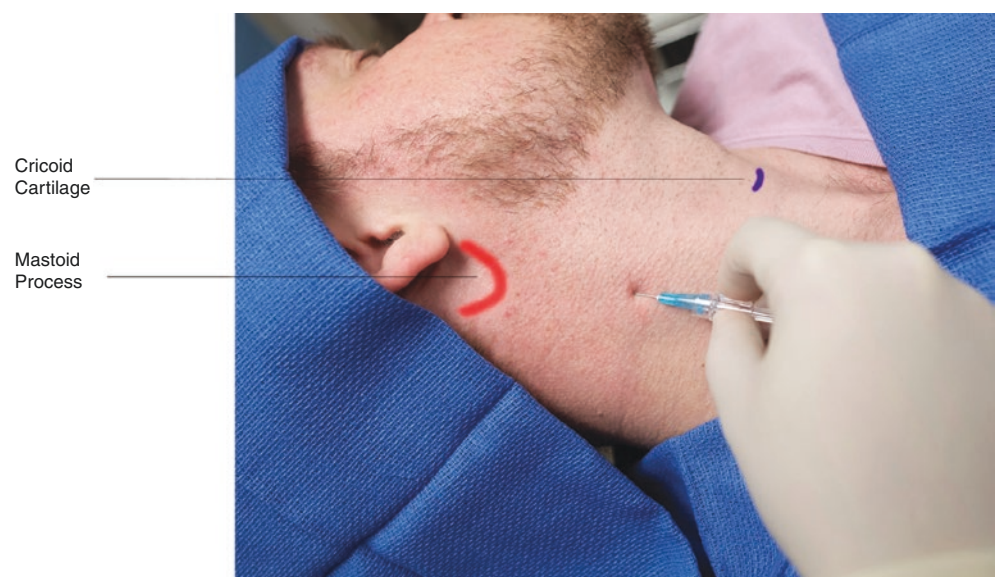




**Fig. 5.10** Injection into the subcutaneous tissues while aiming for the caudad



**Fig. 5.11** Injection into the subcutaneous tissues while aiming for the cephalad



nerves of the trigeminal nerve to synapse with the otic, submandibular, sphenopalatine, ciliary, pterygopalatine ganglion.

As the roots arise from the brainstem at the mid-pontine level, they travel along the petrous portion of the temporal bone to form the trigeminal sensory ganglion (Gasserian). The trigeminal sensory ganglia comprise of pseudounipolar neurons with the central processes constituting the sensory and the peripheral processes forming the three divisions of the trigeminal nerve: ophthalmic (CN V<sub>1</sub>), maxillary (CN V<sub>2</sub>), and mandibular (CN V<sub>3</sub>). The trigeminal ganglion resides in a recess often referred to as Meckel's cave, within the middle cranial fossa at the posterior aspect of the cavernous sinus. The motor root travels past the trigeminal ganglion, and then will merge with the mandibular division (CN V<sub>3</sub>), the only division to contain motor fibers.

In the following, the sensory innervation for each of the three divisions of the trigeminal nerve will be discussed in

turn with a more complete description of the terminal branches, the mandibular division (CN V<sub>3</sub>). The ophthalmic division (CN V<sub>1</sub>), which exits the skull through the superior orbital fissure, is purely sensory in function, with the terminal branches supplying innervation of mucosa of the frontal sinus, skin, and conjunctiva of the middle of superior eyelid, skin, and pericranium of the anterolateral forehead and scalp to the interauricular line, skin of nasal ala, vestibule, and dorsum of the nose. The maxillary division (CN V<sub>2</sub>) exits the skull through foramen rotundum in the base of the greater wing of the sphenoid, where it enters the pterygopalatine fossa, providing branches to the pterygopalatine ganglion. The course continues anteriorly through the inferior orbital fissure where the purely sensory terminal branches provide innervation to their respective areas. Regions innervated by the maxillary division (CN V<sub>2</sub>) are the mucosa of the maxillary sinus, skin, and conjunctiva of the inferior eyelid, maxillary canine and premolar teeth,

skin, and oral mucosa of the superior lip and the skin on the prominence of the cheek.

As the largest and most inferior division of the trigeminal nerve, the mandibular division (CN V<sub>3</sub>) contains both sensory and motor functions. It exits the skull via the foramen ovale at the greater wing of the sphenoid bone. Once exiting the skull, the combined motor and sensory trunk give off a small nerve the nervus spinosus, which travels with the middle meningeal artery through the foramen spinosum to provide sensory innervation to portions of the anterior and middle cranial fossa. The mandibular nerve will then divide into anterior and posterior trunks.

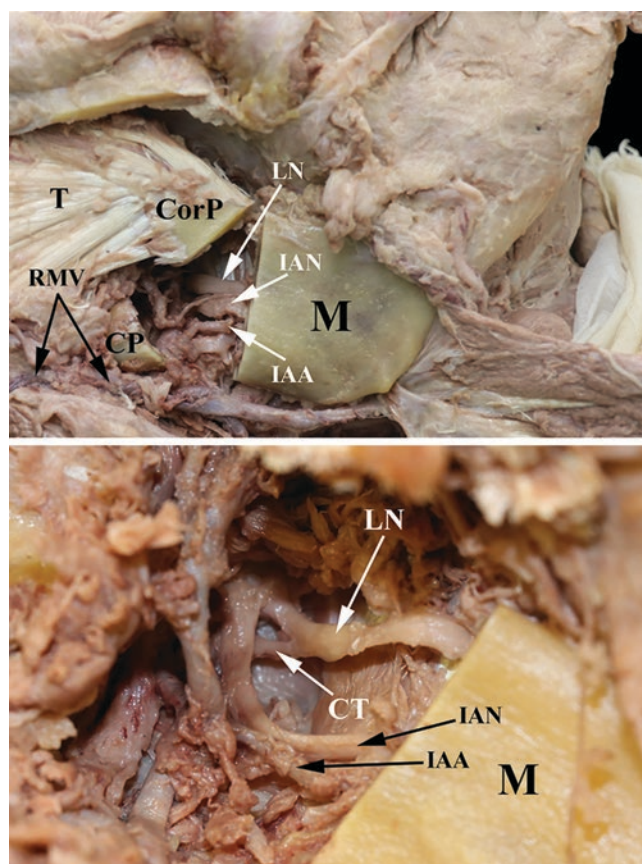
The anterior trunk is smaller and gives rise to muscular branches providing motor innervation to the masseter, temporalis, and lateral pterygoid muscles, all of which are muscles of mastication. Also, from the anterior trunk arises the pure sensory nerve; the buccal nerve (long buccal nerve) is not to be confused with the buccal branch of the facial nerve, which provides motor innervation to the buccinator muscle. As the buccal nerve arises in the infratemporal fossa, its course will take it between the two heads of the lateral pterygoid and it emerges anteriorly from the protection of the ramus of the mandible. The buccal nerve innervates the skin and mucosa overlying the anterior portion of the buccinator muscle.

Larger than the anterior trunk, the posterior trunk of the mandibular division is predominantly sensory with few motor fibers and gives rise to the auriculotemporal, lingual, and the inferior alveolar nerves. The inferior alveolar nerve continues as the mental nerve and the incisive nerve. The auriculotemporal nerve is comprised of two roots from the posterior trunk, which often encircle the middle meningeal artery prior to the artery entering the skull via the foramen spinosum. As the nerve passes laterally, it will pass deep to the neck of the mandible and between the temporomandibular joint and the external acoustic meatus. At the superior lobe of the parotid gland, it supplies the connective tissue sheath surrounding the parotid gland. Also, the parasympathetic fibers arising from the glossopharyngeal nerve via the lesser petrosal nerve innervate the parotid gland travel with the auriculotemporal nerve to arrive at the parotid gland. Areas innervated by the auriculotemporal nerve are the skin anterior to the auricle, posterior two-thirds of temporal region, skin of tragus and adjacent helix of auricle, skin at the roof of the external acoustic meatus, and skin of the superior tympanic membrane.

The lingual nerve is located anterior to the inferior alveolar nerve, and its course to the mouth is between the medial pterygoid muscle and the ramus of the mandible. As it passes anteriorly under the cover of the oral mucosa, it is medial and inferior to the third molar. Also, as the lingual nerve courses anterior, it will pass deep to the submandibular duct. The chorda tympani nerve, arising from the facial nerve (CN

VII), joins the lingual nerve in the infratemporal fossa, which conveys parasympathetic innervation to the submandibular and sublingual glands as well as carrying taste fibers from the anterior two-thirds of the tongue. Areas to which the lingual nerve provides sensory information are the anterior two-thirds of the tongue, floor of the mouth, and the lingual gingiva (Fig. 5.12).

Lastly, the inferior alveolar nerve enters the mandibular foramen and courses through the mandibular canal. Prior to the inferior alveolar nerve entering the mandibular foramen, the nerve to the mylohyoid muscle branches off and runs in the mylohyoid groove on the medial aspect of the mandibular ramus, en route to provide motor innervation to the mylohyoid muscle and the anterior belly of the digastric. As the inferior alveolar nerve passes through the mandibular canal, it sends branches to all mandibular teeth on the nerves on respective side. Often, as the inferior alveolar nerve approaches the mental foramen, it will form a loop anterior to the mental foramen prior to exiting this foramen, termed the anterior loop. The anterior loop is important to recognize



**Fig. 5.12** Pathway of the mandibular division of the trigeminal nerve (CN V<sub>3</sub>) through the infratemporal fossa. View is from the right side; the middle portion of the ramus of the mandible (M) has been removed. CorP coronoid process, T temporalis muscle, CP condylar process, RMV retromandibular vein, LN lingual nerve, IAN inferior alveolar nerve, IAA inferior alveolar a., and CT chorda tympani



when performing endosseous implants as to not damage this structure. The location of the mental foramen is variable by race, sex, dental status along with other factors, but most often it is located in the mid-pupillary line, apical to the second premolar. The nerve exiting the mental foramen is the mental nerve which provides sensory of the skin and mucous membrane of the lower lip, skin of the chin, and the vestibular gingiva if the mandibular incisive teeth. After the mental nerve exits, the continuation of the inferior alveolar nerve is the incisive nerve, coursing in the incisive canal. The incisive nerve innervated the teeth anterior to the mental foramen, usually the premolars and central incisors (Fig. 5.13).

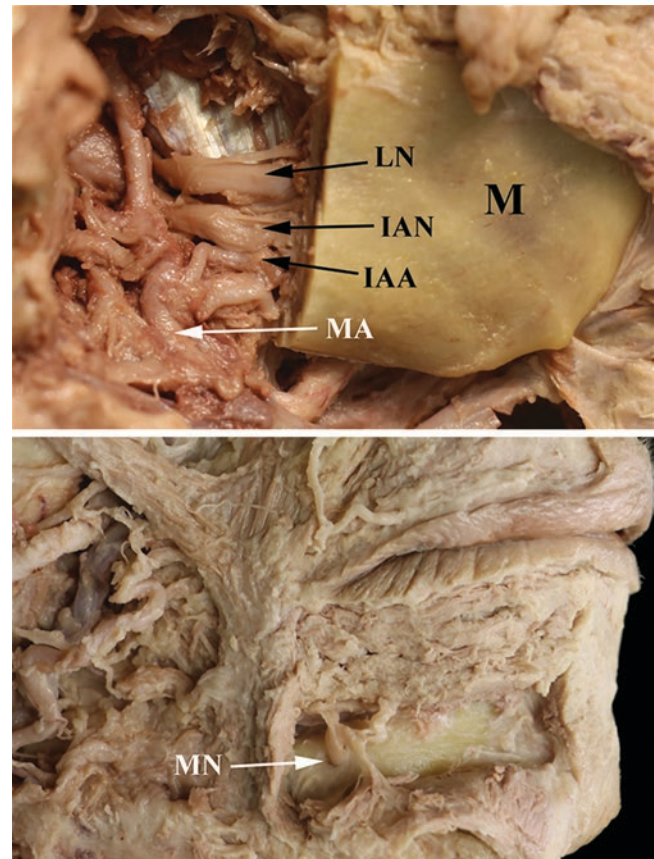
### Technique for the Mental Nerve Block

The mental nerve block is one of the most common blocks performed on the face. The combined simplicity and efficacy of this block make it readily used. There are two general approaches to the mental nerve block, the transoral and the transcutaneous approaches. Both will be covered in this chapter.

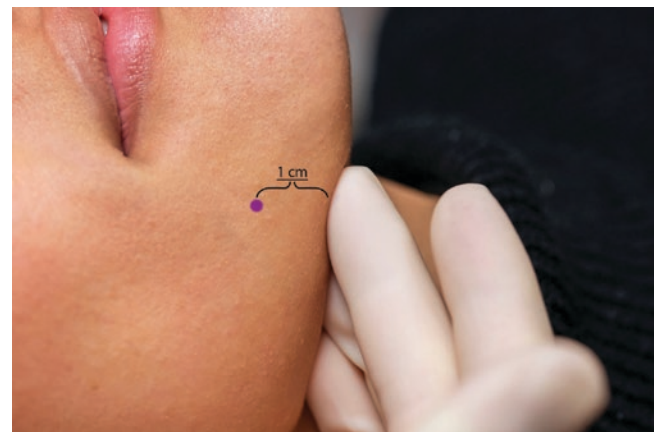The mental foramen is the target of the mental nerve block. As mentioned above, there is usually only one foramen found just apical to the second premolar, about halfway between the alveolar crest and the inferior border of the mandible in dentate patients. If the patient is edentulous, it can be found about 1 cm from the inferior border of the mandible. This is the target of both the transoral and the transcutaneous approaches [8].

### Transcutaneous Approach

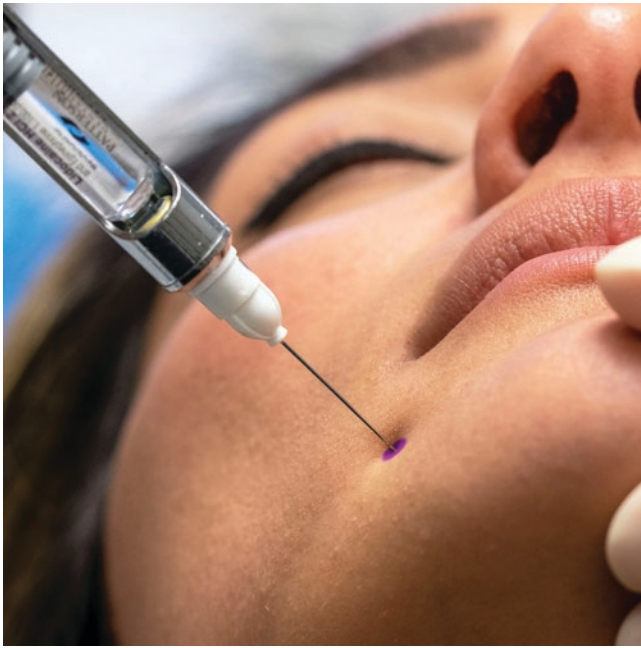1. Position the patient in a comfortable and ergonomic manner.
2. Prep the skin with any skin prep of your choice – e.g., alcohol pad and chlorhexidine as noted in the superficial cervical block.
3. Mark the skin 1 cm from the inferior border of the mandible in line with the mid-pupillary line. To verify the position, you can palpate this area while retracting the buccal tissues with a tongue blade or dental mirror in order to visualize the position of the second premolar (Fig. 5.14).
4. Aim the needle perpendicular to the skin and advance until bone is palpated. If the patient experiences a shock-like sensation, this often means the needle is in close proximity to the mental nerve, so withdraw 1 or 2 mm prior to delivering the anesthetic. The tip of the needle should be between the apices of the premolars. The mental foramen is often apical to the second premolar, but this author would recommend erring toward the mesial or the



**Fig. 5.13** Pathway of the lingual nerve through the infratemporal fossa and termination as the mental nerve. Both images are right side views. In the top image, superior is toward the left; in the bottom image, superior is toward the top. M mandible, LN lingual nerve, IAN inferior alveolar nerve, IAA inferior alveolar artery, MA maxillary artery, and MN mental nerve



**Fig. 5.14** Palpating the inferior border of the mandible and placing a mark 1 cm from the inferior border along the mid-pupillary line



**Fig. 5.15** Injection is perpendicular to the skin. Here, the mark can be seen placed along the mid-pupillary line about 1 cm from the inferior border of the mandible

first premolar when in doubt. Erring on the side of the mesial will allow for a more effective block than erring on the distal due to the path of the nerve fibers being anesthetized. Once positioned, aspirate to verify no entry into a vascular structure and then deliver 1–3 mL of local anesthetic (Fig. 5.15).

5. Place pressure over the injection site for hemostasis and dress as needed. Massaging the area may also help distribute the anesthetic as well. There is debate if this helps the anesthetic work quicker, but many patients tend to appreciate the gesture.
6. Monitor the patient for appropriate block and if the patient does not exhibit anesthesia, consider repeating the procedure as needed.

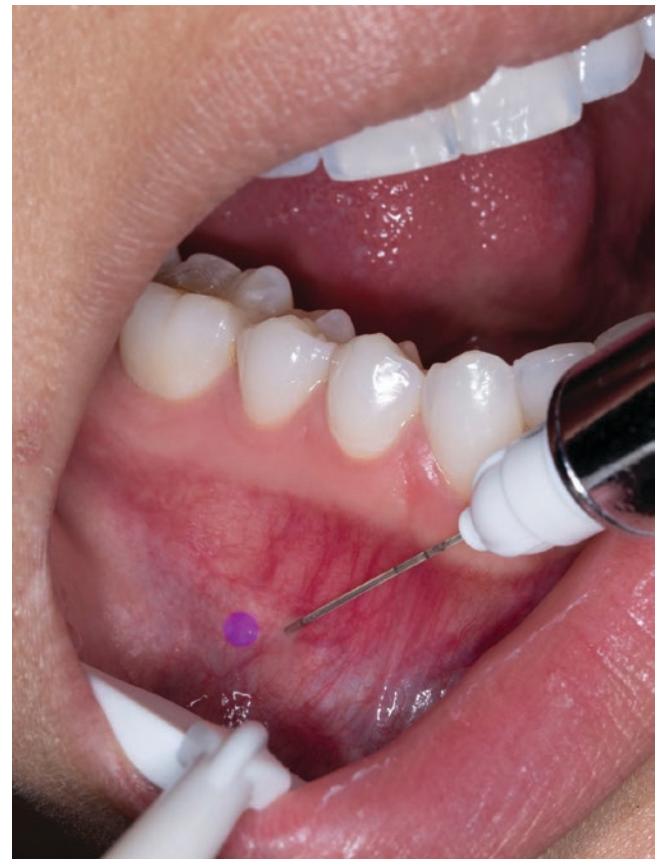#### Tips:

- The most common complication with this injection is often injecting into the oral cavity. Verifying the position of the needle can help prevent this.
- If a shock is felt, withdraw the needle slightly and inject, even if you do not feel the bone. The reason is that it is possible to enter the mental foramen with the needle. This could potentially cause damage to the nerve if the needle is advanced into the foramen [9, 10].

### Transoral Approach

1. Position the patient in a comfortable and ergonomic manner.

2. It is up to the practitioner if they choose to use a topical anesthetic such as benzocaine. The efficacy of this is debatable, but many patients prefer to use it, even if it is for placebo. If it is used, place it in the vestibule lateral to the premolars as directed by the manufacturer.
3. Retract the buccal mucosa and place light tension on the mucosa. The tension helps the needle pass through the tissue easier and will help cause less discomfort to the patient. Often, the branches of the mental nerve can also be visualized through the tissue [9].
4. Aim the needle at the depth of the vestibule, entering the mucosa just lateral to the root of the first premolar and advance ~5 mm. If the patient experiences a shock-like sensation, this often means the needle is in close proximity to the nerve, so withdraw 1 or 2 mm prior to delivering the anesthetic. Due to the angle of injection, the tip of the needle will be near the apex of the second premolar. As mentioned previously, erring on the side of the mesial will allow for a more effective block than erring on the distal. Once positioned, aspirate to verify no entry into a vascular structure and then deliver 1–3 mL of local anesthetic (Fig. 5.16).



**Fig. 5.16** The purple mark approximates the area of the mental foramen. The needle can be seen aiming for this foramen by entering the mucosa lateral to the root of the first premolar

5. As noted previously, massaging the area may also help distribute the anesthetic as well. There is debate if this helps the anesthetic work quicker as well.
6. Monitor the patient for appropriate block and if the patient does not exhibit profound anesthesia, consider repeating the procedure as needed.

#### Tips:

- When injecting, the tissue is soft and generally mobile. Because of this, it is common to see the tissue swell during injection. This is normal and massaging this will often cause the local anesthetic to diffuse into the tissue, decreasing the swelling.
- This is not a sterile injection, and thus does not require the use of any sterile prep [9, 10].

## Chondrolaryngoplasty

Chondrolaryngoplasty, or thyroid cartilage reduction, is one of the procedures that may be offered to transfeminine patients [11]. This procedure is not included elsewhere in this book; so, for the sake of completeness, the anatomy of the region is included here. Thyroid cartilage reduction, and even augmentation, can be performed on an outpatient basis using the local anesthetic techniques described above.

## Anatomy of Larynx

The larynx is innervated primarily by branches off of the vagus nerve (CN X) with both parasympathetic and sympathetic contributions. Four paired nuclei in the medulla oblongata are associated with the vagus nerve. Special and visceral afferent input is received by the solitary nucleus, whereas deep or crude touch sensation, including sensory information from the mucosa of the larynx, is transmitted through the vagus nerve to the spinal trigeminal nucleus. Preganglionic parasympathetic fibers of the vagus nerve arise from the dorsal nucleus of the vagus nerve as well as the nucleus ambiguus. Meanwhile, the postganglionic sympathetic fibers innervating the larynx originate in the sympathetic chain (also commonly referred to as the sympathetic trunk) and join a branch off of the vagus nerve within the neck.

Arising from the medulla oblongata, the vagus nerve ascends toward the jugular foramen between the pyramid and the inferior cerebellar peduncle on each side of the brainstem. Both the vagus nerve and internal jugular vein exit the base of the skull through the jugular foramen, before passing into the carotid sheath within the neck. The carotid sheath descends down the length of the neck anterior to the anterior scalene muscle and just lateral to the

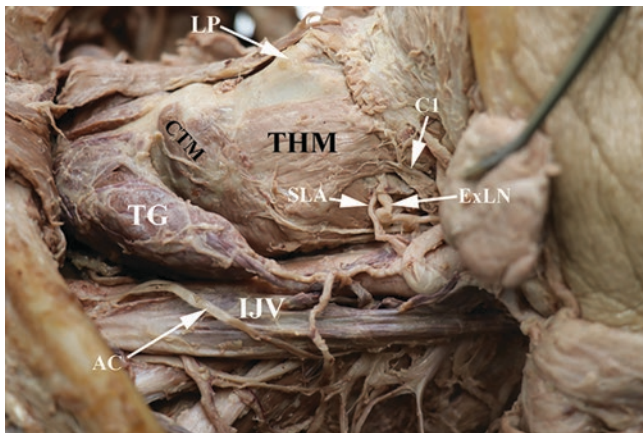
laryngopharynx, which terminates between the levels of C5 and C6 to give rise to the trachea anteriorly and the esophagus posteriorly. Within the carotid sheath, the vagus nerve is located posteromedially to the internal jugular vein and posterolaterally to the internal and later common carotid artery. Afferent sensory and efferent motor innervation to the larynx are provided by two branches off of the vagus nerve, namely the superior laryngeal nerve, which bifurcates into the internal and external laryngeal nerves, as well as the recurrent laryngeal nerve.

The superior laryngeal nerve branches off of the vagus nerve in the middle of the inferior ganglion of the vagus nerve distal to the jugular foramen at the base of the skull. As the superior laryngeal nerve courses inferiorly toward the thyrohyoid membrane, it receives sympathetic fibers from the superior cervical ganglion. Before reaching the posterolateral portion of the thyrohyoid membrane, the superior laryngeal nerve bifurcates into external and internal laryngeal nerves; it is worth noting that the former branch is considerably smaller than the latter. The thyrohyoid membrane spans the anterolateral larynx between the inferior border of the hyoid at C3 and the superior border of the thyroid cartilage at C4. Both the hyoid bone and the laryngeal prominence (or “Adam’s apple”) can serve as palpable landmarks for both branches of the superior laryngeal nerve, which are located roughly midway between the posterior aspects of these structures.

Approximately 1–5 cm anterior to the greater horn of the hyoid, the smaller external laryngeal and larger internal laryngeal nerves diverge. The external laryngeal nerve continues inferiorly along the lateral aspect of the larynx, superficial to the inferior pharyngeal constrictor muscle and anterior to the superior portion of each lobe of the thyroid gland toward the cricothyroid muscle, which it innervates. Only the cricothyroid muscle is innervated by the external laryngeal nerve; all other intrinsic laryngeal muscles are innervated by the recurrent laryngeal nerve.

Rather than descending down the outside of the larynx with the external laryngeal nerve, the internal laryngeal nerve pierces through the thyrohyoid membrane along with the superior laryngeal artery and vein. Upon entering the larynx, the internal laryngeal nerve descends down the supraglottic and transglottic spaces (also referred to as the laryngeal vestibule and intermediate laryngeal cavity). Sensory information from the vestibular (false) folds, laryngeal ventricles, and to some extent the true vocal folds is transmitted by the internal laryngeal nerve to the brainstem for integration. While the internal laryngeal nerve can provide sensory innervation to the true vocal folds and laryngeal structures that are inferior to the folds, sensations from laryngeal structures at or below the true vocal folds are primarily perceived by the recurrent laryngeal nerve’s afferent fibers (Fig. 5.17).





**Fig. 5.17** External anatomy of the larynx. View is from the left side; superior is toward the right. THM thyrohyoid muscle, LP laryngeal prominence of the thyroid cartilage, CTM cricothyroid muscle, TG thyroid gland, C1 branches from anterior ramus of the first cervical spinal nerve innervating the thyrohyoid muscle, SLA superior laryngeal artery piercing the thyrohyoid membrane with the external laryngeal nerve (ExLN), AC ansa cervicalis, and IJV internal jugular vein

The right and left recurrent laryngeal nerves branch off of the right and left vagus nerves in the thorax beneath the right subclavian artery and aortic arch, respectively. A unique feature of the recurrent laryngeal nerves is that they lack bilateral symmetry due to embryonic development, specifically the arteries arising from the fourth pharyngeal arches. The right recurrent laryngeal nerve loops around the right subclavian artery and ascends back into the neck. The left recurrent laryngeal nerve runs anterior to the arch of the aorta at the ligamentum arteriosum (formerly the ductus arteriosus), loops around the aorta, and ascends back into the neck posterior to the arch. Once in the neck, both the right and left recurrent laryngeal nerves pass posterior to the lobes of the thyroid gland, drive deep to the inferior pharyngeal constrictor muscle, and pierce then enter the larynx through the inferolateral portion of the cricothyroid ligament, which spans the anterior surface of the larynx between the inferior border of the thyroid cartilage and the superior border of the cricoid cartilage. The superior border of the cricoid cartilage, roughly located at the level of C6, and the superior aspect of the lobes of the thyroid gland are palpable landmarks for the recurrent laryngeal nerve as it approaches the cricothyroid ligament. The recurrent laryngeal nerve pierces this ligament approximately 3 cm above the superior aspect of the thyroid gland.

Afferent sensory fibers from the recurrent laryngeal nerve innervate the true vocal folds and the laryngeal structures of the subglottic space (also known as the infraglottic cavity) spanning from the true vocal folds to the inferior border of the cricoid cartilage. The recurrent laryngeal nerve can also provide sensory innervation to structures above the true

vocal folds, which are primarily innervated by afferent internal laryngeal nerve fibers. Efferent motor fibers from the recurrent laryngeal nerve will innervate five of the intrinsic laryngeal muscles, namely, the vocalis, thyroarytenoid, transverse arytenoid, posterior cricoarytenoid, and lateral cricoarytenoid muscles. Recall that the cricothyroid muscle is the only laryngeal muscle innervated by the external laryngeal nerve, off of the superior laryngeal nerve, rather than the recurrent laryngeal nerve. Motor innervation from the recurrent laryngeal nerve is solely responsible for the actions of abduction and adduction of the true vocal folds, whereas the act of tightening the folds is achieved by the recurrent laryngeal nerve functioning in tandem with the help of the external laryngeal nerve. The terminal, efferent branch of the recurrent laryngeal nerve is occasionally referred to as the inferior laryngeal nerve.

## Summary

Local anesthesia of the neck is a simple, safe, and effective tool for the cosmetic surgeon. Knowing the basic techniques provides the clinician essential tools for their profession.

## References

1. Shah DM, Darling RC 3rd, Chang BB, et al. Carotid endarterectomy in awake patients: its safety, acceptability, and outcome. *J Vasc Surg.* 1994;19:1015–9.
2. Superficial (and Intermediate) Cervical Plexus Block. <http://www.eurospa.com/wp-content/uploads/2014/10/SCPB-article-1.pdf>
3. NYSORA. Cervical plexus block – landmarks and nerve stimulator technique. NYSORA; 2019, Nov 13. <https://www.nysora.com/techniques/head-and-neck-blocks/cervical/cervical-plexus-block/>
4. Shteif M, et al. The use of the superficial cervical plexus block in the drainage of submandibular and submental abscesses—an alternative for general anesthesia. *J Oral Maxillofac Surg.* 2008;66(12):2642–5. <https://doi.org/10.1016/j.joms.2008.05.365>.
5. Tran DQ, Dugani S, Finlayson RJ. A randomized comparison between ultrasound-guided and landmark-based superficial cervical plexus block. *Reg Anesth Pain Med.* 2010;35(6):539–43.
6. Ultrasound-Guided Cervical Plexus Block. NYSORA, 23 May 2019. <https://www.nysora.com/techniques/head-and-neck-blocks/cervical/ultrasound-guided-cervical-plexus-block/>
7. Waldman SD. Superficial cervical plexus block. *Pain Rev.* 2009;415–6. <https://doi.org/10.1016/b978-1-4160-5893-9.00240-9>.
8. Nguyen J. Anatomy, head and neck, mental nerve. StatPearls [Internet]. U.S. National Library of Medicine; 5 Sept. 2019. <https://www.ncbi.nlm.nih.gov/books/NBK546630/>
9. Zide BM, Swift R. How to block and tackle the face. *Plast Reconstr Surg.* 1998;101(3):840–51. <https://doi.org/10.1097/00006534-199803000-00041>.
10. Nerve Blocks of the Face. 2019, February 18. Retrieved from <https://www.nysora.com/techniques/head-and-neck-blocks/nerve-blocks-face/>
11. Strum A, Chalet SR. Chondrolaryngoplasty-thyroid cartilage reduction. *Facial Plas Surg Clin N Am.* 2019;27:267–72.

# Management of Local Anesthetic Complications

# 6

Ross Camiel, Samuel Roh, and Christy Lottinger

## Introduction

Local anesthetics are frequently administered in dentistry and oral surgery, and as a result are expected to be a potential source of drug-related complications. The statistics regarding incidence of complications from administration of local anesthesia are not well documented but may be anywhere from 4% to 26% [27, 36]. In 1997, a study by Daublander et al. of 2731 patients evaluated by questionnaire after receiving local anesthesia reported a 4.5% overall incidence of complication, 0.07% of which were severe adverse events. Although local anesthetics have been widely accepted as safe, effective, and consistent in the fields of dentistry and oral surgery, this chapter will explore the potential complications of their administration and appropriate strategies for management.

## Systemic Complications

### Psychogenic Reactions

In the setting of local anesthesia administration, psychogenic reactions occur most commonly. Psychogenic reactions will most likely manifest as syncope, “fight or flight response,” and cutaneous flushing. Cutaneous flushing can be observed as spontaneous onset erythema of the lower face, anterior

neck, and chest, and is thought to result from vasodilation of cutaneous vessels [43]. In the anxious patient, fear concerning the procedure can trigger a sympathetic response, leading to physiological alterations. The provider can expect changes in heart rate, respiratory rate, and blood pressure during a psychogenic episode.

### Local Anesthetic Toxicity

Local anesthetic toxicity is exceptionally rare; however, the true incidence of overdose is not well documented in the literature. The FDA (Food and Drug Administration)- and ADA (American Dental Association)-guided maximum dosages of local anesthetics are generally weight based and formulated for “average” patient parameters. Suggested manufacturer dosages (Table 6.1) do not include specific patient considerations and special populations; therefore, it is possible for patients to exhibit signs of overdose at less-than-expected maximum dosages. During administration of local anesthesia, overdose may occur even when administered with appropriate dosage and technique. Even when technique was believed to be ideal, intra-arterial injections increase the potential risk for toxicity.

Special populations, such as the medically compromised, young, elderly, or pregnant, require additional oversight for signs and symptoms of toxicity. Potential for alteration in absorption, metabolism, excretion, and plasma protein binding of the drug must be considered prior to administration. Cardiovascular, hepatic, and renal dysfunction increases the incidence of local anesthesia toxicity. In pregnant patients, it has been suggested that higher cardiac output and reduction in protein binding may predispose the patient to toxicity at lower dosages of local anesthesia [9].

Local anesthetic toxicity may initially present with symptoms such as tinnitus, lightheadedness, and tingling surrounding the oral cavity [43]. During this phase, the patient will exhibit primarily excitatory effects, such as

R. Camiel

Department of Oral and Maxillofacial Surgery, University of Connecticut School of Dental Medicine, Farmington, CT, USA

Department of Oral and Maxillofacial Surgery, Boston Medical Center, Boston University Henry M. Goldman School of Dental Medicine, Boston, MA, USA

e-mail: [camiel@bu.edu](mailto:camiel@bu.edu)

S. Roh (✉) · C. Lottinger

Department of Oral and Maxillofacial Surgery, University of Connecticut School of Dental Medicine, Farmington, CT, USA

e-mail: [roh@uchc.edu](mailto:roh@uchc.edu); [lottinger@uchc.edu](mailto:lottinger@uchc.edu)

**Table 6.1** Manufacturer's maximum recommended dosages

	Cartridge size	Maximum dose		Maximum dose (mg)
		(mg/kg)	(mg/lb)	
Local anesthetic	(mg)	(mg/kg)	(mg/lb)	dose (mg)
2% Lidocaine with 1:100,000				
Epinephrine	36	7	3.2	500
3% Mepivacaine	54	6.6	3	400
2% Mepivacaine with 1:20,000				
Levonordefrin	36	6.6	3	400
4% Prilocaine	72	8	3.6	600
4% Prilocaine with 1:200,000				
Epinephrine	72	8	3.6	600
0.5% Bupivacaine with 1:200,000				
Epinephrine	9	2	0.9	90
4% Articaine with 1:100,000				
Epinephrine	72	7	3.2	500

cardiovascular and central nervous system stimulation. Excitation in this phase can be explained by stimulation of inhibitory neurons as the drug is absorbed systemically [16]. Hypertension, tachycardia, tremors, shivers, twitching, and tonic-clonic convulsions may be encountered in this excitatory phase. Hypertension and tachycardia may also be apparent. As toxicity progresses, the patient will demonstrate a second phase of depression, characterized by myocardial depression, irregular cardiac rhythms, bradycardia, and hypotension. If overdose cannot be reversed, continued decreases in cardiac output and central nervous system response will lead to loss of consciousness [36]. The most dire outcome of local anesthetic overdose is total respiratory and circulatory collapse, which may be fatal.

The severity and magnitude of local anesthetic overdose must be assessed prior to determining management. Management of local anesthetic overdose in the dental or medical office primarily includes supportive measures until the patient can be transported to a higher facility for more definitive treatment. Supportive measures include administration of supplemental oxygen and assessment of airway, breathing, and circulation. In the event that the patient enters a tonic-clonic state, the patient should be placed in the supine position and protected from injuring themselves. In this case, administration of a benzodiazepine anticonvulsant medication, such as midazolam or diazepam, is appropriate [13]. Emergency medical services should be activated, and basic life support provided until help arrives. If the patient does not respond favorably with supportive measures alone, lipid emulsion should be instituted once the patient is transferred to a

hospital setting. Infusion of a 1.5 mL/kg 20% lipid emulsion bolus has shown to be beneficial in severe toxicity by way of sequestering the local anesthetic away from the brain and the heart [58]. Airway management and need for respiratory support should be continually assessed and are paramount to successful recuperation from toxicity. No long-term complications are commonly encountered after recovery [32].

## Acquired Methemoglobinemia

Methemoglobinemia is a rare but serious complication of local anesthetic administration. The condition is characterized by normal ferrous iron within hemoglobin being oxidized to the nonfunctional ferric form. Iron atoms in the ferric form have increased affinity for bound oxygen and decreased affinity for unbound oxygen and carbon dioxide. Therefore, ferric iron impairs normal gas exchange in peripheral tissues, resulting in hypoxia that is unresponsive to supplemental oxygen [20].

The most common cause of acquired methemoglobinemia during administration of local anesthesia is application of topical anesthetics such as benzocaine and injection of prilocaine [46]. Most notably, the excess accumulated metabolites of these medications account for 90% of reported cases. Benzocaine is an ester anesthetic formulation commonly found in topical anesthetics. Though commonly used, topical benzocaine has prompted multiple actions by US Food and Drug Administration. In 2018, the FDA requested manufacturers to halt marketing of over-the-counter oral benzocaine products for use in children less than 2 years old, and to add a methemoglobinemia warning to benzocaine products for adults and children older than 2 years [57].

Another 2019 study produced by US Food and Drug Administration [56] summarized adverse events attributed to benzocaine-associated methemoglobinemia, reporting 119 US cases confirmed by medical diagnosis [29]. Additionally, Cetacaine™ spray (14% benzocaine) and Hurricane™ spray (20% benzocaine) have been implicated in methemoglobinemia when sprayed for more than 1 s, on damaged mucosa, or in dehydrated or pediatric patients [43]. Unfortunately, the severity of methemoglobinemia is not always well correlated with the dose administered, but compliance with maximum recommended doses of benzocaine and prilocaine can prevent patient complications.

A diagnosis of methemoglobinemia should be highly considered in a cyanotic patient that is unresponsive to administration of supplemental oxygen and adequate ventilation. It is also important to understand that SpO<sub>2</sub> readings are expected to fall to 80–85% with rising levels of methemoglobin, but they will stabilize at this level regardless of disease severity. Additionally, it is possible that pulse

oximeters misinterpret fractional arterial oxygen saturation at high levels of methemoglobin. Therefore, pulse oximetry readings are an unreliable measure of patient prognosis. This misinterpretation and potential false elevation of SpO<sub>2</sub> readings on pulse oximetry must always be kept in mind during management [3].

Signs and symptoms of cyanosis include blue or purple coloration seen on the skin, nail beds, and mucous membranes of the patient [21]. The observation of chocolate-brown colored arterial blood is a late manifestation of the condition. The symptoms and severity of methemoglobinemia depends on the fraction of hemoglobin molecules oxidized. Signs and symptoms become apparent at a methemoglobin level of 15–20%, and mental status changes such as headache, fatigue, and syncope may be noted at levels of 20–30%. As the condition progresses, physiologic signs of tachypnea, tachycardia, dysrhythmia, and seizure may be evident at concentrations above 30% [16]. Blood levels of methemoglobin above 70% are often fatal if untreated, as lethargy and stupor ensue [54].

In mild cases of methemoglobinemia, natural enzyme systems in the body will reduce the fraction of affected hemoglobin. In severe and symptomatic cases, the body's metabolic system is overcome, requiring immediate treatment. Management of methemoglobinemia requires immediate administration of 1% methylene blue 1–2 mg/kg administered over a period of 5–10 min, which can be redosed after 1 h up to a maximum of 7 mg/kg [54]. Alternate strategies for treatment include hyperbaric oxygen, charcoal, transfusions, or hemodialysis, which are instituted if the patient fails to respond to other measures. In special populations, such as patients with NADPH and/or G6PD deficiencies, methylene blue will fail as an effective management strategy and will require alternate measures [20].

## Allergy

True allergy to a local anesthetic is estimated to account for only 1% of all adverse reactions during procedures in the oral region, and 80–90% of these cases are allergic contact dermatitis [16]. The majority of patient-reported experiences of allergy to local anesthetics are typically adverse events not related to allergy. Therefore, a careful history is pertinent in determining a patient's risk of adverse allergic reaction to local anesthesia. When allergy is reported, differentiation must be made from transient facial blushing, hematoma, asthmatic wheezing, tachycardia from intravascular or endogenous epinephrine, syncope, or idiosyncratic reaction from the signs of a true allergy [43]. Also, patients have often been told that they are “allergic” by previous providers when in fact they exhibited signs and symptoms of epinephrine sensitivity. In this instance, proper information gathering and

patient counseling is essential prior to proceeding with treatment.

In cases of high suspicion, referral to an allergist is appropriate. Intracutaneous testing has been suggested as a strategy to identify agents that will not trigger an adverse reaction; however, intracutaneous testing has been shown to be of limited value in determining allergy to local anesthetics due to its propensity toward both false-negative and false-positive results [53]. Rather, a provocative “challenge” test is performed using dilutions of suspected allergens, which are sequentially introduced into the mucosa as the patient is monitored for an adverse reaction. Provocative testing is thought to be the ideal strategy to determine if an allergic response is present [4]. However, it must be conducted in close medical surveillance and in the presence of emergency medical personnel, as it carries the risk of anaphylaxis. In patients who have exhibited true local anesthetic allergy, 1% diphenhydramine has been used as an alternative to more traditional local anesthetic agents in patients exhibiting true allergy, reportedly with good success and no cross-reactivity.

The treatment protocol of true allergy to a local anesthetic depends on the progression and severity of symptoms. If recognizable symptoms are present, all further administration of the offending agent must be eliminated. Monitoring is essential, as it is challenging to predict the course of the reaction. In a localized and limited skin reaction, an oral antihistamine such as diphenhydramine 25–50 mg is the most appropriate first-line medication. Depending on practitioner experience, intramuscular or intravenous administration can be utilized.

The onset of cardiovascular or respiratory symptoms prompts immediate emergency medical referral and activation of emergency medical services. To relieve bronchospasm, inhaled albuterol is effective in the early course of the reaction, especially when supplemented with oxygen. If no response is achieved, administration of intravenous isotonic crystalloids and 0.3 mg of intramuscular epinephrine (1:1000; 1 mg/cc) should be considered [43].

## Complications with Use of Vasoconstrictor Additives

Complications with use the use of vasoconstrictor additives are related to adrenergic parameters of the cardiovascular system. When accumulated in sufficient concentrations, vasoconstrictors contained in local anesthetic solutions will act on  $\beta_1$  receptor sites on the heart and  $\alpha_1$  and  $\beta_2$  receptor sites on the vasculature [43]. Adrenergic stimulation includes  $\alpha_1$ -mediated vasoconstriction,  $\beta_1$ -mediated increases in heart rate and contractility, and  $\beta_2$ -mediated skeletal muscle vasodilation. Duration and magnitude of these effects are variable. Signs and symptoms of vasoconstrictor complications include



tremors, dizziness, palpitations, tachycardia, and hypertension. Causes of rapid vasoconstrictor uptake include iatrogenic overdose, intravascular injection, drug interaction, or patient sensitivity. Hemodynamic changes associated with administration of local anesthetic compounded with adrenergic agents is described in the literature; however, these changes are likely clinically relevant only in patients with severe existing cardiovascular disease [2, 8].

In the case of intravascular injection of a small dose of vasopressor, the patient will experience a physiologic challenge. The duration of the response will be short, as epinephrine is rapidly terminated by reuptake at the nerve terminal and metabolism by catechol-O-methyltransferase (COMT). The half-life of vasopressors in central circulation is brief; therefore, complications are likely to manifest acutely. Special care should be taken in patients presenting with evolving myocardial infarction, thyroid storm, acute cocaine intoxication, and dissection aortic aneurysms [43].

Management of vasopressor-related complications should begin by risk versus benefit assessment concerning the limitation of epinephrine-containing solution. Benefits of administering epinephrine include increased duration and profundity of anesthesia. Risks of using epinephrine include cardiovascular stimulation and intravascular injection. Intraoperatively, careful injection technique such as aspiration and slow injection will prevent complications arising from vasoconstrictor additives.

### Potential Adverse Drug Interactions with Vasoconstrictors

A variety of unfavorable interactions may occur between vasoconstrictors and other medications with adrenergic activity. These interactions primarily affect the cardiovascular system, causing alterations in heart rate and blood pressure. Epinephrine is a nonselective alpha and beta receptor agonist, and in medically complex patients taking a variety of pharmaceuticals, physiologic changes in the adrenergic system may occur. The four major scenarios involving drug interaction are:

1. Epinephrine and nonselective  $\beta$ -blockers: when administered with a nonselective  $\beta$ -blocker, unopposed alpha effect of the vasoconstrictor predominates, leading to hypertension and reflex bradycardia. In contrast, this unopposed effect will not occur in patients taking selective  $\beta_1$ -blockers, as the vasodilation from the  $\beta_2$  receptor stimulation will offset  $\alpha_1$  vasoconstriction.
2. Epinephrine and phenothiazine and  $\alpha$ -blockers: when administered with a phenothiazine and  $\alpha$ -blocker, unopposed  $\beta_2$  vasodilation will lower blood pressure.

Vasodilation in the surgical site will promote bleeding and reverse the action of epinephrine due to a more rapid systemic absorption through the vasculature, thus shortening anesthetic activity.

3. Epinephrine and tricyclic antidepressants (TCAs): when administered with tricyclic antidepressants, the neuronal reuptake of adrenergic drugs, such as serotonin and norepinephrine, is inhibited. Inhibition of neuronal uptake produces increased activity of exogenously administered catecholamines. Specifically, this increased potency can be observed with TCA therapy started within 2 weeks of the appointment. TCA medications also permit higher concentrations of vasoconstrictor to be present at the neuronal synapse, resulting in cardiac stimulation. TCA medications have a profound effect when combined with levonordefrin and epinephrine, and even total contraindication has been suggested [61].
4. Epinephrine with monoamine oxidase inhibitors (MAOIs): when administered with MAOIs, there is an accumulation of norepinephrine within presynaptic sympathetic nerve terminals. This is due to the MAOI's inhibition of degradation of tyramine, dopamine, norepinephrine, and serotonin by irreversibly blocking monoamine oxidase. In this case, the patient may present with hypertension from increased concentrations of mixed or indirect sympathomimetic drugs. Furthermore, exogenous epinephrine and levonordefrin will not pose additional risk, as they are direct-acting only.

### Local Complications

#### Local Anesthetic Failure

The three most common clinical scenarios of anesthetic failure include (1) infiltration into inflamed tissues or near painful regions, (2) inability to obtain a mandibular block, and (3) adequate soft tissue anesthesia without reliable pulpal anesthesia.

During the extraction of an infected tooth, anesthesia may be difficult to achieve and maintain. In the locally inflamed region, the pH of the tissue is decreased, therefore favoring the ionized, water-soluble form of the local anesthetic. Because the lipid-soluble form of the drug is required for entry into the nerve itself, diffusion of anesthetic into the intraneural space is impaired, which may serve to inhibit the anesthetic's clinical effect. Local anesthetics with vasoconstrictors are also acidic solutions; therefore continued injection into an environment with an already relatively low pH is unproductive. Mepivacaine can be effectively utilized in this situation, as this molecule has the lowest pKa of the amide group, which increases lipid solubility in acidic solutions.

Inability to obtain a mandibular block can be caused by variation in unique patient anatomy, operator error, intravascular injection, or an unfavorable physiologic profile. Variation in patient anatomy is best demonstrated by differences in prominence of the location of the mandibular foramen and prominence of the medial projection of the internal oblique ridge. Entering from a more posterior approach may improve needle positioning and anesthesia outcomes and panoramic radiograph analysis can reveal variant position of the mandibular foramen. In order to address limitations locating the mandibular foramen, it has been suggested that the Gow-Gates technique for mandibular anesthesia has a higher success rate rather than a traditional inferior alveolar nerve block [19]. The Gow-Gates technique targets the anterolateral surface of the condyle, providing superior anesthesia in close proximity to the divergence of the inferior alveolar, lingual, and buccal nerves. However, controlled clinical studies have failed to prove its advantages.

The etiology of anesthesia of soft tissue without involvement in the dentition is still unknown. Failure to produce profound anesthesia, especially in mandibular anterior teeth, can be explained by the “central core” theory. Nusstein et al. proposed that the inferior alveolar nerve supplies predominantly the mandibular molars, whereas the bicuspid, canine, and incisors are innervated by deeper nerve trunks, which are inaccessible through diffusion [40]. The presence of accessory nerves has also been implicated in difficulty in achieving anesthesia. The mylohyoid nerve is the most commonly implicated accessory nerve branch in failure of mandibular anterior anesthesia [17, 60].

### Injection Pain and Transient Facial Blanching

Display of excessive pain during local anesthesia injection has several etiologies, including decreased pain tolerance, rapid injection of solution, traumatic distention of submucosal tissues, inadvertent intravascular injection, or needle tip proximity to the nerve bundle. Management of injection pain includes a modifying technique, such as withdrawing the needle slightly before continuing to inject. If pain persists, the needle should be removed completely, and a second injection should be performed entering tissue in a different location. A “shock-like” phenomenon during injection is an indicator that the needle tip has entered or is in close proximity to the nerve bundle. In this case, post-operative sensory disturbances are possible.

The use of topical pre-injection local anesthesia can help mitigate pain, especially when used in combination with slow injection technique. According to a study by Reed et al. 2012, needle gauge does not seem to have a significant effect on pain perception during injection [45].

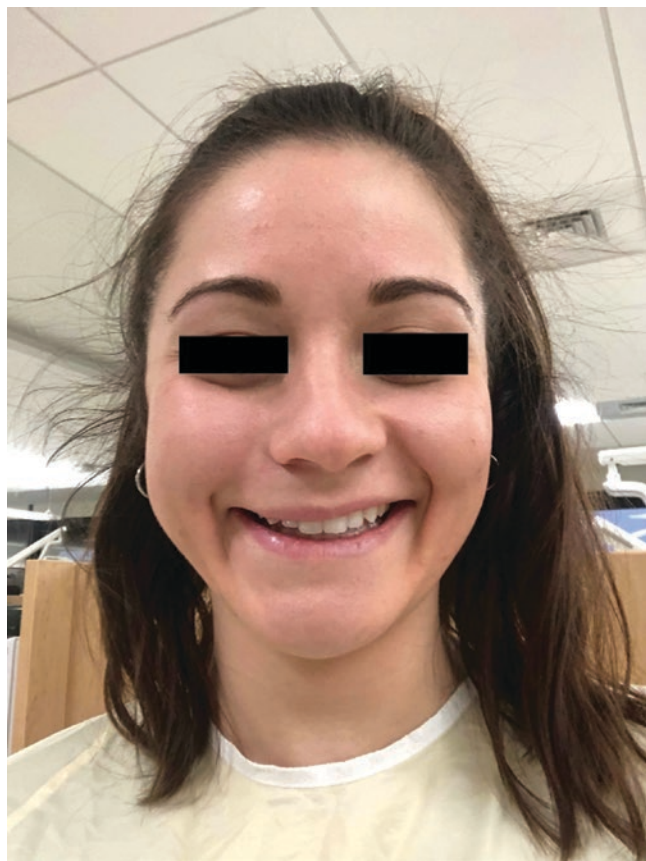A rarer complication, transient facial blanching, is the result of vascular spasm during injection. Local anesthesia, which is inadvertently injected intravascularly, can cause blanching and pain upon the distribution of the vessel. A case report by Pogrel reported blanching of tissues in the left infraorbital region after a left mandibular block [43]. The transient blanching was explained by injection of anesthetic solution into the maxillary artery and was observed in its distribution. In this case, spontaneous resolution occurred in 5–10 min.

### Vascular Injury

Inadvertent injection into a region of high vascularity can cause a variety of different complications. In addition to hemodynamic changes as a result of direct injection of an adrenergic agent into the vasculature, vessel injury may lead to hematoma at the site of injection. In dentistry, this complication occurs most often during injection of a local anesthetic in the posterior maxillary region, as for a posterior superior alveolar nerve block, due to disruption of the pterygoid plexus of veins. Additionally, damage to the posterior superior alveolar artery or its gingival branch is also possible. Hematoma formation can also be caused by inferior alveolar nerve block if the needle is directed too far superiorly [5].

Hematoma formation can occur rapidly after vessel injury and will manifest as cheek swelling on the affected side followed by several days of ecchymosis as the hematoma resolves (See Fig. 6.1). Although bleeding is generally self-limiting, the goals of initial treatment are to achieve hemostasis with pressure and minimize inflammation in the area by application of an ice pack. The patient should be reevaluated in 24–48 h to assess for signs of inadequate hemostasis or secondary infection, as hematomas are prone to colonization by bacteria. Hematomas generally resolve on their own in 1–2 weeks, although the healing process is often accompanied by trismus and/or ecchymosis. The frequency of hematoma formation after injection is higher with maxillary posterior injections, but the overall incidence is around 0.1% [28].

Intravascular injection may also occur as a result of vascular insult. Manifestations may include blanching of the local cutaneous region or signs of central nervous system toxicity as the injected medication is rapidly circulated through the systemic vasculature. Management of intravascular injection will be patient-dependent but often can be managed by patient reassurance alone. If the patient becomes hemodynamically unstable during local anesthesia administration, appropriate emergency medical interventions should be activated, and the patient’s airway, breathing, and



**Fig. 6.1** Right-sided hematoma immediately following posterior superior alveolar nerve injection

circulation should be supported as necessary until emergency medical support arrives.

### Unintended Nerve Involvement (Paresthesia and Palsy)

In rare instances, unintended nerve involvement in a non-surgical region is possible during local anesthesia administration. Increased lipid solubility, enhanced diffusion, misdirection of the needle, inappropriate depth of penetration, or intravascular injection are believed to be the potential causes of unintended nerve involvement.

Unintended paralysis of the facial nerve (seventh cranial nerve) can occur occasionally during routine inferior alveolar nerve injections. The most common etiology is inadvertent administration into the parotid gland from an inferior alveolar nerve block that was directed too far posteriorly [13]. This is more common in patients who have a small anterior–posterior dimension of the mandibular ramus, and injection into the parotid capsule will lead to unintended, transient facial nerve palsy. In addition to the inferior alveolar nerve block, auriculotemporal nerve blocks or intra-

articular injections into the temporomandibular joint have also been described.

On clinical presentation, patients may present with facial weakness such as an inability to furrow the forehead, raise the eyebrow, close the upper eyelid, retract the commissure of the lips to smile, or to turn down the lower lip to grimace [43]. Palsy of the facial nerve most often presents immediately due to direct blockade of neural conduction. Therefore, it is expected that the palsy resolves within a few hours, depending on the anesthetic injected. In some instances, a delayed response can occur, ranging from hours to days [16]. Resolution of facial nerve palsy will occur when the anesthetic diffuses away from the affected nerve. Delayed-type palsy, however, may take anywhere from 24 h to several months to fully resolve, and the etiology is not well understood.

Management of facial nerve paralysis includes measures to prevent injury to the eye, such as corneal abrasion. Therefore, it is recommended that the eyelid be taped shut when the local anesthetic is longer-acting, such as bupivacaine. Systemic steroid therapy may also be considered in these cases [55].

It has also been postulated that delayed facial nerve palsy may be caused by latent viral herpes reactivation during an injection of local anesthesia and that following an injection along the course of a nerve, reactivation of the virus from the trigeminal ganglion can occur with physical and chemical stress. Management of facial nerve palsy associated with viral herpes reactivation may necessitate antiviral agents such as acyclovir as clinically indicated [11].

### Nerve Injury Following Local Anesthetic Injection

It is a well-known phenomenon that on rare occasions during local anesthetic injection, temporary or even permanent nerve involvement is possible. Nerve injury can manifest as anesthesia, paresthesia, dysesthesia, hyperesthesia, or a variety of combinations [44]. The incidence of permanent nerve involvement from a local anesthetic injection is exceptionally rare, ranging from 1 in 25,000 injections to 1 in 1,000,000 injections. In contrast, temporary nerve injuries occur 5–6 times more frequently, with 80–85% of injuries recovering spontaneously.

Nerve injury resulting from local anesthesia differs significantly from injury through direct surgical trauma. In many cases, the nerve injury is poorly localized and can migrate to involve additional nerves not directly associated with the injection site. The inferior alveolar nerve block is the most commonly implicated injection technique. The incidence of trigeminal nerve injury varies wildly in the literature, ranging from rates of 1:20,000 and 1:785,000

[37]. Fortunately, it is thought that 85–90% of injured patients recover full sensation over the course of a few days up to several months [35]. Although it is counter-intuitive, the lingual nerve is twice as often affected, as it is uni-fascicular in the area where the needle passes for the injection.

The exact mechanism of nerve injury as a result of local anesthetic injection is unknown. It has been disproven that direct mechanical trauma to the nerve during insertion of the needle is the primary cause of nerve injury. Based on cadaveric experiments in a study by Pogrel, it is not plausible that a single pass of a local anesthetic needle will cause significant injury [44]. Alternatively, it has been suggested that barbing of the needle after contacting bone followed by withdrawal of the needle can cause trauma [49]. However, the barb theory is not consistent with reports by patients who claim an “electric shock” sensation was present during the injury. Additionally, piercing the inferior alveolar nerve with a local anesthetic needle normally separates the fascicles rather than damaging them directly.

Other theories have emerged which have aimed at exploring hematologic or neurotoxic insults by local anesthetic agents. One theory suggests that the local anesthetic needle may damage blood vessels which communicate with nerve fascicles, leading to neurotoxicity mediated by an interruption in blood supply [44]. Another suggests that the chemical composition of local anesthetics have potential neurotoxicity. However, doses of local anesthesia administered during routine procedures are not high enough to have neurotoxic potential; therefore, it is unclear if chemical toxicity is the cause of neural injury [59].

Treatment of damage to nerves of the oral cavity is unpredictable. When injury does occur, a neurosensory exam should be performed and repeated at each follow-up in order to document the baseline neurosensory status as well as progression and duration of the injury. First-line treatment for patients presenting with nerve injury commonly includes steroids, NSAIDs, and B vitamins; however, long-term success is limited [35]. Steroids and NSAIDs have the potential to alleviate edema surrounding an acutely inflamed nerve. However, as nerve injury enters the chronic phase, it is recommended that painful dysesthesias must be treated medically in a neurology or pain clinic. If symptoms do not resolve within 1–2 weeks after the injury, the standard regimen would include carbamazepine, gabapentin, or pregabalin, plus a tricyclic-type and analgesic medication. Surgical intervention for patients suffering from dysesthesia is generally not recommended because the injured nerve generally appears normal macroscopically and microscopically, and microneurosurgical repair in patients with existing neuropathic pain has a high failure rate [62].

## Ophthalmologic Complications

The etiology of local anesthetic agents migrating to the ocular region is subject to debate [7, 30, 50].

The anatomy of the midface should be examined to better understand how local anesthetic agents can lead to ocular complications. In the posterior and lateral portion of the maxilla, there is communication with the inferior orbital fissure. Anesthetic agents have the potential to migrate through myofascial planes or enter the intravascular space in this region, reaching the motor and autonomic nerves of the eyes. Deep needle positioning, enhanced diffusion, and intravascular injection can lead to an ocular complication [43].

Presenting signs and symptoms of ocular complications include blurry vision, temporary blindness, mydriasis, ptosis, diplopia, or ophthalmoplegia [43]. Abducens nerve palsy is the most commonly described ocular complication after local anesthesia, which results in a paralysis of the lateral rectus muscle and therefore inability to move the affected globe laterally, leading to double vision in all fields of gaze. Paralysis of the lateral rectus will resolve uneventfully as the local anesthesia is metabolized.

In rare instances, permanent, unilateral blindness has occurred followed injection of local anesthesia in the posterior maxilla. Rates of permanent visual impairment are as high as 8% [1]. The etiology of the blindness is presumed to be diffusion of the medication to the optic nerve and resultant neurotoxicity. This scenario demands prompt referral to an ophthalmologist. Additionally, permanent blindness following an inferior nerve block has also been described.

Prevention of ocular complications can be achieved by aspirating prior to injection and proper injection technique. In the event that visual disturbances develop, monitoring and reassessment is required to ensure resolution of symptoms. If symptoms do not resolve within 6 h, referral to an ophthalmologist is warranted to assess for damage to the globe and associated structures [7].

## Localized Tissue Injury

In general, care must be taken to prevent accidental, self-inflicted trauma to soft tissue from administration of local anesthesia. High-risk populations for accidental soft tissue injury include children and the mentally disabled, in whom soft tissue injury can occur in as high as 18% of children, compared to about a 7% risk in individuals of 12 years and older [12]. Iatrogenic injury, including damage to the lips, cheek, and tongue, can present in the form of laceration, ulceration, and/or contusion [43].



Injection of local anesthesia can manifest as physical and/or chemical injury, in many cases presenting as ulcerations [39]. The primary factors affecting the severity of localized tissue injury are the (1) volume of anesthetic injected, (2) location of injection, and (3) presence or absence of vasoconstrictors. Higher volumes of anesthetic, tightly attached mucosa, and presence of epinephrine will increase the risk of ulceration after injection [16].

Management of soft tissue injury should be focused on for protection and prevention. The treatment of soft tissue injury is primarily supportive. In the literature, avoidance of bilateral mandibular block anesthesia as a soft tissue injury prevention strategy, especially in young children, has been subject to debate. In a study by College et al., rates of soft tissue injury have not significantly differed between patients receiving unilateral versus bilateral blocks [12]. The use of shorter acting local anesthetic agents, such as plain mepivacaine, has been explored as an alternative prevention strategy.

Phentolaminemesylate (OraVerse) was recently approved in 2008 by the FDA for prevention of soft tissue injuries caused by local anesthetics. Phentolaminemesylate is a non-selective competitive antagonist of alpha-adrenergic receptors and therefore reverses the effects of local anesthesia by opposing alpha receptors and inducing vasodilation. This enhances clearance of the local anesthesia from the site and results in a more rapid return of sensation. Phentolaminemesylate results in rapid recovery of numbness in 50–60% of normal recovery time. OraVerse is available in standard cartridges as a solution with 0.4 mg phentolaminemesylate. Its recommended dosage is not weight-based; rather it is recommended to administer the same number of cartridges of OraVerse as were administered for local anesthesia, with a total dosage of 0.2 mg (1/2 carpule) maximum in children weighing between 15 and 30 kg. It is not recommended for use in children under the age of 3 or weighing less than 15 kg [33].

## Needle Breakage

Overall, needle breakage is a rare occurrence. Since the 1960s, the widespread acceptance of disposal needles and improvements in flexible alloys used in manufacturing has dramatically decreased needle breakage rates [15]. Needle breakage most commonly occurs during inferior alveolar nerve blocks, causing the needle to be dislodged in the pterygomandibular space in close proximity to vital structures. The majority of events occur with a 30-gauge needle [33]. Although bending of the injection needles is common practice, it should be used cautiously, as needles will resist no more than three bends prior to breakage. Needle breakage occurs with a sudden or unexpected patient movement, jerk-

ing, or improper technique. Prevention of needle breakage can be accomplished through patient management and anticipation of adverse patient reactions. Dentists and oral surgeons should reduce the number of injections made with the same needle. Avoidance of penetration to the needle hub, straight line technique, and slow injection can minimize breakage and improve retrieval outcomes.

In the event that needle breakage occurs, retrieval should be attempted if the needle is visible. Retrieval should be performed with a hemostat while the patient is motionless. If invisible, surgical retrieval with appropriate referral is indicated. A variety of needle retrieval methods exist, such as using plain film radiography, fluoroscopy, image intensifiers, reference markers, and magnets [14, 24, 26, 38, 52]. Innovations in medical technology have made 3D computer-assisted navigation systems for minimally invasive needle retrieval possible and have become the standard of care in stereotactic neurosurgery, endoscopic sinus surgery, skull base surgery, and foreign body removal [47].

In the oral and maxillofacial surgery literature, the MedtronicAxiEM navigation system has been utilized in multiple case reports demonstrating the effective removal of needles from the pterygomandibular space [51]. Minimally invasion retrieval using a Medtronic surgical navigation system requires (1) pre-operative maxillofacial CT scan, (2) tracker device connected to the patient throughout general anesthesia, and (3) tracer registration probe. Real-time navigation is achieved by synchronization of imaging data with the patient's actual position. Direct patient-to-CT data registration is achieved by tracing soft and hard tissue landmarks of the face and oral cavity with the navigation probe. Once calibrated, continuous, three-dimensional tracking of the probe is available to the operator. It is required that the patient position is identical to the CT scan position. In the case report presented by Steiner et al., identical position was made possible by a custom interocclusal splint, which stabilized the mandibular position [51]. Positional discrepancy of 3D navigation systems has been verified to be less than 1 mm [41].

Ultimately, 3D surgical navigation is advantageous because of its potential for improved accuracy and precision in real time to the operating surgeon. 3D navigation can decrease patient morbidity by improved surgeon accuracy and precision. Minimizing damage to vital structures, the size of the surgical access, retrieval time, and opportunity for additional complications will allow for rapid recovery and success for the patient.

## Trismus

Trismus is an uncommon complication of local anesthetic injection. By definition, trismus is tonic contraction of

the muscles of mastication, leading to restricted opening and limited range of motion. In the literature, trismus is known to be associated with inferior alveolar nerve blocks and posterior maxillary injections. According to Stone and Kaban, the most likely etiology is intramuscular edema and hemorrhage. An alternative theory suggests that the edema and hemorrhage is caused by chemical injury to the medial pterygoid muscle during attempted mandibular block injections [6]. Hematoma and needle-track infection may also result from contaminated needles and repeated injections to the same site. Acute pain and inflammation from post-injection trismus are accompanied by muscle spasm, resulting in limitation in mandibular movement [16]. Treatment is aimed at addressing pain and inflammation and improving range of motion, often with NSAIDs, moist heat, and physiotherapy. In the event that the trismus does not resolve spontaneously, gradual forced opening may be required, which can be achieved with physiotherapy or tongue blade therapy. Movement of the jaw prevents fibrosis, which can lead to long-term hypomobility. If infection is suspected, antibiotics should be initiated early.

## Summary

Local anesthesia is indispensable to modern medicine and dentistry; however, both local and systemic complications can occur during routine use. Fortunately, most local anesthesia-related complications are manageable using simple strategies and patient reassurance. Other, more serious events may require more complicated management strategies as well as assistance from emergency medical personnel and transport to a medical facility. Through preventative measures and timely, appropriate interventions, patient morbidity can be reduced and positive outcomes maximized. It is imperative that the local anesthesia provider be well acquainted with the potential for complications and the various management strategies for these events. Additionally, as newer agents are developed, these management strategies may require supplementation to account for a changing market of local anesthetics.

## References

- Alamanos C. Ophthalmologic complications after administration of local anesthesia in dentistry: a systematic review. *Oral Surg Oral Med Oral Pathol Oral Radiol*. 2016;121:39–50.
- Bader JD. A systematic review of cardiovascular effects of epinephrine on hypertensive dental patients. *Oral Surg Oral Med Oral Pathol Oral Radiol Endod*. 2002;93:647–53.
- Barker SJ, Tremper KK, Hyatt J. Effects of methemoglobinemia on pulse oximetry and mixed venous oximetry. *Anesthesiology*. 1989;70:112–7.
- Berkun Y. Evaluation of adverse reactions to local anesthetics: experience with 236 patients. *Ann Allergy Asthma Immunol*. 2003;91:342–5.
- Blanton PL. Avoiding complications in local anesthesia induction: anatomical considerations. *J Am Dent Assoc*. 2003;134:888–93.
- Bosack RC. *Anesthesia complications in the dental office*. Chichester: John Wiley & Sons; 2015.
- Boynes SG. Ocular complications associated with local anesthesia administration in dentistry. *Dent Clin N Am*. 2010;54:677–86.
- Brown RS. Epinephrine and local anesthesia revisited. *Oral Surg Oral Med Oral Pathol Oral Radiol Endod*. 2005;100:401–8.
- Bryne E. Toxicity of local anaesthetic agents. *Trends Anaesth Crit Care*. 2013;3:25–30.
- Butterworth JF. Models and mechanisms of local anesthetic cardiac toxicity. *Reg Anesth Pain Med*. 2010;35:167–76.
- Chevalier V. Facial palsy after inferior alveolar nerve block: case report and review of the literature. *Int J Oral Maxillofac Surg*. 2010;39:1139–42.
- College C, Feigal R, Wandera A, Strange M. Bilateral versus unilateral mandibular block anesthesia in a pediatric population. *Pediatr Dent*. 2000;22:453–7.
- Cummings YD. Complications of local anesthesia used in oral and maxillofacial surgery. *Oral Maxillofac Surg Clin North Am*. 2011;23:369–77.
- Song EK, Seon JK, Park SJ, Yoon TR. Accuracy of navigation: a comparative study of infrared optical and electromagnetic navigation. *Orthopedics*. 2008;31:76.
- Ethunandan M. Needle breakage following inferior alveolar nerve block: implications and management. *Br Dent J*. 2007;202:395–7.
- Lottinger C. Local anesthetics in dentistry. In: Ferneini E, Goupil M, editors. *Evidence-based oral surgery: a clinical guide for the general dental practitioner*. Berlin: Springer; 2019. p. 129–50.
- Frommer J, Mele FA, Monroe CW. The possible role of the mylohyoid nerve in mandibular posterior tooth sensation. *J Am Dent Assoc*. 1972;85:113–7.
- Pérusse R, Goulet JP, Turcotte JY. Contraindications to vasoconstrictors in dentistry: Part I. Cardiovascular diseases. *Oral Surg Oral Med Oral Pathol*. 1992;74(5):679–86.
- Gow-Gates. Mandibular conduction anesthesia: a new technique using extraoral landmarks. *Oral Surg Oral Med Oral Pathol*. 1973;36:321–30.
- Hall DL, Moses MK, Weaver JM, Yanich JP, Voyles JW, Reed DN. Dental anesthesia management of methemoglobinemia-susceptible patients: a case report and review of the literature. *Anesth Prog*. 2004;51:24–7.
- Hegedus F. Benzocaine-induced methemoglobinemia. *Anesth Prog*. 2005;52:136–9.
- Hersh EV. Beta-adrenergic blocking agents and dental vasoconstrictors. *Dent Clin N Am*. 2010;54:687–96.
- Hillerup S. Iatrogenic injury to the inferior alveolar nerve: etiology, signs and symptoms, and observations on recovery. *Int J Oral Maxillofac Surg*. 2008;37:704–9.
- Ho KH. A simple technique for localizing a broken dental needle in the pterygomandibular region. *Aust Dent J*. 1988;33:308–9.
- Jastak JT. Vasoconstrictors and local anesthesia: a review and rationale for use. *J Am Dent Assoc*. 1989;107:623–30.
- Johansson B. Fragment of broken instrument removed from field of operation by an electromagnet. *Br J Oral Maxillofac Surg*. 1987;25:265–6.
- Gall H, Kaufmann R, Kalveram CM. Adverse reactions to local anesthetics: analysis of 197 cases. *J Allergy Clin Immunol*. 1996;97(4):933–7.
- Kuster CG. Frequency of hematoma formation subsequent to injection of dental local anesthetics in children. *Anesth Prog*. 1984;31:130–2.

29. Lardieri AB. Cases of benzocaine-associated methemoglobinemia identified in the FDA adverse event reporting system and the literature. *Ann Pharmacother*. 2019;53:437–8.
30. Magliocca KR. Transient diplopia following maxillary local anesthetic injection. *Oral Surg Oral Med Oral Pathol Oral Radiol Endodontology*. 2006;101:730–3.
31. Malamed SF, Gagnon S, Leblanc D. Articaine hydrochloride: a study of the safety of a new amide local anesthetic. *J Am Dent Assoc*. 2001;132:177–85.
32. Malamed S. *Handbook of local anesthesia*. 6th ed. St Louis: Mosby; 2013.
33. Malamed SF. Local anesthesia reversal. *Dent Today*. 2010;29(3):65–74.
34. Malamed SG. Efficacy of articaine: a new amide local anesthetic. *J Am Dent Assoc*. 2000;131:645–2.
35. Moon S, Lee SJ, Kim E, Lee CY. Hypoesthesia after IAN block anesthesia with lidocaine: management of mild to moderate nerve injury. *Restor Dent Endod*. 2012;37(4):232–5.
36. Moore PA, Hersh EV. Local anesthetics: pharmacology and toxicity. *Dent Clin N Am*. 2010a;54:587–99.
37. Moore PA, Haas DA. Paresthesias in dentistry. *Dent Clin N Am*. 2010b;54(4):715–30.
38. Nezafati S. Removal of broken dental needle using mobile digital C-arm. *J Oral Sci*. 2008;50:351–3.
39. Nouette-Gaulain K. Local anesthetic ‘in-situ’ toxicity during peripheral nerve blocks: update on mechanisms and prevention. *Curr Opin Anaesthesiol*. 2012;25:589–95.
40. Nusstein JM. Local anesthesia strategies for the patient with a “hot” tooth. *Dent Clin N Am*. 2010;54:237–47.
41. Park SS. The clinical application of the dental mini C-arm for the removal of broken instruments in soft and hard tissue in the oral and maxillofacial area. *J Cranio-Maxillofac Surg*. 2012;40:572–8.
42. Peñarocha-Diogo M. Ophthalmologic complications after intraoral local anesthesia with articaine. *Oral Surg Oral Med Oral Pathol Oral Radiol Endod*. 2000;90:21–4.
43. Pogrel MA, Stevens RL, Bosack RC, Orr T. Chapter 31: Complications with the use of local anesthetics. In: Bosack CM, Lieblisch S, eds. *Anesthesia Complications in the Dental Office*. 1st ed. Wiley-Blackwell; 2015:207–18.
44. Pogrel MA, Bryan J, Regezi J. Nerve damage associated with inferior alveolar nerve blocks. *J Am Dent Assoc*. 1995;126:1150–5.
45. Reed KL. Local anesthesia part 2: technical considerations. *Anesth Prog*. 2012;59:127–37.
46. Rehman HU. Evidence-based case review: methemoglobinemia. *West J Med*. 2001;175:193–6.
47. Siebegg M. Image guided surgical navigation for removal of foreign bodies in the head and neck. *J Cranio-Maxillofac Surg*. 2001;29:321–5.
48. Specia SJ. Allergic reactions to local anesthetic formulations. *Dent Clin N Am*. 2010;54:655–64.
49. Stacy GC. Barbed needle and inexplicable paresthesias and trismus after dental regional anesthesia. *Oral Surg Oral Med Oral Pathol*. 1994;77:585–8.
50. Steenen SA. Ophthalmologic complications after intraoral local anesthesia: case report and review of literature. *Oral Surg Oral Med Oral Pathol Oral Radiol*. 2012;113:e1–5.
51. Stein KM. Use of intraoperative navigation for minimally invasive retrieval of a broken dental needle. *J Oral Maxillofac Surg*. 2015;73:1911–6.
52. Thompson M. Locating broken dental needles. *Int J Oral Maxillofac Surg*. 2003;32:642–4.
53. Tomoyasu Y, Mukae K, Suda M, et al. Allergic reactions to local anesthetics in dental patients: analysis of intracutaneous and challenge tests. *Open Dent J*. 2011;5:146–9.
54. Trapp L, Will J. Acquired methemoglobinemia revisited. *Dent Clin N Am*. 2010;54:665–75.
55. Tzermpos FH. Transient delayed facial nerve palsy after inferior alveolar nerve block anesthesia. *Anesth Prog*. 2012;59:22–7.
56. U.S. Food and Drug Administration. *Ann Pharmacother*. 2019:437–8.
57. U.S. Food and Drug Administration. Risk of serious and potentially fatal blood disorder prompts FDA action on oral over-the-counter benzocaine products used for teething and mouth pain and prescription local anesthetics; 2018. <https://www.fda.gov>
58. Weinberg G. Treatment of local anesthetic systemic toxicity. *Reg Anesth Pain Med*. 2010:188–93.
59. Werdnhausen R. Apoptosis induction by different local anesthetics in a neuroblastoma cell line. *Br J Anaesth*. 2009;103:711–8.
60. Wilson S, Johns P, Fuller PM. The inferior alveolar and mylohyoid nerves: an anatomic study and relationship to local anesthesia of the anterior mandibular teeth. *J Am Dent Assoc*. 1984;108:350–2.
61. Yagiela JA. Drug interactions and vasoconstrictors used in local anesthetic solutions. *Oral Surg Oral Med Oral Pathol*. 1985;59:565–71.
62. Zuniga JR. Sensory outcomes after reconstruction of lingual and inferior alveolar nerve discontinuities using processed nerve allograft—a case series. *J Oral Maxillofac Surg*. 2015;73(4):734–44.

---

## Part II

### Regional Anatomy

Christine E. Niekrash

Frank H. Netter MD School of Medicine,  
Quinnipiac University, Hamden, CT, USA



# Anatomy of the Integumentary System

# 7

Bruce M. Koeppen and Christine E. Niekrash

## Overview

The integumentary system consists of the skin, and the epidermal derivatives of the skin:

- Hair follicles
- Sweat glands
- Sebaceous glands
- Nails (*note*: the mammary glands are also epidermal derivatives of the skin but are not discussed in this chapter)

Skin is the body's largest organ and constitutes 15–20% of body mass. It serves multiple functions, including the following:

- *Barrier* – skin provides a barrier to numerous agents in the external environment (i.e., chemical, physical, and biological).
- *Immunity* – skin contains large numbers of antigen processing cells that interact with the body's adaptive immune system, and in that way provide immunologic information.
- *Homeostasis* – skin is an important effector organ involved in the regulation of body temperature, and contributes to fluid balance by preventing water loss.
- *Sensory* – skin is richly innervated with sensory nerve fibers and associated receptors.
- *Endocrine* – skin produces both androgens and estrogens and importantly a precursor of vitamin D.
- *Excretion* – skin excretes substances via its associated glands (e.g., sweat, sebaceous and apocrine).

Skin can also be a route for the absorption of some lipid-soluble substances, as well as the administration of some drugs or therapeutic agents (e.g., nicotine patches).

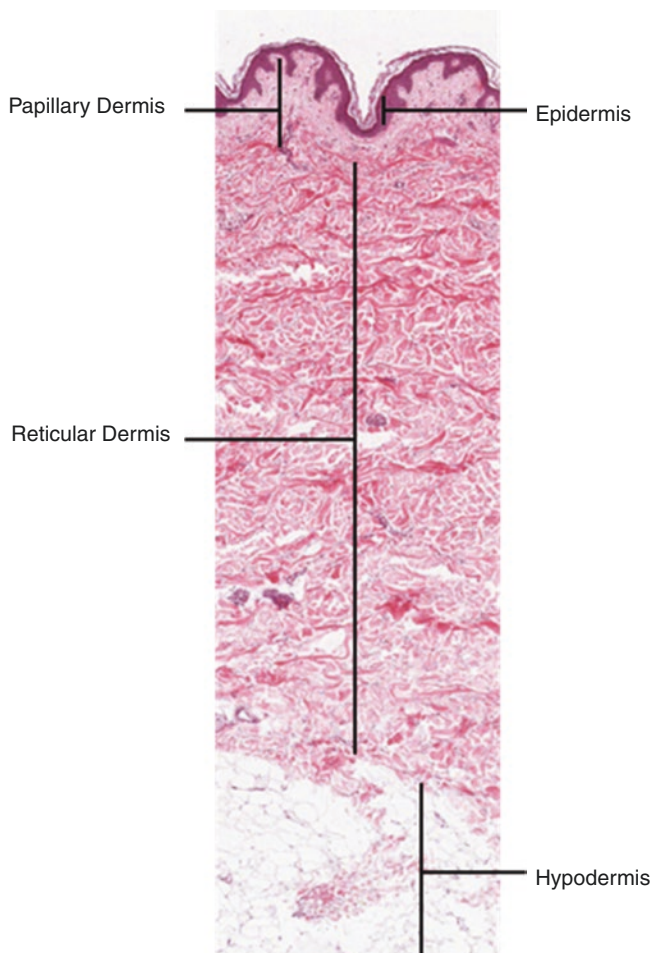
Skin consists of two layers. The outermost layer is the *epidermis*, which is comprised of a stratified squamous keratinized epithelium. The cells of the epidermis continually turnover, with the outermost layer of dead keratinized cells sloughed off daily by a process termed desquamation. Immediately below the epidermis is the *dermis*, which is subdivided into the more superficial *papillary dermis* comprised of loose connective tissue and a deeper *reticular dermis* comprised of dense irregular connective tissue. The dermis sits upon the *hypodermis*, which is comprised primarily of adipose tissue and is not considered to be part of the skin. Figure 7.1 illustrates the layers of the skin as well as the hypodermis.

The skin on the palms of the hands and the soles of the feet are exposed to the greatest abrasive forces. As a result, the epidermis is very thick in these areas. Accordingly, the skin at these sites is called *thick skin*. Thick skin lacks hair follicles as well as their associated sebaceous glands, but it does contain sweat glands. Skin over the remainder of the body has a much thinner epidermis and is therefore called *thin skin*. With the exception of a few sites, thin skin contains hair follicles, sebaceous glands, and sweat glands. The dermis of the skin also varies in thickness. The thickest dermis is found in the skin of the upper region of the back, while the thinnest is found in the skin of the eyelid.

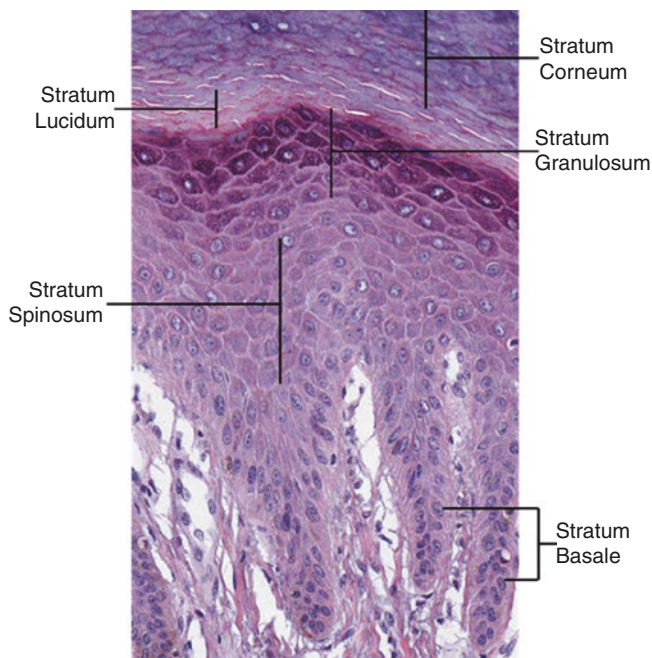
## Epidermis

The epidermis is a stratified squamous epithelium and is comprised of four distinct layers of *keratinocytes* (*note*: a fifth layer, called the *stratum lucidum*, can often be seen in thick skin). Figure 7.2 illustrates the layers of the epidermis in a histologic section of thick skin.

B. M. Koeppen · C. E. Niekrash (✉)  
Frank H. Netter MD School of Medicine, Quinnipiac University,  
Hamden, CT, USA  
e-mail: [Bruce.Koeppen@quinnipiac.edu](mailto:Bruce.Koeppen@quinnipiac.edu);  
[christine.niekrash@quinnipiac.edu](mailto:christine.niekrash@quinnipiac.edu)



**Fig. 7.1** Section of thin skin showing the layers of the skin as well as the underlying hypodermis



**Fig. 7.2** The layers of the epidermis. This is a section of thick skin, which includes the stratum lucidum. The stratum lucidum is not found in the epidermis of thin skin. The stratum basale is a single layer of cells

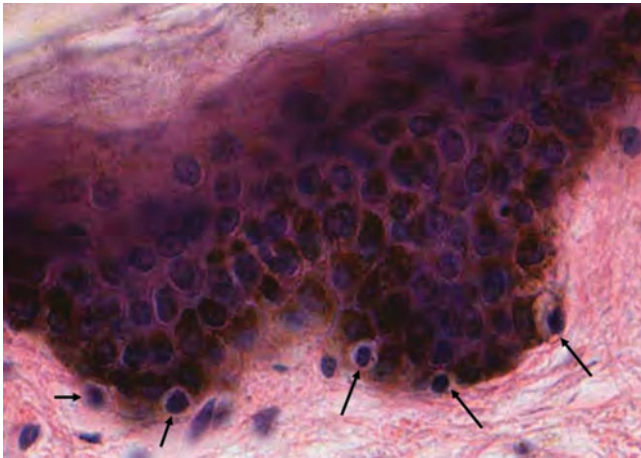
The deepest layer is the *stratum basale*. This single layer of cells contains the stem cells from which the keratinocytes are derived. The melanin producing *melanocytes* are also found in this layer, as are the mechanoreceptor *Merkel's cells*. Immediately above the stratum basale is the *stratum spinosum*. This layer is so named because the cells after fixation have short processes or spines. These spines are formed because of desmosomes connecting adjacent cells. They appear as spines because of shrinkage of the cells during tissue processing for light microscopy. Because of their appearance, the cells are also referred to as *prickle cells*. The next more superficial layer is the *stratum granulosum*. The granular appearance of the cytoplasm of these cells is a result of the presence of *keratohyalin granules*. These granules contain *filaggrin* and *trichohyalin*, which function as promoters for the aggregation of keratin filaments, which begins the process of *keratinization*. The cells of the stratum granulosum also contain lipid-containing *lamellar bodies*. The lipids within the lamellar bodies (e.g., glycosphingolipids, phospholipids, and ceramides) are secreted onto the surface of the cell forming a water impermeable lipid envelope. The outermost layer consists of dead keratinized cells and is called the *stratum corneum*. In some histologic sections of thick skin, the deepest layer of the stratum corneum stains poorly, and thus is given the name of *stratum lucidum* (see Fig. 7.2).

The following cells (and their percentages) are found in the epidermis:

- Keratinocytes ( $\approx 85\%$ )
- Melanocytes ( $\approx 5\%$ )
- Merkel's cells ( $<5\%$ )
- Langerhans' cells ( $<10\%$ )

Keratinocytes are derived from stem cells located in the stratum basale, which divide every 1–2 days. Over the next 30 days or so the keratinocytes migrate toward the surface of the epidermis through the stratum spinosum and stratum granulosum. During this time, they are synthesizing the proteins needed for the keratinization process, which takes place as the cells leave the stratum granulosum and enter the stratum corneum. These cells are also synthesizing the lipids that will make up the water impermeable lipid envelope. During the keratinization process, the cells undergo apoptosis, at which point they become devoid of cellular organelles and are completely filled with keratin. They then reside within the stratum corneum for another approximately 14–15 days before they are sloughed off at the surface. Thus, turnover of the keratinocytes in the epidermis takes approximately 45 days. In individuals with psoriasis, keratinocyte turnover is greatly accelerated, taking only 8–10 days.

Melanocytes are scattered within the stratum basale (see Fig. 7.3). They have long dendritic projections that extend up into the stratum spinosum. Melanin is synthesized from tyrosine. A key enzyme in this process is tyrosinase, the activity



**Fig. 7.3** Section of skin from an individual with dark skin. The cell bodies of melanocytes are indicated by the arrow. The dendritic projections of the cells are too small to be resolved with the light microscope. The cell bodies contain immature melanin, which is colorless. The dark melanin is contained with adjacent keratinocytes

of which is stimulated by pituitary-derived melanocyte stimulating hormone (*MSH*), which is a cleavage product of *pre-proopiomelanocortin (POMC)*. Two types of melanin are synthesized: eumelanin and pheomelanin. Eumelanin is brown-black in color, while pheomelanin is yellow-red in color. The melanin is packaged into vesicles termed melanosomes. The melanosomes are transported along the cell's dendritic processes, where keratinocytes in the stratum spinosum phagocytose small pieces of the melanocyte's melanosome-containing cytoplasm, a process termed *cytochrome secretion*. The melanosomes are released into the cytoplasm of the keratinocytes where they accumulate around the nucleus to provide protection from harmful UV radiation.

The ratio of melanocytes to keratinocytes is relatively constant regardless of ethnicity and skin color. Skin color is therefore determined by the ratio of eumelanin and pheomelanin synthesized by the melanocytes, and the rate at which melanosomes are degraded within the keratinocytes. Compared to individuals with light skin, melanosomes are degraded more slowly in individuals with dark skin.

*Langerhans' cells* are dispersed throughout the stratum spinosum and stratum granulosum. These cells originate in the bone marrow, travel in the blood, and take up residence in the epidermis. They are the macrophages of the epidermis. Once a Langerhans' cell engulfs foreign material, it migrates out of the epidermis to a regional lymph node where it serves as an antigen-presenting cell to initiate an adaptive immune response. Langerhans' cells are involved in delayed hypersensitivity reactions of the skin (e.g., contact dermatitis).

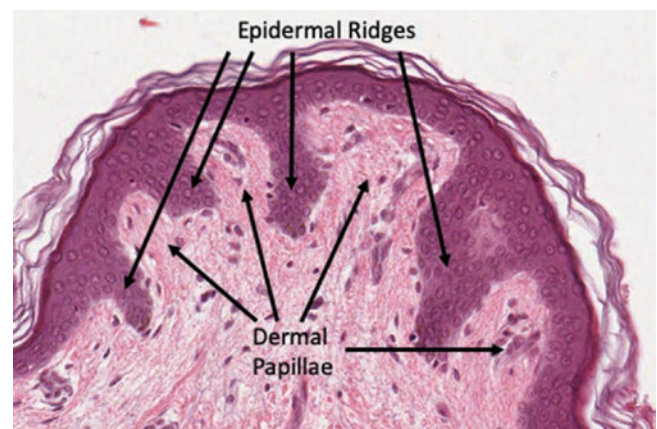
*Merkel's cells* are sensory cells within the epidermis that respond to touch/pressure. They are discussed in more detail below.

## Dermis

The boundary between the dermis and the overlying epidermis is characterized by upward projections of the dermis called *dermal papillae* and downward projections of the epidermis called *epidermal ridges* or *rete pegs* (see Fig. 7.4). The interdigitation of the dermal papillae and the epidermal ridges increases the surface area between these two layers of the skin providing resistance to mechanical stress. In areas of the body that are routinely exposed to high mechanical stress (e.g., palms of the hands and soles of the feet), the epidermal ridges are longer and extend deeper into the dermis increasing the length of the dermal papillae. In addition, the dermal papillae are more closely spaced. Together, this arrangement of epidermal ridges and dermal papillae confers greater resistance to mechanical stress at these sites.

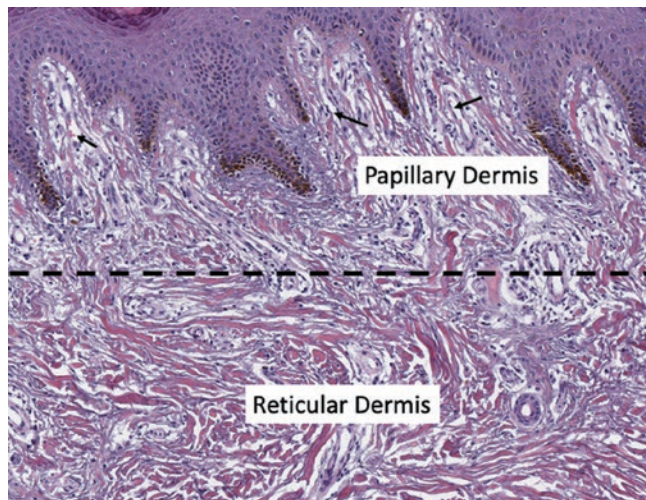
As noted above, the dermis is subdivided into two layers, a superficial layer called the papillary dermis and a deeper and thicker layer called the reticular dermis (see Fig. 7.5). The papillary dermis consists of loose connective tissue. Because the epidermis is avascular, the epidermal cells receive nutrients from the capillaries located in the papillary dermis. As a result, a large number of small blood vessels can be seen in the papillary dermis. The much thicker reticular dermis consists of dense irregular connective tissue, in which large numbers of collagen fibers (primarily Type-I collagen) are found. Both the papillary dermis and reticular dermis also contain elastic fibers. With aging, these elastic fibers are reduced in number and appear frayed. The loss of these elastic fibers contributes to the formation of "wrinkles" and sagging of the skin.

The collagen fibers and elastic fibers within the reticular dermis are arranged to form lines of tension within the skin.



**Fig. 7.4** High power view of the junction between the epidermis and dermis. The interdigitation of the epidermal ridges and the dermal papillae provides an increased surface area to better resist shear forces that could cause the epidermis to separate from the underlying dermis





**Fig. 7.5** The dashed line shows the boundary between the papillary dermis and the reticular dermis. The papillary dermis is loose connective tissue, while the reticular dermis is dense irregular connective tissue. The epidermis is avascular and receives nutrients from the blood supply of the papillary dermis (small vessels are indicated by the arrows)

These lines are called *Langer's lines*. Surgical incisions that are made parallel to the Langer's lines heal with less scarring.

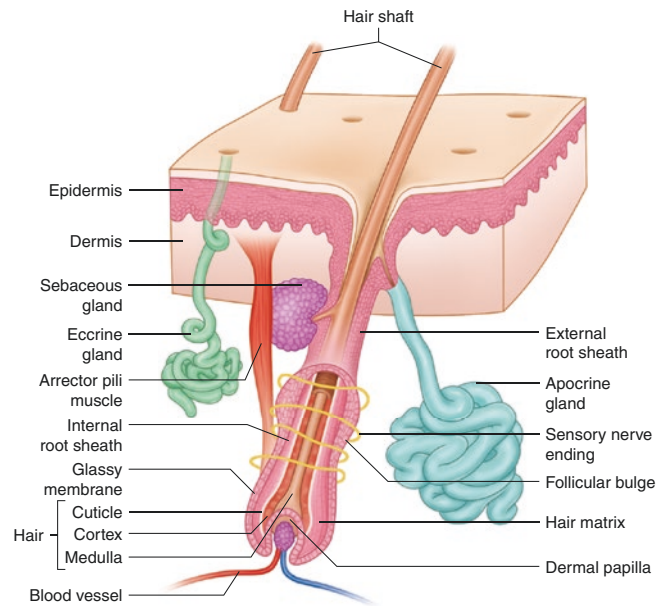
## Epidermal Derivatives

Epidermal derivatives (also called epidermal appendages) include hair follicles, eccrine sweat glands, apocrine sweat glands, sebaceous glands, and nails (*note*: nails are not discussed in this chapter). All are derived from the epidermis (see Fig. 7.6).

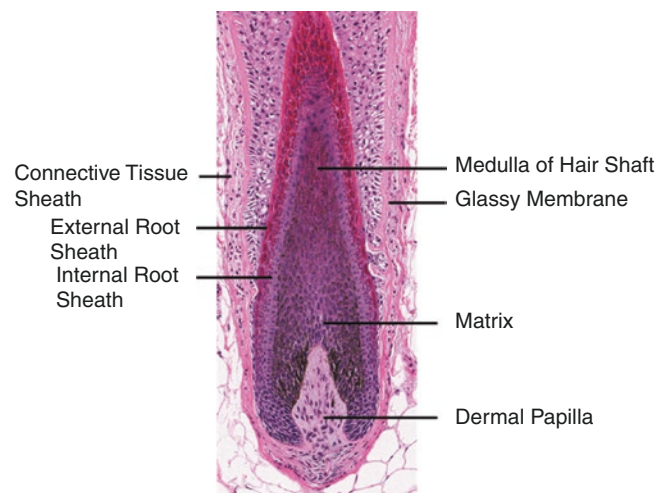
## Hair Follicles

*Hair follicles* are responsible for the production and growth of *hair*, and they are found, with a few exceptions (e.g., palms of the hands, soles of the feet, lips), over the entire body. Sebaceous glands and apocrine sweat glands are closely associated with hair follicles, and the secretions of these glands empty onto the hair shaft.

Although hair follicles are derived from the epidermis, hair growth is not continuous as seen in the epidermis, but instead is cyclical in nature. The growth phase is termed *anagen*, which is followed by a phase where growth is stopped termed *catagen*. Finally, there is a phase termed *telogen*, where the follicle atrophies and the hair is lost. The histologic structure on an anagen follicle is shown in Fig. 7.7. The follicles are found in the hypodermis near its junction with the overlying reticular dermis. The innermost portion of the



**Fig. 7.6** Schematic of the skin showing the epidermal derivatives and their relationship to one another



**Fig. 7.7** Structure of the hair follicle. The blood supply to the dermal papilla is not in the plane of section

follicle, called the *bulb*, consists of a tuft of loose connective tissue called the *dermal papilla*, and surrounding *matrix*. The dermal papilla contains blood vessels which supply the follicle. The matrix consists of stem cells and melanocytes. As cells leave the matrix, they begin the process of keratinization to form the hair shaft. The melanosomes taken up by the matrix cells determines hair color. If the melanosomes contain mostly pheomelanin, the hair will be light in color (e.g.,



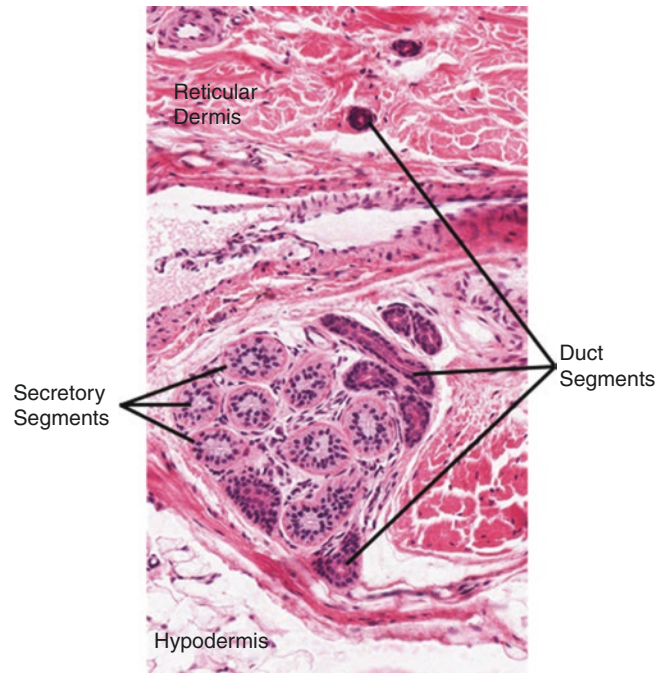
blonde or red). If the melanosomes contain mostly eumelanin, brown or black hair results. With age, the melanocytes undergo apoptosis, which leads to gray or white hair.

Above the dermal papilla is located the *follicular bulge* (see Fig. 7.6), which consists of epidermal stem cells. When the overlying epidermis is injured or lost (e.g., burns) these stem cells migrate to the surface and repair the injured area. If these follicular bulge cells are lost or destroyed, skin repair is compromised and may result in the need for skin grafting.

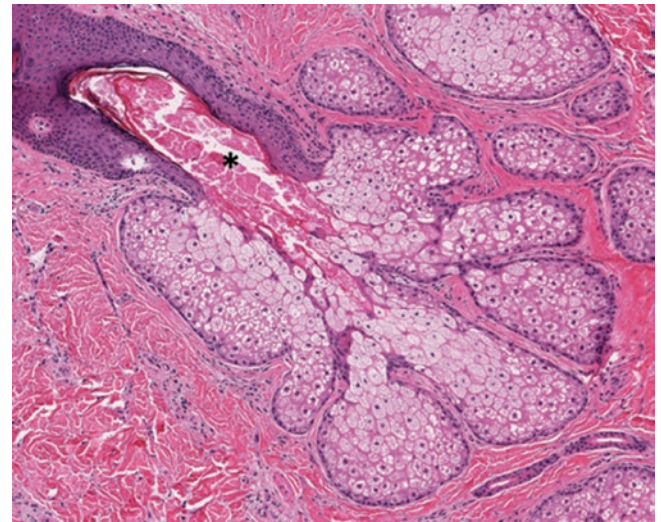
Each hair follicle has a small smooth muscle, called the *arrector pili*, that inserts near the follicular bulge and extends up into the overlying dermis (see Fig. 7.6). The arrector pili is innervated by the sympathetic branch of the autonomic nervous system. Contraction of the muscle causes the hair shaft to stand erect, and produces what is commonly referred to as “goose flesh” or “goose bumps.” In animals with fur, contraction of the arrector pili muscles creates a thicker unstirred layer of air against the animal’s skin, and thus helps to conserve body heat in a cold environment. Because of the lower density of hair on the skin of humans, contraction of the arrector pili has little or no effect on heat conservation. Nevertheless, exposure to cold will lead to arrector pili contraction.

## Eccrine Sweat Glands

*Eccrine sweat glands* are simple coiled blind-ended glands. They are not associated with hair follicles. They consist of a coiled *secretory segment*, and a duct that empties onto the surface of the skin. As shown in Fig. 7.9, the coiled *secretory segment* is located at the junction of the reticular dermis and the hypodermis. The cells of the *duct segment* contain a high concentration of mitochondria (Fig. 7.8). As a result, with light microscopy, they stain more darkly than the secretory cells. When viewed with the electron microscope, two types of cells are seen in the secretory segment. One cell contains abundant glycogen, and the apical and lateral cell plasma membranes are characterized by extensive enfoldings which increase surface area. These cells, called *clear cells*, secrete the watery portion of the sweat. The second cell type, called the *dark cell*, contains an extensive network of rough endoplasmic reticulum, and numerous secretory granules, that are exocytosed from the cell by what is termed a *merocrine* mechanism. These cells secrete the proteinaceous component of sweat. One such product of the dark cells is the antimicrobial peptide *dermcidin*, which has broad-spectrum activity against the bacteria on the surface of the skin. The cells of the secretory segment are surrounded by myoepithelial cells. These cells contract as sweat is produced which prevents the segment from “ballooning out,” and thereby causes the sweat to move up the duct to the skin’s surface.



**Fig. 7.8** Eccrine sweat gland located at the junction of the reticular dermis and hypodermis. The duct segment cells stain darker due to the high density of mitochondria. The clear dark cells of the secretory segment cannot be discerned in light micrographs



**Fig. 7.9** Sebaceous gland showing the pilosebaceous canal (\*) entering into the hair follicle

Eccrine sweat glands play a critical role in thermoregulation. They are innervated by sympathetic fibers of the autonomic nervous system. However, sympathetic postganglionic fibers release acetylcholine rather than norepinephrine. When stimulated the secretory segment produces primary sweat, which has a fluid and electrolyte composition similar to that of extracellular fluid. As primary sweat travels through the duct segment, NaCl is reabsorbed, and as a result, the

sweat that appears on the surface of the skin is hypotonic with respect to that of the extracellular fluid. Both the *epithelial Na<sup>+</sup> channel (ENaC)*, and the *cystic fibrosis transmembrane regulator (CFTR)* are expressed by the ductal cells and are responsible for the reabsorption of Na<sup>+</sup> and Cl<sup>-</sup> respectively. In individuals with cystic fibrosis, Cl<sup>-</sup> reabsorption by the ductal cells is impaired. As a result, the [Cl<sup>-</sup>] of the sweat is elevated above its normal level of equal to or less than 30 mEq/L. This elevated sweat [Cl<sup>-</sup>] is the basis for the “sweat test” for the diagnosis of the disease. When exposed to a warm/hot environment, the reabsorption of NaCl by the ductal cells increases resulting in a more hypotonic sweat. This acclimatization results from increased expression of ENaC secondary to the actions of aldosterone. This allows thermoregulatory sweating to occur without an excessive loss of NaCl.

## Apocrine Sweat Glands

*Apocrine sweat glands* share some features found in eccrine sweat glands, but also have a number of important differences. For example, the distribution of apocrine sweat glands is limited to certain regions of the body, such as the axilla, the areola, and nipple of the breast, the skin around the anus and the genitalia, and the eye lashes (*glands of Moll*). Similar to the eccrine sweat glands, the apocrine sweat glands are coiled tubular glands with the secretory segment located near the junction of the reticular dermis and hypodermis. In contrast to the eccrine sweat glands, the apocrine sweat glands empty their secretion onto the hair shaft (see Fig. 7.6). Prior to puberty, the apocrine sweat glands are inactive. With the onset of puberty, and then throughout adulthood, the apocrine sweat glands produce a secretion that contains proteins, carbohydrates, lipids, and a host of organic molecules (e.g., urea). The secretion is odorless, but when acted upon by bacteria on the skin, it can produce an unpleasant odor. In many mammals, the apocrine sweat glands produce pheromones. They may serve the same function in humans.

It was originally thought that secretion was by an apocrine process (i.e., release of the secretory product of the glandular cells occurred with the release of a small portion of the cells cytoplasm). However, it is now known that the eccrine sweat glands, like the apocrine sweat glands, secrete by a merocrine process. Although misnamed, the term apocrine sweat gland has persisted. The secretions of the gland are not altered by the duct segment, as is the case for eccrine sweat glands. The duct segment of apocrine sweat glands simply conducts the secretion to the hair follicle. Typically, the duct enters the follicle near to, but slightly above, where the sebaceous glands attach to the follicle.

The apocrine sweat glands are not involved in thermoregulation. Instead, they respond to emotional and sensory stimuli. They are innervated by sympathetic fibers of the autonomic

nervous system, and norepinephrine is the neurotransmitter of the postganglionic neurons. This is in contrast to the eccrine sweat glands where the sympathetic postganglionic neurons use acetylcholine as the neurotransmitter.

## Sebaceous Glands

*Sebaceous glands* are derived from the external root sheath. They produce an oily substance called **sebum**, the exact function of which is not completely understood, but may have bacteriostatic and/or emollient properties. Some have also suggested a pheromone role for sebum. Sebaceous gland secretion occurs by a holocrine mechanism (i.e., the cells of the gland accumulate sebum, and then release the sebum when the cell undergoes apoptosis). The sebum and associated cellular debris are released onto the hair shaft via the *pilosebaceous canal* (see Fig. 7.9). Sebaceous gland secretion increases significantly with puberty, and is a contributing factor in the development of acne.

## Innervation of the Skin

The skin is very much involved in sensation, and free nerve endings and a number of encapsulated sensory receptors are present. Figure 7.10 illustrates two encapsulated sensory receptors found in the skin: *Meissner's Corpuscle* and *Pacinian Corpuscle*.

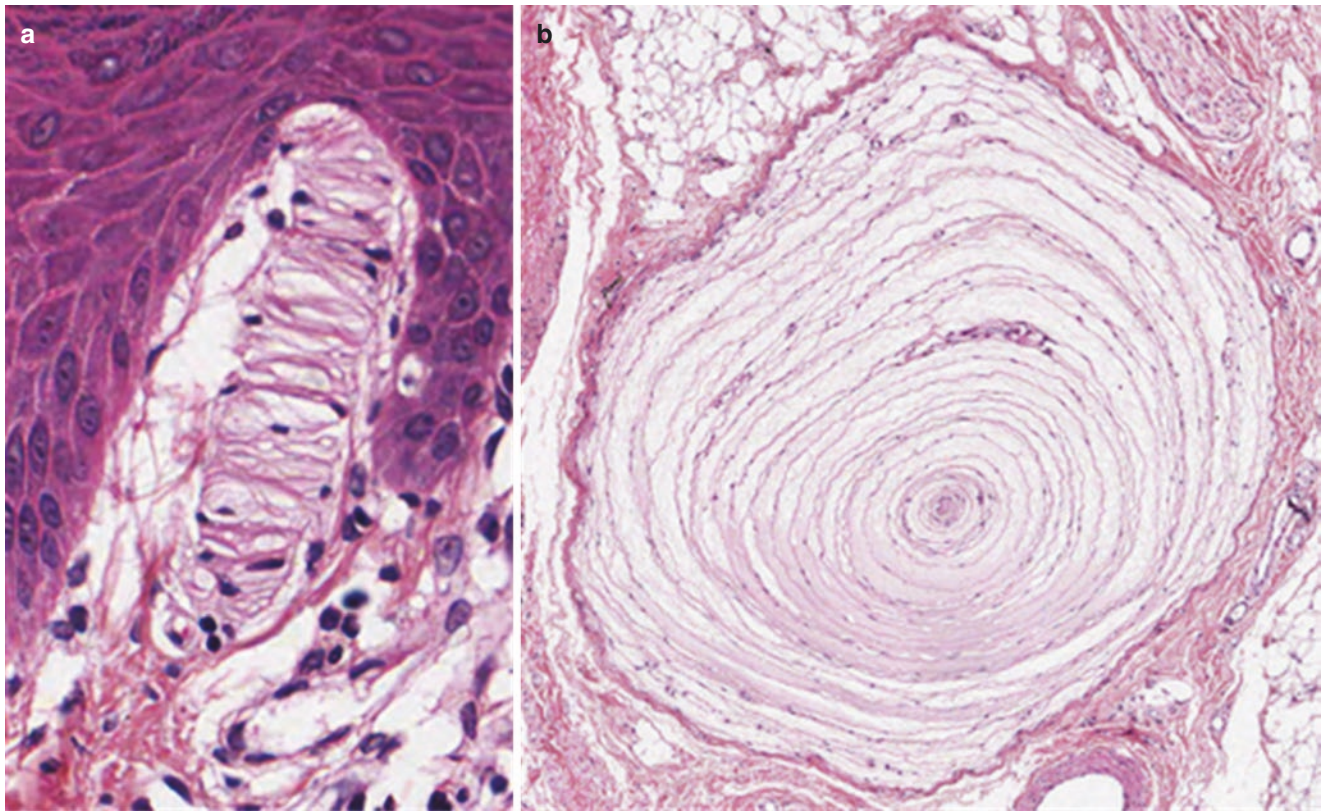
The sensory modality and the size of the receptor field vary among the various receptors found in the skin. Free nerve endings and Merkel's cells are nonencapsulated and located in the epidermis. All other receptors are encapsulated and located at various depths within the dermis. In general, the deeper the receptor is within the dermis, the larger its receptor field. Table 7.1 summarizes the sensory receptors found in the skin, their sensory modality, and the size of their receptor field.

## Tissue Layers of the Scalp

The scalp is typically formed of five layers. The outer three layers are connected tightly to each other and move together, allowing the furrowing of the forehead. The first letter of each layer forms the word SCALP.

1. Skin: This layer is composed of thin skin containing abundant sweat and sebaceous glands, and hair shafts.
2. Connective Tissue: Contains the hair follicles, subcutaneous nerves, and a rich vascular supply.
3. Aponeurosis (Galea): Thick, strong sheet of connective tissue connecting the two bellies of the occipitofrontalis muscle (described later in muscles of facial expression).





**Fig. 7.10** Encapsulated sensory receptors found in the dermis of the skin. (a) Meissner's corpuscles are found just beneath the epidermis in dermal papillae of the papillary dermis. (b) Pacinian corpuscles are located deep in the dermis

**Table 7.1** Receptors found in the skin

Receptor	Sensory modality	Receptor field size
Free nerve ending	Pain, heat, cold and light touch	Small
Merkel's cell	touch and pressure	Small
Meissner's corpuscle	Change in pressure	Small
Pacinian corpuscle	Vibration	Large
Ruffini's corpuscle	Stretch and torque	Large
Krause's end bulb	Cold	Large

4. Loose Connective Tissue: Contains potential spaces where fluid (blood, pus) may accumulate.
5. Periosteum of the Skull: Dense connective tissue layer covering the bones of the skull.

## Changes in Aging Skin

Aging is a complicated process that affects the epidermis, the underlying dermis, and the epidermal appendages. These changes can be accelerated by UV radiation or solar light exposure (photoaging). These changes may manifest as sagging, wrinkling skin, changes in pigmentation (freckles and

depigmentation), and formation of skin lesions including cutaneous cancers.

Within the dermis, there is a decrease in collagen and normal elastic fibers. In normal aging skin, there is a decreased production of Type I collagen. However, with photoaging, the cross-linking between collagen molecules is altered, resulting in unstable collagen fibers which are subject to increased degradation. Also, the elastic fibers appear abnormally thick, frayed, and may be nonfunctional. The number and diameter of the elastic fibers in the papillary dermis decrease. However, the elastic fibers in the reticular dermis thicken and appear coarse and matted. The extracellular matrix of the connective tissue is also affected, triggering increased secretion of elastases and proteases. The dermis overall becomes thinner.

The junction between the epidermis and dermis also changes with age. The dermis–epidermis junction becomes flattened, with a decrease in the length of the dermal projections. This may also contribute to the increased fragility of aging skin. There is also a decrease in the density of the blood vessels in the papillary dermis, directly underlying the epidermis.

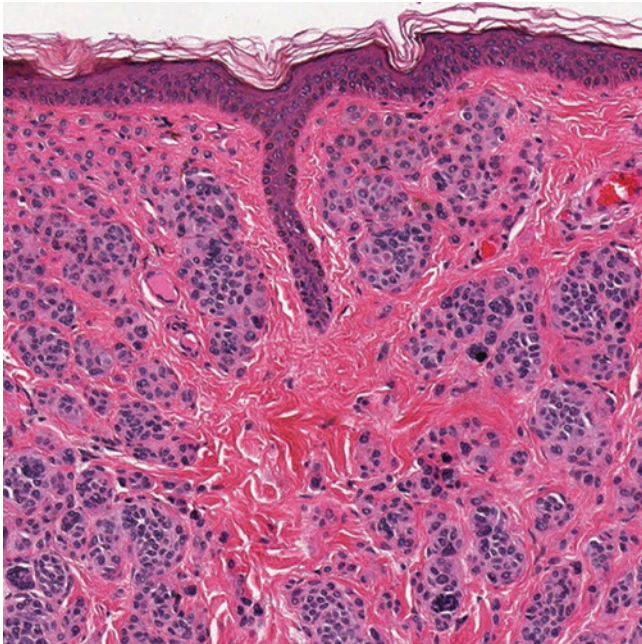
Within the epidermis, the density of melanocytes and Langerhans cells decreases.

The number of sebaceous glands, sweat glands, and hair follicles decreases, and they can become altered structurally.

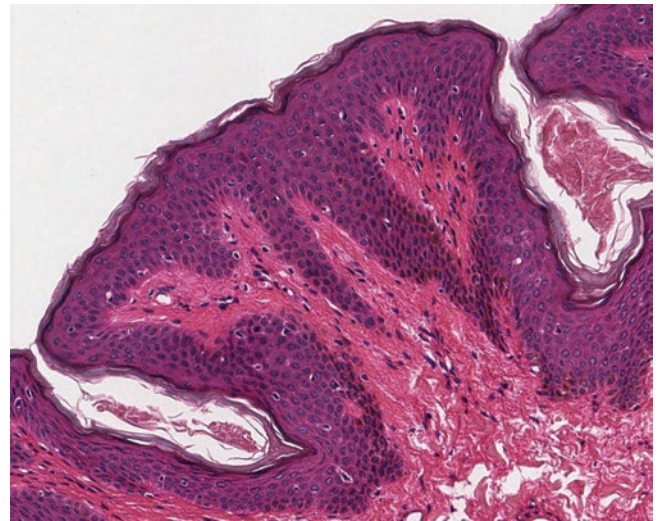
## Benign Neoplasms

There are a number of benign and malignant neoplasms that occur within the skin. Two very common benign neoplasms are presented here.

*Melanocytic nevi*, more commonly called “moles,” can be found in all regions of the skin. The *neval cells* differ from melanocytes in that they lack the dendritic cell processes characteristic of melanocytes (see above). They also contain large pigment granules. Early on, the neval cells are aggregated along the epidermal/dermal junction. This is called a *junctional nevus* and appears as a flat pigmented lesion on the skin. Over time, neval cells penetrate into the dermis resulting in a raised pigmented lesion called a *compound nevus*. Figure 7.11 is a histologic section of a compound melanocytic nevus. As the neval cells penetrate deeper into the dermis, they become small in size and produce little or no pigment. While nevi can give rise to melanomas, this is rare. One of the reasons for this is that the



**Fig. 7.11** Compound melanocytic nevus. Note the numerous clusters of darkly staining neval cells throughout the dermis



**Fig. 7.12** Acrochordon. Note the fibrovascular core with overlying normal epidermis

growth of the neval cell becomes arrested, a process termed oncogene-induced senescence, which involves the accumulation within the cells of a potent inhibitor of cyclin-dependent kinases.

*Acrochordons*, more commonly called “skin tags,” occur over time, and are typically found in skin creases and where the continuous rubbing or abrasion of the skin occurs. On the face, acrochordons are frequently found on the eyelids. Although continuous abrasion of the skin appears to be the primary cause for the formation of acrochordons, there is some evidence that human papilloma virus may play a role as well. They are more common in women suggesting a genetic component too. They consist of a fibrovascular core with a normal appearing overlying epidermis (see Fig. 7.12). They are frequently removed for cosmetic reasons.



# Anatomy of the Periorbital Region

# 8

Christine E. Niekrash

## Superficial Anatomy of the Periorbital Region

The eyelids cover the eye to protect it from injury and excessive light, and to keep the eyeball moist by distributing the lacrimal fluid through blinking. Very thin skin covers the external surfaces of the eyelids. Their internal surfaces are covered with the mucosal palpebral conjunctiva.

The eyeball is covered by a dense connective tissue coat, the sclera, which is white except for its transparent anterior one-sixth, the cornea. The colored iris with the pupil in its center is visible through the cornea.

The upper and lower lids (palpebrae) meet at the medial and lateral palpebral commissures and are separated by the palpebral fissure (Fig. 8.1). They are separated from the eyeball by the conjunctival sacs. The upper and lower depths of these sacs are the fornices. The lacrimal lake separates the sclera from the medial commissure. The lacrimal caruncle is a sweat and sebaceous gland protrusion within the lacrimal lake.

A tear film covers the eye and protects the cornea and conjunctiva from drying. The lacrimal gland is located in the lateral, superior bony orbit (Fig. 8.2). The tears spread medially across the eye and drain through lacrimal puncta to the lacrimal sac, and through the naso lacrimal duct to the inferior meatus of the nasal cavity.

Eyelashes are hairs on the free surface of the eyelids. In the medial commissure is the triangular lacus lacrimalis containing a reddish, raised area, the caruncle.

The *tarsal glands* (of Meibom) within the eyelids secrete a lipid to lubricate the eyelids to keep them from adhering to each other. The eyelids also contain dense connective tissue plates, the *tarsi*, and are surrounded by several fat pads. Ciliary glands are modified sebaceous glands associated with the eyelashes.

The anatomy of the eyeball is beyond the scope of this book.

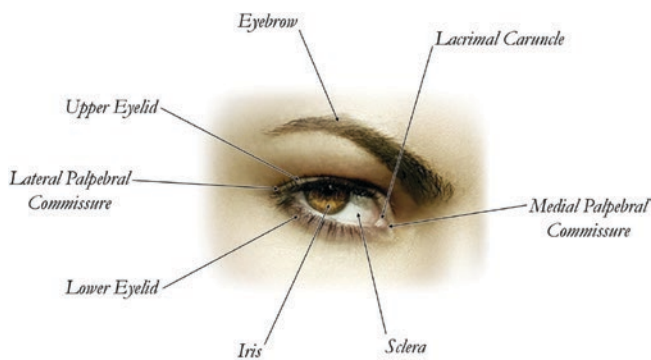
## Osteology of the Orbit

The anterior margin of the orbit is formed by the frontal bone above, the zygoma laterally and below, and the maxilla below and medially. In the medial third of the superior margin is the supraorbital notch or foramen for the supraorbital artery and nerve. Below the middle third of the inferior margin is the infraorbital foramen for the infraorbital nerve and artery.

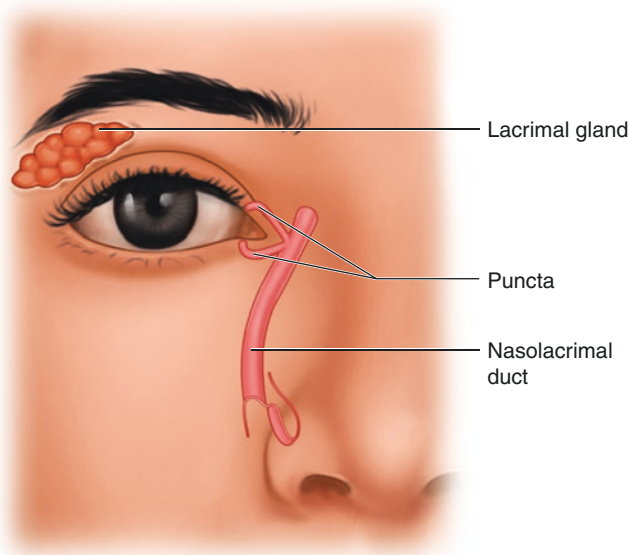
The walls of the orbit are formed by a number of bones (Fig. 8.3). Its roof is the orbital surface of the frontal bone. Laterally, just inside the orbital margin is a shallow fossa for the lacrimal gland. The lateral wall is formed by the greater wing of the sphenoid bone and the orbital surface of the zygoma. Here, the zygomatic foramen forms the entrance to the zygomatic canal which bifurcates to end as the zygomaticofacial foramen on the lateral surface of the zygoma and the zygomaticotemporal foramen on the posterior surface of the zygoma facing the temporal fossa. These foramina transmit sensory nerves with the same names. The superior and lateral walls of the orbit are separated posteriorly by the superior orbital fissure (Fig. 8.4). This fissure transmits the ophthalmic, oculomotor, trochlear, and abducens nerves (Appendices 3 and 4) as well as the superior ophthalmic vein that communicates with the cavernous sinus.

The lateral wall and floor of the orbit are separated by the inferior orbital fissure which transmits the infraorbital branch of the maxillary division of the trigeminal nerve, the infraorbital branch of the maxillary artery, and the inferior ophthalmic vein which communicates with the pterygoid plexus. The floor of the orbit is formed by the orbital surface of the maxilla. Within this surface is an infraorbital groove and canal which transmit the infraorbital nerve and vessels.

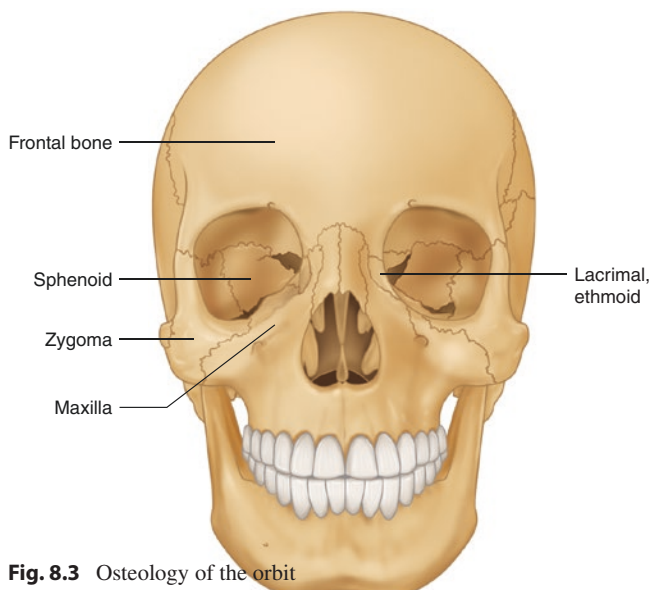
C. E. Niekrash (✉)  
Frank H. Netter MD School of Medicine, Quinnipiac University,  
Hamden, CT, USA  
e-mail: [christine.niekrash@quinnipiac.edu](mailto:christine.niekrash@quinnipiac.edu)



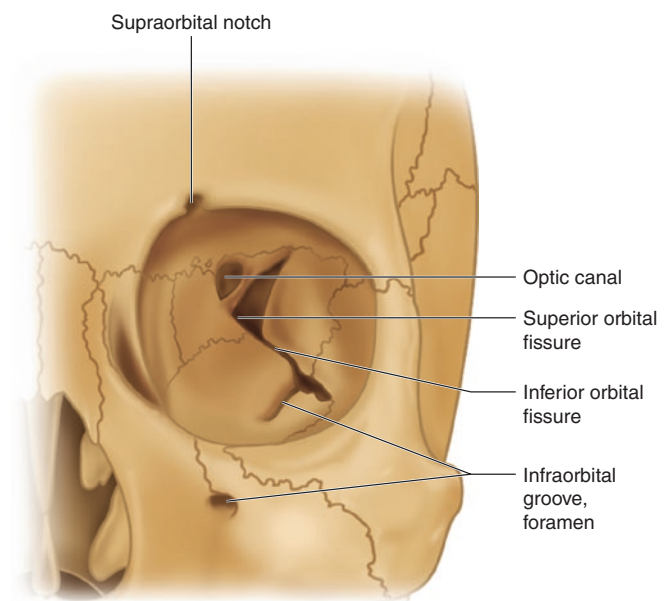
**Fig. 8.1** Superficial anatomy of the orbit



**Fig. 8.2** The lacrimal apparatus for production and drainage of lacrimal fluid



**Fig. 8.3** Osteology of the orbit



**Fig. 8.4** Openings through the bones of the orbit

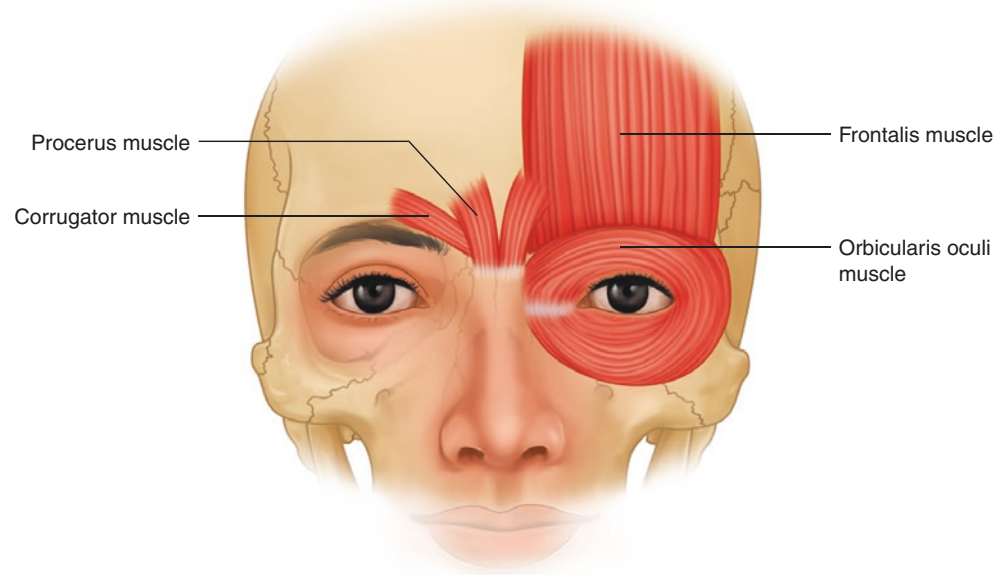
The medial wall is formed by the ethmoid, lacrimal, and frontal bones. The surfaces of the ethmoid and frontal bones are translucent because of the presence of air cells within them. The lacrimal bone is oriented vertically in front of the ethmoid bone. A posterior lacrimal crest can be identified on the lacrimal bone and an anterior lacrimal crest on the frontal process of the maxilla. Between the crests is the lacrimal fossa for the lacrimal sac. The nasolacrimal canal extends inferiorly from the fossa to the nasal cavity. It transmits the nasolacrimal duct. In or just above the suture between the ethmoid and frontal bones are anterior and posterior ethmoidal foramina. They are passageways for branches of the nasociliary nerve with the same names as the foramina. At the anterior and superior aspect of the frontal bone on the medial wall is a rough area for the attachment of the trochlea of the superior oblique muscle. The apex of the orbit is formed by the lesser wing of the sphenoid bone and contains the optic canal or foramen that transmits the optic nerve and the ophthalmic artery.

## The Musculature of the Periorbital Region and the Orbit

### Muscles of the Glabellar Region (Fig. 8.5)

*Orbicularis Oculi*: Surrounds the eye. It receives its motor innervation from the temporal and zygomatic branches of the facial nerve (CN VII). This muscle is divided into orbital and palpebral portions. The orbital segment completely encircles the eye in a series of loops, extending outward into the forehead, temple, and cheek. When it contracts, it closes the eye forcefully as in a winking movement. The palpebral portion

**Fig. 8.5** Muscles of the glabellar region



of the orbicularis oculi spreads over the eyelids. When it contracts, it results in a gentle closing of the eye, as in a blinking movement.

The *Frontalis* muscle belly of the occipitofrontalis muscle is a large fan-shaped muscle that inserts into the orbicularis oculi muscle, with a bifurcation in the midline. When it contracts, it elevates the brow. Injecting neurotoxin into this muscle near the orbital rim can result in ptosis due to the dispersal of the agent to the underlying levator palpebrae muscle described below.

*Procerus* arises from the nasal bones and inserts into skin above the glabella. When it contracts, it depresses the medial eyebrow and creates horizontal lines between the eyebrows.

The *Corrugator Supercilii* muscle arises medially from the nasofrontal suture. Its fibers course laterally and superficially to insert into the skin above the superciliary arch. Its contractions pull the eyebrow medially and inferiorly to form vertical lines between the eyebrows.

## Muscles of the Orbit

The *muscles of the orbit* consist of the levator palpebrae (superioris) and the six muscles moving the eyeball: four recti and two obliques. The levator palpebrae, superior rectus, medial rectus, inferior rectus, and inferior oblique are all supplied by the oculomotor nerve. The lateral rectus is supplied by the abducens nerve and the superior oblique by the trochlear nerve (Appendices 3 and 4). These muscles move the eyeball and elevate the upper eyelid.

### *Levator Palpebrae*

- Arises from the inferior surface of the lesser wing of the sphenoid bone above the origin of the other muscles
- Inserts on skin, connective tissue, and conjunctiva of upper lid
- Elevates eyelid

### *Superior, Medial, Lateral, Inferior Recti*

- Arise from the fibrous cuff surrounding the orifice of the optic canal.
- Insert by aponeuroses into sclera of the eye less than a centimeter behind the junction of cornea and sclera.
- Lateral rectus origin is by two heads between which the oculomotor, nasociliary, and abducens nerves enter the orbit.

### *Superior Oblique*

- Arises from the fibrous cuff and adjacent bone
- Passes forward along the junction of medial and superior margins of the orbit
- Becomes tendinous and passes through trochlea
- Inserts into superior, lateral, posterior quadrant of the eyeball, behind its vertical equator

### *Inferior Oblique*

- Arises from the floor of the orbit lateral to the nasolacrimal canal
- Passes posteriorly and laterally inferior to the inferior rectus
- Inserts inferior to the superior oblique muscle



The muscles of the iris control papillary size. The pupils will constrict in response to light and will focus on a near object. Muscles of the ciliary body control the thickness of the lens. This is called accommodation and allows the eye to focus on near or distant objects.

## The Vasculature

The *ophthalmic artery* is a branch of the internal carotid artery. It enters the orbit through the optic foramen. The ophthalmic artery sends a small branch through the optic nerve to the retina (*central artery* of the retina) and a number of small branches that follow the optic nerve to the posterior surface of the eye. As it enters the orbit, the ophthalmic artery is inferior to the optic nerve. It then curves around the lateral surface of the nerve and crosses it superiorly. While on the lateral surface of the optic nerve, it gives off a *lacrimal branch* that follows the lateral border of the superior rectus muscle to the lacrimal gland. After crossing the optic nerve superiorly, it gives off a *supraorbital branch* that emerges from under the cover of the muscles above the eye and accompanies the supraorbital nerve through the supraorbital foramen or notch. It enters the forehead through the corrugator muscle, dividing into superficial and deep branches. The vertical and brow branches are superficial. This artery anastomoses with the supratrochlear, dorsal nasal, angular, and frontal branch of the superficial temporal arteries which arise from the external carotid artery (Appendix 2), forming a vascular arcade. The trunk of the artery passes anteriorly, lateral to the superior oblique muscle, ending as the *supratrochlear artery*. In its course, it sends *anterior* and *posterior ethmoidal branches* through the foramina with the same

names. The supratrochlear artery exits the orbit and courses onto the forehead, crossing the supraorbital rim often at a prominent glabellar frown line, the junction between the medial end of the corrugator muscle and the procerus muscle.

The dorsal nasal artery is another branch of the ophthalmic artery. It descends along the lateral border of the nose and anastomoses with the angular artery (the terminal branch of the facial artery which ascends along the side of the nose).

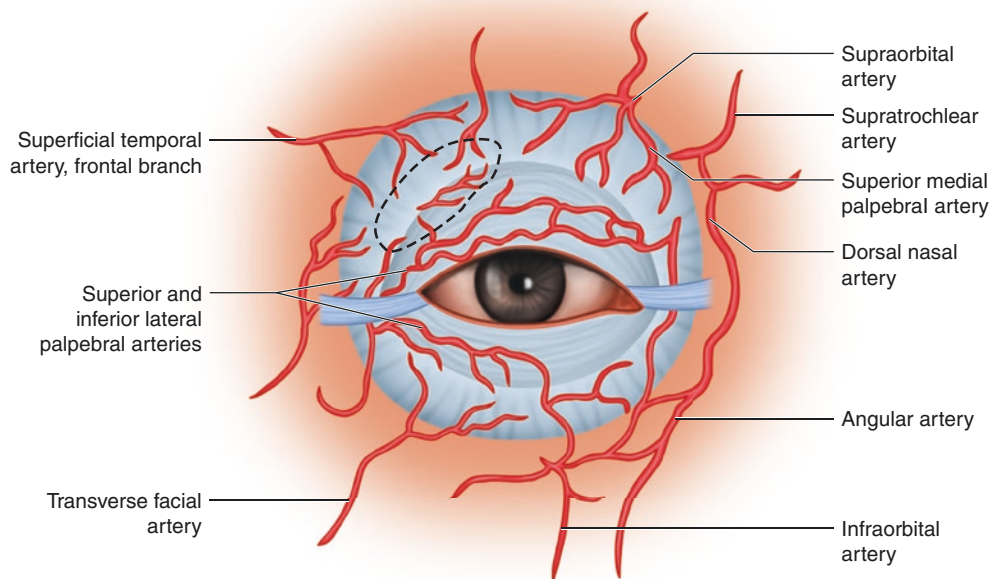
The superficial temporal artery is the terminal branch of the external carotid artery. It courses superiorly onto the scalp above the auricle, branching into frontal and parietal branches. These arteries are superficial to the frontalis muscle and can often be visualized in life. The transverse facial artery is a branch from the superficial temporal artery. It crosses superficial to the masseter muscle between the parotid duct and the zygomatic arch.

Because of the myriad of arterial anastomoses in this region (Figs. 8.6 and 8.7), retrograde injection of materials (such as cosmetic fillers) into the supraorbital artery, supratrochlear artery, or superficial temporal artery can lead to obstruction of the ophthalmic artery or its central artery to the retina, which could result in blindness.

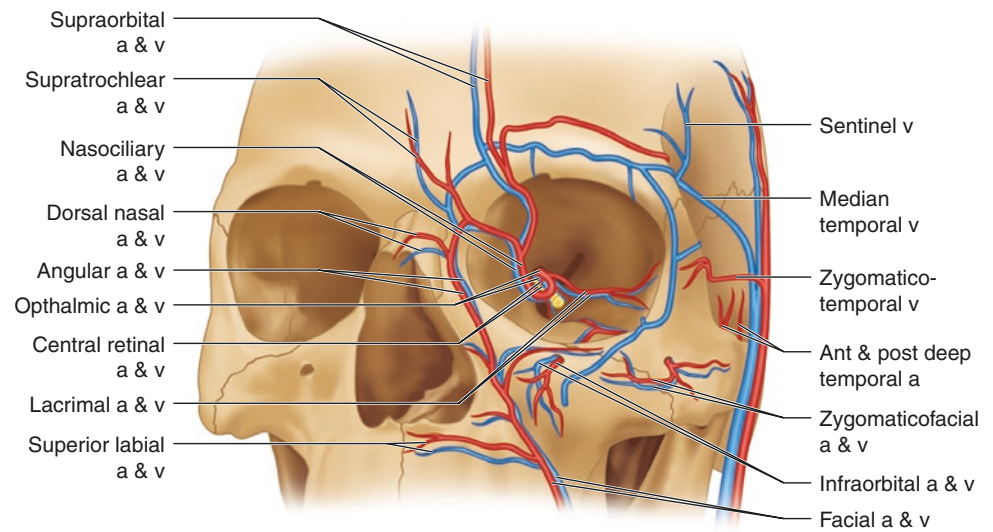
In addition, abundant anastomoses between dorsal nasal artery (from ophthalmic artery), angular artery, and lateral nasal artery (from facial artery) can lead to retrograde embolism (brain infarct) as illustrated in Fig. 8.8. For further details, see Appendix 2 and Chap. 20, Anatomy of the Nose and Paranasal Sinuses.

The *ophthalmic veins* communicate with the *facial vein* by way of the *supraorbital vein* and through the superior orbital fissure with the *cavernous sinus*. They also communicate with the *pterygoid venous plexus* surrounding the lateral

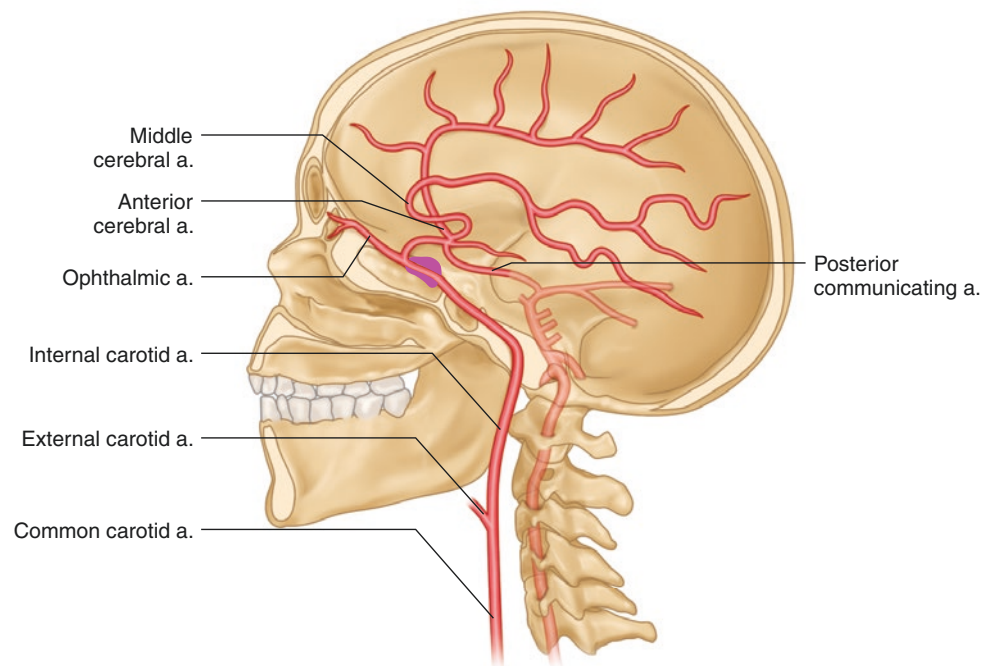
**Fig. 8.6** Arcades of anastomosing arteries supply a rich blood supply to the periorbital region and the eyelids. These are branches that originate from the internal and the external carotid arteries



**Fig. 8.7** Anastomosing arteries and veins supplying the periorbital region



**Fig. 8.8** Route of ophthalmic artery occlusion (blindness) and to possible brain infarction by embolic materials



pterygoid muscle through the inferior orbital fissure. The venous pattern generally mimics the distribution of arteries, but allow for retrograde flow into the cranium.

## The Innervation

*The Optic Nerve (CN II):* Exits the posterior surface of the eyeball (globe) and exits the orbit through the optic canal (with the ophthalmic artery). It receives its blood supply from small branches from the ophthalmic artery.

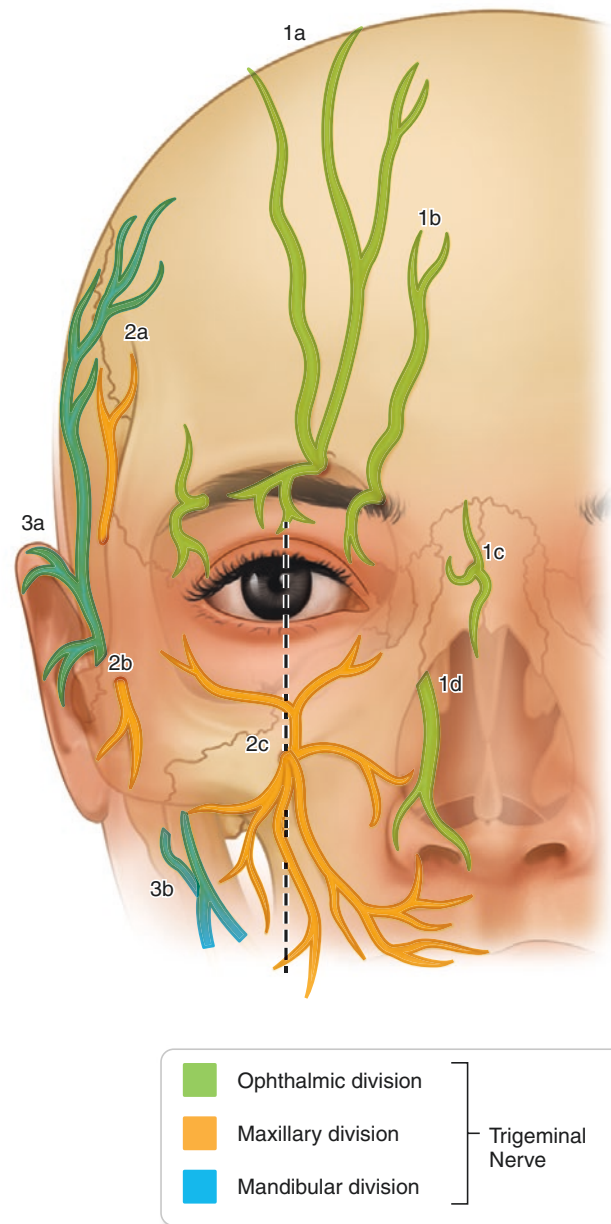
## Sensory Innervation (Fig. 8.9)

The entire course of the *ophthalmic division* of the trigeminal nerve is illustrated in Appendix 5. It enters the orbit through the superior orbital fissure as the frontal, lacrimal, and nasociliary nerves. The frontal nerve divides into the supraorbital and supratrochlear nerves. The supraorbital nerve exits the anterior orbit onto the forehead through the supraorbital foramen or notch to supply sensation to the medial forehead. The supratrochlear nerve leaves the orbit medial to the supraorbital nerve to supply the glabella, the medial upper eyelid, and conjunctiva.

The lacrimal nerve supplies the lacrimal gland and the lateral conjunctiva and lateral upper eyelid.

The nasociliary nerve provides ciliary nerve branches which are sensory to the iris, cornea, and ciliary body. These fibers are important for the initiation of the protective blink reflex. It also sends anterior and posterior ethmoidal branches to the lateral nasal wall, nasal septum, the middle and inferior concha, and the tip of the nose. Parasympathetic fibers traveling with the nasociliary nerve synapse in the ciliary ganglion posterior to the eyeball and distribute to the ciliary and sphincter pupillae muscles.

The trunk of the *maxillary division* of the trigeminal nerve enters the orbit through the inferior orbital fissure, travels on the floor of the orbit in the infraorbital groove, into the infraorbital canal, exiting on the face as the infraorbital nerve. During this course, it gives off branches to the maxillary sinus, maxillary teeth, and facial gingiva. The infraorbital nerve branches into the inferior palpebral nerve which supplies the lower eyelid, the nasal branch which innervates the lateral nose, and the superior labial branch to supply the upper lip.



**Fig. 8.9** Superficial sensory innervation of the face

## Motor Nerves

The facial nerve (CN VII) is described in Appendix 6. The main trunk of the facial nerve divides within the parotid gland. The temporal branch emerges from the parotid gland and courses superiorly over the zygomatic arch approxi-

# Anatomy of the Nose and Paranasal Sinuses

# 9

Christine E. Niekrash

## The Nose

The nose enables the passage of air between the external environment and the lower respiratory system. As air passes through the nose, it is filtered, humidified, and warmed. This is also the site of olfaction. In addition, the nose serves as a conduit for mucus and lacrimal secretions from the nasolacrimal duct and the paranasal sinuses. It consists of an external nose that projects out from the face and an internal nasal cavity that is divided into two segments by the midline nasal septum.

The bony framework of the nose (Fig. 9.1) consists of two nasal bones, the nasal process of the frontal bone and the ascending process of the maxillae. These bones outline a pyramidal shaped opening with the alveolar process of the maxilla below. The midline thickening of the convergence of the maxillary alveolar processes creates the anterior nasal spine. The nasal bones articulate superiorly with the glabella of the frontal bone. The midline depression at this junction is called nasion. The remainder of the outer framework of the nose is made of hyaline cartilage. The dorsum of the nose is covered by loosely attached skin, covering the nasal bones and superior cartilages. The skin is more tightly bound down in the alar and tip regions. This skin also contains a greater density of sebaceous glands. The paired nares are openings on the inferior surface of the nose with alae nasi that flare laterally. The skin extends into the vestibule of the nares and gives rise to hairs (vibrissae) and sebaceous glands that act with mucus to filter the air. Internal to the vibrissae, the skin becomes mucosa. The olfactory area is in the superior third of the nasal mucosa and receives special sensory innervation by the olfactory nerve (CN I).

C. E. Niekrash (✉)  
Frank H. Netter MD School of Medicine, Quinnipiac University,  
Hamden, CT, USA  
e-mail: [christine.niekrash@quinnipiac.edu](mailto:christine.niekrash@quinnipiac.edu)

## The Nasal Cartilages (Fig. 9.2)

The bilateral superior lateral nasal cartilage articulates with the nasal and maxillary bones. Its medial edge is continuous with the septal midline cartilage, but it becomes a free edge inferiorly. The bilateral alar cartilages shape the tip of the nose.

*The nasal muscles* are described in the Superficial Anatomy of the Face chapter.

## The Nasal Septum

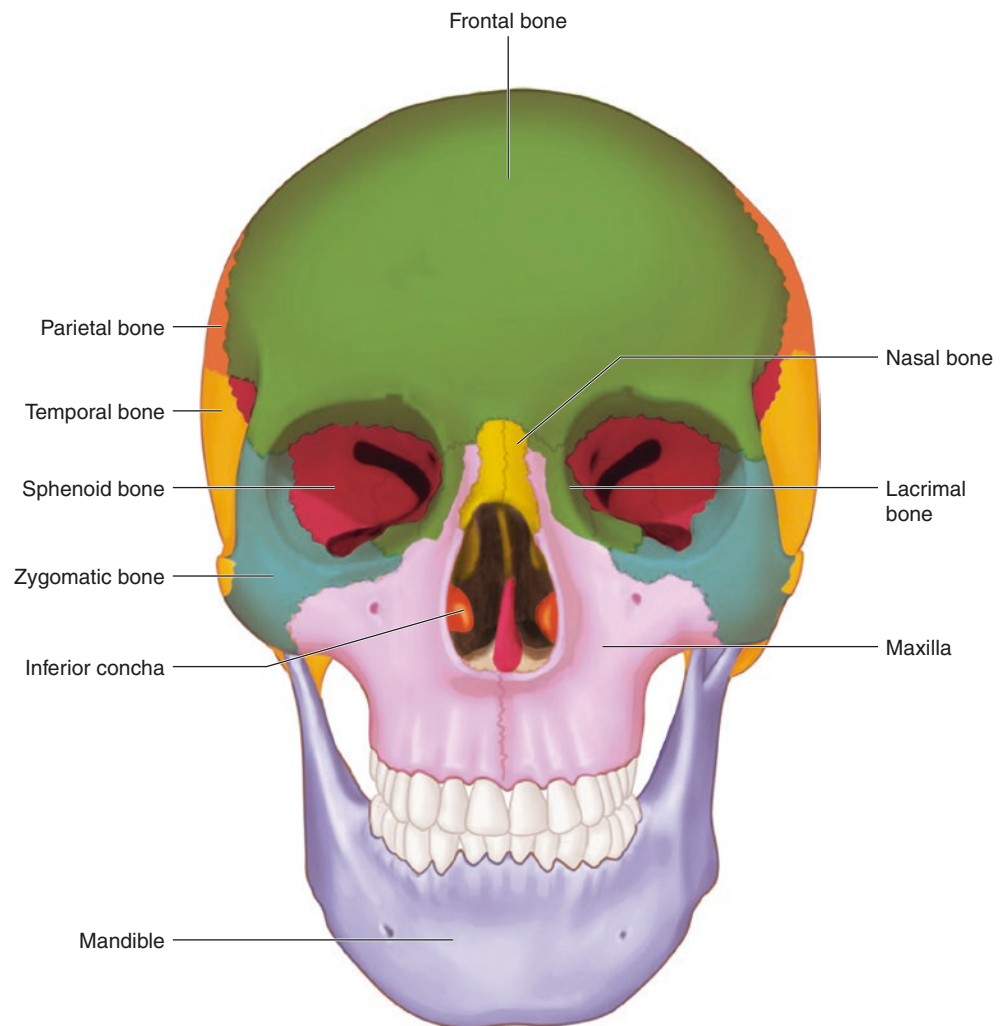
The midline nasal septum divides the internal nasal area into two nasal cavities. The major parts of the septum are the vomer bone (posteroinferior), the perpendicular plate of the ethmoid bone (superior), and the septal cartilage (anterior), as illustrated in Fig. 9.3. The nasal crests of the palatine bone and maxilla contribute to the inferior part of the septum, just below the vomer. The nasal septum is often curved or shifted from the midline.

## Nasal Cavities

The anterior entrance into the nasal cavity is through the nares into the vestibule of the nose. The choanae are the posterior openings into the nasopharynx behind the nasal cavities. The floor of the nasal cavity consists of the palatal process of the maxillary bone in the anterior and the horizontal process of the palatine bone in the posterior. The soft palate controls communication between the oropharynx and nasopharynx. The nasal septum is the medial wall. The lateral wall is composed of three (sometimes four) complex bony and membranous structures, the nasal conchae or turbinates (superior, middle, and inferior). The



**Fig. 9.1** Anterior view, bones of the skull



conchae are scroll-like projections that extend inferiorly and medially, and consist of bone covered by a mucous membrane. The superior and middle conchae are medial portions of the ethmoid bone. The superior concha is small and located anterior to the sphenoid sinus. The inferior concha (the largest) is composed of the inferior concha bone covered by a highly vascular mucosa. These vessels engorge to restrict the size of the nasal cavity and allow cycling of respiration between nostrils. Beneath and lateral to each concha is a meatus (space) with the same name as the concha that covers it. The adjacent sinuses drain into these spaces as described below in the description of the paranasal sinuses. The nasolacrimal duct drains tears from the orbit into the anterior inferior nasal meatus. The inferior concha lies approximately 1 cm anterior to the opening of the pharyngotympanic (Eustachian) tube. The roof of the nasal cavity is composed of the nasal bone and nasal spine of the frontal bone anteriorly, the cribriform plate of the ethmoid bone in the middle, and the sphenoid bone in the posterior.

## Innervation

Sensation to the skin over the root, bridge, and superior lateral surfaces of the nose is conveyed by the supratrochlear and infratrochlear branches of the ophthalmic division of the trigeminal nerve (Appendix 5, Trigeminal Nerve). Sensation to the lateral surface of the lower part of the nose is through the infraorbital nerve (Maxillary Division, Trigeminal Nerve). The external nasal branch of the anterior ethmoid nerve of the ophthalmic division of the trigeminal nerve carries sensation from the dorsal part of the nose to its tip.

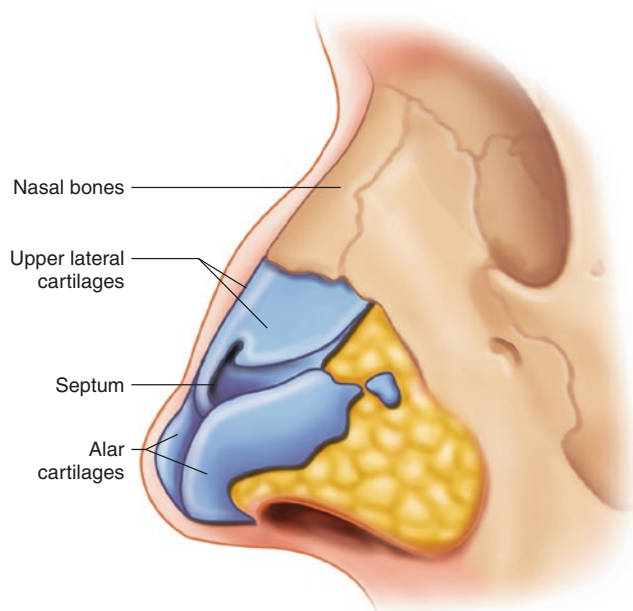
The mucosa of the posterior, inferior nasal cavity is supplied by the nasopalatine nerve of the maxillary division of the trigeminal nerve in the midline, and by the greater palatine nerve in the lateral nasal cavity. The anterior, superior nasal cavity is innervated by the anterior and posterior ethmoidal nerves (Ophthalmic Division, Trigeminal Nerve).

The olfactory nerves (CN I) are located in the superior portion of the nasal cavity. These cells pass through the cribriform plate of the ethmoid bone to synapse in the olfactory bulb.

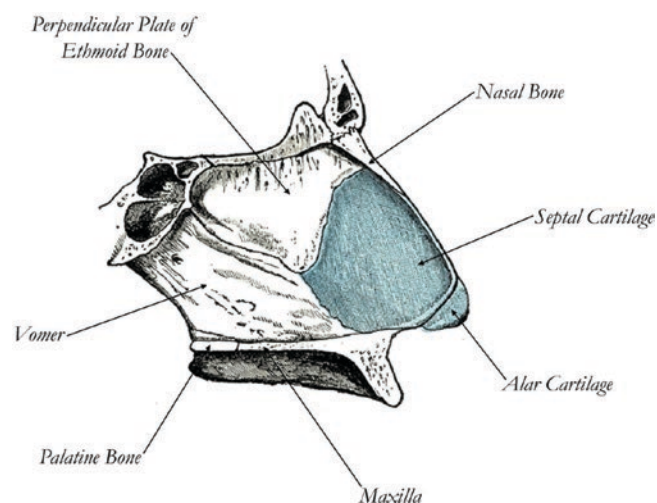
## Blood Supply of External Nose

The blood supply to the external nose is rich and anastomoses extensively (Fig. 9.4). This area is supplied by multiple branches from both the external and internal carotid arteries. The facial artery (branch of External Carotid Artery,

Appendix 2) courses diagonally and superiorly across the face from the lower border of the mandible to the side of the nose. As it ascends, it provides a superior labial branch that further branches into the septal branch to supply the inferior medial nose. The facial artery ascends on the face and provides a lateral nasal branch on the side of the nose. The facial artery then becomes the angular artery.

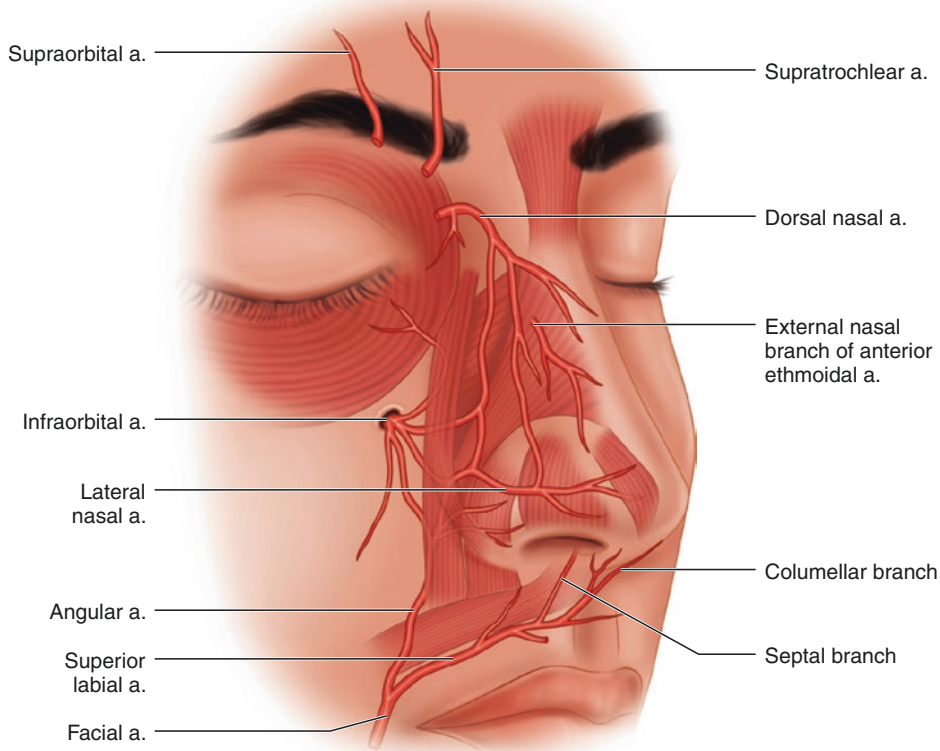


**Fig. 9.2** Cartilages of the external nose



**Fig. 9.3** Midline septum of nose

**Fig. 9.4** Arterial supply to the external nose



The external nose also receives arterial blood from the external nasal artery, the terminal branch of the anterior ethmoidal artery (from the ophthalmic artery, branch of the Internal Carotid Artery, Appendix 2). It exits onto the nose between the lateral cartilage and the nasal bone to supply the skin of the dorsal surface of the nose. The infratrochlear artery, also from the ophthalmic artery, provides arterial blood to the superior lateral nose. These extensive anastomoses with branches of the ophthalmic artery can be dangerous when injecting subdermal materials in the nasal and periorbital area. Material that occludes the ophthalmic artery or its small branch to the retina of the eye can lead to vision problems and possibly blindness.

The infraorbital artery, the terminal branch of the internal maxillary artery enters the face through the infraorbital foramen and supplies the superficial midface and the lateral surface of the nose.

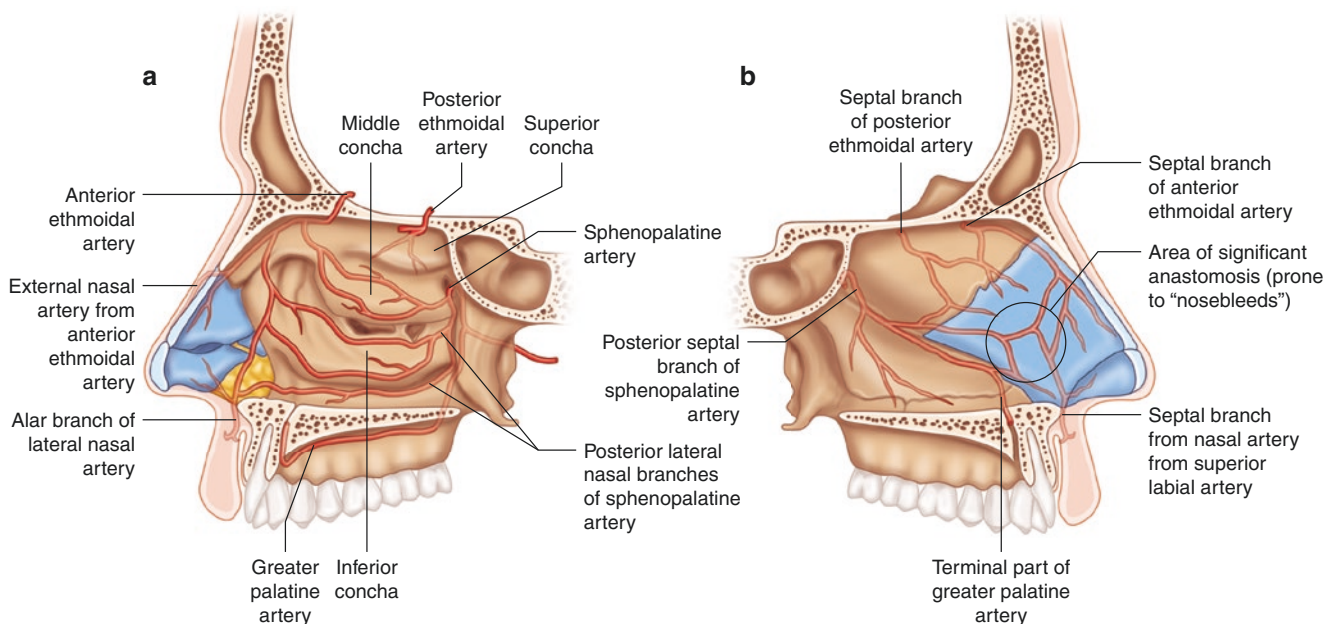
Blood from the external nose drains through the lateral and angular nasal veins to the facial vein. These veins are without valves and communicate superiorly with the ophthalmic veins which drain the cavernous sinus within the cranium. They also communicate with the infraorbital and deep facial veins and the pterygoid plexus which also connects to the cavernous sinus.

Therefore, these veins can quickly transmit infection into the cranium.

### Blood Supply of Internal Nose

The nasal cavity also has a rich vascular supply from multiple arterial sources with profuse anastomoses (Fig. 9.5). The ophthalmic artery from the internal carotid artery provides anterior and posterior ethmoidal arteries that send branches to the medial and lateral walls of the nasal cavity. The sphenopalatine artery (the terminal branch of the internal maxillary artery branch from the external carotid artery) enters the posterior nasal cavity inferior to the sphenoid sinus and provides branches to the posterior nasal septum and posterior lateral wall. Also, the septal branch of the superior labial artery of the facial artery supplies the anterior part of the nasal septum. The greater palatine artery, also from the maxillary artery, ascends into the anterior nasal cavity through the incisive foramen of the hard palate to supply the anterior, inferior part of the nasal cavity. All of these arteries anastomose in the anterior nasal septum in Kiesselbach (Little's) area and are commonly involved with epistaxis.

An extensive submucosal venous plexus drains the nasal cavity into the facial, ophthalmic, and sphenopalatine veins.



**Fig. 9.5** Vascular supply of internal nose

## Paranasal Sinuses (Fig. 9.6)

The paranasal sinuses are air-filled extensions of the nasal cavity into the frontal, ethmoid, maxillary, and sphenoid bones of the skull and face. The sinuses are named after the bone that encloses them. The sinuses vary considerably in shape and increase in size with advancing age. They are lined by a pseudostratified columnar ciliated epithelium typical of the upper respiratory tract. The cilia beat to create a direction of flow from the sinus to the nasal cavity.

### Frontal Sinus

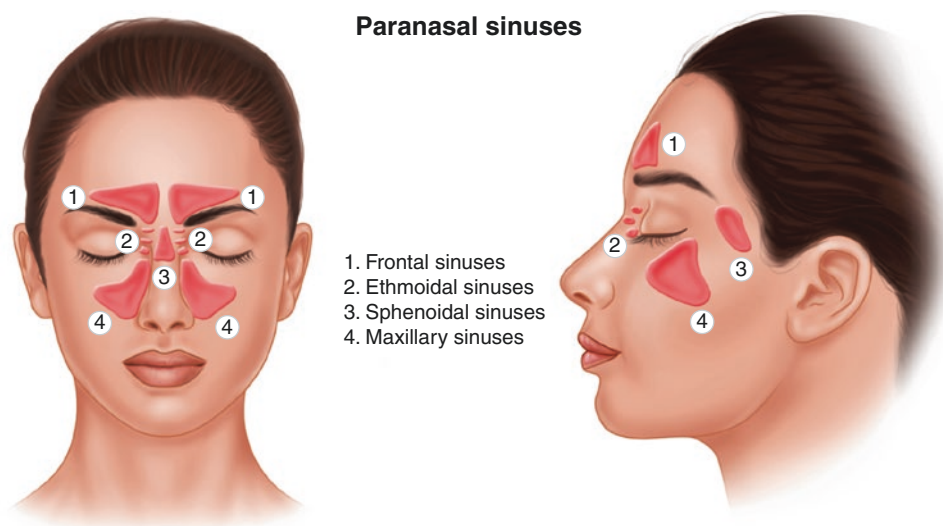
Typically, there are right and left frontal sinuses that are often unequal in size. The larger sinus may cross the midline. The sinus develops between the inner and outer cortical bony plates of the frontal bone posterior to the supraciliary arches. They are not present at birth, but develop by the age of 7 years. The frontal sinuses usually drain through the frontonasal duct into the ethmoidal infundibulum and ultimately to the semilunar hiatus, a deep groove in the middle meatus of the nasal cavity. The frontal sinus is innervated by the supraorbital nerve (from the ophthalmic division of the trigeminal nerve).

### Ethmoid Air Cells

Multiple air cells fill the ethmoid bone between the medial orbital wall and the superior lateral nasal cavity. The number of air cells that develop is highly variable and the bony walls are fragile. The air cells in the anterior and middle ethmoid bone drain into the middle nasal meatus, sometimes through the ethmoidal infundibulum. The posterior ethmoid air cells drain into the sphenoethmoidal recess in the superior aspect of the nasal cavity. These air cells are innervated by the anterior and posterior ethmoid branches of the ophthalmic division of the trigeminal nerve.

### Sphenoid Sinus

The sphenoid sinus is located posterior to the ethmoid air cells. The right and left sphenoidal sinuses are variable in appearance and are rarely symmetric in shape. They are located in the body of the sphenoid bone but can extend into other parts of the bone (the wings). The extensive pneumatization of the sphenoid bone makes it very thin and fragile. Its proximity to the optic nerve, internal carotid artery, pituitary gland, and cavernous sinus make it a dangerous area for infection. The sphenoid sinuses drain into the sphenoeth-



**Fig. 9.6** Paranasal sinuses



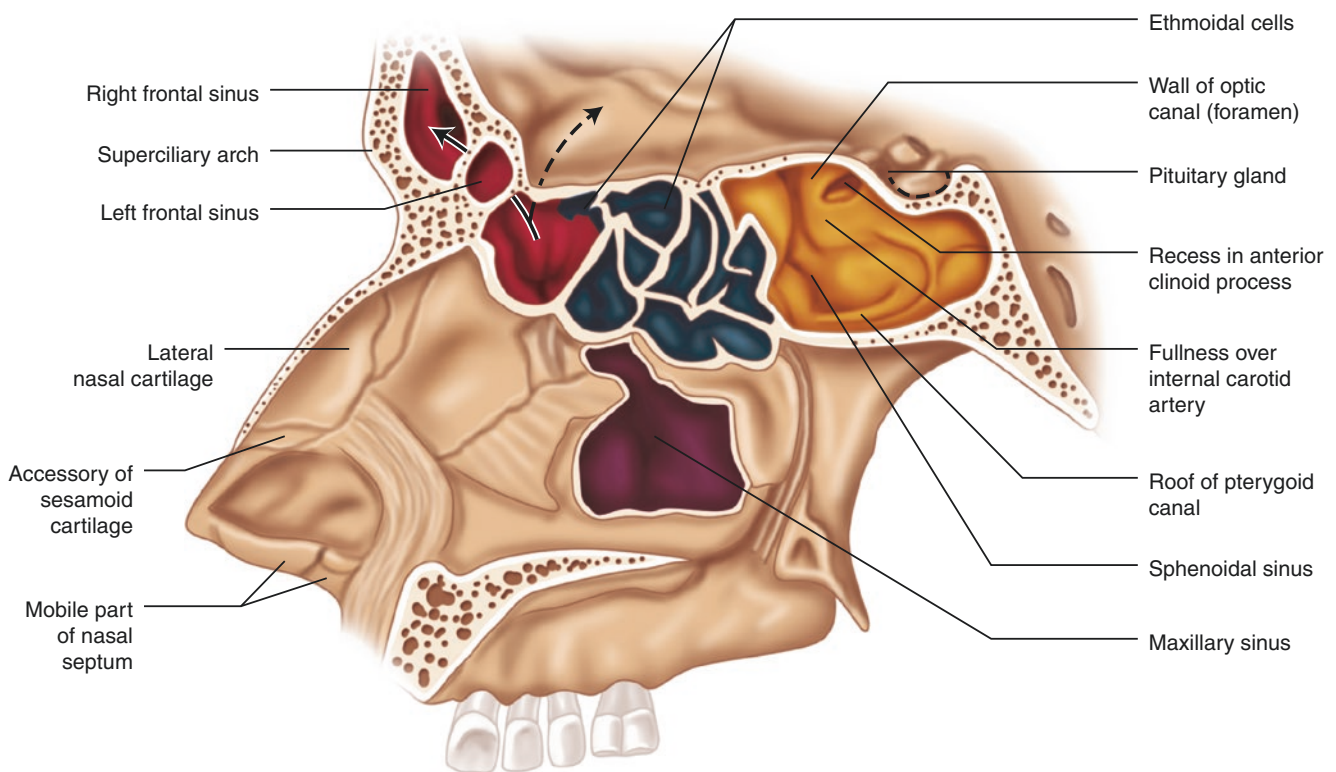
moidal recess above the superior concha of the nasal cavity. It is innervated by the posterior ethmoid nerve from the ophthalmic division of the trigeminal nerve.

## Maxillary Sinus

The maxillary sinuses are usually large and located within the body of the maxilla. Its roof consists of the floor of the orbit. The floor of the sinus is in close proximity to the roots of the maxillary teeth, particularly the canine and molars. The development of communication between the oral cavity and the maxillary sinus is a significant risk during extraction of these teeth. The maxillary sinuses drain into the hiatus

semilunaris of the middle meatus of the nasal cavity. These drains are located in the superior section of the medial sinus wall through the narrow ethmoidal infundibulum which can make sinus drainage difficult. The nasolacrimal duct is in the anterior section of the medial wall of the sinus. The infraorbital nerve (from the maxillary division of the trigeminal nerve) courses in the roof of the maxillary sinus through the infraorbital canal. As it is coursing anteriorly, the infraorbital nerve gives rise to the posterior, middle, and anterior superior alveolar nerves which course through the bony wall of the maxillary sinus to innervate the maxillary sinus and teeth.

The location of the sinuses and the proximity to each other is illustrated in Fig. 9.7.



**Fig. 9.7** Paranasal sinuses

# Anatomy of the External Ear

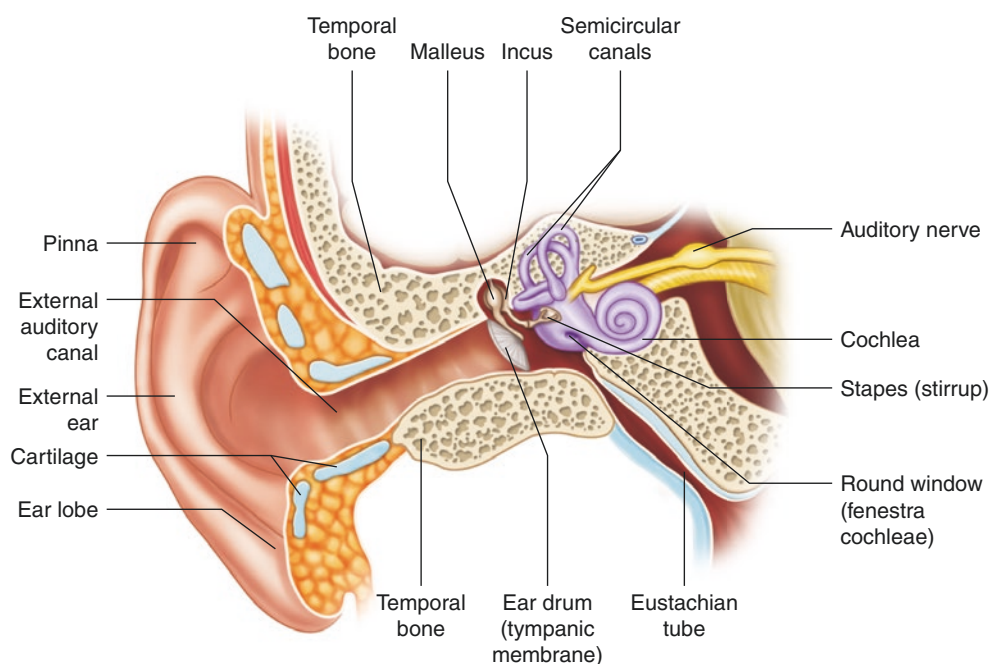
10

Christine E. Niekrash

## Overview

The ear is the organ responsible for the sense of hearing and equilibrium. It is divided anatomically into the external, middle, and internal ear (Fig. 10.1). The middle and external ear are mainly responsible for the transmission of sound to the internal ear which contains the vestibulocochlear apparatus that receives sound and maintains equilibrium. Detailed discussion of the middle and internal ear is not within the scope of this book. The external acoustic meatus is a tube through

the tympanic part of the temporal bone to connect the auricle to the middle ear. The tympanic membrane is a thin, oval-shaped structure that separates the external acoustic meatus from the middle ear. It vibrates in response to sound waves funneling through the external auditory meatus. The pharyngotympanic tube (Eustachian tube or auditory tube) connects the middle ear to the nasopharynx through an opening posterior to the inferior nasal meatus. This tube is responsible for equalizing pressure between the middle ear and the atmosphere.



**Fig. 10.1** External, middle, and inner ear

C. E. Niekrash (✉)  
 Frank H. Netter MD School of Medicine, Quinnipiac University,  
 Hamden, CT, USA  
 e-mail: [christine.niekrash@quinnipiac.edu](mailto:christine.niekrash@quinnipiac.edu)

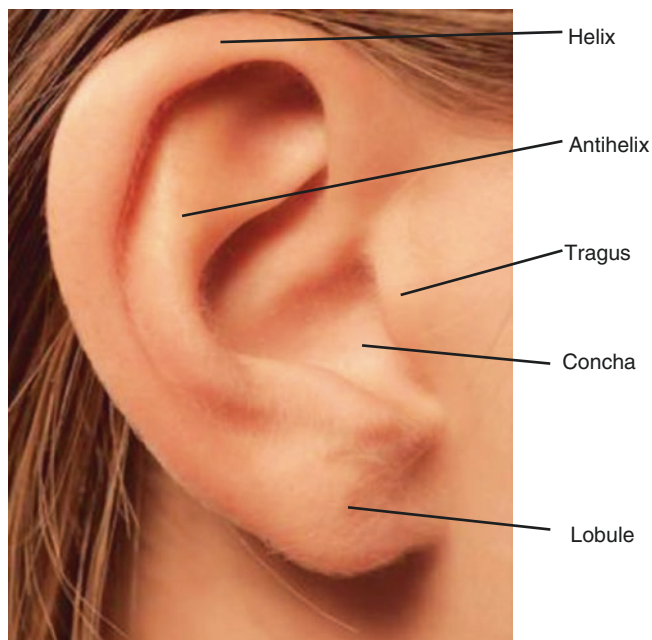
## External Ear

The external ear consists of three parts: the lateral-most structure, the auricle (pinna) which is responsible for collecting sound and directing it medially; the external acoustic meatus which transmits this collected sound; and the tympanic membrane.

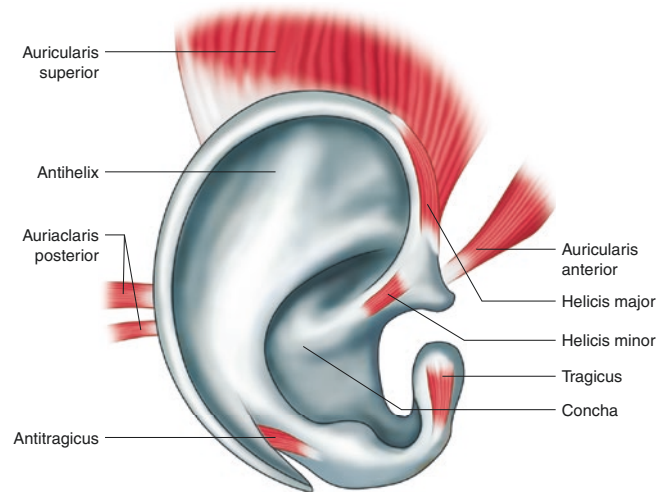
### The Auricle

The *auricle* is a complex, prominent helical structure composed of a single plate of elastic cartilage covered by perichondrium with an overlying layer of tightly bound thin skin on the lateral surface, and with more loosely bound skin with underlying adipose tissue on the medial surface. The medial surface has a rich vascular network within this layer of adipose tissue.

The auricle consists of several folds, protrusions, and depressions (Fig. 10.2). The *lobule* of the auricle consists of fibrous tissue, blood vessels, and fat and does not contain cartilage. Therefore, this lobule is a common site for piercings, but is difficult to reconstruct. The *external auditory canal* opens within the deepest depression of the lateral surface of the auricle (the *concha* of the ear). The concha is separated into two parts, the *cymba* and *cavum* by the promi-



**Fig. 10.2** External ear, lateral view



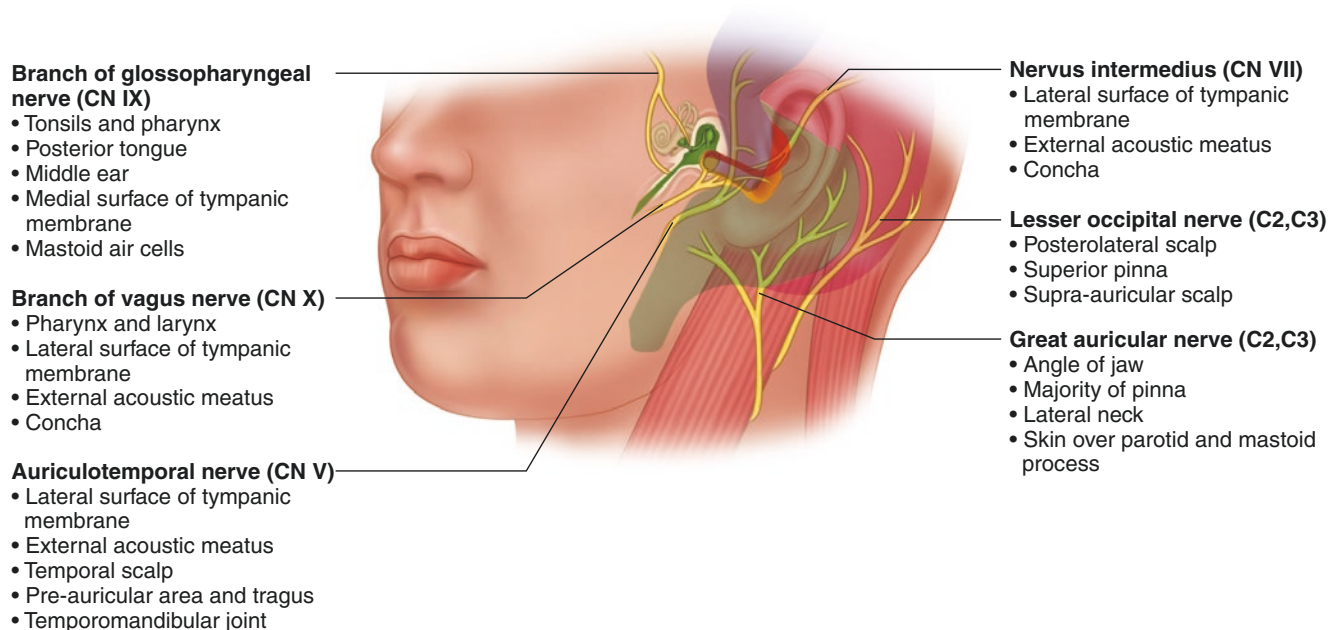
**Fig. 10.3** Lateral view, extrinsic muscles of the auricle

nent crus of the helix. The *tragus* is the cartilaginous projection external and anterior to the opening of the external auditory meatus. The outer rim of the ear is the *helix*, and it is usually rolled cartilage extending from the anterior attachment of the auricle to the posterior end of the elastic cartilage at the ear lobe. The helix of the ear is highly variable in its appearance. The antihelix is a prominence anterior and parallel to the helix. Its tail joins the antitragus which also projects over the concha. The skin, particularly in the depressions, may contain an abundance of sebaceous glands with hair follicles. The auricle is cosmetically important because of its prominence and its function in directing sound to the external auditory canal. The medial surface has an inverse pattern to the lateral surface.

Elastic cartilage composes the framework of the auricle, and it gives the auricle the ability to be folded and to bend. However, cartilage defects are difficult to repair because of the lack of direct blood supply to the chondrocytes.

The cartilage of the auricle is attached to the skull by anterior, superior, and posterior ligaments. Small extrinsic muscles (anterior, posterior, and superior, Fig. 10.3) are also involved with this attachment and allow movement of the auricle as a whole. Intrinsic muscles within the auricle are rudimentary.

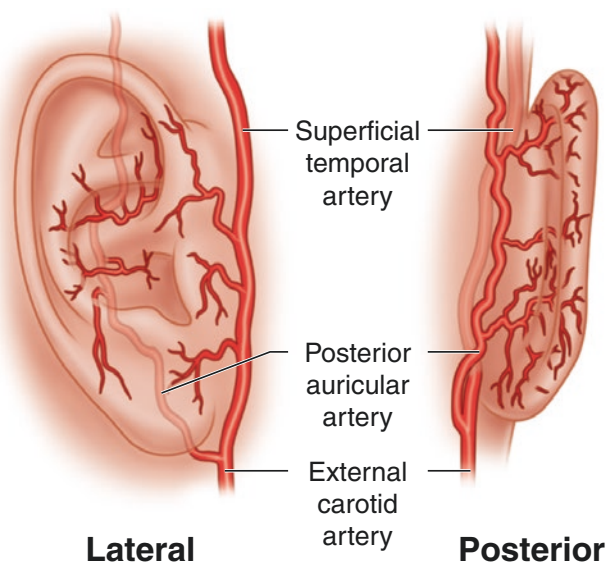
The sensory nerves to the auricle are from multiple cranial nerves and a cervical nerve (Fig. 10.4). The *auriculo-temporal nerve* (branch of CN V) provides sensation to the parts of the ear that are anterior to the external acoustic canal. See Appendix 5 for the complete distribution of CN V. The



**Fig. 10.4** Sensory nerves of external ear

posterior and medial surfaces of the auricle are supplied by the *great auricular nerve* (from the cervical plexus, Appendix 7). Other minor sensory contributions arise from the vagus nerve (CN X), the facial nerve (CN VII), the glossopharyngeal nerve (CN IX), and the lesser occipital nerve (from the cervical plexus). This becomes significant in the distribution of vesicles in herpes zoster infections. Motor innervation of the extrinsic muscles of the auricle is by branches of the facial nerve (CN VII).

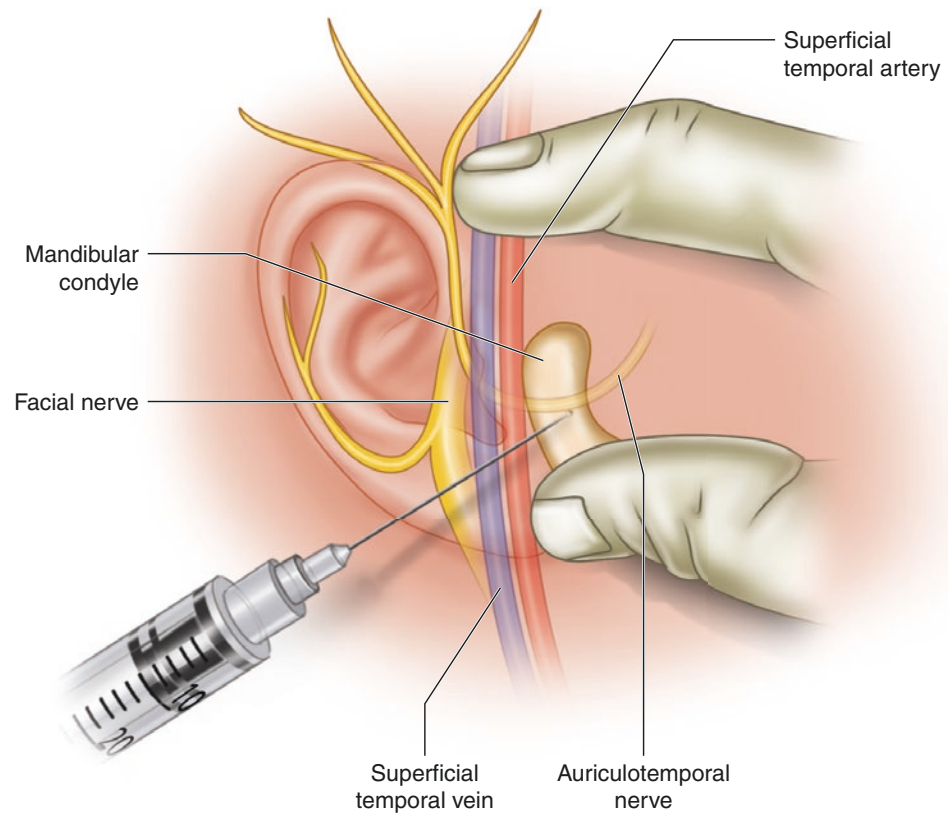
The blood supply to the part of the auricle anterior to the external auditory meatus is from the *anterior auricular artery*, branching from the *superficial temporal artery* anterior to the ear. The posterior part of the auricle is supplied by the *posterior auricular artery* located behind the ear, a branch of the external carotid artery (Fig. 10.5). The *auricular* branch of the occipital artery also supplies the medial part of the auricle. See Appendix 2 for the images and descriptions of the origins and distribution of these vessels. The venous drainage is through corresponding veins. Figure 10.6 illustrates the relationship of these vessels to the external ear, the head of the condyle, and the auriculotemporal nerve, all important in the delivery of an auriculotemporal nerve block.



**Fig. 10.5** Arterial distribution to the external ear



**Fig. 10.6** Auriculotemporal nerve block, showing the relationship of the superficial temporal artery, superficial temporal vein, condyle of the mandible, and the auriculotemporal nerve



### The External Auditory Canal

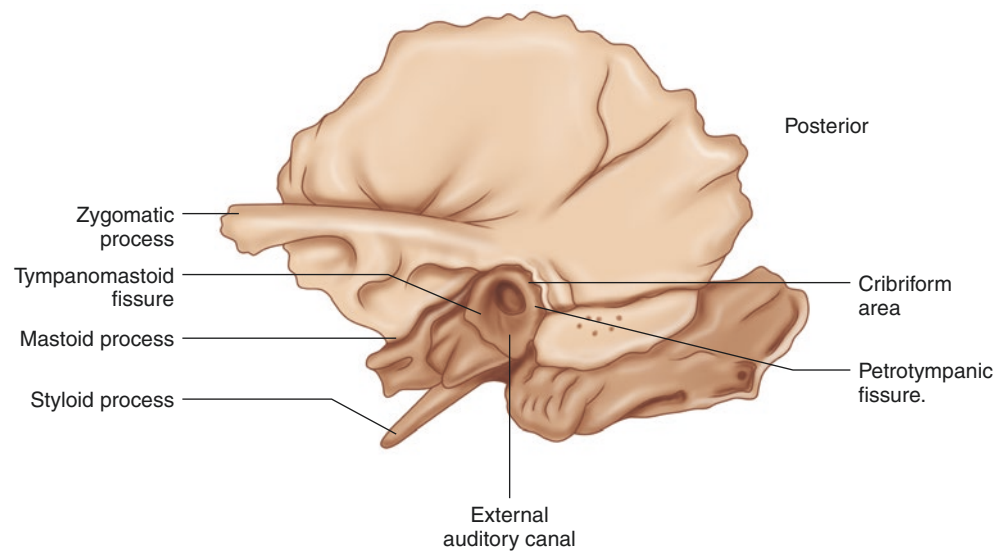
The external auditory canal is approximately 4.0 cm long from the tragus to the tympanic membrane and is S-shaped. The lateral section courses anterosuperiorly, while the medial part runs posteriorly. The external third is composed of cartilage covered by skin that is continuous with the auricle. This skin contains hair follicles and sebaceous and ceruminous glands. These glands are located mostly in the dermis of the interior and superior walls of the canal, producing cerumen (earwax). They may become infected, producing a furuncle. The medial two thirds of the tube is composed of temporal bone covered by thinner epithelium lacking glands or hair which is continuous with the tympanic membrane. There are two constrictions within the auditory canal, one at the lateral end of the cartilaginous portion and the narrowest point in the isthmus of the osseous portion. In infants, this canal is very short and the tympanic membrane is more horizontally oriented. The anterior part of the external auditory canal lies close to the temporomandibular joint and the parotid gland. The posterior part is separated from the mastoid air cells by very thin bone, allowing the potential for infection spread from the mastoid to the subperiosteal area. The blood supply

for the external auditory canal arises from branches of the superficial temporal, posterior auricular, and maxillary arteries (Fig. 10.5).

### The Lateral Surface of the Temporal Bone

The lateral surface of the temporal bone (Fig. 10.7) contains the five parts of the bone: squamous, tympanic, mastoid, styloid, and petrous, surrounding the external auditory canal. The cribriform area, superior to the external auditory canal and anterior to the mastoid process, contains areas of communication between the mastoid cortex and the mastoid antrum. This is a possible site of purulence from a mastoid infection. The suprameatal spine of Henle is inferior and anterior to this cribriform area. The tympanomastoid fissure separates the mastoid from the tympanic portions of the temporal bone. Infection may spread through this fissure from the external auditory canal to the base of the skull. The chorda tympani nerve (taste and parasympathetic fibers) and the anterior tympanic artery pass through the petrotympanic fissure.

**Fig. 10.7** Lateral surface of the temporal bone



### The Tympanic Membrane

The thin, semitransparent *tympanic membrane* is at the medial end of the external acoustic meatus, separating it from the middle ear. It has an oval shape and is covered by thin skin externally and mucous membrane internally with a discontinuous middle fibrous layer (*lamina propria*). Its movements are transmitted via the auditory ossicles in the middle ear to the inner ear. The tympanic membrane is angled anteroinferior to the axis of the external auditory canal, tipped to receive sounds from the anterior and lateral sides of the head. The external surface of the membrane is concave and the umbo is the shallow center of the concavity.

The sensory innervation of the lateral surface of the tympanic membrane is primarily by branches of CN V (auriculotemporal nerve), with contributions from CN VII, IX, and X. However, the medial surface is innervated by branches of CN VII and IX. The lateral blood supply is from arteries of the external auditory canal and the medial supply is from arteries that supply the middle ear.

# Anatomy of the Perioral Region

11

Christine E. Niekrash

## Anatomy of the Perioral Region

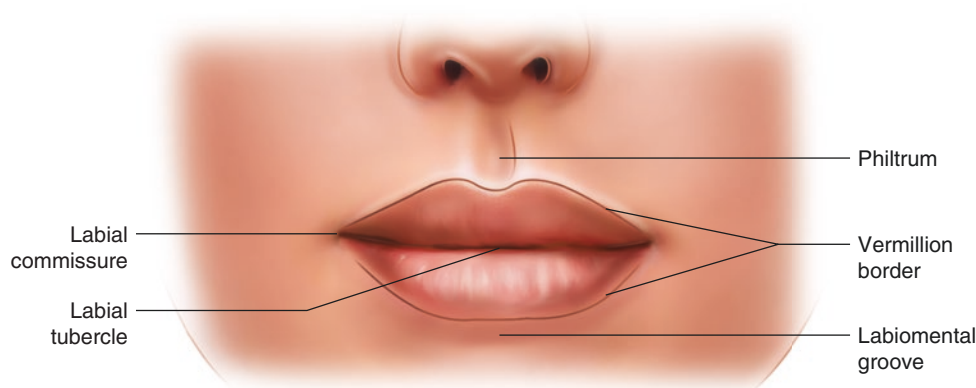
The mouth and lips are important structures in our appearance and in facial expression.

Lips are movable, and the capacity and amount of opening of the mouth are important in the ability to eat, speak, and maintain the contents of the mouth within the oral cavity. The mouth allows the entrance of food and drink and air to the body. The process of digestion begins in the mouth with the mastication of food and the initiation of digestion by salivary enzymes.

## Lips

The vermillion zone is the transition of skin to the nonkeratinized stratified squamous epithelium of the oral mucosa which lines the oral cavity (Fig. 11.1). The skin covering the lip is thin and without hair. It overlies extensive capillary beds, giving the lips their color. The vermillion border is the edge of the vermillion zone adjacent to the skin.

The labial commissure (cheilion) is the lateral location of the junction of the upper and lower lips. The oral fissure is the opening between the lips (entrance to the oral cavity).



**Fig. 11.1** Anterior view, mouth

C. E. Niekrash (✉)  
 Frank H. Netter MD School of Medicine, Quinnipiac University,  
 Hamden, CT, USA  
 e-mail: [christine.niekrash@quinnipiac.edu](mailto:christine.niekrash@quinnipiac.edu)

The upper lip contains a midline protrusion in the vermillion border, the labial tubercle. Superior to the tubercle is the philtrum, a shallow vertical groove extending toward the nose in the midline. The nasolabial groove separates the upper lip and philtrum from the cheek. It extends at an angle from the alar surface of the nose to the angle of the mouth.

The labiomental groove separates the chin from the lower lip.

## Musculature

The muscles controlling the mouth are complex, three-dimensional, bilateral, and interdigitated (Fig. 11.2). They are described in a general fashion in the Superficial Anatomy Chapter. More specific descriptions are below.

The orbicularis oris is a sphincter, a circular muscle surrounding the mouth. It gives support to the lips and allows for a tight seal of the oral cavity and protrusion of the lip. It also allows subtle movements essential for the generation of speech. Some intrinsic fibers originate from the alveolar bone housing the roots of the maxillary and mandibular incisors. Its fibers decussate with fibers from other facial mus-

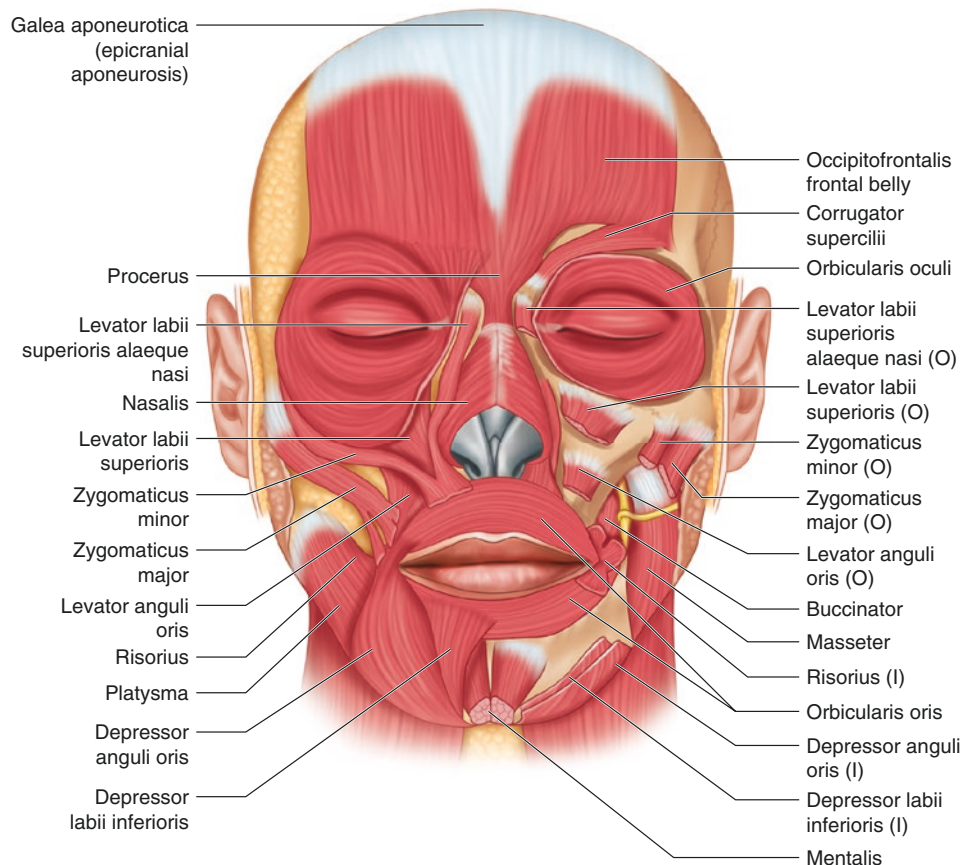
cles that converge on the mouth, including the buccinator, levator labii superioris, levator anguli oris, depressor anguli oris, depressor labii inferioris, and zygomaticus major.

## Elevators of the Upper Lip

Levator labii superioris arises from the lower margin of the orbit, superior to the infraorbital foramen and it inserts into the orbicularis oris and the skin of the upper lip. When contracted, it raises the upper lip and accentuates the nasolabial groove.

Levator labii superioris alaeque nasi arises from the superior aspect of the maxilla and courses inferiorly and laterally. Some fibers insert on the alar aspect of the nose and other fibers insert into the muscles of the upper lip. When it contracts, it will flare the nostril and elevate the upper lip.

Levator anguli oris is a deep muscle that originates from the canine fossa of the maxilla, inferior to the infraorbital foramen. It inserts into the decussation of muscles near the commissure of the mouth. It acts together with the other lip elevators to dilate the mouth and deepen the nasolabial groove. The infraorbital nerve and vessels lie infe-



**Fig. 11.2** Anterior view, muscles of facial expression



rior to the levator labii superioris and on top of the levator anguli oris.

Zygomaticus major originates on the lateral part of the zygomatic bone and travels medially and inferiorly to insert at the corner of the mouth, decussating with other perioral muscles. Its contraction results in a smiling action by moving the commissure of the mouth in a posterior, superior direction.

Zygomaticus minor also originates from the zygomatic bone medial to the origin of zygomaticus major. It inserts into the upper lip between the levator labii superioris and the zygomaticus major.

The risorius muscle is a thin, narrow muscle that arises from fascia covering the masseter muscle and buccal skin and also inserts at the angle of the mouth. When contracting, it pulls the commissure of the mouth in a lateral and downward direction.

---

## Depressors of the Lower Lip

Depressor anguli oris is a superficial muscle with a triangular shape. It arises from the oblique line of the mandible interdigitating with the platysma and inserts into the corner of the mouth. It acts to depress the angle of the mouth.

Depressor labii oris arises from the oblique line of the mandible between the symphysis and the mental foramen and inserts into the lower lip and the orbicularis oris. Some fibers interdigitate with the depressor labii oris arising from the opposite side of the mouth. It functions to depress the lower lip.

The mentalis muscle is a deep muscle that arises from the incisive fossa of the mandible. It inserts into the skin of the chin lateral to the lip frenum. It holds the lower lip against the incisor teeth, elevates the lower lip, and causes dimpling of the chin when it is contracted.

---

## Buccinator

The lateral surface of the buccinator muscle underlies the fascia and skin of the cheek and the medial surface supports the lateral mucosa of the oral cavity. It is a deep muscle underlying the other facial muscles. It is located between the maxilla and mandible and arises from the posterior alveolar process of both of these bones and the pterygomandibular raphe which connects the buccinator to the superior constrictor muscle. The buccinator inserts through decussating fibers in the upper and lower lips. The duct of the parotid gland passes through the buccinator to empty saliva into the oral cavity opposite to the maxillary second molar. The action of the buccinator keeps the bolus of food on the masticatory

surfaces of the teeth. It also tenses the cheek to allow forceful exhalation of air from the mouth, as in blowing a trumpet.

## Modiolus

The modiolus is a fibromuscular, multiplanar structure where as many as nine perioral muscles (described above) interlace. It is located at the lateral border of the labial commissure and is highly variable in appearance. It is important in the formation of facial expressions and dimples. The facial artery is located approximately 1 mm lateral to the modiolus.

---

## Motor Innervation

All of the muscles of the perioral region are innervated by the facial nerve (CN VII), the more superior muscles from the buccal division and more inferior muscles from the mandibular division. Please see Appendix 6 and the chapter on the Superficial Anatomy of the face for the details of this cranial nerve. In the perioral area, the buccal branch of the facial nerve innervates the muscles around both the upper and lower lips. The mandibular branch innervates the muscles of the lower lip, and it courses over the margin of the mandible just anterior to the masseter muscle. The cervical branch innervates platysma.

---

## Sensory Innervation

Sensory innervation of the perioral region is by the trigeminal nerve (Appendix 5) and cervical nerves (Appendix 7).

The infraorbital nerve, a branch of the maxillary division of the trigeminal, emerges onto the face through the infraorbital foramen of the maxilla located between the origins of levator labii superioris and levator anguli oris. The infraorbital nerve provides sensation to the medial surface of the lower nose, the lower eyelid, and the cheek all the way to the upper lip.

The buccal nerve, a branch of the mandibular division of the trigeminal, courses either beneath or through the inferior part of the temporalis muscle, enters the buccal fat pad, and terminates in the cheek at approximately the occlusal plane. It provides sensation to the cheek.

The mental nerve is the terminal branch of the inferior alveolar nerve of the mandibular division of the trigeminal. It leaves the mandible through the mental foramen beneath the depressor labii inferioris between the roots of the mandibular premolars. The mental nerve provides sensation to the lower lip and the chin.

Sensation to the skin along the inferior border of the mandible and the angle of the mandible is provided by the transverse cutaneous and great auricular nerves of the cervical plexus.

### Arterial Blood Supply

The blood supply to the face has a rich collateral circulation with many anastomoses occurring among vessels. This is wonderful for perfusion, but makes bleeding sometimes difficult to control.

The facial artery, a branch of the external carotid artery (Appendix 2), travels deep to the stylohyoid muscle and posterior belly of the digastric muscle, superior or through the submandibular gland, and over the margin of the mandible onto its external surface at the anterior border of the masseter muscle. It then takes a tortuous, oblique course deep to the platysma, risorius, zygomaticus major and minor muscles, but superficial to the buccinator muscle and continues along the lateral surface of the nose as the angular artery.

In the perioral region, the facial artery gives off superior and inferior labial arteries within or close to the orbicularis oris.

### Venous Drainage

The facial vein (Appendix 2) courses parallel to the facial artery inferiorly and obliquely across the face. It is deep to the zygomaticus muscles and runs between the mandible and the submandibular gland to empty into the retromandibular vein. It anastomoses with many veins, including those draining the orbits and the pterygoid plexus. Because these veins do not have valves, infections in this area may cause retrograde flow through these veins to the cavernous sinus. Infections along the path of this vein are in the danger zone of the face because of the potential rapid spread of infection to the cavernous sinus within the cranium.

## Superficial Anatomy of the Neck

The skeleton of the neck is composed of the cervical vertebrae, the clavicles, the manubrium of the sternum, and the hyoid bone. The trachea and its associated cartilages lie in the anterior midline of the neck. The thyroid cartilage is the largest cartilage in the airway and houses the larynx. The esophagus is posterior to the trachea and is continuous superiorly with the pharynx, a musculomembranous area posterior to the nasal, oral, and laryngeal structures. The main arterial flow to the head and its venous drainage lie in the anterior, lateral portion of the neck.

The superficial neck is divided into two major triangles, the anterior triangle and the posterior triangle, by the sternocleidomastoid muscle (Fig. 12.1). It is a prominent muscle easily visualized and palpated in the neck. The carotid artery and internal jugular vein are deep to this muscle, and the external jugular vein crosses diagonally on top of it.

The structures listed below (Fig. 12.2) can be palpated in the neck and serve as anatomic landmarks. The bones are described in more detail in Appendix 1.

- *Hyoid bone*: located below the mandible. It is U-shaped, consisting of a body and greater and lesser horns (cornu).
- *Thyroid cartilage*: consists of right and left laminae and a laryngeal prominence anteriorly. The superior notch can be palpated. The thyroid cartilage is connected to the hyoid bone by the thyrohyoid membrane. The laminae have superior and inferior horns. The lateral surface of each lamina is marked by an oblique line that serves as an attachment for the sternothyroid, thyrohyoid, and inferior constrictor muscles. The thyrohyoid membrane is pierced

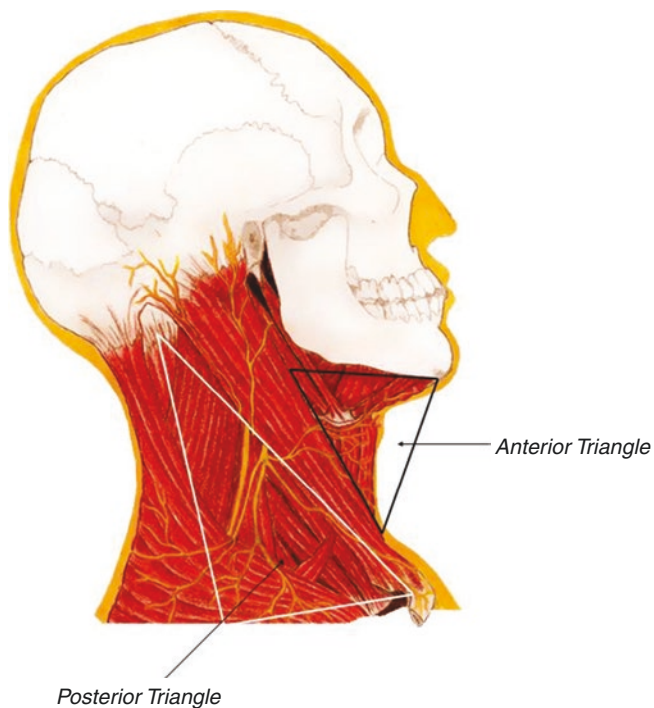
by the internal branch of the superior laryngeal nerve and superior laryngeal vessels. The thyroid cartilage is hyaline and is the first of the laryngeal cartilages to ossify, beginning around age 20–23 years. The cartilage can be visualized upon radiologic examination, but may not be fully ossified. Therefore, circular areas in the center of the cartilage may not be ossified and can easily be confused with neoplastic invasion and damage.

- *Cricoid cartilage*: located below the thyroid cartilage and connected to it by the cricothyroid muscle laterally and the cricothyroid membrane anteriorly. The cricoid cartilage is shaped like a signet ring with a tall posterior lamina (the signet) and a shorter anterior arch (the band). The cricoid cartilage is the only complete ring of cartilage in the respiratory tract. Posteriorly and laterally on the lamina is a facet for articulation with the inferior horn of the thyroid cartilage to form the cricothyroid joint. Posteriorly and superiorly on the lamina is a smooth area for articulation with the arytenoid cartilages of the larynx to form the cricoarytenoid joint. Anteriorly, the cricoid and thyroid cartilages are connected by the median cricothyroid ligament. The cricoid cartilage is also hyaline and begins to ossify in the second decade of life, after the thyroid cartilage. Therefore, the cartilage can also be viewed on radiological examination.
- *Tracheal rings*: located below the cricoid cartilage. They are C-shaped and have a lamina posteriorly and a cartilaginous arch anteriorly.
- *Transverse processes of cervical vertebrae*.

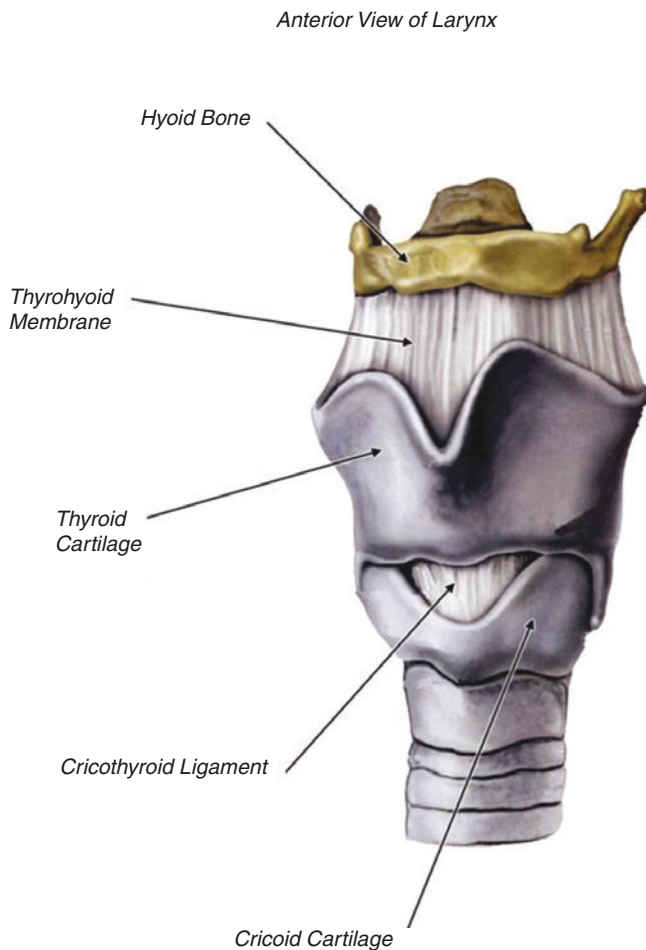
## Emergency Airway Access: Cricothyroidotomy

The safest and easiest way to access the airway in the event of obstruction at or above the level of the vocal cords is through the cricothyroid membrane. This layer of connective tissue is relatively superficial and can be identified by palpation.

C. E. Niekrash (✉)  
Frank H. Netter MD School of Medicine, Quinnipiac University,  
Hamden, CT, USA  
e-mail: [christine.niekrash@quinnipiac.edu](mailto:christine.niekrash@quinnipiac.edu)



**Fig. 12.1** Triangles of the neck separated by the sternocleidomastoid muscle



**Fig. 12.2** Anterior view: palpable structures in the neck

ing the prominence of the cricoid cartilage and then locating the soft-tissue depression immediately above it and below the thyroid cartilage. Entering the airway at this point avoids the vascular thyroid isthmus that overlies the trachea.

Other cartilaginous structures in the neck include:

- The *arytenoid cartilages*: two pyramidal-shaped cartilages within the larynx that sit on top of the cricoid cartilage and are located posteriorly, protected by the thyroid cartilage. The arytenoid cartilages have a vertical process, a vocal process anteriorly to which is attached the vocal fold (ligament, cord) and a lateral process to which laryngeal muscles attach. The articulation with the cricoid cartilage permits both lateral–medial sliding and rotational movements. Thus, movements of the arytenoid cartilages can approximate or separate the vocal folds and tense or relax them. The arytenoid cartilages are hyaline, ossify usually by age 30, and can be viewed on radiologic examination.
- The *epiglottis* is a heart-shaped cartilage attached in the angle between the thyroid laminae by the thyroepiglottic ligament, just above the vocal fold. During swallowing, the epiglottis is bent posteriorly to cover the opening to the larynx and the airway. The epiglottis is elastic cartilage covered by mucous membrane and it seldom ossifies.

## Visceral Structures of the Neck

### The Thyroid Gland

The thyroid gland consists of two lobes connected by an isthmus. The isthmus of the thyroid gland lies across the trachea below the cricoid cartilage. The lobes of the gland then circle laterally around the trachea, esophagus, and inferior constrictor muscle and are deep to the sternothyroid and sternohyoid muscles. Often, a third (pyramidal) lobe extends superiorly from the isthmus in the midline. The lobes of the thyroid press posteriorly against the carotid sheaths. The recurrent laryngeal nerves and branches of the vagus (Appendix 8) are located in close proximity to the thyroid gland.

The thyroid gland receives its rich blood supply from the superior thyroid branch of the external carotid artery and the inferior thyroid branch of the thyrocervical trunk from the subclavian artery. It is drained by the superior and middle thyroid veins into the internal jugular vein and by the inferior thyroid vein into the left brachiocephalic vein (see Appendix 2).

### The Parathyroid Glands

Usually, there are four parathyroid glands within the capsule of the thyroid gland or embedded within the thyroid. A detailed description of the thyroid and parathyroid glands is beyond the scope of this book.



## The Submandibular Salivary Gland

The submandibular gland is located inferior and medial to the mandible. It is enclosed in a connective tissue capsule, secretes saliva, and contains both serous and mucous producing cells. The gland empties via ducts of the submandibular gland (Wharton's duct) into the anterior floor of the mouth. The facial artery passes through or over the posterior part of the gland and curves superiorly onto the face over the inferior border of the mandible.

## Muscles of the Neck

The platysma is a large, superficial, thin muscle found in the anterior and lateral portions of the neck. The major cutaneous nerves of the neck lie deep to this muscle. Because of its innervation (facial nerve, CN VII) and function, it is grouped with the muscles of facial expression.

### Platysma

- *Arises* in fascia over the deltoid and pectoralis major muscles
- *Inserts* on border of mandible
- *Decussates* with platysma from opposite side and muscles of facial expression over the chin
- *Innervated* by cervical branch of facial nerve
- *Located* in subcutaneous tissue of the neck
- *Lies* superior to the external jugular vein
- *Great variability* in appearance, thickness, and continuity
- *Functions*:
  - Tense skin
  - Depress mandible
  - Depress corners of mouth

## The Posterior Triangle

The posterior triangle is bounded posteriorly by the anterior border of the trapezius and anteriorly by the posterior border of the sternocleidomastoid. The apex is formed where the muscles meet above on the superior nuchal line. The base is the middle third of the clavicle. The floor of the triangle is formed by the deeper muscles. The muscles found in this triangle include the following:

- Sternocleidomastoid
- Trapezius
- Levator scapulae
- Anterior scalene
- Middle scalene

- Posterior scalene
- Inferior belly of omohyoid

### Sternocleidomastoid Muscle

- *Arises* inferiorly by two heads from the upper border of the manubrium and the medial one third of the clavicle
- *Inserts* above onto the lateral surface of the mastoid process and lateral half of superior nuchal line
- *Innervated* by the accessory nerve (CN XI)
- *Actions* when one side contracts:
  - Rotates head to opposite side
  - Tilts head toward shoulder
- *Actions* when both contract:
  - Draws head forward
  - Flexes cervical vertebral column
  - Can elevate thorax in forced inspiration

### Trapezius Muscle

- *Arises* from medial third of superior nuchal line, external occipital protuberance, ligamentum nuchae, and spinous process of C7–T12 vertebrae
- *Inserts* on lateral third of clavicle, acromion, and spine of scapula
- *Innervated* by accessory nerve and C3 and C4
- *Functions*: elevates, retracts, and rotates scapula

### Levator Scapulae Muscle

- *Arises* from the transverse process of C1–C4 vertebrae
- *Inserts* on medial border of the scapula
- *Innervated* by C3–C5
- *Functions*: inclines the neck laterally

### Posterior Scalene Muscle

- *Arises* from transverse process of C4–C6 vertebrae
- *Inserts* on second rib
- *Innervated* by ventral rami of C5–C8
- Bends the cervical vertebral column to the same side
- Located between middle scalene and levator scapulae

### Middle Scalene Muscle

- *Arises* from the transverse processes of the cervical vertebrae
- *Inserts* on posterior first rib
- *Innervated* by ventral rami of spinal nerves C3–C8
- *Functions*: if the first rib is fixed, it bends the cervical vertebral column forward and laterally
- The roots of the brachial plexus emerge between the anterior and middle scalene muscles

### Anterior Scalene Muscle

- *Arises* from the transverse processes of cervical vertebrae
- *Inserts* on first rib

- Lies deep to the subclavian vein and superficial to the subclavian artery
- The brachial plexus and subclavian artery emerge from its posterolateral border
- Phrenic nerve lies on top and crosses medially as it descends
- The subclavian vein, suprascapular artery, and superficial cervical artery cross on top of the anterior scalene
- Thyrocervical trunk of the subclavian artery is on the medial border
- Flexes and rotates cervical vertebral column

The posterior triangle of the neck is further subdivided into the *occipital triangle* and the *supraclavicular triangle* by the inferior belly of the omohyoid muscle (Fig. 12.4).

## Anterior Triangle

The anterior triangle is bounded in front by the midline of the neck, behind by the anterior border of the sternocleidomastoid and above by the lower border of the mandible. The anterior triangle contains the pharynx and esophagus, the larynx and trachea, and the thyroid gland. It also contains a major neurovascular bundle that includes the carotid arteries and the branches of the external carotid, the internal jugular vein and its tributaries, and the vagus nerve and its branches. The common and internal carotid arteries, internal jugular

vein, and vagus nerve are enclosed in the carotid sheath of fascia.

The muscles of the anterior triangle are divided into the infrahyoid group and the suprahyoid group. All of these muscles help control the posture of both the larynx and the tongue during speech and swallowing. They also balance the muscles posterior to the vertebral column, influencing the posture of the head.

## Infrahyoid Group

All infrahyoid muscles (also called strap muscles) are innervated by fibers from the upper cervical spinal nerves which accompany the hypoglossal nerve to form the ansa cervicalis. The infrahyoid group consists of the following muscles (Fig. 12.3):

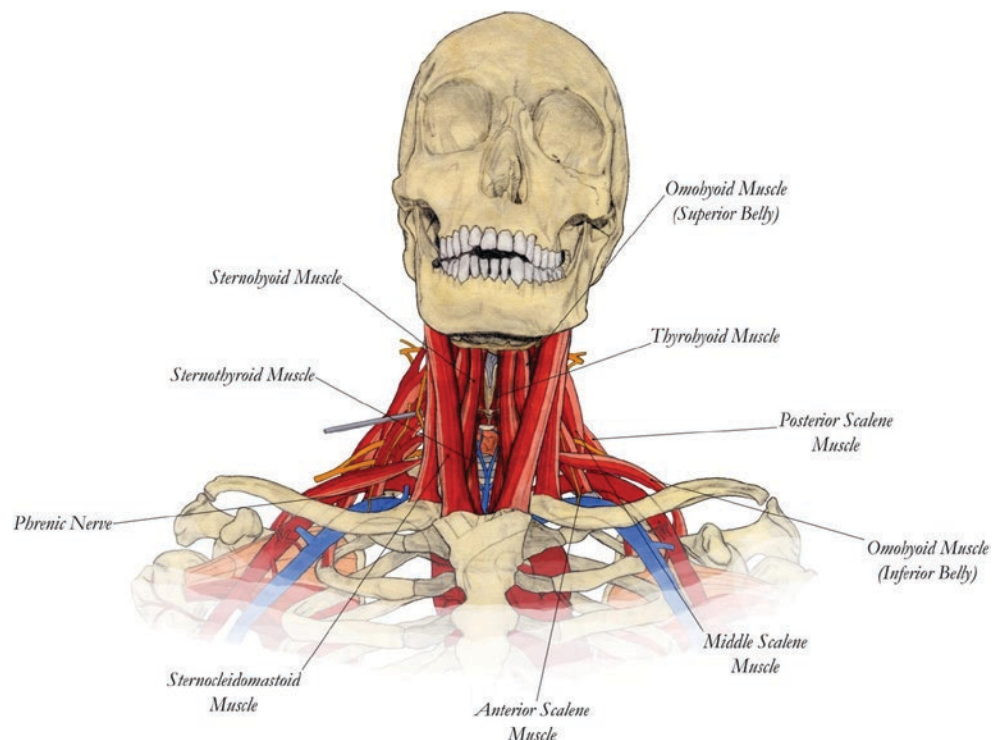
- *Omohyoid*
- *Sternohyoid*
- *Sternothyroid*
- *Thyrohyoid*

The omohyoid and sternohyoid are superficial to the sternothyroid and thyrohyoid which are deep.

## Omohyoid Muscle

- Long thin muscle that crosses both the anterior and posterior triangles
- Arises from the upper border of the scapula

**Fig. 12.3** Anterior view: muscles of the neck



- Inserts on the lower border of the hyoid bone
- Has an intermediate tendon that passes through an indistinct sling of fascia attached to the clavicle and the first rib deep to the sternocleidomastoid
- Lowers the hyoid bone

### Sternohyoid Muscle

- Arises from the posterior surface of the sternoclavicular joint
- Inserts on lower border of the body of the hyoid bone
- Lowers the hyoid bone after swallowing

### Sternothyroid Muscle

- Arises from the posterior deep surface of the manubrium
- Inserts on the oblique line of the thyroid lamina
- Depresses larynx after swallowing

### Thyrohyoid Muscle

- Arises from the oblique line of the thyroid lamina
- Appears as superior continuation of sternothyroid muscle
- Inserts at lower border of greater horn and body of the hyoid bone

### Stylohyoid Muscle

- Arises from the base of the styloid process
- Inserts on body and greater horn of hyoid
- Innervated by facial nerve

### Suprahyoid Group

If the hyoid bone is stabilized, the suprahyoid muscles depress the mandible (open the mouth). If the mandible is stabilized, they elevate the hyoid bone, a common action in speech and swallowing. The suprahyoid group consists of four muscles:

- *Mylohyoid*
- *Geniohyoid*
- *Digastric*
- *Stylohyoid*

### Digastric Muscle

- Arises from the mastoid notch medial to the mastoid process
- Inserts in the digastric fossa on the lingual surface of the mandible near the midline
- Has an intermediate tendon which passes through a sling formed by the attachment of the stylohyoid muscle to the lesser horn of the hyoid
- Posterior belly innervated by the facial nerve
- Anterior belly is innervated by the mylohyoid branch of the inferior alveolar branch of the trigeminal nerve

### Mylohyoid Muscle

- Arises from the mylohyoid line on the medial surface of the body of the mandible
- Inserts on both the body of the hyoid and, anteriorly, a midline connective tissue raphe, forming the muscular floor of the oral cavity
- Innervated by the mylohyoid branch of the inferior alveolar nerve branch of the trigeminal nerve
- Elevates the floor of the mouth and the hyoid bone

### Geniohyoid Muscle

- Located above the mylohyoid muscle
- Arises from the inferior mental spine (genial tubercle)
- Inserts on anterior surface of the hyoid bone
- Elevates and protrudes hyoid
- Supplied by fibers from C1 via the hypoglossal nerve

### Stylohyoid Muscle

- Arises from styloid process of temporal bone.
- Located anterior and superior to the posterior belly of the digastric muscle.
- Inserts on body of the hyoid bone.
- Innervated by the facial nerve (CN VII).
- Elevates and retracts hyoid.
- The stylohyoid ligament arises from the tip of the styloid process and extends to the hyoid bone. It may become ossified.

### Actions of Suprahyoid Muscles

- If hyoid is stabilized, depress mandible.
- If mandible is stabilized, elevate hyoid.
- Attach hyoid to mandible.

The *anterior triangle* of the neck is subdivided into the *submandibular triangle*, *submental triangle*, *carotid triangle*, and *muscular triangle* (Fig. 12.4).

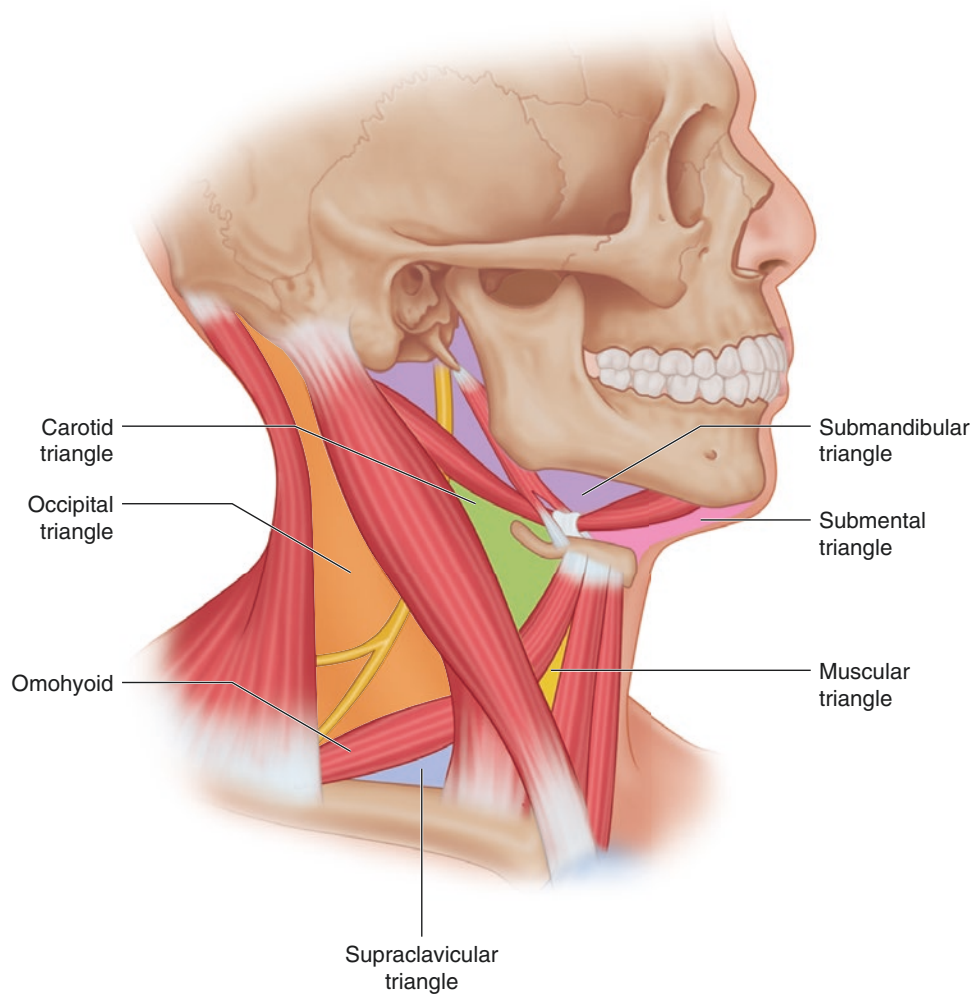
The muscles of the posterior neck and the vertebral muscles are beyond the scope of this book and are therefore not included.

---

## Fascia of the Neck

Dense connective tissue called fascia surrounds many of the structures in the neck and segments the neck into various compartments. Understanding their anatomy explains the potentially dangerous spread of infection in the neck region.

The *superficial cervical fascia* encircles the neck and consists of adipose-rich connective tissue directly underlying the dermis. The platysma muscle lies within this superficial layer.



**Fig. 12.4** Lateral view: triangles of the neck

The *deep cervical fascia* divides the contents of the neck into compartments. It consists of four layers: investing, pretracheal, prevertebral, and carotid sheath. The *investing layer* surrounds the entire neck deep to the skin and superficial cervical fascia. It splits to encircle the sternocleidomastoid and trapezius muscles, the submandibular gland, and the parotid gland. The investing layer is tightly bound to the adjacent bony structures. It condenses to form the ligamentum nuchae in the posterior and the stylomandibular ligament laterally.

The *pretracheal layer* of the deep cervical fascia is in the anterior portion of the neck from the hyoid to the thorax. It encircles the suprahyoid and infrahyoid muscles, the trachea, esophagus, and thyroid gland.

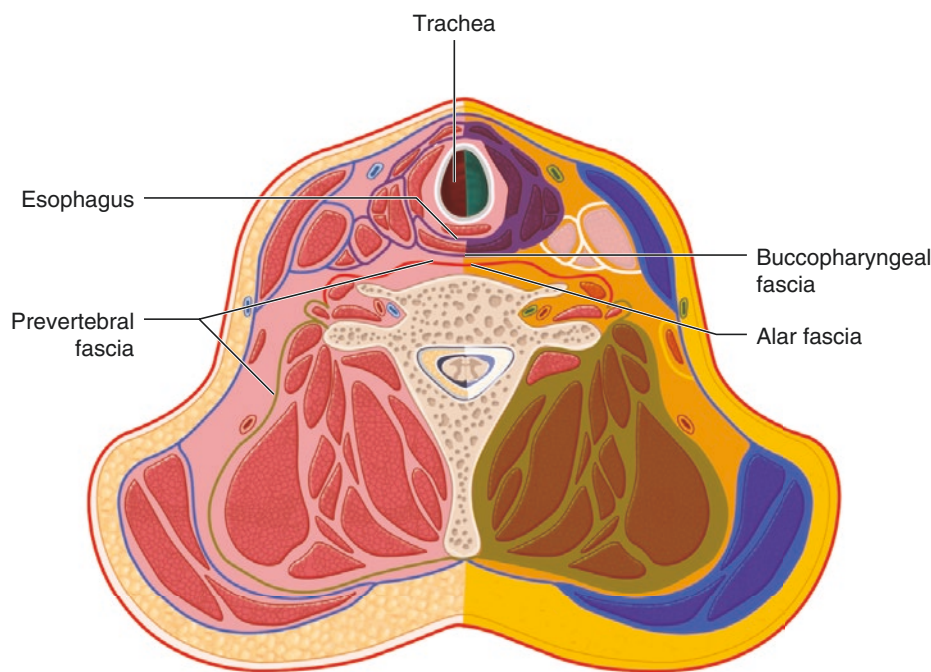
Posteriorly, the *prevertebral layer* surrounds the cervical vertebral column and its deep muscles. The *carotid sheath* is

an extension of these fascial layers, and it surrounds the common and internal carotid artery, the internal jugular vein, and the vagus nerve (CN X).

Another layer of fascia (the buccopharyngeal fascia) invests the pharynx located superiorly. Inferiorly, it is connected to the pretracheal fascia. This creates a potential space between the prevertebral layer of fascia and the pretracheal layer/buccopharyngeal fascia, the *retropharyngeal space*, which communicates down to the mediastinum. It is subdivided by a thin alar fascia (Fig. 12.5).

Notice the interfascial potential spaces. These areas consist of loose connective tissue and allow the structures in the neck to move and slide over each other. They also allow separation of the structures during surgery or dissection. This is also the site of infection, inflammation, and tumor spread guided by the fascia.





**Fig. 12.5** Fascia of the neck

## Nerves of the Neck

### Accessory Nerve (CN XI)

From the accessory nucleus in the cervical spinal cord (branchial motor) at the level of the C1–C5 segments, the *accessory nerve* (CN XI) enters the cranial cavity through the foramen magnum. It then exits the skull through the jugular foramen. The nerve passes deep to the sternocleidomastoid muscle, which it supplies, emerges from its posterior border, and crosses the posterior triangle across the levator scapulae muscle above the prevertebral layer of the deep cervical fascia. It enters the trapezius muscle to innervate it. It courses within or deep to the investing layer of the deep cervical fascia.

### Cervical Nerves

Fibers from the upper cervical spinal nerves (Appendix 7) accompany the hypoglossal nerve to form the *ansa cervicalis*. These fibers join the hypoglossal nerve as it leaves the hypoglossal canal, travels with it a short distance, and leaves the nerve to form the superior limb of the ansa cervicalis. This limb is joined by other fibers from the upper cervical

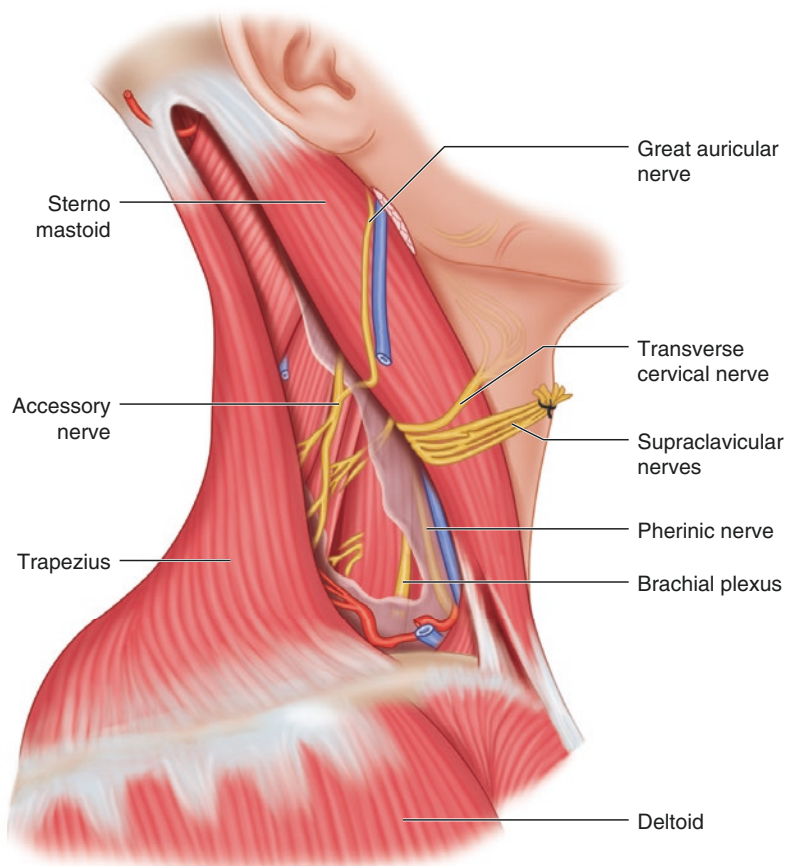
segments (inferior limb) to form the ansa. The fibers to the thyrohyoid and geniohyoid muscles leave the hypoglossal nerve as a separate branch (C1 fibers) rather than accompanying the fibers to the ansa.

The cervical plexus gives off several additional branches. The *lesser occipital nerve* supplies the skin of the posterolateral scalp and the superior portion of the external ear. The *great auricular nerve* supplies the skin over the parotid gland, over the mastoid process, and on the posterior surface of the external ear. The *transverse cutaneous nerve* of the neck supplies the skin of the anterior neck from the chin to the sternum. The *supraclavicular nerves* supply the skin of the back, shoulder, and chest down to the level of the second rib. These nerves along with the accessory nerve (CN XI) emerge from under the posterior midportion of the sternocleidomastoid muscle (Fig. 12.6).

The cervical plexus also gives rise to the *phrenic nerve* that innervates the diaphragm. It courses across the top of the anterior scalene muscle.

### Facial Nerve (CN VII) Branches

The course of the facial nerve is described in Appendix 6. The *mandibular branch* of the facial nerve courses onto the



**Fig. 12.6** Lateral view: superficial nerves of the neck

neck approximately 2 cm below the inferior border of the mandible before it crosses the facial artery and vein to innervate the depressor muscles of the lower lip. The cervical branch of the facial nerve is inferior to the mandibular nerve and innervates the platysma.

### Glossopharyngeal Nerve (CN IX)

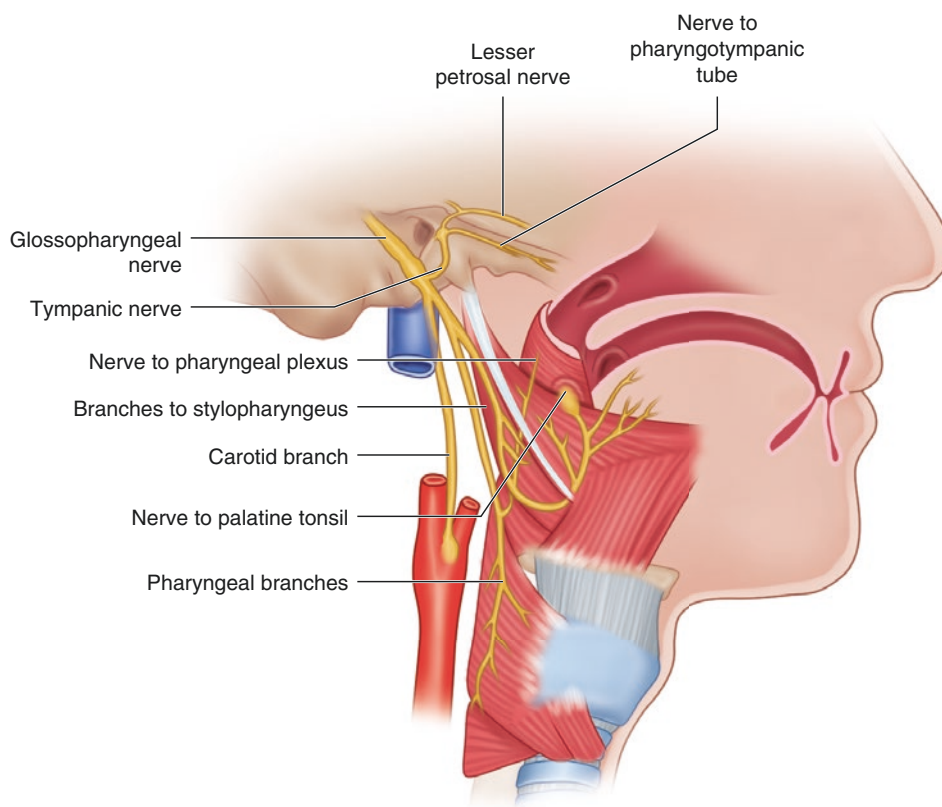
The course of the glossopharyngeal nerve (including its role in parasympathetic innervation of the parotid, and special sensory (taste)) is described in detail in Appendix 8 and shown in Fig. 12.7. It exits the cranium through the internal jugular foramen deep to the styloid process and follows the lateral surface of the stylopharyngeus muscle which it supplies. It courses between the superior and middle pharyngeal constrictor muscles to provide sensation to the posterior third of the tongue, palatine tonsil, pharynx, and soft palate. It gives rise to lingual, tonsillar, and pharyngeal branches. It also sends a sensory branch to the carotid body and sinus. This nerve initiates the gag reflex.

### Vagus Nerve

The vagus nerve is described in detail in Appendix 9. It leaves the cranium and enters the neck through the jugular foramen, between the glossopharyngeal and accessory nerves. The vagus then descends in the neck within the carotid sheath. It sends branches to the palate, pharynx, and larynx (Fig. 12.8). The superior laryngeal nerve arises high in the carotid triangle and branches into the external laryngeal nerve and the internal laryngeal nerve. The external laryngeal nerve descends with the superior thyroid artery, deep to the sternothyroid muscle to supply the cricothyroid muscle. The internal laryngeal nerve passes through the thyrohyoid membrane with the superior laryngeal artery to supply sensation to structures superior to the vocal folds and inferior to the epiglottis.

The right and left vagus nerves follow different paths as they descend in the neck. The left vagus descends between the left subclavian and left common carotid arteries. The right descends between the subclavian artery and the brachiocephalic vein. In the root of the neck, the vagus nerve

**Fig. 12.7** Lateral view:  
peripheral distribution of the  
glossopharyngeal nerve



gives rise to the recurrent laryngeal nerves. The left recurrent laryngeal nerve loops under the arch of the aorta, and the right recurrent laryngeal nerve arises more superiorly coursing under the right subclavian artery. The recurrent laryngeal nerves on both sides course superiorly deep to the medial portion of the thyroid in the trachea–esophageal groove. The recurrent laryngeal nerves supply all of the intrinsic muscles of the larynx with the exception of the cricothyroid muscle.

The vagus then continues to descend into the thorax and abdomen, beyond the scope of this book.

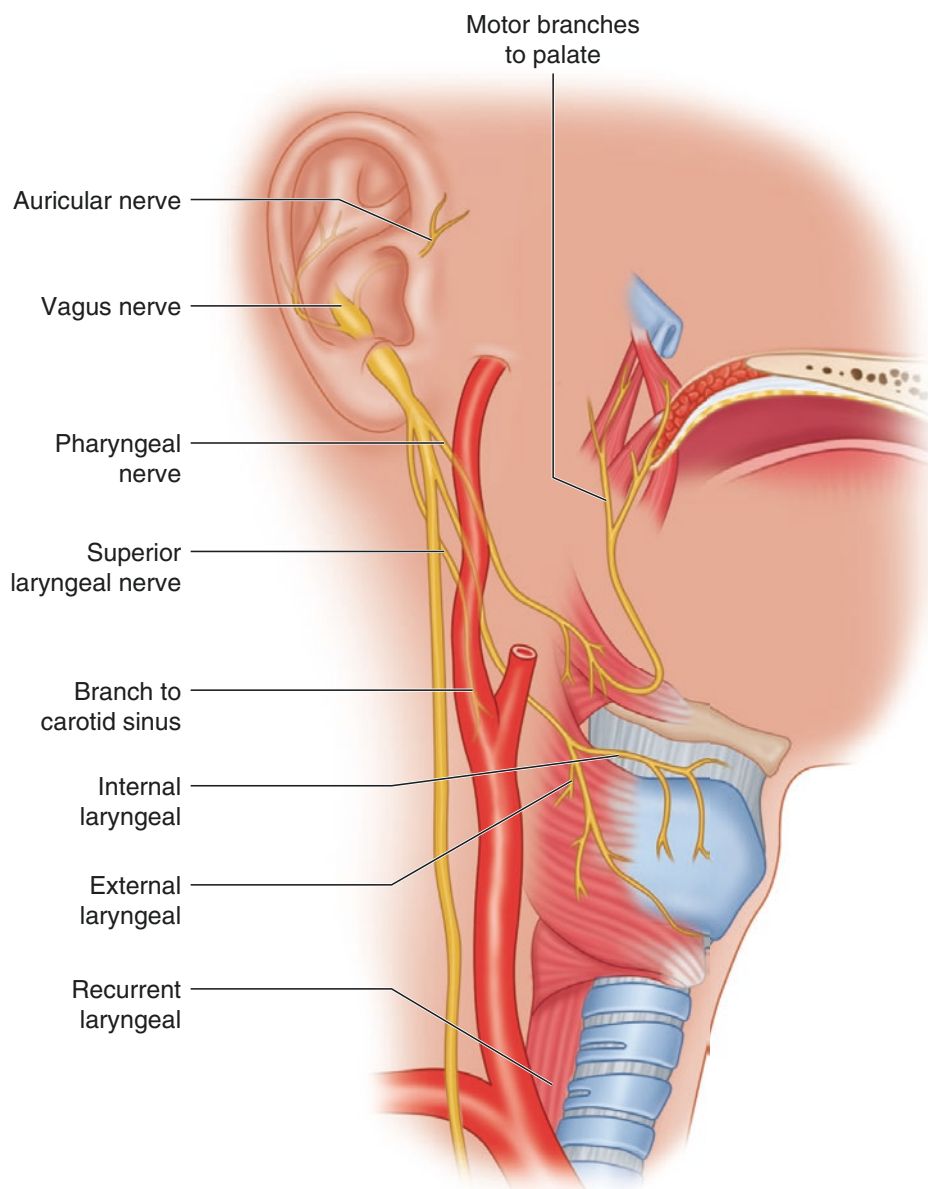
### The Cervical Sympathetic Trunk

In the neck, the sympathetic trunk ascends anterolateral to the cervical vertebrae. It usually contains three ganglia (inferior, middle, and superior) that receive presynaptic fibers from the thoracic spinal nerves. After synapsing in the superior cervical ganglion, the postsynaptic fibers ascend as periarterial nerve plexuses to the head and neck, especially in the internal carotid plexus. Often, the inferior cervical ganglion is fused with the first thoracic ganglion and is then called the stellate ganglion, at the level of C7.

### Hypoglossal Nerve

This nerve innervates the extrinsic and intrinsic muscles of the tongue, except the palatoglossus which is embryologically a muscle of the palate supplied by the vagus nerve. Its course is described in Appendix 10. It exits the cranium through the hypoglossal canal in the occipital bone and enters the neck underneath the posterior belly of the digastric muscle, courses inferiorly. Where the external carotid artery gives rise to the occipital artery, the hypoglossal nerve passes inferior to the occipital artery, courses anteriorly, superficial to the internal and external carotid artery. It passes deep to the anterior portion of the posterior belly of the digastric, superficial to the hyoglossus muscle, and dives deep to the mylohyoid muscle.

The hypoglossal (Fig. 12.9) is joined, after it leaves the skull through the hypoglossal canal, by fibers from the ventral rami of the first and second cervical nerves. These fibers subsequently leave the hypoglossal nerve and descend to form a loop with descending fibers from the ventral rami of the second and third cervical nerves. The loop is the ansa cervicalis, and fibers from it innervate all of the muscles joining the clav-



**Fig. 12.8** Lateral view: vagus distribution within the neck

icle to thyroid cartilage to hyoid bone to mandible, except the digastric (trigeminal and facial nerves) and mylohyoid (trigeminal nerve). These "strap muscles" are the omohyoid, sternohyoid, sternothyroid, thyrohyoid, and geniohyoid.

### Arteries of the Neck

On the left, the *common carotid* and *subclavian arteries* are both branches of the arch of the *aorta*. On the right, the *brachiocephalic trunk* from the aorta divides into the common carotid and subclavian arteries. Please consult Appendix 2 for illustrations of these vessels.

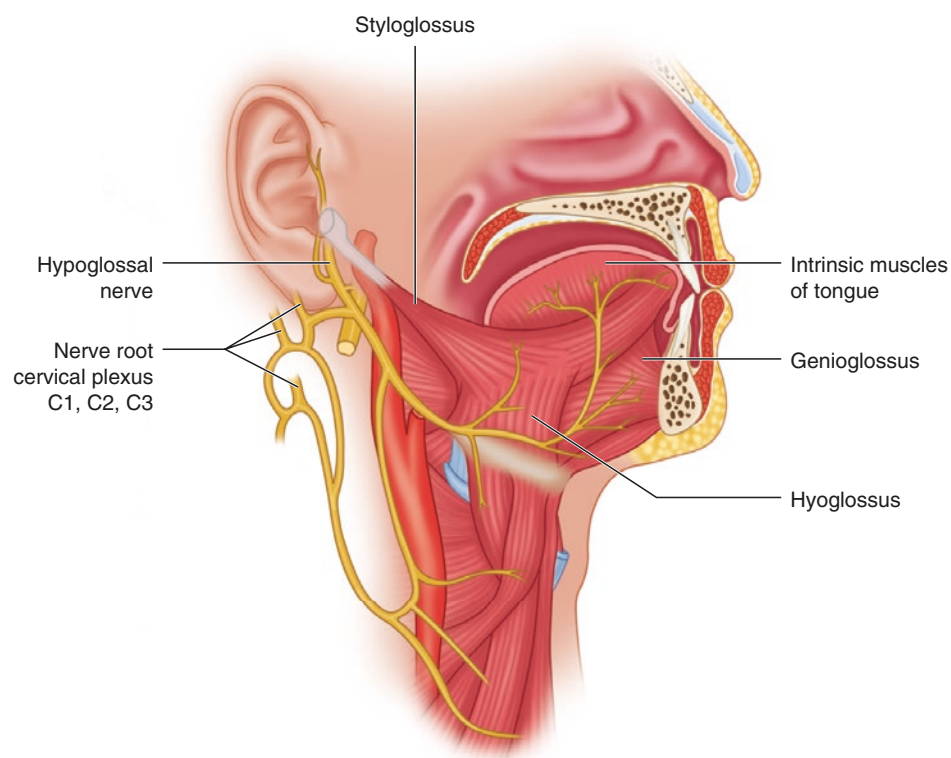
### Branches of the Subclavian Artery (Fig. 12.10)

Medial to the anterior scalene muscle, the subclavian artery gives off the following vessels:

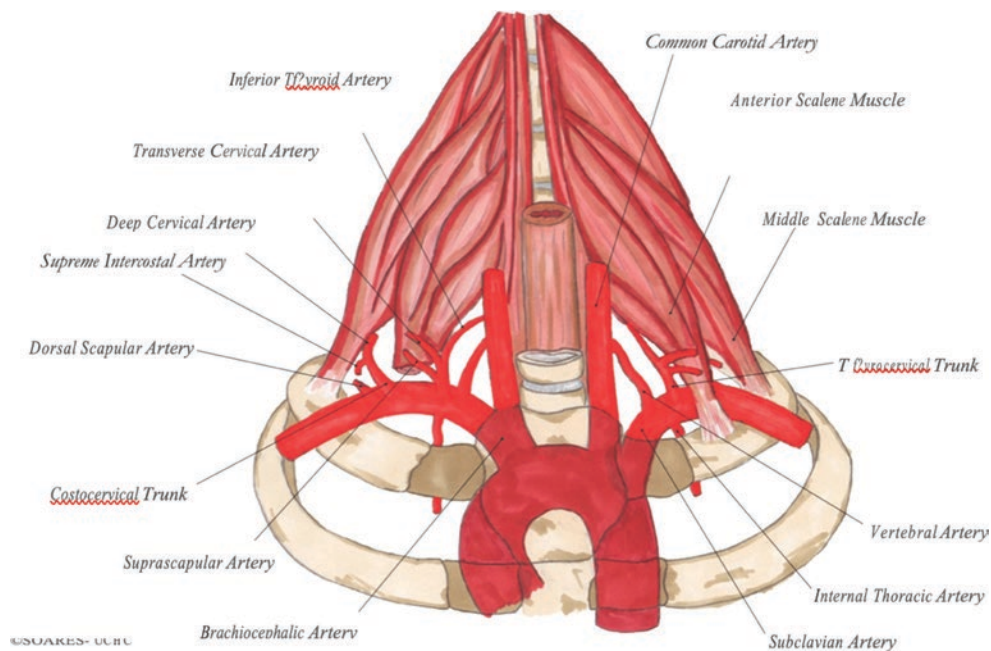
1. The *vertebral artery* ascends and disappears into the fascia covering the vertebral muscles and then enters the transverse foramen of vertebra C6, ultimately entering the skull through foramen magnum.
2. The *internal thoracic artery* descends into the thorax.
3. The *thyrocervical trunk* has three branches:
  - (a) The *inferior thyroid artery* that supplies the thyroid gland and adjacent muscles.



**Fig. 12.9** Lateral view:  
distribution of the hypoglossal  
nerve with connections to the  
cervical plexus



**Fig. 12.10** Anterior view:  
branches of the subclavian  
artery in the root of the neck



(b) The *suprascapular artery* passes anterior to the anterior scalene muscle, lateral to the brachial plexus, deep to the sternocleidomastoid muscle, and internal jugular vein. The suprascapular artery supplies the muscles posterior to the scapula.

(c) The *superficial cervical artery* arises superior to the suprascapular artery. This artery also passes anterior to the anterior scalene muscle, lateral to the brachial plexus, deep to the sternocleidomastoid muscle and internal jugular vein. It crosses the posterior triangle

and disappears beneath the trapezius. It supplies the trapezius and adjacent muscles.

Deep to the anterior scalene muscle, the subclavian has one branch, the *costocervical trunk*. The origin of this trunk is on the posterior surface of the subclavian artery. The costocervical trunk branches into the *supreme intercostal artery* and the *deep cervical artery*. The deep cervical artery passes between the transverse process of the C7 vertebra and the neck of the first rib to supply the muscles of the back of the neck.

Distal to the anterior scalene, the subclavian gives off the *descending scapular artery*. This artery passes through the brachial plexus, anterior to the middle scalene muscle and deep to the levator scapulae to supply muscles attached to the medial border of the scapula. Variations do occur. The superficial cervical and descending scapular arteries frequently have a common origin from the thyrocervical trunk called the *transverse cervical artery*. The transverse cervical has a superficial branch with the same distribution as the descending scapular artery.

## Carotid Artery Branches in the Neck

The *common carotid artery* bifurcates at the level of the hyoid bone into the internal and external carotid arteries. The *internal carotid artery* has no branches until it enters the cranial cavity. The *external carotid artery* has a number of important branches in the neck that are listed below.

The *ascending pharyngeal artery* is the first branch of the external carotid artery and usually the smallest. It arises just above the bifurcation of the common carotid from the medial side of the external carotid and courses superiorly, supplying the wall of the pharynx.

The second branch is the *superior thyroid artery*. It arises from the anterior surface of the external carotid artery and supplies the thyroid gland, larynx, and adjacent muscles.

The third branch, also from the anterior surface of the external carotid, is the *lingual artery*. It supplies the tongue and the floor of the mouth.

The fourth branch of the external carotid artery, also anterior, is the *facial artery*. It loops medial and superior to the submandibular gland before becoming subcutaneous on the lateral surface of the mandible. The facial artery has branches that supply the wall of the pharynx and the soft palate and tonsillar bed. It also supplies the submandibular salivary gland and gives off a submental branch that runs forward on the mylohyoid muscle. Other branches supply the muscles

and skin of the face. The facial and lingual arteries sometimes arise from the external carotid as a common trunk.

The fifth branch of the external carotid in the neck is the *occipital artery* that supplies the posterior scalp and the muscles along its course. It emerges from the posterior surface of the external carotid artery at the lower border of the posterior digastric muscle, is deep to the hypoglossal nerve, and disappears deep to the digastric. After the external carotid artery courses superiorly out of the neck, it gives off a *posterior auricular branch* and ends by forming *superficial temporal* and *maxillary arteries*. Please see Appendix 2 for a complete illustration of the external carotid artery and its branches.

## Carotid Body

- Mass of tissue in bifurcation of carotid artery.
- Chemoreceptor monitors oxygen levels in blood.

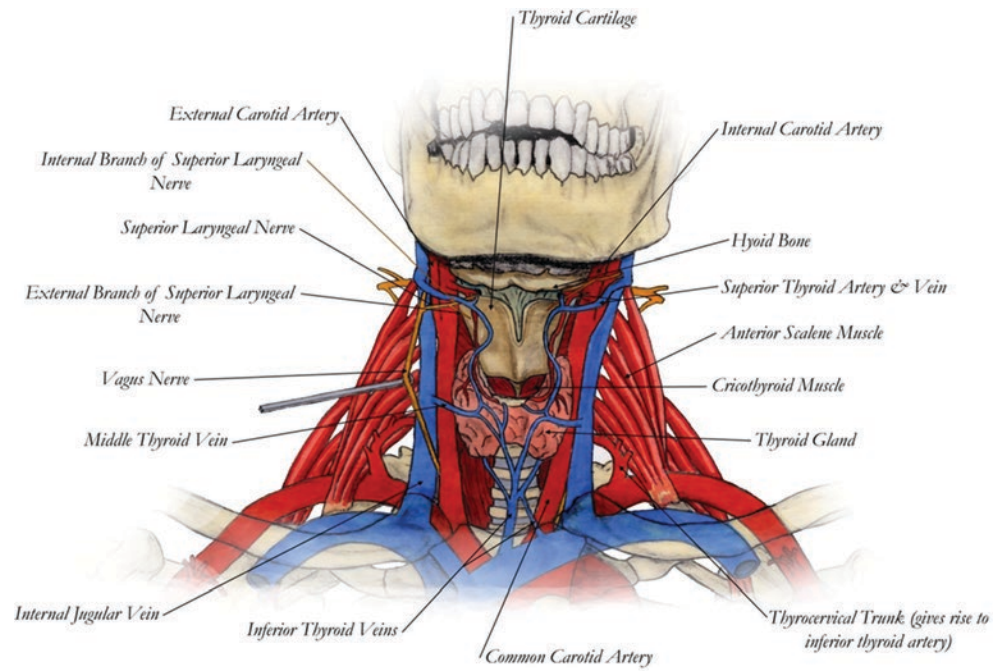
## Carotid Sinus

- Slight dilation of internal carotid artery
- Baroreceptor
- Responds to changes in arterial blood pressure

## Veins of the Neck

The veins of the neck (Fig. 12.11) are even more variable than the arteries. The *retromandibular vein* descends through the parotid gland posterior to the mandible. At the lower border of the jaw, it often divides into *anterior* and *posterior trunks*. The posterior trunk joins the *posterior auricular vein* to form the *external jugular*. The anterior trunk joins the *facial vein* to form the common facial which drains into the internal jugular. The external jugular vein located on top of the sternocleidomastoid muscle empties into the subclavian vein. The *subclavian vein* is anterior to the subclavian artery and is separated from the artery by the anterior scalene muscle. The *internal jugular vein* is medial to the sternocleidomastoid muscle. It joins the subclavian vein to form the *brachiocephalic vein*. The two brachiocephalic veins join to form the *superior vena cava*. The anterior jugular vein descends from the hyoid region anterior to the sternocleidomastoid muscle and passes between the sternocleidomastoid and the sternohyoid to join either the external jugular or the subclavian vein. Smaller and less predictable tributaries of the veins usually accompany the arteries.

**Fig. 12.11** Anterior view:  
veins of the neck



# Anatomy of the Superficial Face: Muscles of Face and Scalp, Superficial Vessels and Nerves, Major Salivary Glands

# 13

Christine E. Niekrash

The surface anatomy of the face, although highly variable in appearance, has several constant landmarks illustrated in Fig. 13.1.

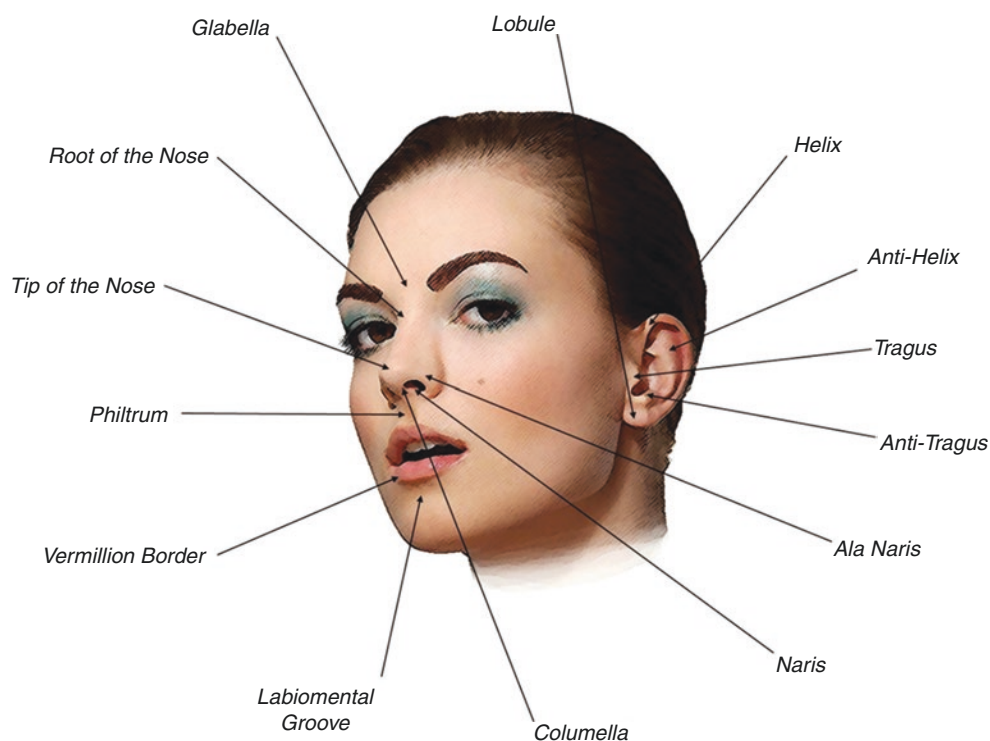## Muscles of Facial Expression

The muscles of facial expression are located in the subcutaneous tissue. They attach to fascia or bone and insert into the skin. When they contract, they produce the myriad of facial

expressions. All of the motor functions of the muscles of facial expression are supplied by the *facial nerve* (CNVII), with no exception. The full description of the facial nerve distribution can be found in Appendix 6 of this book. The facial nerve also supplies motor innervation to the stylohyoid, posterior belly of the digastric, and stapedius muscles.

The muscles of facial expression are difficult to dissect because they are small and insert directly into the skin to provide the complex movements involved with facial expressions. They may also be embedded with fat. Figure 13.2 dis-

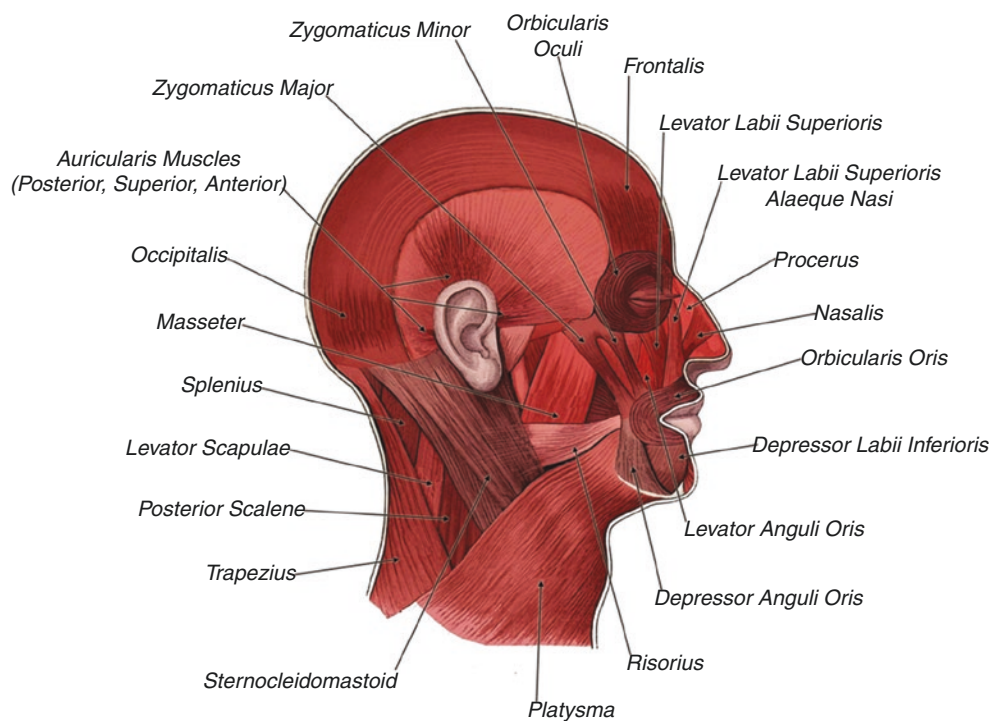
**Fig. 13.1** The surface anatomy of the face, although highly variable in appearance, has several constant landmarks illustrated in this figure



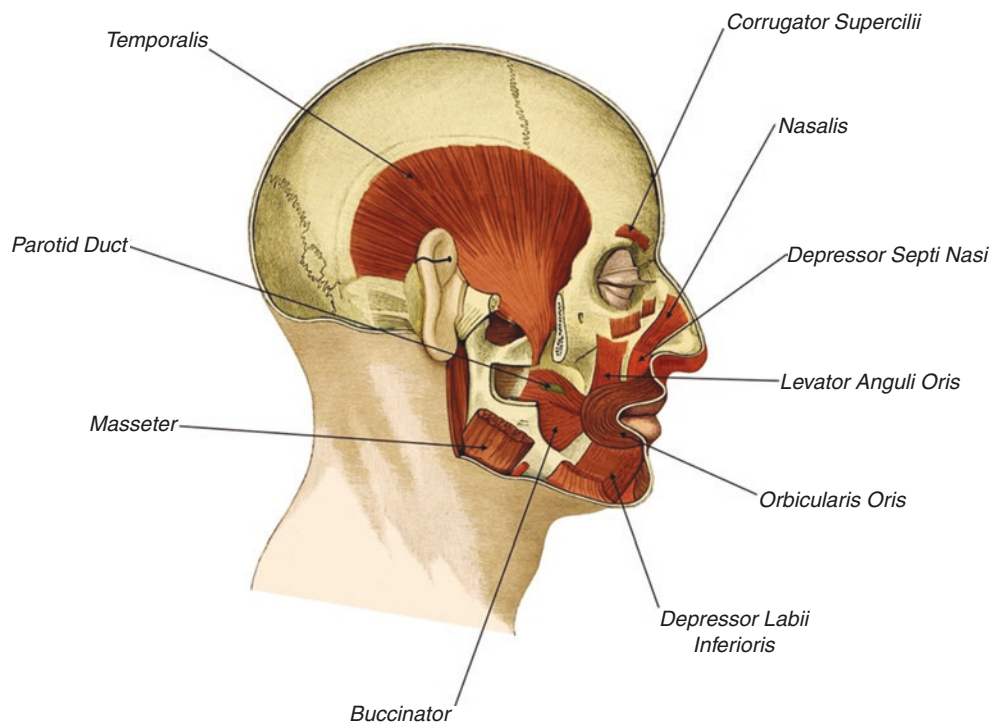
C. E. Niekrash (✉)  
Frank H. Netter MD School of Medicine, Quinnipiac University,  
Hamden, CT, USA  
e-mail: [christine.niekrash@quinnipiac.edu](mailto:christine.niekrash@quinnipiac.edu)



**Fig. 13.2** Lateral view: superficial muscles of facial expression, masseter, sternocleidomastoid, trapezius, posterior scalene, levator scapulae, and splenius muscles



**Fig. 13.3** Lateral view: deep muscles of facial expression, masseter (cut), temporalis (cut), and parotid duct



plays the muscles of facial expression. The deeper muscles are shown in Fig. 13.3.

The origins, insertions, and major functions of the muscles of facial expression are listed in the chart below.

Additional, more detailed descriptions of these muscles are provided in the specific anatomical region chapters. Please refer to Appendix 1, Relevant Osteology for descriptions and images of the bones.

<b><i>Occipitofrontalis:</i></b> Contains epicranial aponeurosis Occipitalis attaches posteriorly to superior nuchal line Frontalis inserts anteriorly into orbicularis oculi Functions to raise eyebrows and furrow skin of forehead Its position effects the position of the eyebrow	<b><i>Orbicularis oculi:</i></b> Arises from nasal part of frontal bone Attaches at frontal process of maxilla Courses beneath the skin of upper and lower eyelids Functions as sphincter of eye, voluntarily and involuntarily Mediates eye closure	<b><i>Zygomaticus major and minor:</i></b> Arises from anterior surface of zygomatic bone Inserts into corner of the mouth Pulls the angle of the mouth upward and laterally (smile) Zygomaticus major is located lateral to zygomaticus minor	<b><i>Depressor labii inferioris:</i></b> Arises from the mandible superior and medial to depressor anguli oris Inserts into muscle fibers of lower lip Depresses lower lip	<b><i>Mentalis:</i></b> Arises from the incisive fossa of the mandible Inserts into skin of lower lip and chin Raises and protrudes the lower lip, wrinkling skin of chin Contraction results in cobblestone chin
<b><i>Levator labii superioris:</i></b> Arises from lower margin of orbit above infraorbital foramen Inserts into muscles surrounding upper lip Raises and everts upper lip Infraorbital nerve lies deep to this muscle With aging, this muscle contributes to tear trough formation	<b><i>Levator anguli oris:</i></b> Arises from canine fossa Arises below the infraorbital foramen Inserts into corner of the mouth Raises the angle of the mouth	<b><i>Depressor anguli oris:</i></b> Arises from external oblique line of the mandible and below mental foramen Inserts into corner of mouth Pulls the angle of the mouth downward and laterally With aging, contraction causes Marionette lines to form	<b><i>Orbicularis oris:</i></b> Consists of intrinsic fibers encircling lips, combining fibers contributed by all muscles which insert in and around the lips Decussation ensures seal of lips Functions as sphincter of the mouth, compresses lips, protrudes lips Functions in speech and mastication	<b><i>Buccinator:</i></b> Arises from horizontal line above the alveolar process of maxilla, from external oblique line of mandible, and from pterygomandibular raphe Raphe extends from pterygoid hamulus to posterior end of mylohyoid line near third molar Fibers insert into corner of the mouth Presses cheek against the teeth, keeping food on biting surfaces When cheeks are distended, expels air trapped in the mouth (means trumpeter)
			<b><i>Platysma:</i></b> Arises from fascia covering upper parts of anterior chest muscles Fibers cross clavicle and insert into lower border of mandible, skin, and subcutaneous tissue of lower face and muscles around angle of the mouth Wrinkles skin of neck, may depress mandible and corners of the mouth	

With aging, wrinkles in the skin form perpendicular to the direction of muscle fibers and direction of force (Fig. 13.4).

<b><i>Levator labii superioris:</i></b> Arises from maxilla at the lower medial margin of orbit Inserts into alar cartilage of nose Dilates nostril	<b><i>Risorius:</i></b> Arises from parotid fascia Inserts at angle of the mouth Dilates mouth and depresses corner of mouth	<b><i>Alaeque nasi:</i></b> Originates from nasal bones Inserts into skin above glabella Depresses medial eyebrow Contraction creates horizontal lines between eyebrows	<b><i>Corrugator supercili:</i></b> Arises medially from nasofrontal suture Courses laterally and superficially Inserts into skin above superciliary arch Pulls eyebrows medially and inferiorly Forms vertical lines in between eyebrows
--	---	---	--

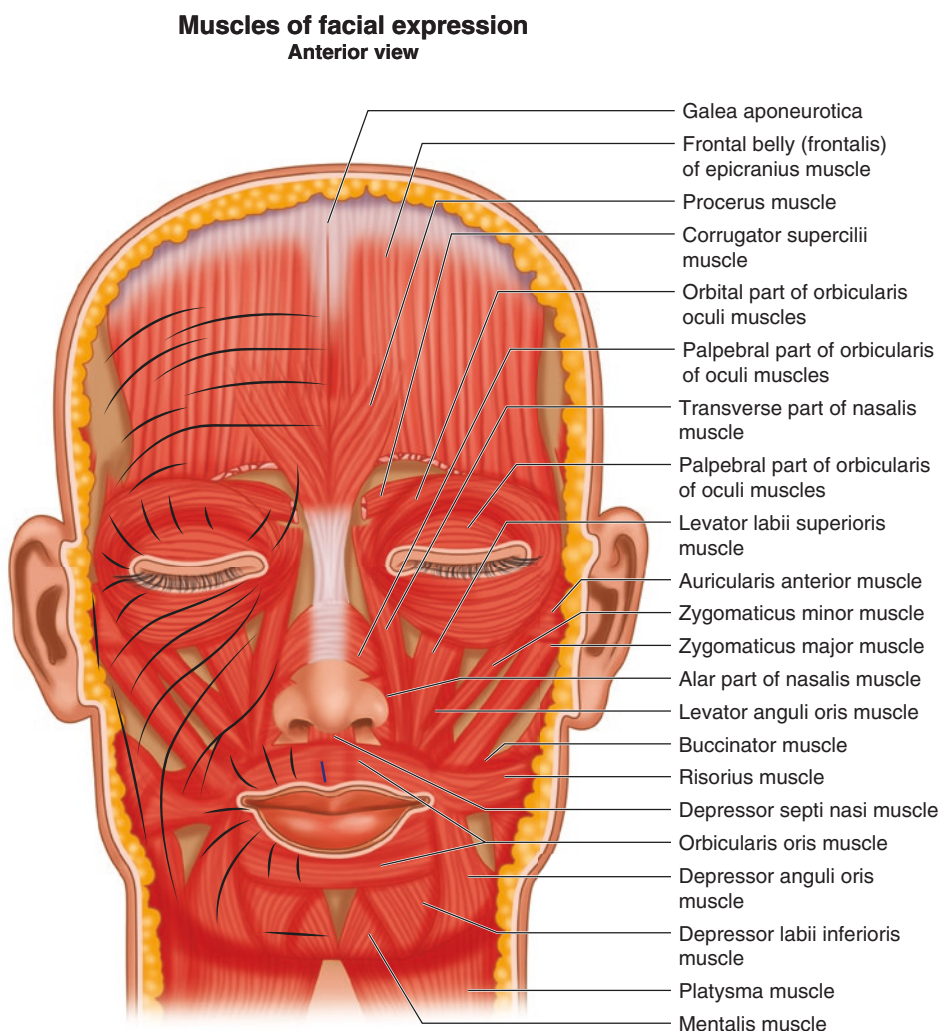
## Overview of Superficial Sensory Nerves of the Face

The complete distribution of the trigeminal nerve is explained in Appendix 5: Trigeminal Nerve. The description of the cervical plexus is found in Appendix 7: Cervical Plexus. The superficial sensory nerve fibers found in the face are described in the following (Fig. 13.5).

The *supraorbital branch* of the frontal branch of the ophthalmic division of the trigeminal nerve emerges from the supraorbital notch or foramen beneath the frontalis muscle. It supplies the skin of the forehead and much of the scalp, and it sends branches to the frontal sinus as well as to the conjunctiva of the eye.

The small *supratrochlear branch* of the frontal branch of the ophthalmic division of the trigeminal nerve supplies the skin medial to the eye and sends branches to the upper lid and forehead. It also sends branches to the conjunctiva of the

**Fig. 13.4** Location of wrinkles that form as a result of the contraction of the muscles of facial expression



eye. (One of the muscles of the eye makes a bend in the orbit, passing through a connective tissue loop called the trochlea. This nerve emerges above the attachment of the trochlea to the medial wall of the orbit.)

The tiny *infratrochlear branch* of the nasociliary branch of the ophthalmic division of the trigeminal nerve emerges below the trochlea and supplies the skin on the lateral surface of the nose and medial to the eye and sends branches to the conjunctiva and to the lacrimal sac.

A cutaneous branch of the *lacrimal branch* of the ophthalmic division supplies a small piece of skin over the lateral portion of the upper lid. It emerges beneath the lateral third of the orbital margin.

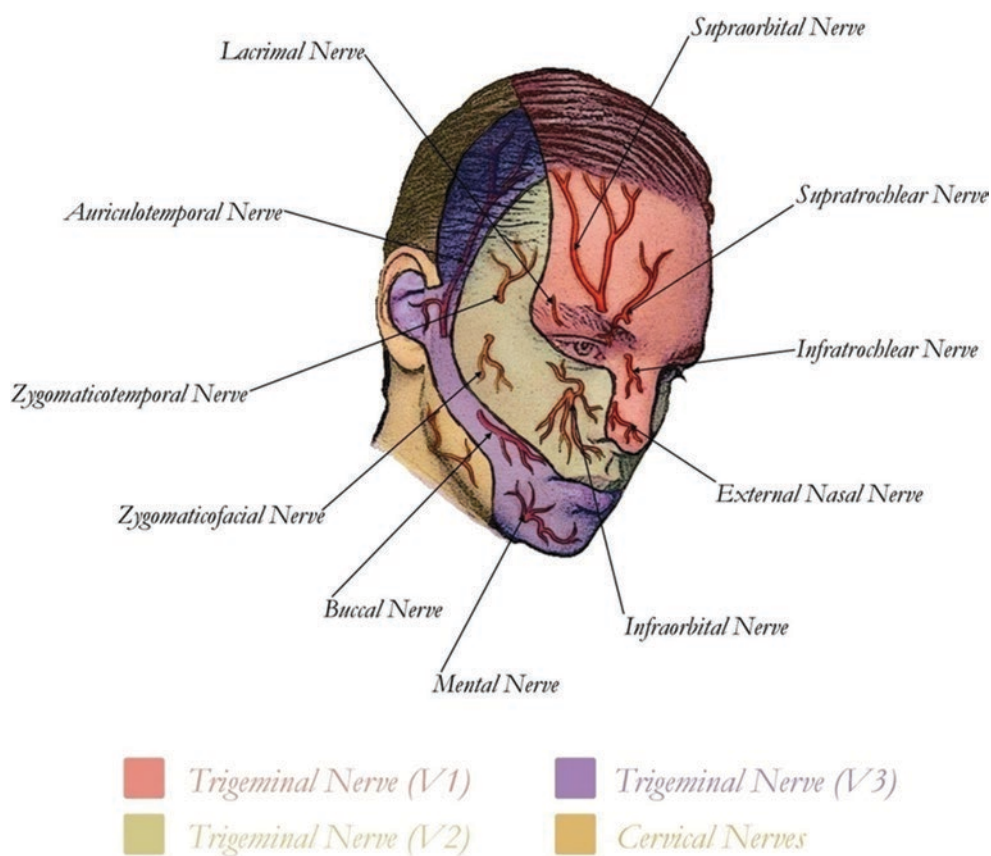
The small *external nasal* termination of the nasociliary branch of the ophthalmic division supplies the skin at the tip of the nose and the vestibule of the nose. It emerges at the lower edge of the nasal bone, between the bone and the cartilage forming the tip of the nose.

Hair-sized *zygomaticotemporal* and *zygomaticofacial* branches of the zygomatic branch of the infraorbital branch of the maxillary division of the trigeminal nerve supply the skin over the zygoma and the temple. They emerge through the lateral wall of the orbit through foramina with names the same as the nerves.

The terminal *infraorbital branch* of the maxillary division of the trigeminal nerve supplies the skin of the lower lid, middle face, upper lip, and lateral surface of the nose. It emerges from the infraorbital foramen deep to the levator labii superioris and superficial to the levator anguli oris muscles.

The *auriculotemporal branch* of the mandibular division of the trigeminal nerve supplies the skin over the temple, the skin surrounding the auditory canal, and the tympanic membrane. It also provides branches to the temporomandibular joint. It is accompanied by the superficial temporal artery and vein.

**Fig. 13.5** Superficial sensory nerves found in the face are illustrated. The origins of the nerves are indicated by the color of the region of the face in this drawing



The *buccal branch* of the mandibular division supplies the skin and oral mucous membrane overlying the buccinator muscle.

The *mental branch* of the mandibular division supplies the skin and oral mucous membrane of the lower lip. It emerges from the mandible through the mental foramen beneath the depressor anguli oris muscle.

The *great auricular nerve* is a cutaneous branch from the cervical plexus of nerves (see Appendix 7: Cervical Plexus). It ascends in the neck and provides sensation to the inferior auricle, and the skin is located over the angle of the mandible and parotid gland.

### Superficial Motor Nerves to the Muscles of Facial Expression

All of the muscles of facial expression are innervated by branches of the facial nerve (CNVII). The distribution of the facial nerve is described in Appendix 6. The superficial branches encountered in the face are described below. It is important to note that disruption of the facial nerve can result in the inability to close the eye, seal the mouth, and hemiparalysis of the face.

After a lengthy course through the facial canal in the temporal bone, the facial nerve emerges from the cranium

through the stylomastoid foramen, anterior and medial to the external ear. It immediately gives rise to the *posterior auricular branch* which courses posteriorly and superiorly behind the external ear between the parotid gland and the sternocleidomastoid muscle. It innervates the occipital portion of the occipitofrontalis muscle and the posterior external muscles of the ear. It also provides some sensation to the mastoid region and the posterior auricle. The motor fibers to the stylohyoid and posterior digastric muscles leave the trunk of the nerve lateral to the styloid process.

The main trunk of the facial nerve continues anteriorly through the parotid, dividing ultimately into five terminal branches. The most superior is the *temporal branch*. It leaves the superior portion of the parotid and course superficially over the zygomatic arch and innervates the superior portion of the orbicularis oculi, the frontalis portion of the occipitofrontalis muscle, and the anterior external muscles of the ear. Damage to this branch can result in paralysis of the forehead.

The *zygomatic branch* passes anteriorly on top of the masseter muscle to the region lateral and inferior to the orbit. Importantly, it supplies the inferior portion of the orbicularis oculi. Damage to this branch may result in an inability to close and protect the eye. This branch also innervates the muscles of facial expression just inferior to the orbit.



The *buccal branch* travels on the lateral surface of the buccinator muscle which it supplies and extends to the muscles controlling both lips including segments of the orbicularis oris. This nerve branches extensively anterior to the parotid gland, but lies beneath the parotid fascia.

The *mandibular branch* courses inferiorly and exits from the parotid gland lateral to the mandible and deep to the platysma over the angle of the mandible. It supplies the muscles of the chin and lower lip, including risorius.

The *cervical branch* travels inferiorly to supply the platysma.

Multiple anastomoses among the nerve branches create highly variable distributions.

## Overview of Superficial Vessels of the Face

Appendix 2: Major Blood Vessels of the Head and Neck contains a full description of the distribution of the blood vessels. The superficial branches are described below.

The *supraorbital* and *infraorbital* nerves are accompanied by arteries with the same names, terminal branches of the ophthalmic and maxillary arteries, respectively. Immediately anterior to the ear, and commonly buried in dense fascia, are the *superficial temporal artery* and *vein* accompanied by the *auriculotemporal nerve*. The superficial temporal artery is one of the terminal branches of the external carotid artery. The vein drains into the retromandibular vein. These vessels supply the tissues that overlie the temporalis muscle. The *transverse facial branch* of the superficial temporal artery lies parallel to and slightly below the zygomatic arch.

The *facial artery* (Fig. 13.6) and accompanying *vein* cross a notch in the lower border of the mandible anterior to the masseter muscle. It is located superficially just beneath the platysma. The pulse can be felt in this artery at this location. The facial artery is a branch of the external carotid, and the accompanying vein drains into the internal jugular vein after joining a branch of the retromandibular vein. The facial artery courses tortuously and superiorly, crossing superficial to the buccinator and levator anguli oris, deep to the zygomatic major, and usually deep to the levator labii superioris ending on the lateral surface of the nose. It has a *submental branch* (under the floor of the mouth), *superior* and *inferior labial branches* to the upper and lower lips, and a *lateral nasal artery* to the side of the nose. The facial artery terminates as the angular artery after it gives off the lateral nasal artery.

## The Major Salivary Glands

Although there are many small salivary glands scattered throughout the oral cavity, there are three paired major sali-

vary glands: parotid, submandibular, and sublingual. The major functions of saliva are listed below.

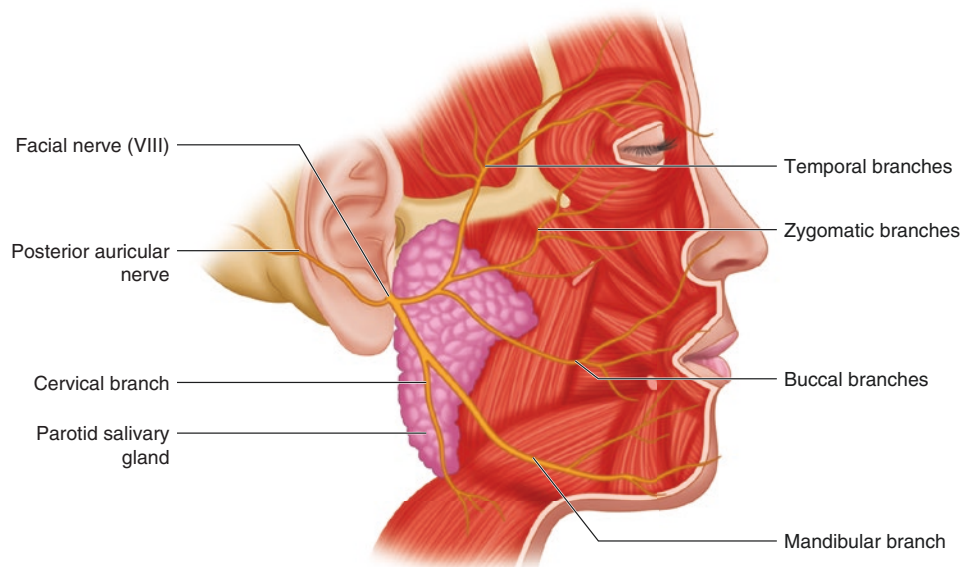
### Functions of Saliva

- *Protection*
  - Lubrication
  - Mechanical washing
  - Forms pellicle
- *Buffering*
  - Maintains pH
  - Neutralizes acids
- *Digestion*
  - Forms bolus
  - Digests starch
- *Taste*
  - Dissolves substances
- *Antimicrobial function*
  - Mucus barrier
  - Antibacterial proteins
  - Antibodies
- *Maintenance of tooth integrity*
  - Enamel maturation
  - Remineralization

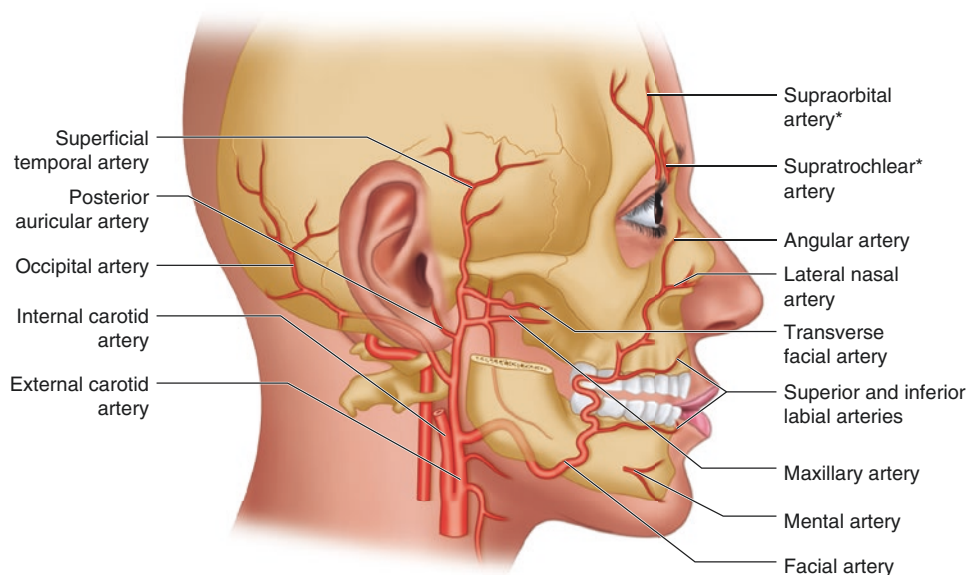
### Parotid Gland

The parotid gland is the largest of the major salivary glands, has a complex shape, contains significant adipose tissue, and is enclosed within a capsule. It lies both superficial to and behind the posterior mandible and anterior and below the external auditory meatus. The secretory glands of the parotid are serous and they empty into the mouth via the parotid (*Stenson's*) *duct*, located in the buccal mucosa opposite to the maxillary second molars. The duct courses anteriorly across the lateral surface of the masseter muscle and then travels medially through the buccinator muscle. The bed of the parotid is formed posteriorly by the mastoid process and the anterior border of the sternocleidomastoid muscle. Anteriorly, the posterior border of the ramus of the mandible, the masseter, and medial pterygoid muscles are beneath the parotid gland. Superiorly, the capsule of the temporomandibular joint and the tympanic portion of the temporal bone compose the bed. The stylohyoid and digastric muscles form the inferior boundary. Medially, the styloid process, the muscles arising from it, and the fascia extending from the styloid process to the posterior border of the ramus form the bed for the gland. Processes from the body of the gland extend between the ramus and the medial pterygoid muscle, between the tympanic portion of the temporal bone and the capsule of

**Fig. 13.6** Lateral view:  
distribution of the facial nerve  
branches



**Fig. 13.7** Lateral view:  
major branches of the external  
carotid artery



the temporomandibular joint, medially, anterior to the carotid sheath, and on the face over the neck of the condyle, the temporomandibular joint, and the masseter muscle.

The trunk of the facial nerve is embedded within the parotid gland and the superficial branches emerge from the gland as shown in Fig. 13.6 and in Appendix 6 (Facial nerve, CN VII). Also, the external carotid artery and the retromandibular vein are found within the gland. The sensory innervation

to the gland and the skin overlying it is from the auriculotemporal nerve (a branch of the mandibular division of the trigeminal nerve, Appendix 5) and the great auricular nerve (from the Cervical Plexus, Appendix 7). The parasympathetic fibers originate in the glossopharyngeal nerve (CN IX) and course to the otic ganglion where the fibers synapse. The postganglionic fibers travel to the parotid gland via the auriculotemporal nerve.

## **Submandibular Gland**

The submandibular gland is located inferior and medial to the mandible. It has a capsule and secretes both serous and mucus saliva. The gland empties via ducts of the submandibular gland (Wharton's duct) into the anterior floor of the mouth. The gland may be palpated when the patient presses his tongue against the upper incisor teeth. The parasympathetic fibers originate in the facial nerve (CN VII, Appendix 6) through the chorda tympani to join the lingual nerve of the mandibular division of the trigeminal nerve and travel to the submandibular ganglion where they synapse and distribute to the submandibular gland.

## **Sublingual Gland**

The sublingual salivary glands are the smallest of the paired major salivary glands, the most variable in appearance, and not in a capsule. It is a primarily mucus-secreting gland that opens into the floor of the mouth through a series of small ducts. The parasympathetic innervation pathway is the same as to the submandibular gland.

# Muscles of Mastication and the Temporomandibular Joint

# 14

Christine E. Niekrash

The muscles of mastication cause movements of the mandible and the temporomandibular joint. These movements are important in eating, swallowing, speech, and respiration. The masseter, temporalis, lateral pterygoid, and medial pterygoid are all derivatives of the first pharyngeal arch and are innervated by branches of the mandibular division of the trigeminal nerve (CNV). Appendix 5: Trigeminal Nerve provides the full distribution of this nerve. The muscles of mastication are listed below with their origin, insertion, and major functions. Figure 14.1 illustrates the location of the masseter and temporalis muscles. Figure 14.2 shows the position of the medial and lateral pterygoid muscles.

## Masseter

- Large superficial portion, smaller deep portion
- Arises from anterior two-third of the lower border of zygomatic arch
- Inserts into the angle and lower half of the lateral surface of the ramus of the mandible
- Innervated by a branch of the mandibular division of the trigeminal nerve
- Functions as the most powerful elevator of the mandible

## Temporalis

- Arises from the temporal fossa (bounded by the temporal lines) and the deep surface of the temporal fascia
- Tendinous insertion on the coronoid process and the anterior border of the ramus of the mandible as far inferiorly as the distal molar tooth

- Innervated by branches of the mandibular division of the trigeminal nerve
- The thicker anterior portion of the muscle with nearly vertical fibers, functions to elevate the mandible
- The thinner posterior portion with horizontal fibers, acts to retrude the mandible after it has been protruded by the lateral pterygoid muscles

## Medial Pterygoid

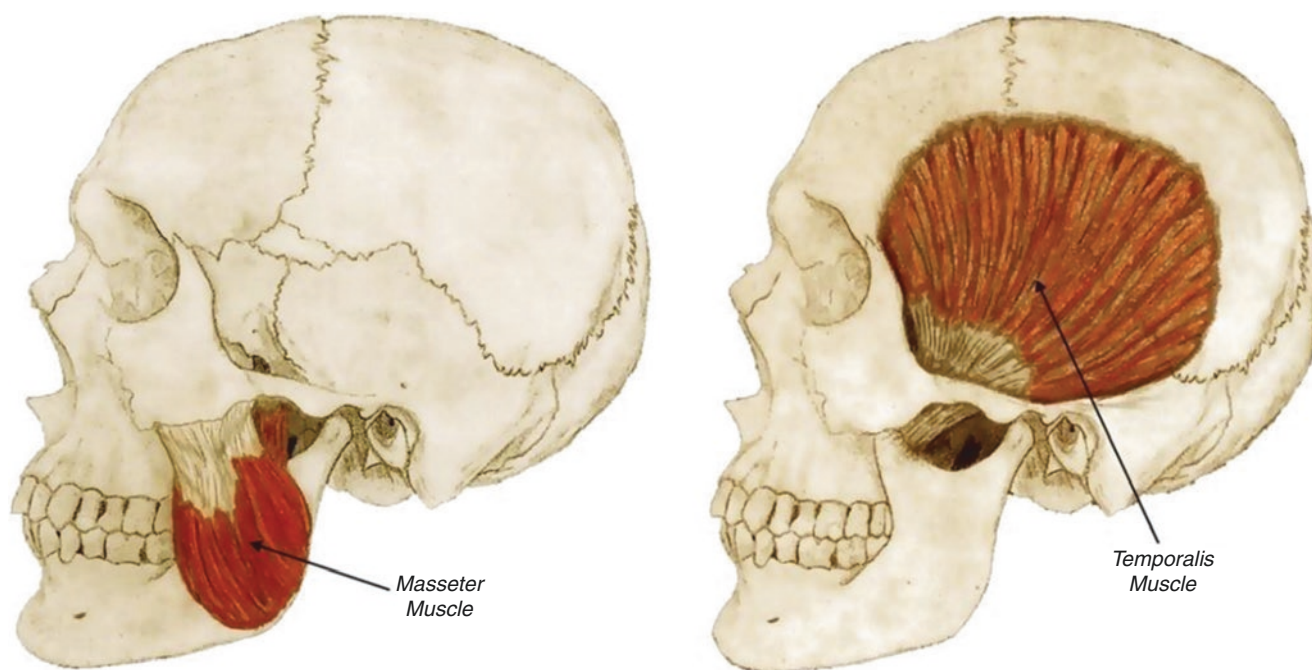
- Arises from medial surface of lateral pterygoid plate and often from the tuberosity of the maxilla
- Inserts on lower half of the medial surface of the ramus and angle of the mandible
- Fibers approximately parallel to masseter fibers
- Innervated by mandibular division of V
- Functions to elevate the mandible

## Lateral Pterygoid

- Upper head arises from infratemporal surface of greater wing of sphenoid
- Lower head arises from lateral surface of lateral pterygoid plate
- Inserts into anterior surface of neck of condyle and into the articular disc
- Acts to protrude or open the mouth when the muscles of the two sides act together
- Moves chin toward opposite side when only one muscle contracts

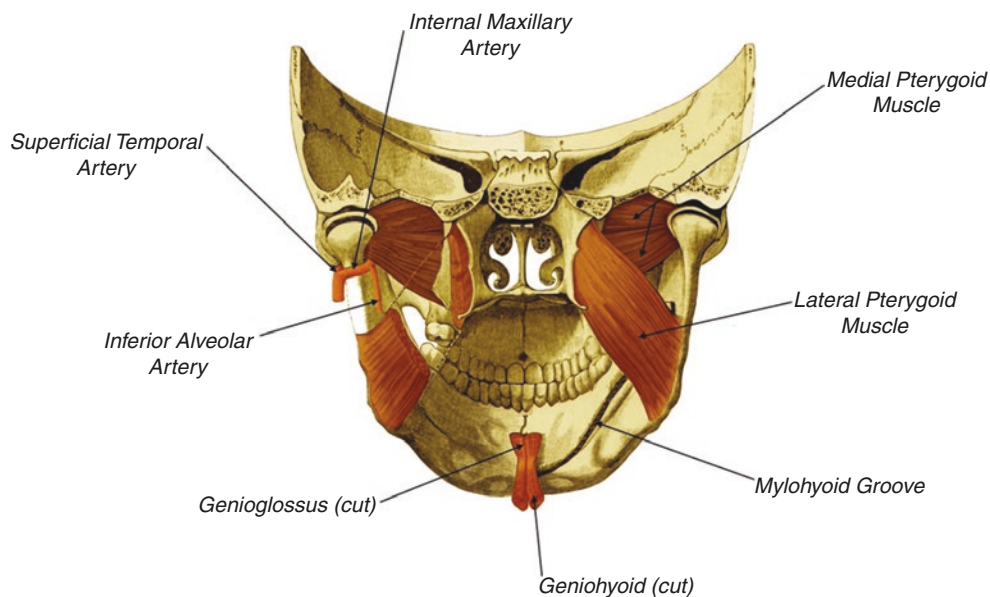
C. E. Niekrash (✉)  
Frank H. Netter MD School of Medicine, Quinnipiac University,  
Hamden, CT, USA  
e-mail: [christine.niekrash@quinnipiac.edu](mailto:christine.niekrash@quinnipiac.edu)





**Fig. 14.1** Lateral view, masseter and temporalis muscles

**Fig. 14.2** Posterior, coronal view: location of medial pterygoid and lateral pterygoid muscles



### Innervated by mandibular division of trigeminalThe Temporomandibular Joint

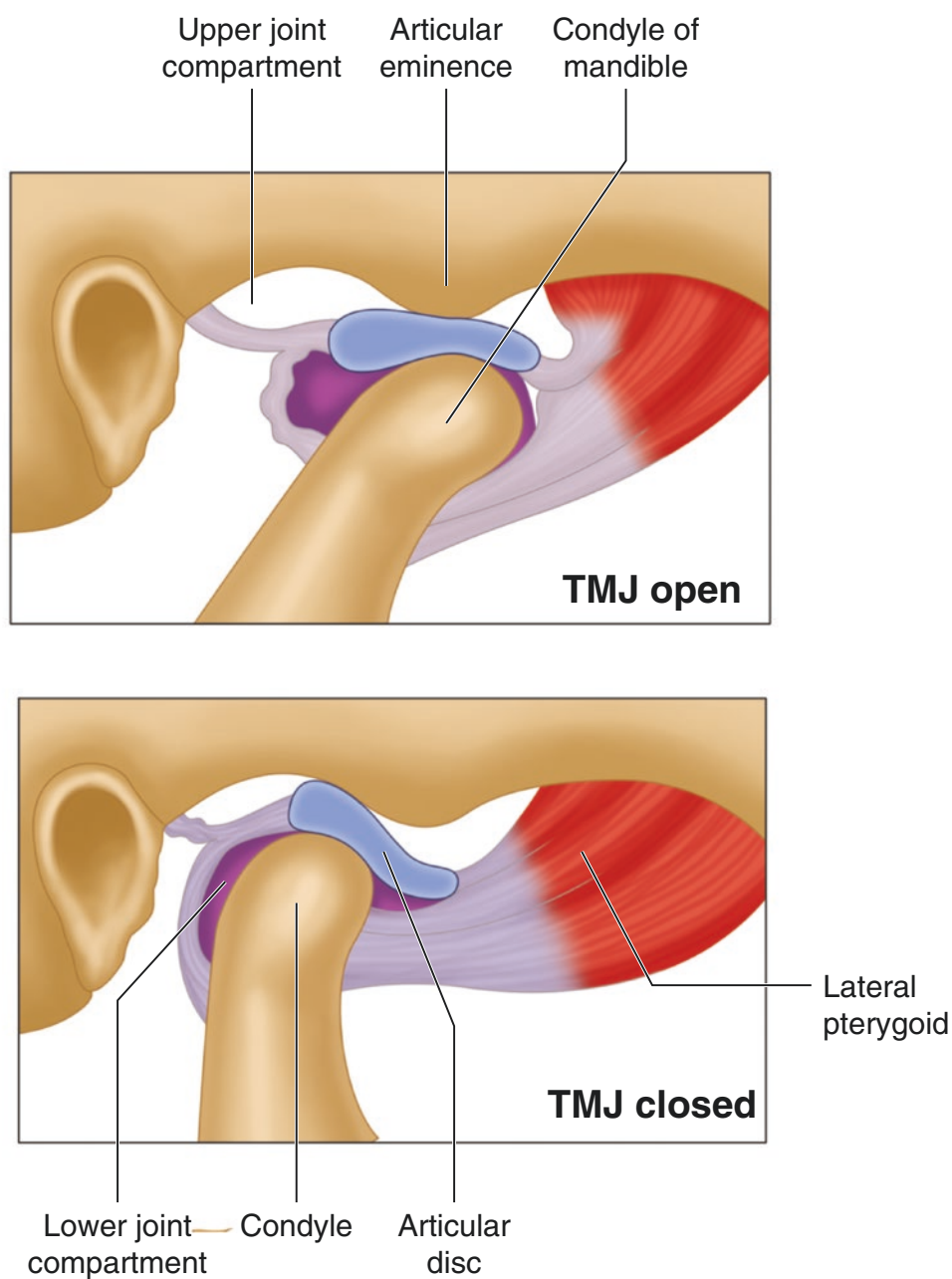
#### Articular Fossa

The temporomandibular joint is formed by the *articular (mandibular) fossa* of the temporal bone, the *articular eminence* anterior to the fossa on the inferior surface of the

zygomatic arch, and the head of the condyle of the mandible. The lateral end of the articular eminence may be accentuated to form an articular tubercle (Fig. 14.3).

Dense connective tissue forms the *capsule* of the joint. The capsule is attached above to the *post-glenoid lip* in the articular fossa and anteriorly to the anterior surface of the articular eminence. Below, the capsule is attached to the neck of the condyle. Its lateral surface is thickened to

**Fig. 14.3** Lateral view, temporomandibular joint with mouth open (superior image) and mouth closed (inferior image)



form the *temporomandibular ligament*. This ligament is attached anteriorly and above to the articular tubercle, and posteriorly and below to the posterior surface of the neck of the condyle. It limits posterior movement of the condyle, protecting the relatively soft tissues that occupy the posterior half of the articular fossa.

The temporomandibular joint is divided into two compartments by the dense fibrous tissue of the *articular disc*. Simple rotational movements occur in the lower compartment. Since the disc is rather tightly attached to the head of the condyle, sliding motions occur in the upper compartment to allow full opening of the mouth.

---

## Part III

# Surgical Anatomy

Elie M. Ferneini

Beau Visage Med Spa, Greater Waterbury OMS,  
Cheshire, CT, USA

Division of Oral and Maxillofacial Surgery,  
University of Connecticut School of Dental Medicine,  
Farmington, CT, USA

Department of Surgery, Frank H Netter MD  
School of Medicine, Quinnipiac University, Hamden, CT, USA

## Introduction

One of the greatest cosmetic concerns among patients is the aging face and facial rhytids. The aging process is affected in several ways by both intrinsic and extrinsic variables. Intrinsic factors include genetics, loss of soft tissue volume, skeletal changes affecting the foundation of the face, and muscle activity/overactivity of the muscles of facial expression. Extrinsic factors include photodamage (sun tanning and tanning salons), gravity, alcohol consumption, and smoking. Many of the variables can be treated, but typically require multiple modalities and often require staging for optimal results. Treating wrinkled skin requires not only resurfacing the skin (i.e., chemical peels, lasers, Intense Pulse Light, Broad Band Light, dermabrasion, etc.), but also the underlying tissues including the muscles of facial expression.

Facial rhytids are one of the most common complaints that are treated with regard to aging. The activity of the muscles of facial expression may contribute to deep furrowing of the skin both in dynamic appearances as well as static. Consequently, the treatment of facial rhytids with Botulinum toxin type A (BTX-A) is the most frequent minimally invasive procedure performed each year in the United States. An estimated 7.2 million BTX-A procedures were performed in 2017. This procedure continues to grow in popularity and has risen over 800% since the year 2000 [1]. This is over four times more popular than all of the cosmetic surgeries performed in a year combined!

Botulinum toxin was initially approved in the United States by the FDA in 1989 for the treatment of ophthalmological conditions including strabismus and blepharospasm [2–4]. Subsequent to these indications, it was later discovered that concomitantly, patients had improvement of facial rhytids in

the glabellar region [5, 6]. In 2002, BTX-A was approved for the temporary improvement in the appearance of moderate-to-severe glabellar lines in adults [7]. As of writing this chapter, the specific indications for cosmetic use per the FDA and manufacturers include the treatment of rhytids in the glabellar, forehead, and lateral canthal regions [7]. Dysport (AbobotulinumtoxinA), Xeomin (incobotulinumtoxinA), and Jeuveau (prabotulinumtoxinA-xvfs) are approved for the treatment of moderate-to-severe glabellar lines [8, 9]. Botox® owns 65% of the market share and this represents 3.17 billion dollars in annual revenue for Allergan [10].

## Pharmacology of Botulinum Toxin

There are seven different exotoxins produced by the bacteria, *Clostridium botulinum*. The most commonly used toxins are types A and B (the others are labeled C through H). Type A is in fact the most potent of the various toxins and is the most common cosmetic botulinum toxin used today. Type A toxin is composed of a heavy chain (100-kDa) and a light chain (50-kDa). The mechanism of action has been elucidated by Huang et al. [11]. The heavy chain binds to the membrane of the neuron. Upon binding to the membrane, the toxin is moved intracellularly via endocytosis. The light chain then degrades a protein (SNAP-25) that prevents acetylcholine, stored intravesicularly, from binding to the nerve cell's membrane, and thus being released into the synaptic cleft or gap. The affected nerve is rendered dysfunctional and a flaccid paralysis of the muscle results. Type B botulinum toxin works in a similar fashion but affects a different cellular protein, similar to SNAP-25. Most patients will begin to notice the clinical effects of BTX-A a few days after treatment, but the full clinical affect may take up to 10–14 days.

The nerve cell begins to recover several weeks after treatment. The exact mechanism of recovery has still not been elucidated [12]. In the interim, the presynaptic membrane sends out new dendritic processes that establish a new synap-

M. Goldschmidt (✉)  
Private Practice, Independence, OH, USA

J. B. Clemow  
Metrohealth Medical Center, Cleveland, OH, USA



tic terminal. The new processes are able to release acetylcholine and affect the motor end plate until the original neurons regain their actual function. Accordingly, the clinical affect ends when the original neurons have regained their function. For most patients, the resulting affect will last roughly 3 months. Some patients who undergo years of BTX-A treatment may derive longer affects, but this is certainly not consistent nor the anticipated result of repeated therapy [11]. BTX-B lasts less than BTX-A and most patients will have a duration of action around 6–8 weeks.

## BTX-A and BTX-B Production

There are four main corporations that produce BTX-A in the United States: Merz (Xeomin), Galderma/Medicis/Tercica (Dysport), Evolus (Jeuveau), and Allergan (Botox). Xeomin is supplied in either 50- or 100-unit vials. Dysport (aibobotulinum toxin) is supplied in either 300- or 500-unit vials. In addition, 125 mcg of albumin and 2.5 mg of lactose are compounded with the botulinum toxin and may cause sensitivity in patient allergic to milk protein. Jeuveau is supplied in 100-unit vials, and Botox is supplied in either 50- or 100-unit vials. There are 0.25 mg of human albumin and 0.45 mg of sodium chloride in each 50-unit vial (there is 0.5 mg and 0.9 mg, respectively, in a 100-unit vial). All three of these products are derived from the fermentation of Hall strain *Clostridium botulinum* serotype A. The preparation and assay method for each of these products is unique. Thus, the potency of each product is difficult to compare to identify relative strengths of each toxin. Xeomin is the only preparation that does not include or compound any additional proteins when it is supplied. The significance of the lack of the accessory proteins (or presence) is not known.

Myobloc (rimabotulinumtoxin) is manufactured by Solstice Neurosciences, Inc. and is supplied in 3.5-mL glass vials. Each single-use vial of formulated Myobloc contains 5000 Units of botulinum toxin type B per milliliter in 0.05% human serum albumin, 0.01 M sodium succinate, and 0.1 M sodium chloride at approximately pH 5.6. The neurotoxin is produced by fermentation of *Clostridium botulinum* type B (Bean strain) [13].

There are several other formulations that are currently in FDA trials that promise increased longevity of the medications. These formulations have not been made available to the public nor have the details regarding their clinical profile or pharmacodynamics, etc. been revealed.

## Dilution Technique

Allergan specifies that Botox should be reconstituted with 2.5 mL of preservative-free saline. Jeuveau has the same dilution recommendation as Botox. In both cases, this yields

4 units of BTX-A per 0.1 cc. Dysport and Xeomin do not recommend a specific dilution but does recommend reconstituting the product with preservative-free saline as well. All manufacturers recommend single patient usage, administration within 24 hours, and storage between 2 °C and 8 °C. Off-label reconstitution may include addition of local anesthetic (most commonly lidocaine), epinephrine to reduce bruising, and sodium bicarbonate to reduce the discomfort of the injection. One study suggested increased longevity when lidocaine with epinephrine was used in part to reconstitute BTX-A [14].

## Indications/Contraindications/Adverse Events

Botox is indicated for the temporary improvement of moderate-to-severe glabellar lines from the procerus and corrugator muscles, forehead lines from the frontalis muscle, and lateral canthal lines (“crow’s feet”) associated with the orbicularis oculi muscle [7]. Dysport, Xeomin, and Jeuveau have indications for the treatment of glabellar lines only [8, 9].

Non-cosmetic indications of Botox include cervical dystonia in adults to decrease the severity of abnormal head position and neck pain. It is also indicated in patients with strabismus, blepharospasm, headache, and Bell’s Palsy. Botox is also used in the treatment of axillary hyperhidrosis. Dysport is indicated for the treatment of lower limb spasticity and cervical dystonia. Xeomin has additional indications for upper limb spasticity and blepharospasm in patients previously treated with Botox. Myobloc has indications for the treatment of cervical dystonia as well [7–9, 11]. There are other known uses of these products including hypersecretory syndromes, back pain, and writer’s cramp. Jeuveau touts the distinction of being the only neurotoxin dedicated exclusively to esthetics.

The use of BTX-A for cosmetic purposes is not limited to the strict adherence to the indications listed above. Many practitioners regularly treat all the muscles of facial expression and are proficient in obtaining consistent results for facial rejuvenation. This is considered an “off-label” use of this drug.

## Adverse Effects of BTX-A Treatment

The most common adverse effects reported by the manufacturers include the following: headache (9%), nasopharyngitis (4%), eyelid ptosis (3%), brow ptosis (2%), facial pain (1%), eyelid edema (1%), muscular weakness including spread to adjacent sites (1%), injection site pain (less than 1%), hematoma (less than 1%), infection (less than 1%), nausea (less than 1%), syncope (less than 1%), sinusitis (less than 1%), rhinitis (less than 1%), and upper respiratory infection (less than 1%) [7–9, 11].

A firm understanding of the facial anatomy and proper injection technique will aid in avoiding some of these problematic consequences—especially affecting adjacent muscles. The use of devices that help visualize the venous anatomy may also help reduce intravenous injection and trauma to those same vessels. This helps reduce the risk of hematoma and subsequent ecchymosis. Also, having patients avoid anti-inflammatory medications and anticoagulants also reduce the rise of these phenomena. Arnica Montana and Bromelain can also be used in the peri-procedure period to further reduce the risk as well [15, 16].

## Injection Technique

### 1. Dosing

The various formulations of BTX-A by the manufacturers preclude the ability to standardize dosing between the proprietary drugs. Each BTX-A formulation must be considered individually when used to achieve optimal outcomes. Trying to convert units of BTX-A between the corporations should be avoided (e.g., 3 units of product X equals 1 unit of product Y). In addition, there are several variables that need to be considered when treating patients. First, men may have greater muscle mass and, consequently, may need higher doses to achieve a similar effect versus female patients. Second, the facial musculature may have significant variability between patients and each patient needs to be evaluated for proper dosage. Third, the degree of paralysis requested by patients may be variable. Some patients prefer absolute immobilization of various muscle groups (especially the forehead), while others would like to “soften the wrinkles” and may benefit from lower doses to preserve various facial expressions.

### 2. Anatomic Sites and General Dosage Ranges

The glabellar region is the only site approved by the FDA for all four manufacturers of BTX-A. The glabellar muscle groups (corrugators, procerus, depressor supercilii, and orbicularis oculi) create the vertical and horizontal furrows in this region. Allergan and Evolus recommend the use of 20 units with five injection points (4 units per site) injected as follows: two injections into each corrugator muscle (paired muscle group) and one injection into the procerus. Dysport should be injected in a similar fashion using 10 units per site for a total of 50 units. Xeomin is injected in a similar manner as Botox [7–9, 11].

In all cases, it is recommended to inject at least 1 cm away for the supraorbital rim and to inject perpendicularly to the muscles treated.

The frontalis muscle is the primary brow elevator and is solely responsible for the horizontal furrows across the forehead. The recommended dose to reduce the activity of this muscle is 20 units. In a similar fashion to the treatment of the glabellar region, the frontalis should be injected in five sites (4 units per injection site). When injecting above the eyebrow, it is important to stay at least 2 cm cephalad to the eyebrow to reduce the risk of brow ptosis. In the author’s personal experience, using lower doses (1 unit per injection site) and more sites (8–10 sites) tends to produce a more uniform effect and also reduces the risk of brow ptosis.

The crow’s feet region or lateral canthal rhytids are the result of contraction of the orbicularis oculi muscles. Squinting or smiling cause the orbicularis oculi to constrict in a sphincter-like fashion. This results in horizontal rhytids that extend in a radial fashion laterally from the lateral canthal region. Allergan recommends three injection sites (4 units per injection—12 units total per side) staying at least 1 cm away from the orbital rim to reduce the risk of intra-orbital migration affecting the extra-ocular muscles (lateral rectus and inferior oblique muscles). Diplopia may result from intra-orbital migration if these muscles were affected. In addition, injecting too much along the inferomedial aspect of the orbicularis may result in cheek ptosis as this aids in cheek elevation. Patients with laxity of the lower eyelid may experience ectropion or lower lid retraction. Patients with some orbital fat prolapse may exhibit worsening of their condition if the orbicularis oculi is weakened and loses some of its tone.

## Chemical Brow Lift or Brow Elevation

Conceptually, brow elevation is achievable when segments of the orbicularis oculi and glabellar region are chemically denervated. Weakening the central portion of the frontalis may also result in increased activity in the frontalis directly cephalad to the brows. This can also be an untoward effect some patients may not like especially if it is unilateral (“Mr. Spock” appearance). By injecting the glabellar region and affecting the medial brow depressors (procerus, corrugators, medial orbicularis oculi) along with the central aspect of the frontalis will allow the medial brow to elevate. Patients who depress their brows (laterally) when they smile may also be injected in the lateral canthal region. Injections toward the tail of the brow in this situation will allow the lateral portion of the brow to elevate. In all of these scenarios, injecting the frontalis over the brow region should be avoided so as not to negate the effects of reducing the brow depressors. Additionally, injection in the eyebrow itself should be done cautiously to help relax the orbicularis oculi in this region. Injecting deep in this region can lead to brow and eyelid pto-

sis and only 0.5–1 unit should be injected in a couple of sites along the brow.

## Bunny Lines

The nasalis muscle runs transversely across the nasal dorsum. When activated it leads to diagonal furrows along the lateral aspect of the dorsum. Superiorly to this muscle is the procerus and when this muscle is activated it leads to more horizontal furrows. These are two distinct anatomic sites and as such need to be treated independently. When the nasalis muscle is injected, it should be done superficially and along the maxillary process of the nasal bones. Injections deep and along the maxilla could result in inadvertent injection of the angular artery or hematoma. This also helps prevent BTX-A affecting the levator labii oris and the levator labii alaeque which could result in the upper lip drooping or an asymmetric smile [5].

## Mentalis

Patients with strong or hypertrophied mentalis muscles may exhibit unattractive dimpling of the chin, especially in combination with loss of subcutaneous tissue (*peau d'orange*). Sometimes the activity can also lead to noticeable horizontal furrow across the same region. Five to ten units of Botox may be injected (20–30 units of Dysport) into the superficial aspect of the mentalis. Caution should be taken to not over-inject, inject too superiorly, or inject deeply as this could possibly affect the lower lip and oral competency. Some patients may present with hypertrophied mentalis muscles, retrognathia, and oral incompetence and should not be treated with BTX-A in the chin region. Injecting toward the midline will also reduce the possibility of injecting the depressor labii and/orbicularis oris as this can lead to drooling, drooping of the lower lip, and/or an asymmetric smile.

## Platysmal Bands

Platysmal bands can be seen in the aging neck and may be seen as a residual effect after rhytidectomy. They can be easily treated with BTX-A. The patient can easily exhibit the bands by clenching their teeth and showing the lower anterior teeth. Patients with skin laxity are better candidates for neck lift with platysmaplasty. Patients with significant laxity of skin will have modest results and likely be displeased. The bands are injected just below the inferior border of the mandible and injected every centimeter along the band. Typically, 20 units of Botox may be used to treat this anatomic region. The best way to inject the band is to grasp the band with the

non-injecting thumb and index finger to isolate the muscle band. Over injection in the neck and diffusion to the strap muscles can lead to significant problems including postural issues/neck weakness, dysphagia, and dysphonia.

## Depressor Anguli Oris

One of the most common complaints patients present with is the downward corner of the mouth or marionette line. The depressor anguli oris (DAO) is the primary muscle responsible for this appearance along with frowning. The DAO can be injected near its origin on the mandible. Two to five units can be injected either at one or two sites. Cephalad injections that encroach on the lower lip and orbicularis oris may result in drooling or asymmetric smile. Patients with injuries to the marginal mandibular nerve may benefit from injecting this muscle on the contralateral side to help improve symmetry. Patients with oral incompetency may also see benefit with injection of the DAO on the affected side to elevate the lower lip and commissural region. The addition of a filler (hyaluronic acid) to this region may also help support the lower lip and further improve the esthetics of this area.

## Upper Lip/Perioral Rhytids

The actions of the orbicularis oris may result in dynamic furrows or rhytids in the perioral region. The orbicularis oris may be injected in a superficial fashion with 2–4 units of BTX-A in multiple sites (0.5 units or 1 unit per site). Most patients will also benefit from concomitant injection of filler (hyaluronic acid) to restore volume and improve the rhytids in these areas. Several injection sites should be used either at the vermillion border or just above. Injecting the upper lip toward the base of the nose may result in lengthening of the upper lip. This may be intentional for patients with vertical maxillary excess (“gummy smile”). Asymmetric lip position may also result if disproportionate amounts of BTX-A is used in the upper lip. Over-injection can affect speech, facial expressions, speech, eating, drinking, and playing wind instruments.

## Posttreatment Instructions

After treatment, patients are instructed to avoid heavy exertion/lifting, apply cold compresses for reduction of bruising/swelling/discomfort, and avoid rubbing or massaging the treated areas. In addition, some providers instruct their patients to perform exercises to help the BTX-A “work into the muscles.” Some providers also tell their patients to avoid airline travel and not to bend for up to 24 hours after treat-

ment. None of these instructions have been shown to alter the outcomes or longevity of the desired effects of BTX-A. It is generally believed that after 90 minutes, the toxin has bound to its receptor sites and will not be significantly altered at this time. The author instructs patients they should avoid exercise and laborious activity for the first 2 h after treatment and use Tylenol as some may experience a headache posttreatment.

### Longevity of Effect

The duration of effect has several variables that must be considered in the discussion of longevity of effect. Allergan reports that the duration of effect for 20 units of Botox on glabellar lines is approximately 3–4 months. Galderma states a similar duration (up to 4 months) for 50 units of Dysport in the glabellar region. The package insert for Xeomin and Jeuveau both state that 20 units should be administered no more frequently than every 3 months [7–9]. Generally speaking, this seems to be the standard duration of action for most anatomic regions. With that said, this effect may vary based on dosage, muscle density, degree of facial animation, anatomic site, age, and anatomic variations. Many patients will return prior to the 3-month interval to reduce the possibility of the effect completely “wearing off.” The maximum dose per Allergan is 400 units within 3 months [7].

### Patient Evaluation

A patient interview must include an accurate medical history as well as meticulous physical examination. The medical history will illicit any information regarding muscle-related disorders (e.g., myasthenia gravis, motor neuron diseases, amyotrophic lateral sclerosis (ALS), Eaton Lambert syndrome) as these conditions may be exacerbated by the administration of BTX-A. BTX-A should also be avoided in patients with a history of Guillon Bare syndrome, hypersensitivity to BTX-A, and cow’s milk allergy (specific to Dysport). If there is an active infection at any potential injection site, then the area should be allowed to heal prior to injection. A thorough understanding and familiarity of muscles of facial expression are essential to obtaining optimal results. (*DIAGRAM OF MUSCLES OF FACIAL EXPRESSION*) Not only are the anatomic variations important to recognize, but also the functional anatomy as it may differ substantially from patient to patient. Each patient must be examined carefully to determine which muscle group(s) may contribute to any given furrow or wrinkle. As this is critical in the development of a treatment plan that will effectively reduce the activity of unaesthetic muscle effects.

### Crow’s Feet/Periorbital Rhytids

The orbicularis oculi muscle encircles the orbit and acts in a sphincter-like fashion to close the eye and protect the globe. The lateral and inferior aspects of this muscle, when activated may create significant rhytids and furrows that can be easily treated with BTX-A. Careful examination of this region is necessary to identify asymmetries, laxity of the lower eyelid, and presence of herniation of fat in the lower eyelids. Some patients will not tolerate higher dosages of BTX-A and may result in untoward effects. Patients with laxity of the lower eyelid when injected may result in ectropion and possibly exacerbation of any cheek/malar ptosis. The orbicularis oculi may also aid in elevation of malar elevation/projection. Over-injection can thus lead to loss of projection or ptosis. Injection into the lower eyelid region can also lead to increased scleral show or further herniation of the lower eyelid fat pads if the orbicularis tone is diminished.

Allergan has provided data in its studies that show the efficacy of using 12 units per side (24 units total) to the periorbital region. This treatment showed significant improvement in the lateral canthal lines of the test subjects versus placebo [7]. It is important to inject the most active segments of the orbicularis oculi and to have multiple sites of injection. This will help reduce any irregularities caused by active portions of the muscle that have not been treated.

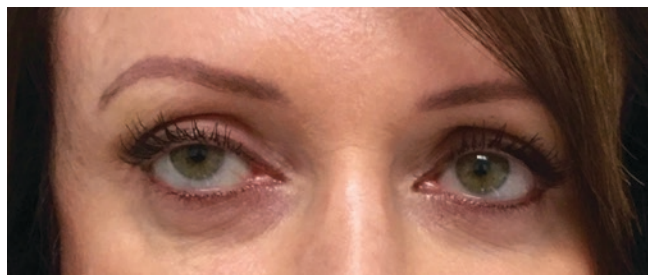### Glabella

The glabellar region is one of the most common sites patient’s request for injection and treatment. Careful examination of this area needs to be performed prior to injection. The procerus and corrugator supercilii muscles along with the medial aspect of the orbicularis oculi muscles contribute to furrows in this region. The contribution each muscle bundle makes to these furrows may vary significantly between patients. When asked to make an angry face, act as though they are smelling something (i.e., “wrinkle their nose”) or frown, these glabellar muscles will move the brows inferomedially. In some patients, however, the brow may move superomedially. Consequently, when BTX-A is injected into this region, the outcome may vary from patient to patient.

Allergan recommends injecting the glabella with 20 units of Botox which is also the same dosage recommended for Xeomin and Jeuveau [7, 9]. Fifty units of Dysport are recommended to treat this same region [8]. Males may require higher dosages and there may be some preliminary evidence that using higher doses may result in a greater duration of effect. Care should be taken to inject above the supraorbital rim. When injecting, the non-injecting hand should be used



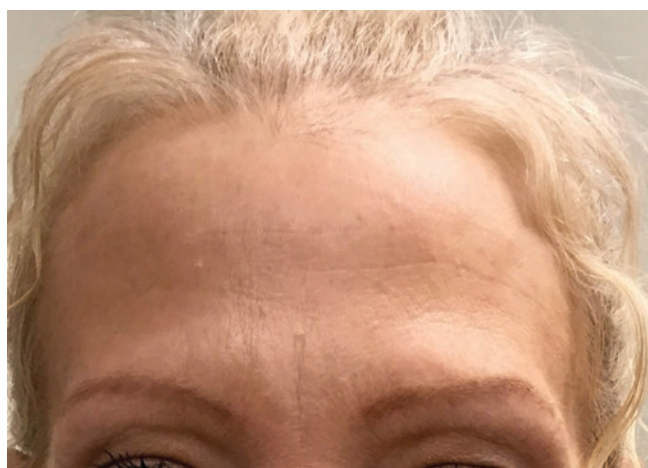to hold the tissue in a stable position. The patient may be asked to elevate their brow and then make a facial expression (as discussed above) to help identify the active portions of the muscles that need to be treated. Most of the BTX-A will be used to treat the corrugator muscles and a small amount will be used to treat the procerus muscle.



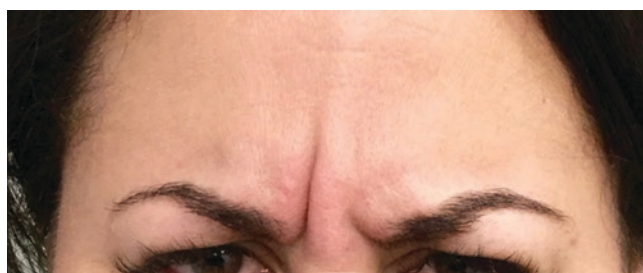
Right eyelid ptosis after neurotoxin treatment



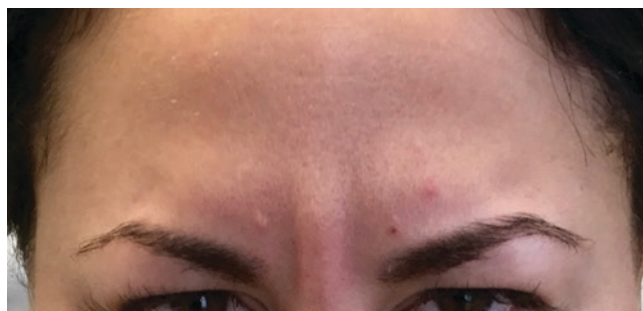Forehead before treatment with neurotoxin



Forehead after treatment with neurotoxin



Glabella before treatment with neurotoxin



Glabella after treatment with neurotoxin

## Non-cosmetic Indications

Although the focus of this chapter is on cosmetic uses, BTX-A is FDA approved for a number of therapeutic indications, including bladder dysfunction, chronic migraine, spasticity, cervical dystonia, primary axillary hyperhidrosis, blepharospasm, and strabismus. It is also routinely used for treatment of patients with myofascial pain, although this use is considered “off-label.” Although the pathophysiology of myofascial pain has not been fully elucidated, the role of muscle hyperactivity is thought to be central. It is thought that hyperactive skeletal muscle bands develop in response to trauma, strain, or overuse, and that these trigger points evoke a referred pain pattern [17]. Therefore, proposed treatment modalities aim to arrest, stabilize, or reverse this muscle overactivity. The ability of BTX-A to elicit a weakening or paralytic effect on the muscle may only account for part of the explanation for its analgesic effect. In addition to its effect on acetylcholine release, Botox also has an inhibitory effect on the release of substance P, which is a potent neurotransmitter in the activation of neurological inflammation [18].

The suggested injection pattern for chronic migraine is described in the Botox Prescribing Information and includes a total of 155 Units into seven different muscle groups. In

contrast, the injection technique for treatment of myofascial pain usually focuses on only the easily accessible muscles of mastication (masseter and temporalis), and because this indication is off-label, there is less clear guidance on injection pattern. This author typically uses 100 units, with 35 units injected into the bilateral masseter, and 15 units injected into the bilateral temporalis. These muscles are much larger than the muscles of facial expression, and therefore larger quantities of neuromuscular blocker are needed to achieve a therapeutic effect. The injector should be aware that the target of masticatory musculature is expected to be deeper than the muscles of facial expression which are immediately subcutaneous. Especially for the masseter in a patient with more adipose tissue, there is occasionally the need for a longer needle than the standard 1/2" needle on a TB syringe.

## Complications

A variety of complications have been reported, ranging from minor issues like bruising and asymmetry to major problems like anaphylaxis, dysphagia, and breathing difficulties. With the relatively small doses required for cosmetic indications, major complications are exceedingly rare and facial cosmetic use of Botox has a very well-established track record of safety [7]. Hypersensitivity to botulinum toxin has been reported, and usually manifests as soft tissue edema or urticaria. Bruising and bleeding at the injection site is not uncommon, and for this reason most practitioners suggest discontinuation of aspirin and other NSAIDs 1 week prior to injection [19].

Other preventative measures include icing immediately before injection (also has analgesic effect), injecting superficially, and avoiding vessels. Hematoma formation, caused by inadvertent vascular puncture, is less likely. Some authors advocate the use of vein illumination devices as helpful in identifying smaller vessels, especially in dark-skinned patients.

Most functional complications can be attributed to unintended spread of neurotoxin, or neuromuscular blockade of unintended muscles which can be due to improper injection technique or misidentification of facial muscular anatomy. Brow or eyelid ptosis are particularly undesirable complications both because of the ease of detection of even small asymmetries, and because of the potential for visual disturbance. When injecting the glabella care should be taken to stay at least 1 cm above the superior orbital rim and inject perpendicular to the muscle. Diffusion of neurotoxin can cause weakness of the levator palpebrae superioris, causing upper eyelid ptosis. Further laterally, the "safe-zone" for injection of the forehead to avoid brow ptosis is generally considered to be at least 2–2.5 cm above the superior orbital rim. Similarly, injection of crow's feet is best performed no closer than 1–1.5 cm from the orbital rim to avoid diplopia

caused by neurotoxin spread into the orbit, weakening the lateral rectus or inferior rectus.

Nonfunctional complications related to cosmetic asymmetry are easier to manage. These include peaked lateral brows ("Spock eyebrow"), uneven brow position, uneven smile, etc. It is recommended to wait 2 weeks after initial injection before doing a touch-up to allow for variations in timing of muscle response to neurotoxin [5].

Ptosis, as a complication of Botox injection too close to the upper lid, can be at least partially treated with apraclonidine (Iopidine; Alcon Labs Inc., Ft Worth, TX) 0.5% drops used 30 min before social situations. This  $\alpha$ -adrenergic agonist stimulates Mueller's muscle, causing several hours of transient lid opening.

## Bibliography

1. 2017 Plastic Surgery Statistics Report. <https://www.plasticsurgery.org/documents/News/Statistics/2017/plastic-surgery-statistics-report-2017.pdf>
2. Scott A, Rosenbaum A, Collins C. Pharmacologic weakening of extraocular muscles. *Invest Ophthalmol Vis Sci.* 1973;12(12):924–7.
3. Scott A. Botulinum toxin injection into extraocular muscles as an alternative to strabismus surgery. *J Pediatr Ophthalmol Strabismus.* 1980;17(10):21–5.
4. Scott A, Kennedy R, Stubbs H. Botulinum a toxin injection as a treatment for blepharospasm. *Arch Ophthalmol.* 1985;103(3):347–50.
5. Carruthers J, Fagien S, Mattarasso SL, et al. Consensus recommendations on the use of botulinum toxin type A in facial aesthetics. *Plast Reconstr Surg.* 2004;114:1s–22s.
6. Carruthers J, Carruthers J. Treatment of glabellar frown lines with Clostridium botulinum A exotoxin. *Dermatol Surg.* 1992;18:17–21.
7. Botox® (onabotulinumtoxin A) for injection. Prescribing information. Irvine: Allergan, Inc.; 2017.
8. Dysport™ (abobotulinumtoxinA) for injection. Prescribing information. Ipsen Pharmaceuticals and Galderma Laboratories; 2016.
9. Xeomin™ (incobotulinumtoxinA) for injection. Prescribing information. Franksville: Merz Pharmaceuticals, LLC; 2010.
10. Crow D. <https://www.ft.com/content/49570b38-221f-11e8-9a70-08715791301>. Financial Times Limited; 2018, March 8.
11. Huang W, Foster J, Rogachefsky A. Pharmacology of botulinum toxin. *J Am Acad Dermatol.* 2000;43(2 Pt 1):249–59.
12. Warren RJ, Neligan PC. Plastic surgery, volume 2: Aesthetic surgery, 3rd ed. Elsevier Health Sciences; Sep 5, 2012. p. 31, Chapter author- Micheal AC Kane.
13. Prescribing information. San Francisco: Solstice Neurosciences, Inc.; 2010.
14. Kim A, Jung J, Pak A. *Cutis.* 2013; Suppl:12–18.
15. Seeley BM, Denton AB, Ahn MS, Maas CS. Effect of homeopathic Arnica montana on bruising in face-lifts. *Arch Facial Plast Surg.* 2006;8:54–9.
16. Rowe DJ, Baker AC. Perioperative risks and benefits of herbal supplements in aesthetic surgery. *Aesthet Surg J.* 2009;29(2):150–7.
17. Smith HS, Audette J, Royal MA. Botulinum toxin in pain management of soft tissue syndromes. *Clin J Pain.* 2002;18:S147.
18. Guyer BM. Mechanism of botulinum toxin in the relief of pain. *Curr Rev Pain.* 1999;3:427.
19. Qaqish C. Botulinum toxin use in the upper face. *Atlas Oral Maxillofacial Surg Clin North Am.* 2016;24:95–103.

## Introduction

Administration of facial fillers is a minimally invasive procedure that has increasingly become popular over the past few decades. Soft tissue fillers ranked second in total number of minimally invasive procedures behind Botulinum Toxin injections in 2018 [1]. Since most esthetic treatments done for facial rejuvenation are on the rise, it is fundamental that providers be aware of the associated risks and potential complications that can occur after administration of these products. In-depth knowledge of facial fillers is vital for providers to manage adequately post-procedure complications. Prior to administration of any facial fillers a thorough understanding of facial anatomy is indispensable to avoid negative outcomes and maintain patient safety. A variety of mild adverse events including swelling, nodule formation, and pain have been reported while more severe complications include tissue necrosis and visual changes. Facial anatomical considerations lay the foundation for safe filler administration in conjunction with expertise in procedural technique and knowledge of the materials used. There are many different filler materials, each having their own indications and associated techniques for application.

## Anatomy

Facial anatomy is quite intricate and requires an in-depth review. While understanding of the facial planes is useful in treatment planning and achieving successful cosmetic outcomes, the main emphasis is on the location of the vasculature to prevent severe complications. The anatomy of the face is best described in a layered fashion from superficial to deep and includes the following: skin, subcutaneous fat, superficial musculo-aponeurotic system (SMAS), deep fat, and deep fascia. The epidermis is the outermost layer of the skin consisting of keratinizing stratified squamous epithelium and is anchored to the underlying dermis by hemidesmosomes at the basement membrane. The dermis gives the skin its pliability, elasticity, and tensile strength. The subcutaneous fat has different characteristics depending on which region of the face. Understanding of the fat distribution and SMAS is helpful in evaluating a patient and determining where dermal filler is needed. In the temple, neck, forehead, periorbital and mid-face the subcutaneous fat is loose and separate from the skin. In the periorbital, nasal, and eyebrow regions, the muscle fibers insert directly into the skin and have a tighter adhesion of fat to the skin itself. The superficial fat is subdivided into distinct anatomic compartments. The jowl fat is adherent to the depressor anguli oris and inferiorly fuses with the platysma muscle. The cheek fat has medial, middle and lateral compartments. The middle cheek fat is a larger compartment found anterior and superficial to the parotid gland. The lateral cheek fat compartment lies immediately superficial to the parotid gland and connects the temporal fat to the cervical subcutaneous fat. The SMAS is an organized fibrous network that separates the subcutaneous fat from the parotid-masseteric fascia and fascial nerve branches. The SMAS invests the superficial mimetic muscles, including the platysma muscle, orbicularis oculi muscle, occipitofrontalis muscle, zygomatici muscles, and levator labii superioris muscle.

The upper, mid, and lower face can be divided into nine major subunits each further divided into divisions [2]. Each

---

S. Halepas (✉)  
New York-Presbyterian/Columbia University Medical Center,  
New York, NY, USA  
e-mail: [sh3808@cumc.columbia.edu](mailto:sh3808@cumc.columbia.edu)

E. Ress  
University of Florida, Jacksonville, FL, USA

E. M. Ferneini  
Beau Visage Med Spa, Greater Waterbury OMS,  
Cheshire, CT, USA

Division of Oral and Maxillofacial Surgery, University of  
Connecticut School of Dental Medicine, Farmington, CT, USA

Department of Surgery, Frank H Netter MD School of Medicine,  
Quinnipiac University, Hamden, CT, USA



of these subunits have different considerations in regard to relevant anatomical structures (muscles, nerves, arteries, veins, etc.). The muscles of facial expression consist of 23 paired muscles in addition to the orbicularis oris. Freilinger et al. discuss a proposed innervation scheme for four distinct layers of facial musculature [3]. The first layer is comprised of the depressor anguli oris, zygomaticus minor, and orbicularis oculi. The depressor labii inferioris, risorius, platysma, zygomaticus major, levator labii superior alaeque nasi make up the second layer. The orbicularis oris and levator labii superioris make up the third layer, and the mentalis, levator anguli oris, and buccinator make up the fourth layer. It is suggested that the first three layers receive innervation from their deep surfaces while layer four is innervated from the superficial surface [3]. The facial mimetic muscles consist of elevators, depressors, abductors, adductors, sphincters, that work in harmony to allow for complex facial expression. These muscles originate from the SMAS layer and insert into the skin. They are innervated by the extracranial branches of the facial nerve. In the upper face, the frontalis muscle is responsible for brow elevation and the formation of transverse forehead rhytids. The frontalis originates from the broad galea aponeurotica which anchors on the posterior nuchal line and is fixed to the underlying pericranium of the calvarium. This muscle has two halves and extends vertically downward to insert in the dermis at the eyebrow just above the supraorbital rim and glabella. The muscle lies 3–5 mm deep to the skin of the forehead. In the midline, there is an aponeurosis separating the two halves.

The majority of arterial vasculature of the face is supplied by several branches from the external carotid artery. The facial artery gives rise to many branches including, but not limited to the inferior and superior labial arteries, the angular artery, and the dorsal nasal artery. The maxillary artery gives rise to the infraorbital artery which emerges through the infraorbital foramen supplying the skin of the lower lid and midface. The ophthalmic artery, arising from the internal carotid gives off several branches that supply the globes as well as the proximal portion of the nose. Due to the risk of embolization and severe complications associated with this adverse event knowledge of the complex vasculature of the face is integral to safe administration of facial fillers. Specific areas of the face that are especially susceptible to soft tissue necrosis include the nose, nasolabial folds, and glabellar region [4].

## Upper Face

The upper face includes the forehead and periorbital subunits. The eyelids as part of the upper periorbital subunit are broken into three soft tissue depressions: junction of the inferior orbital septum and tarsal plate, the inferior orbital rim, and the location over the zygomaticomalar ligament [5].

The frontalis is counterbalanced by the depressors of the brow, which consists of the glabellar complex (corrugators supercilii, procerus, and depressor supercilii) and orbicularis oculi. The corrugators originate from the frontal bone near the superior and medial portions of the orbital rim. They pass through the galea fat pad before penetrating the frontalis and orbicularis to insert in the dermis. There are transverse and oblique heads of the muscle; the transverse head travels superolateral to insert in the dermis above the middle of the eyebrow, and the oblique head terminates in the dermis just medial to the brow. The oblique head acts with the other brow depressors forming oblique rhytids, and the transverse head results in medial brow displacement with accompanying vertical and oblique rhytids. The procerus is a pyramidal muscle that originates in the lower nasal bone and extends vertically and inserts into the skin between the eyebrows. It is a depressor and forms a horizontal glabellar rhytid. The depressor supercilii originates from the bony prominence near the medial canthus and courses directly upward to insert in the skin of the medial brow. The orbicularis oculi muscle is the sphincter muscle encircling the globe and anchoring at the medial and lateral canthi.

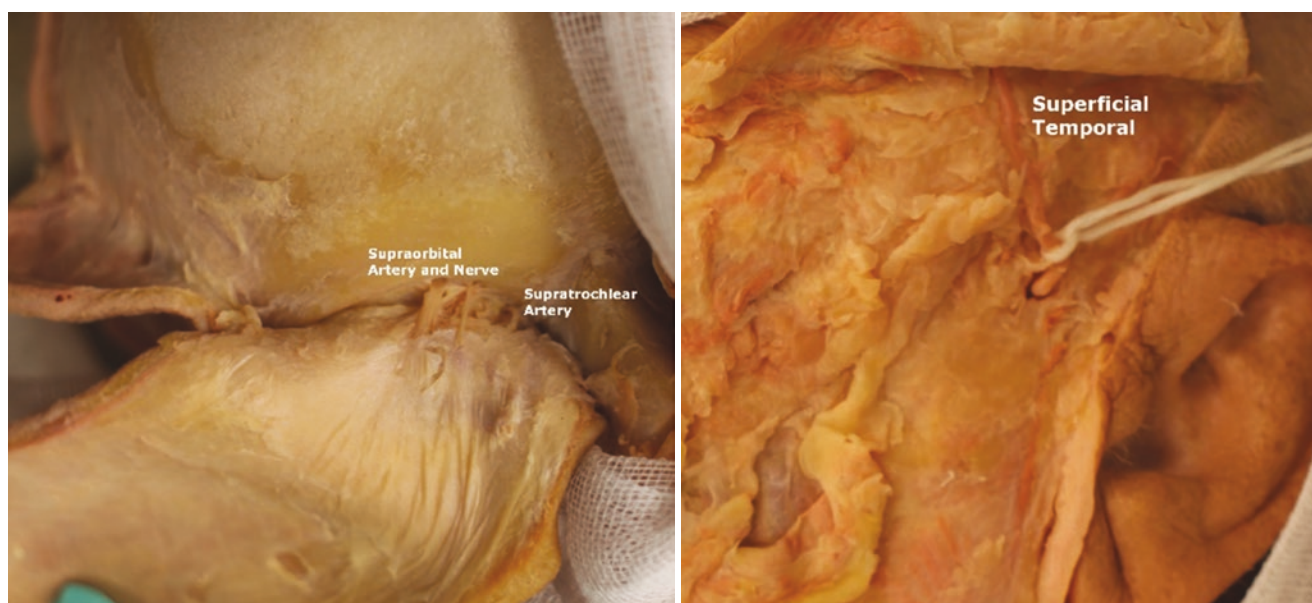
The ophthalmic artery gives rise to the supraorbital, supratrochlear, and posterior ethmoidal arteries. The prevalence of the supratrochlear and supraorbital arteries arising as two distinct branches was seen in 33 of 38 dissections [6]. The supratrochlear artery, exiting the superomedial orbit, is located on average inferior to the transverse third of the forehead and medial to the canthal vertical line [7]. Because the artery is located 1–2 mm deep to the musculature its location is important when injecting in this area. Although located more posteriorly, the superficial temporal artery should be considered due to its division into parietal and frontal branches (Fig. 16.1). In the temporal region, fillers should be injected either deeply or superficially. Deep injections should be in the periosteal plane [8].

## Midface

The midface subunits include the nasal, medial and zygomatic cheek, upper lid, and auricular subunits. A major landmark to consider in the midface is the infraorbital foramen, which is located on average  $9.6 \pm 1.7$  mm from the infraorbital rim [9] and one third of the distance between the medial and lateral canthi.

In the midface, the facial mimetic muscles are deeper than in the upper face. The nasalis muscle lies just below the glabellar complex with the upper part traveling transversely across the dorsum and vertically down the lateral sides of the nose. The transverse head of the nasalis compresses the dorsum, the vertical heads dilate the nares. These muscles contract to form the “bunny lines” or oblique rhytids of the nasal dorsum. The depressor septi muscle is a muscle that originates in the columella and inserts into the upper lip, which will rotate the nasal

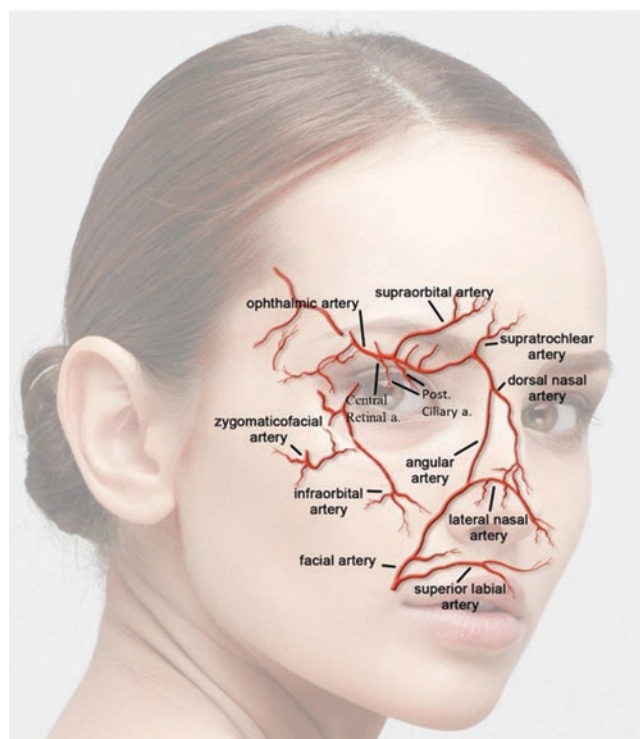




**Fig. 16.1** Cadaveric dissection demonstrating the supraorbital artery and supratrochlear artery as it leaves the supraorbital notch (left) and superficial temporal artery as it runs superior (right). Notice how superficial the artery is as it runs in the SMAS

tip downward and elevate the upper lip. The zygomaticus major inserts at zygomatic body just below the lateral orbital rim and extends medial and inferior to insert into the lateral aspect of the upper lip. The zygomaticus minor is just medial to the zygomaticus major and both acts to draw the lateral lip up and back. The principal elevator of the upper lip is the levator labii superioris, which originates in the mid-orbit medial to the zygomaticus minor and acts in concert with the levator labii superioris alaeque nasi, which originates from the lateral nose. The levator anguli oris is a deep muscle originating in the area of the canine fossa and inserts near the commissure to elevate the corner of the mouth. The risorius muscle arises from the lateral cheek and is variably developed and pulls the commissure laterally. The orbicularis oris muscle is the sphincteric muscle of the mouth and consists of superficial and deep parts. The deep layers act as a constrictor and the superficial layer brings the lips together and provide expression.

The infraorbital branch of the maxillary artery exits the foramen and supplies the skin of the lower lid and middle face. Its location deep to the levator labii superioris muscle and superficial to the levator anguli oris muscle should be taken into consideration when injecting in this area. The dorsal nasal artery, a branch of the ophthalmic artery, lies 5 mm above the medial canthal horizontal line [7] and anastomoses with the angular artery. The angular artery on average is located approximately 5 mm medial to the medial canthal line with the accompanying angular vein laying medial to the artery in the deep muscle fascia [7] (see Fig. 16.2). The anastomoses of the facial vasculature and proximity to important structures (globe, cavernous sinus) make intravascular injections a major concern when injecting in this area. For this



**Fig. 16.2** Vasculature of the midface

reason, *midface injections should be deep to avoid intravascular cannulation or vascular compromise*. If the injections are also not sufficiently deep, a superficial injection can compress superficial vasculature in the tip and alar facial groove leading to tip and alar necrosis.

## Lower Face

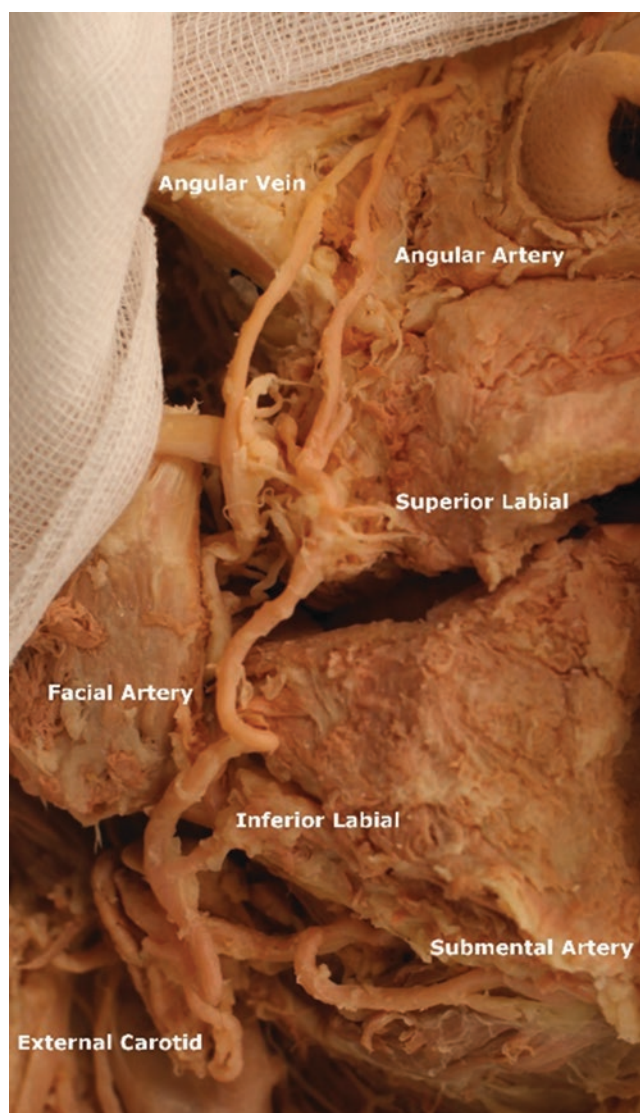
The lower face subunits include the lateral and buccal cheek, lower lip, and mental subunits. The lower lip depressors act to balance the actions of the elevators of the upper lip. The depressor anguli oris arises laterally and inserts into the modiolus along with the orbicularis oris, risorius, and the levator anguli oris. The depressor anguli oris serves to depress the commissure and can be seen as the melomental folds or “marionette lines.” The depressor labii inferioris is medial to the depressor anguli oris and acts to depress and evert the lower lip. The mentalis muscle is a paired midline muscle deep to the other depressors and acts to elevate and protrude the lower lip. The platysma originates in the neck as a paired muscle that crosses the mandibular border and inserts into the dermis and subcutaneous tissues of the lower lip and chin. Vasculature of the lower face is primarily supplied by the facial artery. It branches off the external carotid, passing through the submandibular gland at the lower border of the mandible. The facial artery gives off branches including the submental, inferior labial, superior labial, and angular arteries (see Fig. 16.3). Due to the inferior labial arteries posterior location at the mucosal-muscular interface below the superior border of the lip, it is important to not administer fillers more than 2 mm deep. Intravascular injections in this location can potentially result in tissue necrosis [10].

## Materials

Facial fillers can be divided into two categories, those that are derived from either natural (temporary) or synthetic (permanent) materials. Examples of natural fillers include hyaluronic acid, poly-L-lactic acid, and calcium hydroxyapatite. The natural biologic fillers are safer in that enzymatic activity can usually degrade them. The downside is that they are therefore temporary. Hyaluronic acid is typically the one most often used due to its ease of use and reversibility.

Hyaluronic acid (HA) is a naturally occurring substance in the body and therefore is a wonderful biomaterial. The dermal filler HA has increased crosslinking which allows an increased half-life of about 18 months. HA is relatively thin compared to other dermal fillers, so it is injected into the subcutaneous or dermal layers. By utilizing this layer, HA stimulates fibroblast to produce additional collagen increasing the volume. Several brands of HA exist, but the common ones are Restylane-L, Juvederm Volbella, Belotero, and Hylaform. Histologically, HA causes a pool of amorphous, acellular blue material surrounded by giant cells (see Fig. 16.4a) [11, 12].

Calcium Hydroxyapatite (CaHA) is another natural material and therefore also temporary. The filler is produced as a suspension of glycerin and sodium methylcellulose with

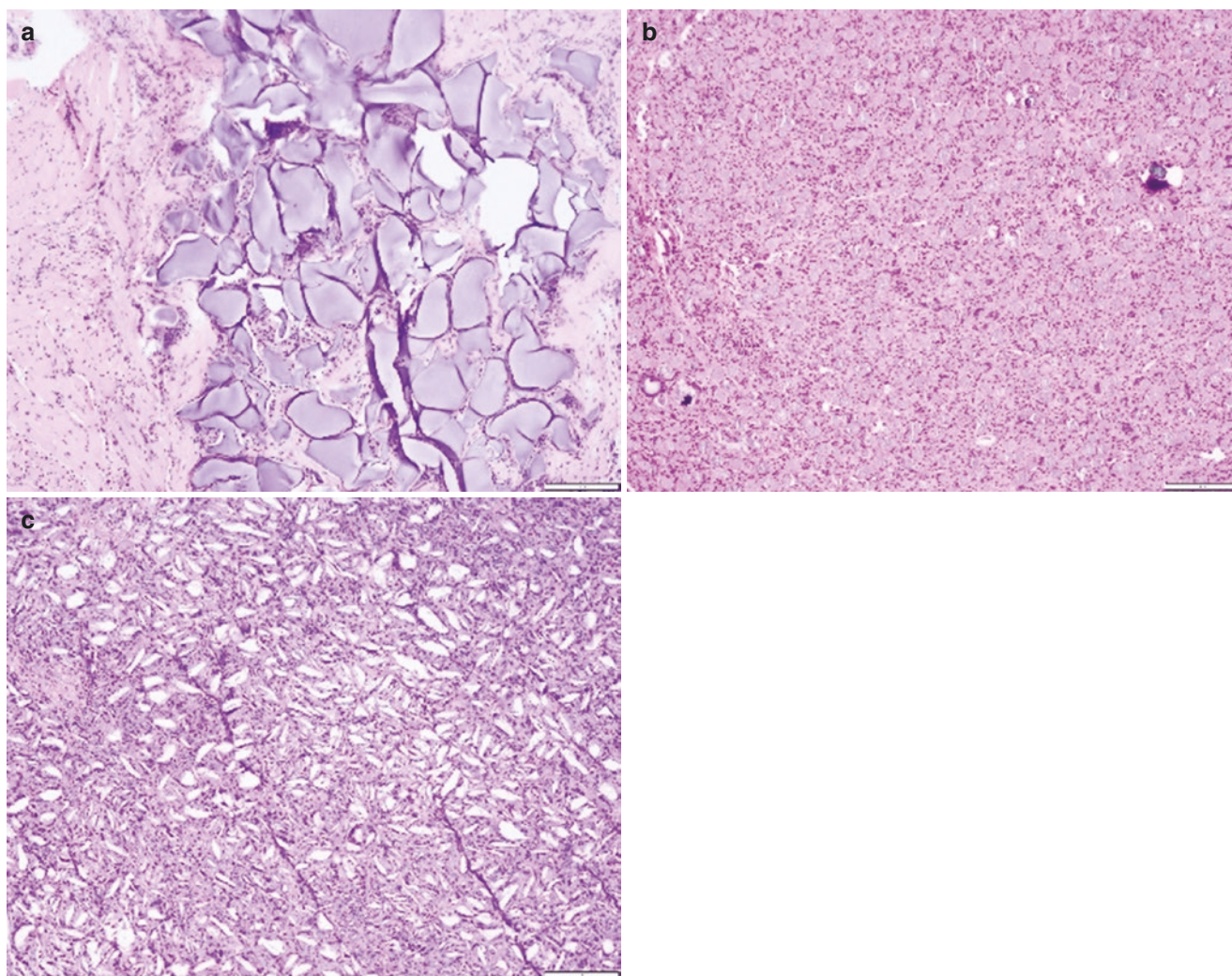


**Fig. 16.3** Cadaveric dissection for the facial artery as it comes off the external carotid until becoming the angular artery in the midface

microspheres of the CaHA. The suspension material is absorbed over a three-month period, which then activates fibroblasts resulting in more collagen deposition. A single treatment can last anywhere from 1 to 2 years. Common brands of calcium hydroxyapatite are Radiesse and Radiance. The increased viscosity of this material requires a deeper injection as superficial injection can lead to nodule formation and increased pain and swelling. Therefore, CaHA is administered in a supraperiosteal injection. Histologically, CaHA results in uniform-sized spherules containing brown granular material (see Fig. 16.4b).

Poly-L-lactic acid (PLLA) is a biodegradable synthetic polymer which stimulates fibroblasts aiding in collagen deposition just like the other materials discussed. PLLA is believed to have one of the most potent stimulators of fibroblasts compared to the other injectables and therefore has a





**Fig. 16.4** (Left) Reactions to hyaluronic acid-based facial fillers show pools of amorphous, acellular, blue material surrounded by foreign body type giant cells (H&E,  $\times 100$ ). (Middle) Calcium hydroxyapatite-based facial fillers show uniform-sized spherules containing brown, granular material within a background of chronic inflammation and for-

eign body type giant cells (H&E,  $\times 100$ ). (Right) Poly-L-lactic acid facial fillers demonstrate spiky, elongated vacuoles which contain variable amounts of polarizable material and are associated with foreign body type giant cells (H&E,  $\times 100$ ). *Histological slides courtesy of Scott Peters, DDS*

duration of up to 3 years. As one of the most potent stimulators, it results in a large amount of edema. Patients therefore see substantial volume initially that then subsides as the edema dissipates and the collagen production begins and should be informed of this phenomenon. Providers should wait a minimum of 4 weeks between each set of injections. PLLA is the principle component in Sculptra and Silhouette Instalift [13]. Like CaHA, PLLA is administered as a supra-periosteal injection. Histologically, PLLA forms spikes and elongated vacuoles which contain variable amounts of polarizable material (See Fig. 16.4c).

The permanent fillers are polymethylmethacrylate and silicone. These facial fillers are not typically used as much in today's world. The permanent fillers result in fibroblast activation depositing collagen and encapsulating the injected

material in a fibrous scar. This results in a permanent increase in volume but has a higher risk of infection and mispositioning.

## Techniques

Injection technique varies based on provider preference but essentially four techniques are utilized most often. Threading is a technique in which a needle is inserted to depth and filler material is deposited consistently as the needle is withdrawn. Cross-hatching is essentially the threading technique but in an overlapping grid pattern that allows to correct a larger area of volume. Serial deposits are when the needle is in the deepest portion of the dermis and a small deposit of filler

material is injected. Additional deposits are then deposited, and the area is gently massaged to ensure adequate volume, and distribution have been achieved. The fanning technique is when the needle is placed at a 30° angle, and the needle is passed back and forth changing directions as filler is deposited. This technique allows for overlapping deposits and a well-distributed amount of volume. All techniques can be used with a microcannula, but the fanning technique in particular is useful with a microcannula as the blunt tip is safely moved in different directions. A microcannula is recommended with facial filler application as it injects on the lateral aspect and has a blunt tip. This theoretically lowers the chance of an intravascular injection or compression of an artery. As with all injections, it is vital the practitioner aspirates before injecting. If the practitioner is utilizing local anesthetic before the procedure, it is recommended to avoid the use of epinephrine as the vasoconstriction can mask arterial occlusion, therefore making it difficult to diagnosis an early complication. Many of the facial fillers are now marketed with lidocaine in the delivery system, so local anesthetic prior to dermal filler application is not often necessary. If being utilized, it is recommended to use block injections to prevent distortion of the tissues.

## Periorbital

The periorbital area can be significantly impacted with dermal fillers. Volume loss is noticed in the supraorbital and infraorbital areas leading to the tired/aged appearance. While many patients would benefit from a blepharoplasty, minimally invasive dermal fillers can provide drastic improvement by adding volume and decreasing skin laxity and wrinkling. The skin in the periorbital region is very thin; hyaluronic acid is the ideal choice for augmentation in the periorbital region due to its low viscosity and ability to stay relatively superficial without nodular formation. In the supraorbital region, HA should be deposited into the sub-orbicularis plane depositing small amounts of no more than 0.25 cc at a time. Using a small needle or microcannula (30-gauge) is recommended and inject slowly from the lateral to medial direction (see Fig. 16.5). As one approaches medially, it is vital to be mindful of the supraorbital notch where the neurovascular bundle lies. In the supraorbital region, the volume deficiency is often in the middle to lateral aspect. The infraorbital area and tear troughs are also great locations for HA. This area often requires more volume, but it is important to make small deposits during each application. The threading technique can be applied and injected into the deep dermal plane. Constant massaging is needed to ensure adequate dissipation of the material. As stated, the tear troughs can require a substantial amount of volume in certain individu-

als. An alternative to HA is the use of PLLA in this area. If PLLA is utilized, the injection site should begin at the lateral aspect, at the junction where the eyelid skin and thicker mid-face skin meet. The threading technique is again utilized from the infraorbital rim inferiorly. The material is deposited just supraperiosteal. Between injections, the provider should massage the material gently and pull toward the tarsal plate. The process is repeated from the medial aspect of the orbital rim, and a fanning technique can be utilized. It is important not to overfill the sites, and the total recommended material is 3 cc per side. The process can be repeated two more times at four-month increments.

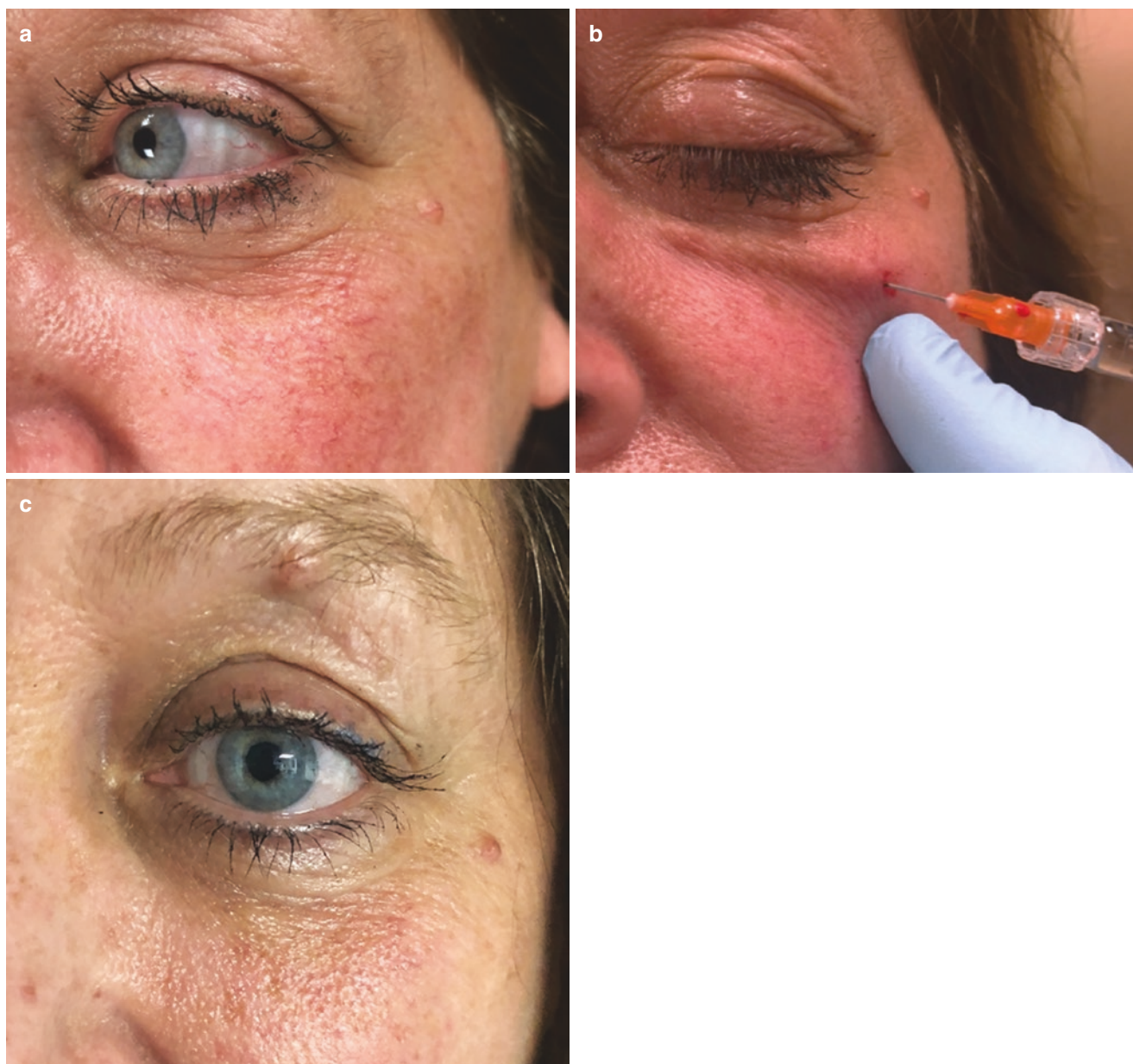## Nose

In nonsurgical rhinoplasty, HA filler can be utilized to make a dorsal hump less prominent and/or to make the tip of the nose rotate upwards. First, identify the dorsal hump and the associated valley. Along the midline dorsum of the nose inject in the depression very small amounts of dermal filler just subcutaneously. Gentle massaging will allow a uniform distribution. The skin is very thin in this area, and the underlying cartilage is very superficial, so it is important to deliver small amounts of filler and see the results. This area is at higher risk for ischemic changes. Small deposits can be placed at the tip and supratip of the nose. The additional volume here makes the skin tighter and gives the appearance of a more upward rotation, essentially moving the most prominent point superiorly, providing a more pleasing appearance.

## Cheek

Cheek augmentation can be performed with really any of the major dermal fillers. In the malar and submalar region, CaHA is particularly effective and is done using the cross-hatching approach, but PLLA and HA are also often used in this location. The injections should stay lateral to the nasolabial fold. A 25- or 27-gauge needle is used and inserted at a 45° angle until the zygomatic bone is contacted (see Fig. 16.6). Withdraw a few millimeters to the supraperiosteal plane and deposit small amounts as the needle is withdrawn. Care should be taken as the angular artery is in the area of the nasolabial fold, and the infraorbital artery continues over the zygomatic arch. Serial injections can be performed along the zygomatic bone usually from the medial to lateral direction. Massaging the area aggressively can minimize nodular formation. When HA is being utilized, compared to CaHA or PLLA, a layering technique is needed. The injection starts supraperiosteal and deposits are made as the needle is withdrawn into the deep dermis.





**Fig. 16.5** (a) Wrinkles under the eyelid preoperatively. (b) Deposition of filler material using microcannula through single port. (c) One week postoperatively with softened under the eyelid wrinkling for a more natural appearance

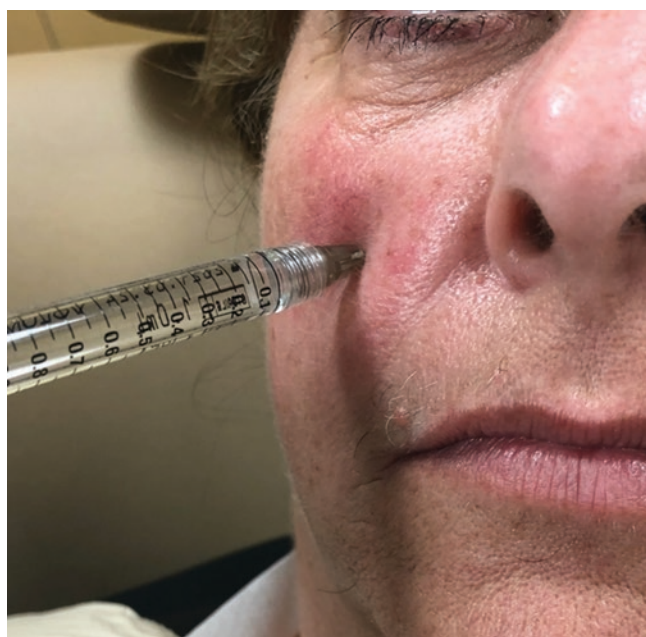### Nasolabial Fold

The nasolabial fold is a high-risk area due to the course of the facial artery. Practitioners often can provide adequate esthetic results by injecting the cheeks, which results in changes in the nasolabial folds. Utilizing a microcannula is also recommended, especially in this high-risk area. Injecting perpendicular to the nasolabial fold, injecting slowly, and using the threading technique instead of large boluses decreases the risk of arterial compromise. Insert the needle just lateral to the fold and use very small quantities of filler

material. Massage the filler into the desired region by pulling medially.

### Lips

The lower lip is naturally larger than the upper lip, and this proportion needs to be maintained. Local anesthesia can be administered intraorally via the infraorbital nerves and mental nerves bilaterally. A needle can be used to make an incision at the commissure for both the upper and lower lip. A



**Fig. 16.6** A 27-gauge needle inserted at a 45° angle until the zygomatic bone was sounded, and filler material was deposited in the supra-periosteal plane

blunt tip canula can then be entered and inserted to depth with the tip extending to cupid's bow. The threading techniques are used in a layering technique. Proper massaging is preformed to ensure adequate distribution. HA is the filler of choice for this region due to its viscosity.

## Chin/Jaw

The chin can be augmented with any of the dermal fillers. If a large amount of filler or substantial amount of injections are needed, the provider can utilize intraoral mental nerve blocks to provide increased patient comfort. PLLA and CaHA are particularly useful in larger volume augmentations in the chin and jaw, but HA can also be used to augment this region. PLLA and CaHA are delivered in the supra-orbital plane while HA is in the subcutaneous plane. Inferior labial artery and mental are at risk with the chin augmentation, and the facial and submental artery are at risk when injecting along the inferior border of the mandible for jaw line augmentation.

## Complications

Complications associated with dermal fillers are very rare. As with any procedure, patients should expect mild bruising, ecchymosis, erythema, and/or edema [14]. Most patients

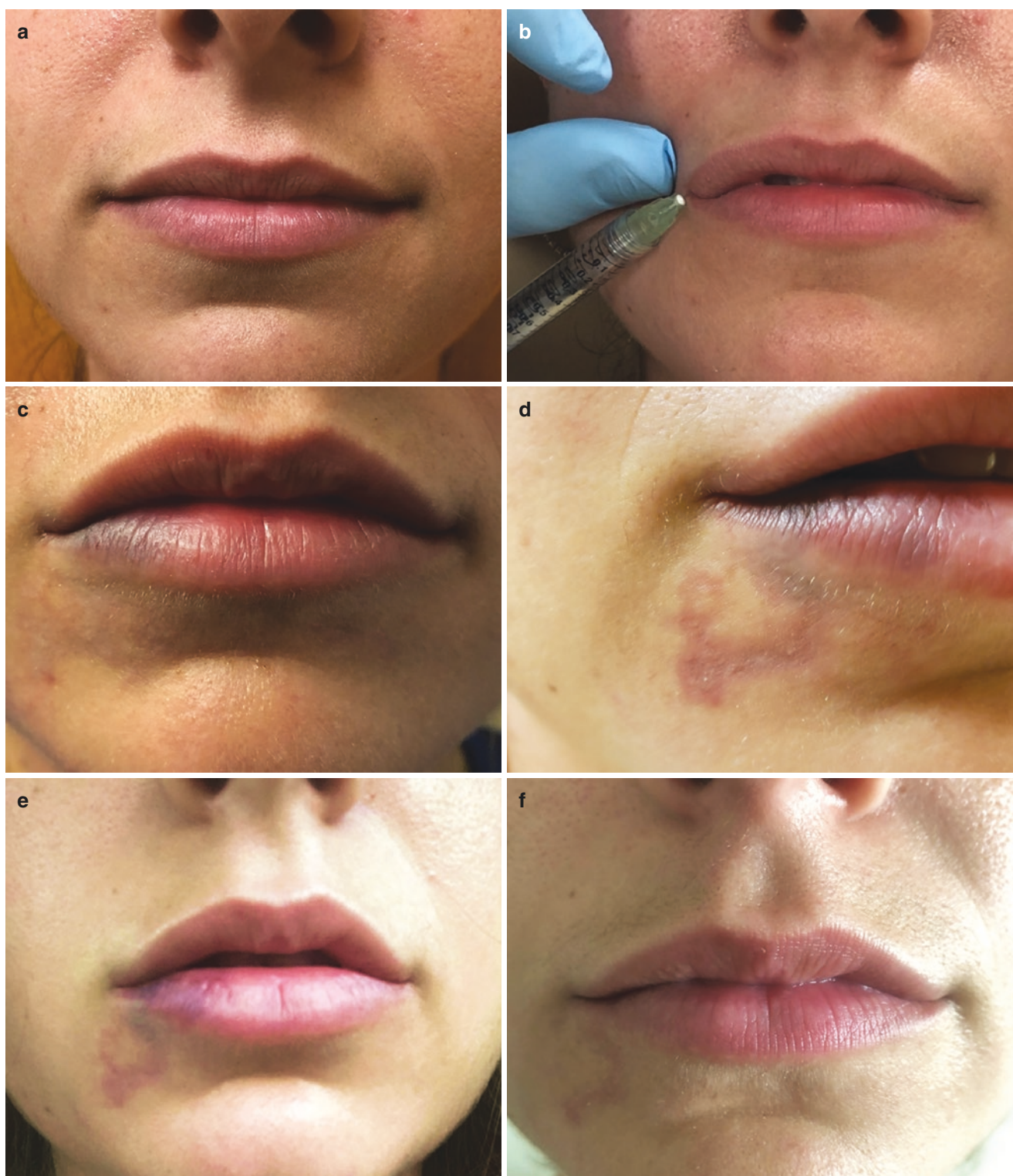complain of very minimal side effects that can easily be treated with NSAIDs and ice.

Infections associated with dermal fillers is exceedingly uncommon, estimated at 0.04–0.2% depending on the source [15]. Bacterial infection when they do occur typically are due to *P. Acnes* and *S. epidermidis* as they are the topical flora commonly found on the skin. In rare instances, infections can form from *Staphylococcus aureus* and *Streptococcus* species; this is suspected especially if an abscess or cellulitis presents after the procedure. If an abscess does occur, incision and drainage with cultures may be indicated and appropriate antibiotic therapy would be warranted. The best treatment is proper prevention using sterile technique prior to the procedure. Topical disinfectants should be used such as 70% isopropyl alcohol, betadine, chlorhexidine, or other solutions. Prophylactic antibiotics are unwarranted for majority of immunocompetent patients. Viral infections can occur in patients with herpes simplex virus where reactivation presents in the perioral regions. In patients with a known history, pretreatment with acyclovir is highly effective.

More severe complications include skin discoloration, scarring, or foreign body granuloma formations. Devastating complications can include hypersensitivity reactions and/or arterial embolization/compression leading to ischemic necrosis and even blindness [16]. In the cases of intravascular injection, the filler material may completely or partially occlude a vessel resulting in an ischemic event or emboli to a distant artery. Tissue necrosis should be suspected if a bluish/violet discoloration develops (see Fig. 16.7). Hematoma from these injections are infrequent, but it is important to distinguish between a hematoma and impending tissue necrosis. Signs of tissue necrosis are severe pain that is relentless, delayed, or absent capillary refill, and the tissue can often appear cold/dry. See Table 16.1 for sample protocol for suspected tissue necrosis.

Anatomically, as the facial artery continues superior and medially it becomes the angular artery and anastomoses with the dorsal nasal artery, which is a branch of the ophthalmic artery. Embolization of the facial artery at any point along this path therefore can result in blockage of the ophthalmic artery and result in blindness. Arterial embolization or compression is extraordinary atypical estimated as around 0.001% [17]. However, there are case reports in the literature that describe this devastating circumstance that can be avoided with proper anatomical understanding. A study by Beleznyay et al. reported 146 cases of visual disturbances after facial filler administration [18]. Early treatment when this is suspected is vital to preventing permanent blindness. An ophthalmology consult should be obtained, and a brain magnetic resonance imaging study should be performed to determine if any vascular occlusion exists. See Table 16.2 for soft tissue emergency kit to address potential blindness.





**Fig. 16.7** Preoperative lip injections (a). Filler was deposited from the commissures in a threaded layering technique (b). When injecting the lower right lip, the patient experienced blanching, followed by a bluish/purplish discoloration (c). Capillary refill was sufficient; the decision was made to monitor the lower lip for possible vascular compromise.

Within 12 hours, the skin inferior to the lower lip developed a lacy appearance (d). The decision was then made to reverse the lip filler in this area using the protocol from Table 16.1, the following morning (e). Patient healing well 2 weeks following the procedure (f)

**Table 16.1** Sample necrosis protocol in cases of suspected vascular compromise following facial filler administration [12]

Agent	Rationale
Warm compress	Reduce swelling
Filler reversal agent	Degrade filler causing obstruction
Aspirin 325 mg	Inhibit platelet cascade
Nitro paste	Precipitate vasodilation to counteract ischemia
Hyperbaric oxygen	Improve blood supply and prevent permanent necrosis
Prednisone	Minimize swelling
Cephalexin	Prevent infection

**Table 16.2** Components needed in a soft tissue filler emergency kit [19]

Skin necrosis	Blindness	Anaphylaxis
250 cc of 0.9% NaCl for dilution of hyaluronidase	All from previous column plus:	All from previous column plus:
1 cc Syringe	22G × 25 mm Angiocath	100 mg Hydrocortisone
3 cc Syringe	0.25% Timolol drops	50 cc Promethazine
5 cc Syringe	Mannitol 20%	Adrenaline
25G × 38 mm canula	500 mg/vial Acetazolamide	1 mg/mL 1:1000 Salbutamol
25G × 50 mm canula		100 µg/dose
18G × 25 mm needle		
23G × 25 mm needle		
33G × 9 mm needle		
Alcohol prep		
Providone-iodine prep pads		
50 cc of 2% lidocaine		
325 mg aspirin tablets		
8 mg IM Dexamethasone		
Hyaluronidase		

Anaphylaxis from fillers is possible, albeit also uncommon. A provider is more likely to see a hypersensitivity reaction rather than true anaphylaxis. Signs and symptoms of a hypersensitivity reaction include erythema, edema, hives, pruritus, among others. Anaphylaxis would have similar symptoms but with the addition of dyspnea and possible signs of shock. Initial treatment for a hypersensitivity reaction should include a steroid like a methylprednisolone dose pack and diphenhydramine. If anaphylaxis is suspected, EMS should be activated and the patients vitals should be closely monitored. The use of albuterol or epinephrine might be indicated given the clinical scenario.

## Conclusion

Dermal fillers for facial augmentation are a very common procedure and can result in very favorable outcomes for one's patient population. As stated earlier, as the facial fillers become more mainstream, as well as a very lucrative treat-

ment modality, we expect to see an increased number of health care providers of varying specialty training offer these minimally invasive procedures. A thorough understanding of facial anatomy is vital to minimizing devastating consequences such as avascular necrosis and/or blindness. Proper technique can help minimize other complications such as erythema and edema. Proper patient selection and education are vital as with any cosmetic procedure. Prevention and early recognition are key to avoiding the majority of severe complications, and proper follow-up allows the practitioner to recognize early and act quickly.

## References

1. Surgeons, A. S. o. P. National plastic surgeon statistics. 2018.
2. Fattahi TT. An overview of facial aesthetic units. *J Oral Maxillofac Surg.* 2003;61(10):1207–11.
3. Freilinger G, Gruber H, Happak W, Pechmann U. Surgical anatomy of the mimic muscle system and the facial nerve: importance for reconstructive and aesthetic surgery. *Plast Reconstr Surg.* 1987;80(5):686–90.
4. Ozturk CN, Li Y, Tung R, Parker L, Piliang MP, Zins JE. Complications following injection of soft-tissue fillers. *Aesthet Surg J.* 2013;33(6):862–77.
5. Ferneini E, Jackson T, Ferneini C, Banki M. A review of new facial filler techniques for facial rejuvenation. *Am J Cosmet Surg.* 2014;31(4):166–73.
6. Erdogmus S, Govsa F. Anatomy of the supraorbital region and the evaluation of it for the reconstruction of facial defects. *J Craniofac Surg.* 2007;18(1):104–12.
7. Kleintjes WG. Forehead anatomy: arterial variations and venous link of the midline forehead flap. *J Plast Reconstr Aesthet Surg.* 2007;60(6):593–606.
8. Boulos M, Halepas S, Ferneini E. Facial fillers. In: Ferneini E, Goupil M, editors. *Office-based maxillofacial surgical procedures.* Cham: Springer; 2019.
9. Hwang SH, Kim SW, Park CS, Cho JH, Kang JM. Morphometric analysis of the infraorbital groove, canal, and foramen on three-dimensional reconstruction of computed tomography scans. *Surg Radiol Anat.* 2013;35(7):565–71.
10. Ferneini EM, Halepas S, Watras J, Ferneini AM, Weyman D, Fewins J. Surgeon's guide to facial soft tissue filler injections: relevant anatomy and safety considerations. *J Oral Maxillofac Surg.* 2017;75(12):2667.e1–5.
11. Owosho AA, Bilodeau EA, Vu J, Summersgill KF. Orofacial dermal fillers: foreign body reactions, histopathologic features, and spectrometric studies. *Oral Surg Oral Med Oral Pathol Oral Radiol.* 2014;117(5):617–25.
12. Halepas S, Chen XJ and Ferneini EM. "Thread-Lift Sutures: Anatomy, Technique and Review of the Current Literature." *Journal of Oral and Maxillofacial Surgery.* 2020;78(5):813–20.
13. Ferneini EM, Halepas S, Weyman DM, Watras J. "Surgeon's guide to soft tissue filler injections: relevant anatomy and safety considerations." *Journal of Oral and Maxillofacial Surgery.* 2017;75(2):2667.e1–2667.e5.
14. Halepas S, Weyman D, Ferneini EM. Complications in minimally invasive facial cosmetic surgery. *J Oral Maxillofac Surg.* 2018;76(10):e44–5.
15. Ferneini EM, Beauvais D, Aronin SI. An overview of infections associated with soft tissue facial fillers: identification, prevention, and treatment. *J Oral Maxillofac Surg.* 2017;75(1):160–6.



16. Ferneini E, Banki M, Ferneini C, Castiglione C. Hypersensitivity reaction to facial augmentation with a hyaluronic acid filler. *Am J Cosmet Surg*. 2013;30(4):231–4.
17. Bucking P, Ferneini M, Ferneini E. Ch. 13 soft tissue fillers and an overview of their potential complications. In: Ferneini E, Castiglione C, Banki M, editors. *Complications in maxillofacial cosmetic surgery*. 1st ed. Cham: Springer; 2018.
18. Beleznyay K, Carruthers JD, Humphrey S, Jones D. Avoiding and treating blindness from fillers: a review of the world literature. *Dermatol Surg*. 2015;41(10):1097–117.
19. Fakih-Gomez N, Orte-Alde MDC, Poonja K, Khanna D. Hyaluronic acid filler emergency kit. *Am J Cosmet Surg*. 2019;36(4):183–190.

Damon R. T. McIntire, Frank Paletta,  
and Douglas Lee Johnson

## Background

Aesthetic rejuvenation of the face has been a goal of cosmetic therapy with documentation extending as far back as the era of the ancient Egyptians [1]. Physiologic changes that occur in the face that contribute to the appearance of age include thinning of the epidermis, loss of elastic fibers and subcutaneous fat, weakening of the underlying muscles, bone resorption, ptosis, and skin changes that are produced from intrinsic (i.e., chronologic) and extrinsic (i.e., photo-damage) factors [2]. Clinically, the skin may appear thin, dry, atrophied, and have variable discolorations (Table 17.1). Facial rejuvenation brings with it some of the most rewarding and dramatic results for the appropriately selected patient. However, as a result of the hyperkinetic society of today, many patients are demanding minimal recovery time with results that are comparable to more traditional surgical procedures. When exploring the possibilities for skin resurfacing procedures of the face, there are many options a patient can be presented, each with its own unique indications and limitations. These options range from superficial skin treatments with topical therapies (i.e., retinoids,  $\alpha$ -hydroxy acids, antioxidants, medical micro-needling, monopolar and bipolar radiofrequency devices) to more invasive, ablative procedures (i.e., mechanical dermabrasion, chemical peels, and laser resurfacing). Surgical procedures like brow, eye, and facelifts will help reposition tissue planes and remove excess skin but will not address the intrinsic nature of skin aging.

There are many types of lasers with different applications that can address multiple diagnoses. Examples of types of lasers listed from lowest to highest wavelength in nanometers are Excimer, Argon, Pulsed dye, Ruby, Alexandrite, Nd:Yag, Holmium, Erbium, and CO<sub>2</sub> [3]. Laser-tissue interaction of relatively low power lasers produce a superficial tissue injury (burn). All cosmetic lasers work by absorption of laser light to a certain selective chromophore (blood, melanin, water, etc.). The gold standard for facial skin resurfacing is the carbon dioxide (CO<sub>2</sub>, 10,600 nm) [4, 5] laser. As the energy of the laser interacts with the tissue chromophore, there is a transfer of energy. The interaction is dependent on the absorption coefficient, which is “the probability per unit path length that a photon at a particular wavelength is absorbed” [3]. This particular modality can provide predictably satisfying results but is associated with higher risks and complications [2]. These include pain, swelling, local infections, prolonged recovery time, hyper- or hypopigmentation, and scarring. It is imperative that these potential complications be discussed with the patient prior to undergoing any intervention, and they should demonstrate understanding in detail. In order to minimize these sequelae, non-ablative technologies have been explored as an alternative or initial option. Rejuvenation technologies such as near infrared (1319–1320 nm), IPL (intense pulsed light), potassium titanyl phosphate (KTP, 532 nm), and pulsed dye lasers (PDL, 585–595 nm) were explored, but ultimately demonstrated minimal skin tightening affects [5–7]. This shortcoming led to the exploration of non-ablative fractional photothermolysis (FT, 1550 nm). Fractional photothermolysis is a concept introduced in 2004 by Manstein and centered around the creation of microscopic thermal wounds in the skin that allow for more rapid healing [2, 7–9]. These zones can range from 100 to 400  $\mu$ m in width to approximately 300–700  $\mu$ m in depth. The first commercial non-ablative FT was approved for skin resurfacing and treatment of periorbital rhytids, pigmented lesions, melasma, acne scars, and surgical scars [6]. Non-ablative fractionated lasers are shorter in wavelength ranging from 1320 to 1927 nm. Patients had little to no

D. R. T. McIntire (✉)

Division of Plastic and Reconstructive Surgery, The Warren Alpert Medical School of Brown University, Providence, RI, USA

F. Paletta

MSL Facial & Oral Surgery, Warwick, RI, USA

Department of Surgery, Warren Alpert Medical School of Brown University, Providence, RI, USA

D. L. Johnson

University of Florida, Saint Augustine, FL, USA

downtime and tolerated the procedures well, most of the time needing between four and six treatments. Currently, there are many devices that are commercially available. Ablative fractionated lasers range from 2940 to 10,000 nm and have more downtime than non-ablative lasers but significantly less than fully ablative lasers.

The evolution from non-ablative FT lasers to ablative lasers occurred during the push to obtain results that more closely resembled traditional fully ablative resurfacing. There are many wavelengths that can be utilized, but CO<sub>2</sub> and Er:YAG (2940 nm) lasers are the two most commonly used currently. Er:YAG lasers have a 25-fold higher affinity for water when compared to CO<sub>2</sub> lasers [10]. This allows the Er:YAG laser to ablate tissue well but does not produce significant lateral thermal heating. This ultimately results in less tissue tightening. The goal of this treatment is to reduce or remove facial rhytids, skin irregularities, lentigines, keratoses, benign and pre-cancerous lesions, dyschromias, uneven pigmentations, and scars [4–6, 8] (Table 17.2). These goals are met by growth of new skin, shrinking of collagen, and formation of new collagen. This treatment, in the right hands and right patient, can have minimal to moderate downtime (up to 7 days typically). For mild aging and photodamage, lighter settings can be utilized to achieve more limited downtime (1–3 days). To obtain more dramatic and predictable results, the procedure may require a form of topical, local, and/or intravenous anesthesia and may require multiple treatments. This controlled skin ablation and thermal coagulation leads to improved skin texture and reduction of fine lines, as well as dermal tightening and shrinkage for wrinkle reduction [2, 8]. At 1 month, there is histologic evidence of nucleogenesis, and there is evidence of continued collagen

maturation until 4–6 months after the treatment. The micro- and macroscopic results may continue to evolve over the first year until the final tightening effects are seen [5].

The ablative fractionated lasers work in much the same manner as the traditional lasers. The primary difference is that fractionated lasers use a beam that is split by a lens into several microbeams [8]. This results in the partial ablation of the skin by creating columns of ablation (micro thermal zones, MTZ) while leaving a portion of the skin intact, as opposed to the traditional lasers that ablate all of the tissue in the area of concern [11]. The micro-column healing process begins with the delivery of the degenerated necrotic tissue (microscopic epidermal necrotic debris, MENDs) outward to the epidermis, which is a process unique to fractional thermolysis [6, 11]. The skin healing process then starts within the pilosebaceous unit, which serves as the progenitor from the base up through the hair shaft and then out laterally in a process known as epiboly [4]. This type of ablation produces a lower rate of overall complications and high patient satisfaction. It is particularly associated with more expedient recovery, less erythema, and decreased risk of pigmentation changes or scarring (Table 17.3). Depending on the parameters utilized, multiple treatments may be indicated to produce the ultimate desired results. Each laser system has its own protocol for treatment. The fractionated laser pulse usually can be calibrated to a variable scanning size and shape to assist in treating different topographic areas of the face. The parameters may also allow the operator to select how the pattern is delivered to the skin. These computer-generated ablative patterns spread the heat more evenly in the tissue and may help with intra- and post-procedure comfort.

Specific settings of the laser beam frequently include output power (Watts), which determines the depth of penetration; percent of coverage, determined by the distance between each column in the treated region; and the length of time the laser beam column stays in contact with the surrounding tissues (dwell-time), which prescribes the amount of collateral tissue injury. The zone of surrounding residual thermal damage is a more important factor in neocollagenesis than the depth of ablation [5]. There is some thought that ablative fractionated lasers may be superior to traditional resurfacing devices for skin tightening, given that fractionated lasers can penetrate deeper into the dermis with lower risk of injury to the surrounding skin, theoretically resulting in superior healing and reduced complications [9]. The cur-

**Table 17.1** Intrinsic and extrinsic aging factors

Intrinsic aging factors	Extrinsic aging factors
Epidermis thins	Epidermis thickens
Dermis and bones shrink	Dermis thins
Fine wrinkles	Coarse wrinkles, deep wrinkles, furrows
Pigmented spots, lentigines	Mottled, uneven, roughened skin
Dry skin	Skin growths
Muscles weaken	Epithelial atypia
Loss of elastic fibers	
Fat on face decreases	

**Table 17.2** Goals of fractionated laser resurfacing

Goals of fractionated laser resurfacing
Reduce rhytids
Reduce skin irregularities
Reduce lentigines, keratosis, benign precancerous lesions
Reduce dyschromias or uneven pigmentations
Reduce acne scarring or scars

**Table 17.3** Benefits of fractionated laser treatment

Benefits of fractionated laser treatment
Less overall complications
Quicker recovery
Less erythema
Decreased risk of pigmentation changes or scarring
High patient satisfaction

rent fractionated laser utilized by the senior author allows for a pulsed emission that produces rapid ablation of the epidermis and the superficial dermis, while the second part of the pulse has low peak power which produces targeted heating of the deeper areas of the skin [12]. Settings are not universally applicable and should be tailored to the condition being treated and the patient's goals. As the parameters are escalated to obtain more dramatic results, the length of recovery and risks of complications increase proportionately.

Examples of setting utilized by the senior author for his current laser of choice, Deka, SmartXide DOT fractional laser are:

Power: 8–30 Watts

Dwell Time: 200–2000 us

DOT spacing: 200–1000  $\mu\text{m}$

These settings are dependent on the patient's desired results, amount of down-time available, prior treatments, location of treatment on the face, and skin type. As power is increased, dwell time is increased, and spacing is decreased; the overall risk profile rises, as well as degree of results. Areas with thinner tissue need to be treated less aggressively and areas with more significant rhytids should be stretched under tension while treating for best results. Repeat passes may be indicated, and if a significant improvement is desired by the patient, then a discussion is held at the time of the initial consult regarding the necessity of performing a secondary treatment. If treating only certain facial units (perioral, periocular), either less aggressive treatment is performed or a lighter full face treatment followed by more aggressive unit coverage to help prevent demarcation lines.

## Pre-procedure Considerations

Prior to performing any ablative skin resurfacing procedure, a standard and thorough patient workup should be performed. Contraindications to laser skin resurfacing include history of hypertrophic scarring or keloid formation, use of systemic isotretinoin within the past year, recent skin resurfacing procedure, open flap procedures within the past 6 months, immunocompromise, autoimmune and collagen vascular diseases, history of severe herpetic outbreaks, and pregnancy or current lactation [4, 5]. Diseases such as vitiligo and psoriasis, which have koebnerizing features, are considered relative contraindications [7] (Table 17.4). A thorough skin analysis should be performed by the treating physician, or a full dermatologic exam should be obtained to rule out any potential preexisting skin pathology that may be altered or masked by a resurfacing procedure.

Once the patient has been deemed an appropriate candidate for laser resurfacing, alternative options are discussed with the patient in detail. Medical micro-needling is an entry level skin resurfacing procedure that may be an appropriate alternative for those patients who require or desire less

**Table 17.4** Contraindications to laser skin resurfacing

<i>Contraindications to laser skin resurfacing</i>	
History of hypertrophic scarring/keloid formation	
Systemic isotretinoin (within 6–12 months)	
Recent medium to aggressive resurfacing procedure	
Recent open flap cosmetic procedure	
Severe herpetic outbreaks	
Collagen vascular diseases	
Pregnancy/current lactation	
<i>Relative contraindications</i>	
Vitiligo, psoriasis, koebnerizing features	
Immunocompromised patients	

aggressive therapy. There are many proprietary devices that create small channels in the skin to programmed depths. With the use of micro-needling, there is no thermal effect, but the micro channels can help stimulate formation of new collagen and elastin. Application of certain topical agents at the time of the microneedling procedure can help stimulate the healing process and the overall results (PRP, Vit C, hyaluronic acid serums, etc.). Mechanical dermabrasion, though still practiced by some, has fallen out of mainstream use in favor of newer technologies given that it is both technique and practitioner-sensitive and potentially hazardous in patients with blood-borne pathogens. Chemical peels continue to be a frequently practiced technique in the field of skin rejuvenation. Chemical peels come in a variety of types and each has a unique mechanism of action that determines their effect and efficacy, as well as different concentrations that also affect their performance. The two most common mechanism of action are keatolytics (alpha-hydroxy acids, salicylic acids) and protein denaturants (TCA). Alpha-hydroxy and salicylic acids are usually suited for more superficial peels and alpha-hydroxy acids need to be neutralized to deactivate and prevent continued penetration. Trichloroacetic acid (TCA) is one of the most common agents used in chemical peels and can be applied to a level that gives predictable results. This level can be altered by the number of applications, quantity of product used, and the concentration. Depending on the patient's desires, a light peel can be performed with proportionately minimal down-time and risk of complications. These peels can be performed in a series of one treatment approximately every 2 weeks for three to five treatments. A medium peel can increase the degree of results but brings with it increased recovery time and risks. A medium peel can also be incorporated with a pretreatment (i.e., Jessner's solution) to help produce enhanced results without the risks of multiple coats. Deep phenol peels can be performed by those practitioners with more experience. They must be performed in smaller regional units under cardiac monitoring. As previously touched on, depth of penetration of the peel is dependent on many factors. The skin thickness, which varies among different in



anatomic areas, as well as skin health (pre-conditioning), must be appreciated at the time of the peel and can be evaluated intra-procedure to help determine clinical depth, which also correlates with the histology. By evaluating the “frost” of a TCA peel, which starts as an unorganized light frost (epidermis) then progresses to more transparent frost with a pink undertone (papillary dermis) to a solid white appearance (reticular dermis).

Each practitioner will have their own specific algorithm and preferences for topical agents to be used in skin preparation to post-procedure care. These may include cleansers, toners, topical retinoids or tazarotene, bleaching agents (i.e., hydroquinone, kojic acid, azelaic acid), and sun block. Antioxidants such as vitamins E and C are common agents that work to combat oxygen radicals and may appeal to the public as wholesome natural substances [13]. It takes approximately 6 weeks for the skin cell cycle to be completed, so if one is trying to prepare the skin, it is best to start these products 4–6 weeks prior to treatment. Using a more aggressive skin preconditioning program also gives the clinician an appreciation of the patient’s tolerance, motivation, and dependability. If the patient cannot tolerate the topicals well, they may not be a good resurfacing procedure candidate. Also, certain products (hydroquinone, retin A) are indicated to help reduce post-inflammatory hyperpigmentation depending on the skin type (III and higher). Microdermabrasion and light chemical peels may also help prepare the skin for a more predictable result after a resurfacing procedure. Some of these products may be stopped a few days before the procedure to decrease skin sensitivity during and after the procedure.

Once a patient and practitioner have discussed risks, benefits, and alternative treatments and the patient has elected to continue to pursue fractionated laser treatment, certain ancillary topics must be addressed. If the patient has had oral or facial herpes outbreaks in the past, the risk of developing an outbreak in peri-procedure period must be discussed and appropriate anti-viral coverage (i.e., acyclovir, valacyclovir, and famciclovir) should be initiated if indicated. Antibiotic coverage is a controversial topic that has no set standard, so this may be left up to the discretion of the performing provider. Systemic or topical steroids have no specific indication for use, but they may be administered pre- and posttreatment at the providers’ discretion given their experience to help reduce swelling and erythema determination regarding the type of anesthesia for use during the procedure usually depends on the patient’s subjective pain tolerance, the planned depth of treatment, availability of adjunctive cooling devices, and the facility’s or provider’s ability to administer intravenous or general anesthesia. In the author’s hands, IV anesthesia for medium to deep resurfacing is invaluable as a predictable level of anesthesia can be titrated to affect for patient comfort.

## Procedural Technique

If a light to medium resurfacing procedure is being performed, the patient is typically instructed to present 1 h prior to treatment. An oral analgesic (i.e., hydrocodone and acetaminophen) and an anxiolytic (i.e., diazepam) are administered, as well as a topical anesthetic (i.e., lidocaine and prilocaine cream). The patient also takes an oral antibiotic (i.e., cephalexin 500 mg if no contraindications). The patients would have started an antiviral agent (i.e., acyclovir 400 mg TID) the day prior to the treatment if they have a history of herpetic outbreaks. The surgical suite follows laser safety precautions. If intravenous anesthesia is being performed, appropriate monitors are in place, and supplemental oxygen is turned off while the laser treatment is being directly performed. The topical anesthetic is wiped off completely, the skin is cleaned with a cleanser, and degreased with acetone. The skin surface is then re-wiped with sterile water and dried thoroughly. External laser safety eye shields or, if periorbital resurfacing is being performed, metal corneal shields are utilized. Topical anesthetic eye drops (tetracaine 0.5% ophthalmic solution), then the corneal shields with lubricant (i.e., lacri-lube or ophthalmic antibiotic ointment) are placed. Moistened towels are placed around the periphery of the face to aid in fire safety. Use of a smoke evacuator is highly recommended to protect the health of not only the patient but the practitioner and assistants as well. Test spots are performed usually near the forehead hairline to evaluate skin response and patient tolerance. At this point, the areas that have been designated are treated without overlapping to prevent overtreatment. Certain areas must be treated less aggressively, such as around the eyes (to minimize risk of ectropion), and areas of bony protuberances like the over cheek bones and along the jaw line (to decrease potential for scarring). For deeper rhytids and furrows, the skin should be stretched under tension, and higher energy with longer dwell times should be used and multiple passes may be indicated. Feathering at the periphery to blend the border between the untreated and treated skin is suggested. The char may be wiped off between passes and left after the last pass to act as a wound dressing. Fine pin point bleeding may be encountered and is common when the depth of the reticular dermis is encountered. Once the treatment is complete, iced and saline-soaked gauzes are serially placed and changed to cool the skin and aid in comfort. Depending on the treating physician’s protocol, a closed versus open wound care approach can be utilized. With the closed dressing approach, one of the many proprietary dressing is utilized (films, hydrogels, hydrocolloid), which may decrease erythema, crusting, and patient care but are traditionally more costly and difficult for the patient to wear. The open technique allows the patient to directly clean the resurfaced area but is dependent on the

patient performing correctly, and most patients will experience erythema for a more prolonged period of time. The author likes to implement an open postoperative care regimen because it is easier for the patient to perform direct wound care and is less expensive. Patients need to be cautious that no trauma to the wound occurs when cleaning or sleeping and infrequently develop milia that can be treated if persistent. An emollient (i.e., Aquaphor, Vanicream, or any proprietary cream) is applied judiciously to the treated areas before discharge.

A skin chemical peel follows many of the same procedural recommendations for anesthesia and premedication. The peeling agent can be applied with a swab applicator or gauze. It is best to apply the peel in a systematic fashion in facial units and to apply equal amounts. If a glycolic acid (typically 50–70%) is performed, the acid is placed and allowed to penetrate for 1–2 min, then diluted or neutralized. Depending on the physician's experience and patient's desires, for a TCA peel (typically 15–35%) multiple coats may be applied and the skin response evaluated (as discussed in prior section) to the desired depth. Some physicians may choose to treat with Jessner's (salicylic acid, resorcinol, lactic acid, and ethanol) solution for an initial superficial peel, followed by the TCA peel. It is important to keep in mind when using this technique that more rapid and deeper penetration of the TCA will occur. The peeling agent will give results similar to that of a fractionated laser but will not achieve the same skin tightening effect over time.

## Rehabilitation and Recovery

Patients are given posttreatment instructions at their pre-laser consult. All supplies are suggested to be obtained before their scheduled treatment through a standard post-care kit or over-the-counter products if there are acceptable substitutes. Immediately upon arriving home after the procedure, patients are advised to rest with their head elevated to approximately 30°. Continued gauze or towel soaks with ice can be utilized for comfort. It is important for the patient to keep a clean environment and wash their hands before and after caring for the area. Every 3–4 h, the patient is instructed to use 0.25% acetic acid or a non-mentholated shaving cream to clean the treated skin by massaging the area lightly with their fingertips. The skin should then be gently rinsed with warm water. After patting dry with a clean towel, the patient should coat the treated area with a light coat of recovery cream or emollient. The patient is instructed that they may shower and bathe normally, while avoiding shampoo or hot water running onto the treated sight. Mild-to-moderate redness is expected for 7–10 days if moderate or deep laser treatment is performed. Patients should be counseled that erythema can persist for up to 4 months (usually in lighter

skin types I and II). Mild-to-moderate swelling is normal for 3–7 days. If peri-orbital treatment is performed, the eyelids may swell and visual fields may be decreased for 2–4 days. Oozing of clear fluid from the resurfaced sites may be seen after procedural intervention for up to 3 days usually. Patients should avoid removal of scabs by scaling or picking as this may leave a scar or cause hyperpigmentation. The patient should be advised that the skin is in a delicate transition stage while healing and must be treated gently. Pruritus is a common side effect after laser resurfacing and is typically self-limited. If bothersome to the patient, it can be treated with an over-the-counter antihistamine and mild topical steroid if indicated. The patient is instructed to avoid direct sun exposure for 3 months at the minimum. Makeup and sunscreen may be applied after the skin has rejuvenated and bland, non-fragrance, PABA-free products are recommended. Routine daily activities can begin at 7–10 days; routine skin care products can usually be restarted around 3 weeks. The patient is reminded that it will take approximately 4–6 months before the effects of the procedure have been finalized.

The safety profile for fractionated lasers is excellent when used appropriately. Most patients are able to resume normal work and social activities within 7–10 days [14]. The spectrum of post-treatment sequelae and adverse events are similar to those seen in fully ablative procedures, however they are less frequent and less severe [15] (Table 17.5). It is imperative that appropriate education on wound care is provided pretreatment, so patient can have time to review your instructions, ask questions, and obtain the necessary items. Many of the common issues patients have can be prevented with strict adherence to wound care recommendations and fall outside the treating doctor's oversight. Erythema, as mentioned previously, is typically of short duration and easily managed. Ruling out contact sensitivity is important, and infrequently topical steroids may be utilized as needed. Erythema in lighter skin (Fitzpatrick Scale I & II) is more common in extent and duration. Edema is common and as the depth increases of the treatment, so too does the edema. Elevating one's head and placing clean ice packs will help reduce the overall edema. Periorbital edema, with eyelids swelling shut, is not uncommon over the first few days and is best explained to the patient beforehand in preparation. If

**Table 17.5** Fractionated laser posttreatment sequelae/complications

Fractionated laser posttreatment sequelae/complications
Erythema/edema
Hyper-/hypopigmentation
Infection (bacterial, viral, fungal)
Pruritus
Contact dermatitis
Milia
Acne
Scarring

hypopigmentation is seen, it is a result of inappropriately deep treatment. Post-inflammatory hyperpigmentation is the most common adverse effect of laser treatment [7], especially in individuals with darker skin. This complication occurs less frequently with fractionated laser treatment and is often responsive to pharmacologic treatment (i.e., hydroquinone and tretinoin) and sun avoidance. True hypopigmentation is limited even with darker skin tones [10, 14]. Infection-related complications (bacterial, viral, and fungal) should be kept in mind any time a resurfacing procedure is performed. Appropriate evaluation and treatment are indicated as soon as an infection is suspected in order to minimize adverse results. Infections may present with increased pain, burning, and/or itching, but this is not universal. If infection is suspected, the wound should be cultured for bacteria, virus, and yeast (Gram stain, Tzank, and KOH), and empiric broad spectrum antibiotic, antiviral, and antifungal should be started if not already implemented. Milia are usually self-declaring but may need to be treated by unroofing the lesion, administration of topical retinoids, and potentially diathermy, curettage, and cryotherapy. Contact dermatitis may occur, and the offending agent should be identified and discarded. Mild anti-itch lotions or mild steroid creams may be indicated. Acne flares may occur as the oil glands recover with resurfacing; they may also be a result of too thick layers of emollient use. After appropriate education and if acne persists, topical antibiotics (i.e., erythromycin or clindamycin) or systemic antibiotics (i.e., doxycycline) may be indicated. Scarring is a rare complication with fractionated lasers, but if it does occur, it must be identified and treated as early as possible. Strong topical steroids, silicone sheets or gel, steroid injections, and pulsed dye lasers are options for treatment. Petechiae are usually self-limited, and reassurance to the patient is the only indicated treatment.

## Summary

Traditional fully ablative CO<sub>2</sub> laser resurfacing is an excellent treatment modality for facial rejuvenation, and the results are typically well worth the risk and downtime. However, as patients demand decreased downtime, less risks, and more predictable results, newer technologies have been developed to try and meet these needs. As with all new technologies, there is a learning curve associated with fractionated laser resurfacing, and there may be overly hopeful optimism that cannot meet the desires of the patient. The procedure induces skin tightening through dermal heating, wound healing, neocollagenesis, and dermal remodeling. Fractionated laser CO<sub>2</sub> resurfacing has evolved and now pro-

vides most of the benefits of traditional resurfacing, high overall patient satisfaction, and decreased negative side effects [16]. Chemical peels are a valid option/alternative for skin resurfacing that give similar skin results. The determining factor may be if more skin tightening is desired, as well as the clinician's comfort level with more invasive treatments. As with all invasive treatments, each should be tailored to the patient's desires in order to achieve overall long-term satisfying results that have met the patients' demands.

## Bibliography

1. Beer K, Bayers S. Aesthetic treatment considerations for the eyebrows and periorbital complex. *J Drugs Dermatol*. 2014;13(1):17–20.
2. Hunzeken C, Weiss E, Geronemus R. Fractionated CO<sub>2</sub> laser resurfacing: our experience with more than 2000 treatments. *Aesthet Surg J*. 2009;29:317–22.
3. Fitzpatrick RE, Goldman MP. *Cosmetic laser surgery*. St Louis: Mosby; 2000.
4. Niamtu J. *Cosmetic facial surgery*, Chapter 12, Skin resurfacing, St. Louis Missouri: Elsevier Mosby; 2011. p. 517–603.
5. Gotkin RH, Sarnoff DS, Cannarozzo G, Sadick N, Alexiades-Armenakas M. Ablative skin resurfacing with a novel microablative CO<sub>2</sub> laser. *J Drugs Dermatol*. 2009;8(2):138–44.
6. Gold M. Update on fractional laser technology. *J Clin Aesthet Dermatol*. 2010;3(1):42–50.
7. Alexiades-Armenakas M, Dover J, Arndt K. The Spectrum of laser skin resurfacing: nonablative, fractional, and ablative laser resurfacing. *J Am Acad Dermatol*. 2008;58:719–37.
8. Tresses M, Shohat M, Urdiales F. Safe and effective one-session fractional skin resurfacing using a carbon dioxide laser device in super-pulse mode: a clinical and histologic study. *Aesthet Plast Surg*. 2010;35(1):31–42.
9. Ortiz A, Goldman M, Fitzpatrick R. Ablative CO<sub>2</sub> lasers for skin tightening: traditional versus fractional. *Derm Surg*. 2014;40:S147–51. <https://doi.org/10.1097/dss.0000000000000230>.
10. Obagi S. Fractionated laser. *SURGE*, a publication of the AACS, Issue 1; 2015:20–21.
11. Lipozencic J, Makos Z. Will nonablative rejuvenation replace ablative lasers? Facts and controversies. *Clin Dermatol*. 2013;31:718–21.
12. Le Pillouer-Prost A, Zerbinati N. Fractional laser skin resurfacing with SmartXide DOT. Initial results. *Dermatitis*. 2008;19:24.
13. Hegedus F, Diecidue R, Taub D, Nyirady J. Non-surgical treatment modalities of facial photodamage: practical knowledge for the oral and maxillofacial professional. *Int J Oral Maxillofac Surg*. 2006;35:389–98.
14. Khaled M, Benedetto A. Facial skin rejuvenation: ablative laser resurfacing, chemical peels, or photodynamic therapy? Facts and controversies. *Clin Dermatol*. 2013;31:737–40.
15. Duplechain J. Fractional CO<sub>2</sub> resurfacing has it replaced ablative resurfacing techniques? *Facial Plast Surg Clin N Am*. 2013;21:213–27.
16. Kohl E, Meirhofer J, Koller M, Zeman F, Groesser L, Karrer S, Hohenleutner U, Landthaler M, Hohenleutner S. Fractional carbon dioxide laser resurfacing of rhytids and photoaged skin- a prospective clinical study on patient expectation and satisfaction. *Lasers Surg Med*. 2015;47:111–9. <https://doi.org/10.1002/lsm.22326>.

Cosmetic surgery, especially facial cosmetic surgery, has enjoyed an unprecedented increase in popularity over the past two decades. Starting with baby boomers and now generation X, the desire of the aging population to feel and look rejuvenated has made facial cosmetic surgery more accepted and therefore increased the number of procedures performed. The ultimate goal of improving one's appearance remains unchanged. However, the desire of the aging population to feel and look rejuvenated and provide a more youthful and natural appearance with faster recovery has led to new techniques.

Endoscopy has proven to be a valuable tool in almost every medical specialty. Surgical patients have benefited from smaller incisions, less morbidity, and rapid convalescence. It is not surprising that in the world of cosmetic surgery, where patients are becoming ever more knowledgeable and demanding, endoscopic procedures are increasingly popular. Of all endoscopic cosmetic procedures performed, the endoscopic forehead and brow lift has proved to be the most common and predictable of the facial cosmetic techniques [1].

In treatment of an aging face, proper diagnosis and rejuvenation for the upper third of the face is a vital. Esthetic concerns of the forehead and brow regions affect a wide range of age groups. A standard lower face and neck rhytidectomies are more commonly performed on patients older than age 45. But endoscopic brow and forehead lift, which addresses the upper third of the face may be evident for patients in their 20s and 30s because of genetic predisposition. A comprehensive examination of the forehead and the brow is necessary to fully evaluated for a wide range of interlacing problems. Skin thinning and laxity due to age and

gravity represent only a portion of the forehead and brow region dynamics. One must address all problems to achieve optimal results and patient satisfaction. Matching the diagnosis to the ideal rejuvenation treatment is essential for maximum esthetic benefit.

The endoscopic forehead and brow lift is a comprehensive operation and is not just a method used for raising the brows [2, 3]. When used properly, it can address not only brow ptosis but also dynamic muscular problems such as depressor muscles of the glabella (Fig. 18.1). And compared with traditional bicoronal technique, several articles have shown superior and long-lasting results in regards to height of the eyebrows [4–7]. By selectively combining with other rejuvenation procedures such as fat grafting, skin resurfacing, Botox, and bone remodeling, endoscopic brow and forehead lift can yield a more dramatic facial improvement. Therefore, the importance of accurate diagnosis of age-related changes is critical.

The aging process typically leads to forehead and brow ptosis for almost every patient. However, for optimal results, it is necessary to determine whether the ptosis seen around the forehead and brow region is related to brow position, upper eyelid laxity, or whether it is caused by the combination of the two. Sometimes, what some may see as ptosis in the lateral brow may actually be fat atrophy, which can be better rejuvenated with fat grafting than with lifting of the brow. Other times, dynamic lines produced by muscle activity in the glabellar region and in the forehead itself also must be addressed using neuromodulators such as Botox. Skin texture, variable hairline patterns, bony abnormalities, and asymmetries should also be evaluated.

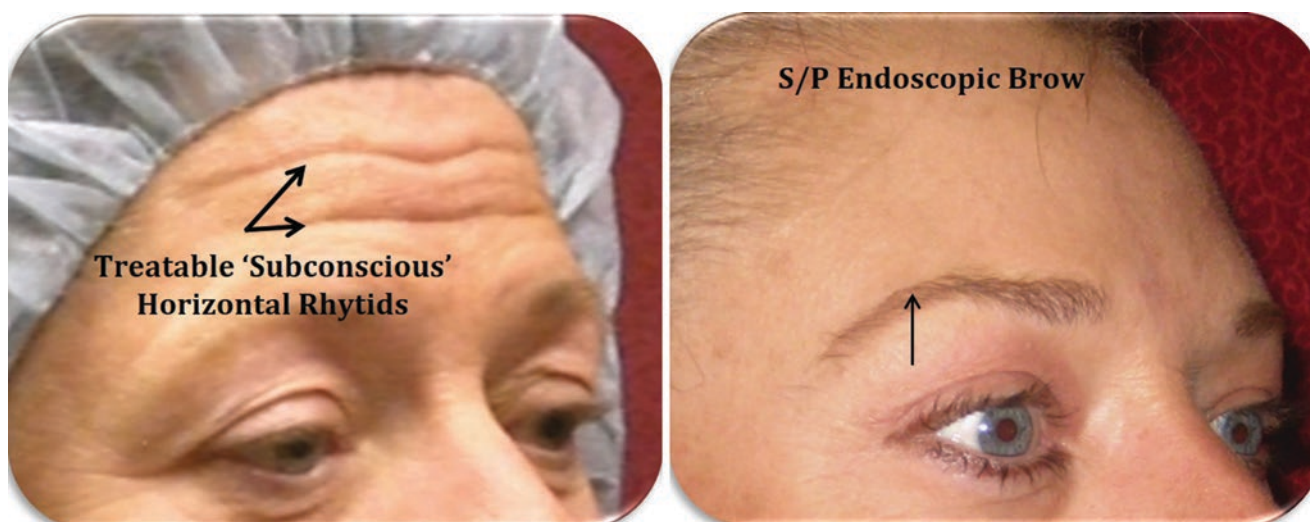Rejuvenation of the upper third of the face can be one of the most rewarding and fulfilling procedures one can offer to select patients. Specific elevation and correction of lateral hooding, along with a reduction in wrinkles and/or treatment of loss of facial volume, can result in a natural appearance, yet still can impart a tremendous improvement in the patient's overall beauty and youthful appearance. The goal of this

---

A. Cuzalina (✉)  
Tulsa Surgical Arts, PC, AACS Cosmetic Surgery Fellowship,  
Tulsa, OK, USA  
e-mail: [angelo@tulsasurgicalarts.com](mailto:angelo@tulsasurgicalarts.com)

A. Sohn  
Fellow, Tulsa Surgical Arts, Tulsa, OK, USA





**Fig. 18.1** The endoscopic forehead and brow lift is much more a comprehensive operation than just a method for raising the brows. Glabellar wrinkles resulting from dynamic muscular problems can be treated, as can lateral brow hooding, as seen here, 6 weeks postoperatively

chapter is to review upper facial third anatomy specific to the endoscopic forehead brow lift procedure.

### Anatomic and Esthetic Considerations

An ideal facial proportion described by Leonardo da Vinci can be divided in horizontal thirds. It is commonly accepted that a youthful forehead represents roughly one third of the overall facial height. In essence, the upper third which measures from trichion (the midline point of normal hairline) to glabella (the smooth prominence between the eyebrows) is equal to the distance from the glabella to the subnasale (the midpoint where the nasal septum meets the upper lip) which is equal to the distance from the subnasale to the menton (the most inferior point of the chin). A youthful appearing eyebrow is different for men than for women. The female eyebrow should be arched and positioned just above the orbital rim with the peak point of the brow between middle and lateral third of the eyebrow which usually lies on the sagittal line of the lateral limbus of the eye. In contrast, a typical male brow should lie along the orbital rim in a more horizontal fashion. Elevating the lateral one-third of the male eyebrow disproportionately more than the remaining brow will create a feminine appearance.

Lateral eyebrow position and hooding can be very rejuvenating, especially for the ideal female patient with brow ptosis. However, caution must be used to avoid over-elevation of the medial brow which can give a very unnatural or “surprised” look (Fig. 18.2).

The comprehensive anatomy of individual areas has been well described in the literature, often in relation to the specific procedure that is being performed. Therefore, the ana-

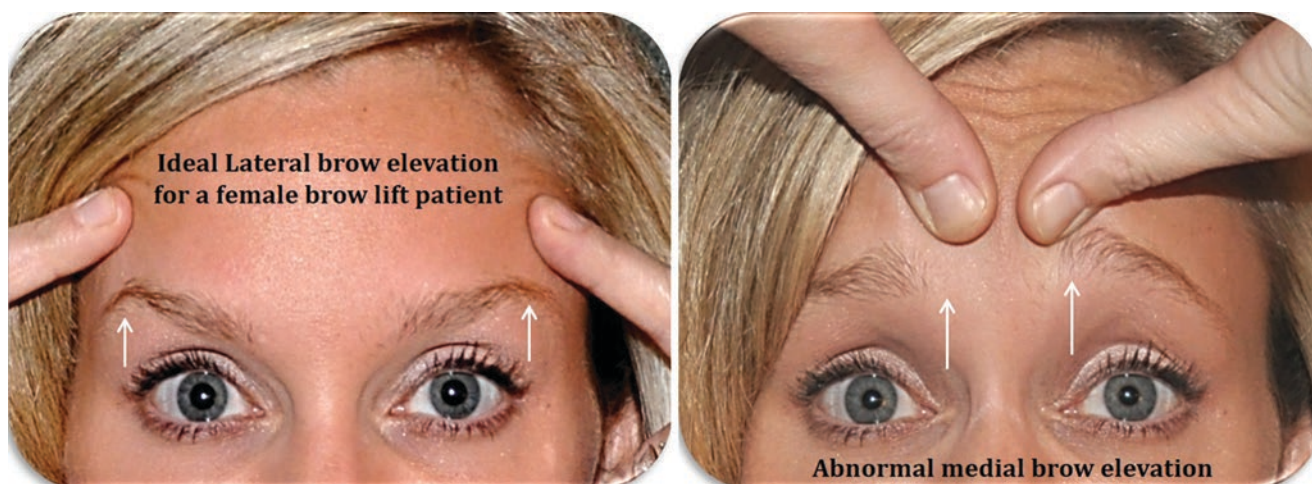
tomic discussion can be simplified by separating the specific regions into bone anatomy, muscle and fascial anatomy, vessel and nerve anatomy, and endoscopic anatomy. Each anatomic region will be addressed individually, so the reader will gain an understanding of surgical anatomy as it relates specifically to the endoscopic forehead and brow lift.

### Bone Anatomy

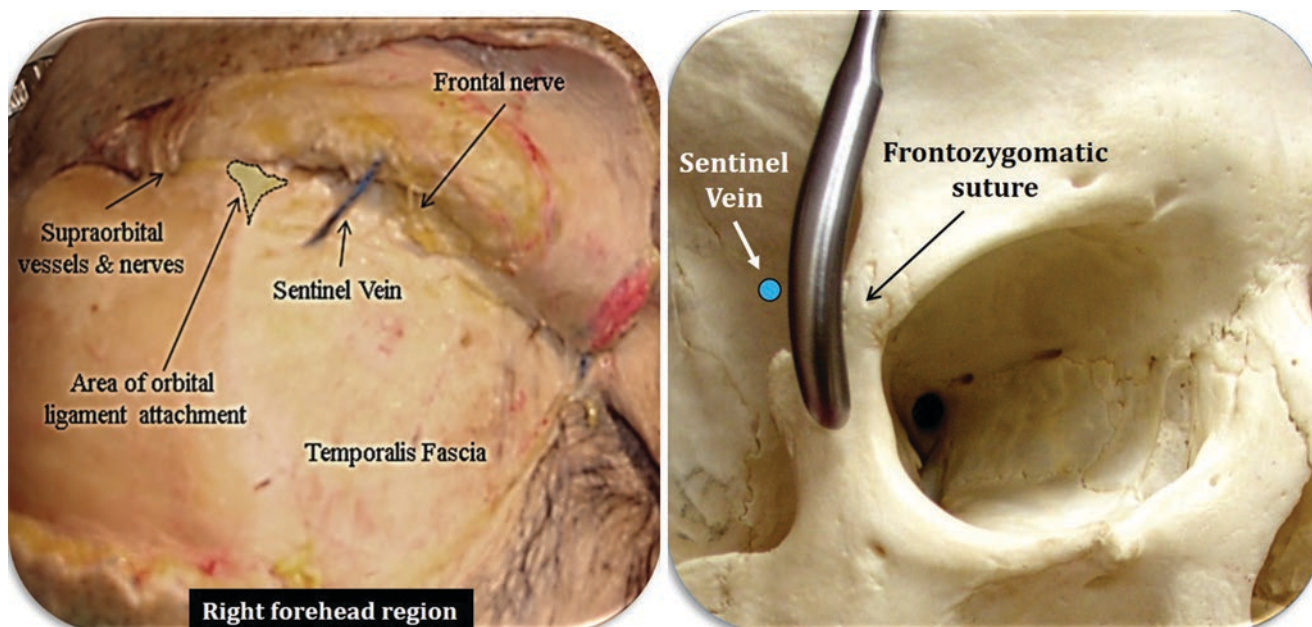
Bony landmarks of the forehead and brow region can be focused all around the frontal bone, which makes up the highest percentage of the upper facial third. Adjacent parietal bone, zygoma, maxilla, and nasal bones will be at least partially exposed when the procedure is performed.

The bony junctions (suture lines such as the nasofrontal, fronto-zygomatic, and coronal) are important landmarks because they can be clinically relevant for limits of dissection but also help assist with navigation within the surgical field during dissection.

For instance, the fronto-zygomatic suture line is an ideal location for most basic brow lift dissections to end. Surgeons may consider to perform additional dissection and elevation in the subperiosteal plane below the fronto-zygomatic suture into the cheek for increased lift in the mid-face or if the patient desires more elevation at the lateral canthal region. Overaggressive dissection and elevation around the orbit or in the submalar region particularly medially along the fronto-zygomatic suture line and lateral canthus can create an unnatural “cat eye” appearance. Just posterior and slightly inferior to this suture line is the sentinel vein (medial zygomatico-temporal vein) (Fig. 18.3). This vein is avoided or cauterized to prevent undesirable bleeding which may



**Fig. 18.2** The female shown is lifting her lateral brow in the first depiction to illustrate an “ideal” brow lift for a female patient. While the photo on the right illustrates major medial elevation of the eyebrows that produces an odd and unnatural appearance for a male or female patient



**Fig. 18.3** Dissection near the fronto-zygomatic suture line is required for adequate release and proper lateral brow elevation. However, caution is required near the sentinel vein (also known as the medial zygomatico-temporal vein), which is located 1 cm posterior to the

suture line and has the frontal nerve branch typically immediately above the vein. Cauterization or ligation of the vein must be made at the base of the temporal fascia

complicate the procedure. The vein is within 2 mm of the frontal nerve, so ligation or cauterization must be performed along the temporal fascia well below the nerve branch. Knowledge of its location in relation to the adjacent bone landmark is critical.

The nasofrontal suture line is another ideal landmark to note during dissection. The dissection needs to proceed only a few millimeters below this suture level onto the nasal bones for adequate release. If desired, nasal tip rotation can be achieved by extending the dissection below the level of the

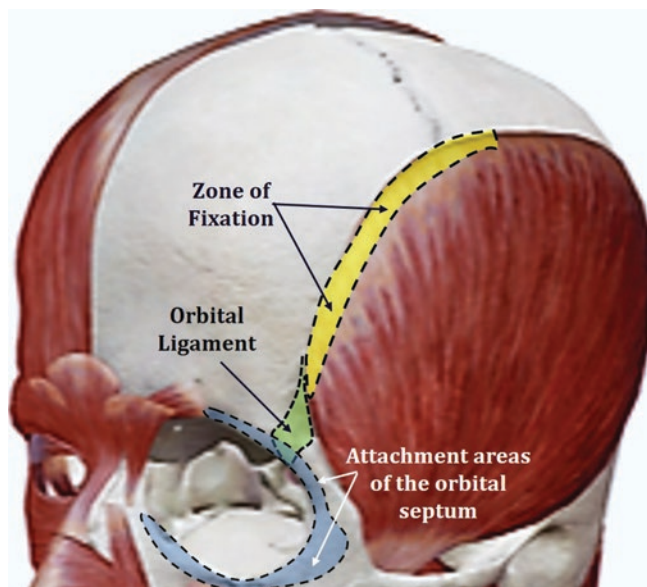
nasofrontal suture line. Procerus muscle is located near this landmark. Once identified, this paired muscle can be transected if indicated, and depending on the point of horizontal transection, the nasofrontal angle location can be altered slightly if desired.

Another important bony landmark is the orbital rim and associated arcus marginalis (orbital rim margin), which limits inferior dissection but must be well visualized and freed of periosteal attachments if the brow and brow fat pads are to be elevated for long-lasting results. Important muscle and



fascial attachments are also located medially and laterally at the level of the orbital rim. The tenacious temporal fusion line (zone of fixation), which exists along the temporal ridge, is critical to identify during dissection (Fig. 18.4). It is also important to know its location preoperatively for proper incision placement to facilitate a clean dissection under this area that enhances endoscopic visualization [8].

Another anatomical consideration during brow elevation procedure is bone thickness. Bone thickness varies in different areas of the skull, and this must be recognized when using fixation method that requires drilling into the skull. In addition, venous lakes located on the inside surface of the skull tend to be more centralized around the sagittal suture line. If bone tunnels or bone screws are planned for fixation purposes, the midline should be avoided if possible due to the sagittal sinus, as well as higher density venous lakes in this area. Thickness increases posteriorly near the occiput, but bone screw or tunnel fixation here is more challenging and not required. Caution must be taken to avoid bone penetration near the temporalis muscle in the lateral skull region, where the middle meningeal arteries could be injured. Proficient knowledge of skull anatomy including average thickness for a given location and of internal anatomy is necessary before drilling into the skull is performed for any reason. The safest site used for bone tunnels or fixation screws for brow elevations is located along the parasagittal line, approximately at the mid-pupil or lateral limbus line and just anterior to the coronal suture.



**Fig. 18.4** The tenacious zone of adherence along the entire temporal crest can be elevated bluntly once the planes are established on either side. Release of the entire zone of adherence, as well as its terminal orbital ligament just above the fronto-zygomatic suture, is critical for adequate release and long term stability of the brow lift procedure

## Muscle and Fascial Anatomy

Paired muscles of the forehead and brow region are commonly thought of as elevators and depressors. There are several depressor muscles which pull the brow down or obliquely. The frontalis is the only true elevator of the forehead, which moves upward to raise the brow. This movement, along with some static tone, maintains brow position and can produce horizontal creases over time. The frontalis muscle originates from the deep galeal plane (galea aponeurotica that connects to the occipital muscle posteriorly) [9, 10]. It inserts into the orbital portion of the orbicularis oculi muscle inferiorly, which inserts into the dermis immediately below the eyebrow. Its lateral extension fuses into the dense collection of fasciae approximately 1 cm wide, known as the *zone of adherence*; this zone extends the length of the superior temporal line and ends inferiorly just above the zygomatico-frontal suture at the fascia attachment known as the *orbital ligament* (Fig. 18.4).

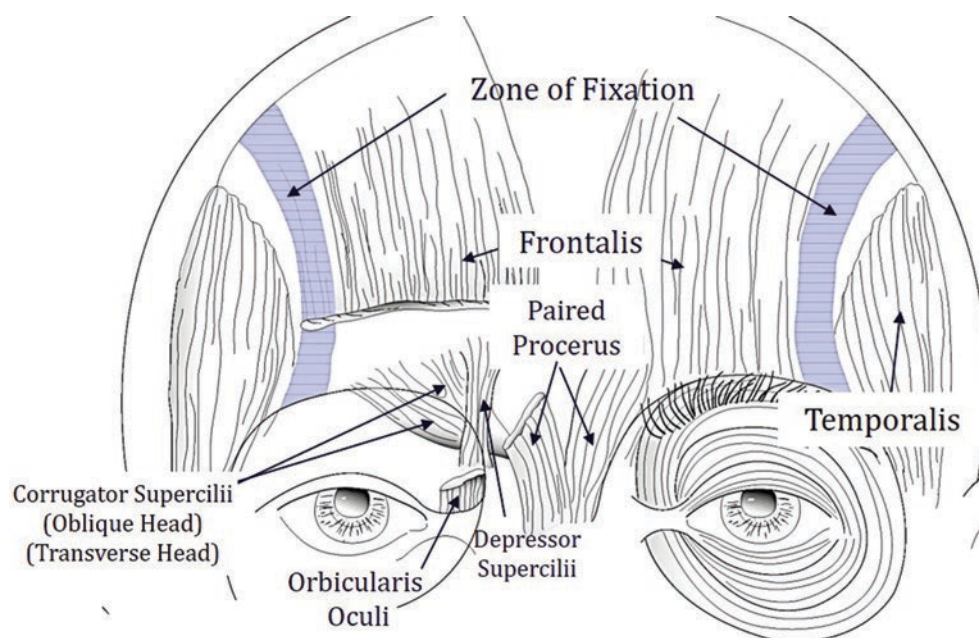
The orbital ligament is the inferior termination point of the zone of adherence near the orbital rim where connective tissue fibers of the temporoparietal fascia are fixated to the bone at the superolateral orbital rim. Lateral to the orbital ligament is the orbicularis-temporal ligament, which is the transverse fusion zone of fibers from the lateral orbicularis, the temporoparietal fascia, and the temporalis fascia.

To achieve long-term predictable results with lift procedures, it is necessary to detach and free the tissue in this clinically important anatomic area known as the zones of adherence. However, care is necessary in this region to avoid overzealous stretching and injury to the facial nerve.

The acronym SCALP applies in the forehead for the standard layers: skin, subcutaneous tissue, aponeurosis (the thick galeal fascia), loose areolar (subgaleal) plane, and perios-teum. The galeal fascia has merely fused into the frontalis muscle and its midline fascial attachments at the forehead level. This allows sliding movement over the scalp with contraction of the muscle. The frontalis and the galea may be thought of as an extension of the temporoparietal fascia in the temporal region and in the SMAS (superficial musculo-aponeurotic system) below the level of the zygomatic arch. The temporoparietal has loose and spongy clinical appearance and houses the frontal branch of the facial nerve on its undersurface in the temporal region.

There are several other paired forehead and brow muscles thought of as “depressors” which are present along the brow and facilitate facial expression (Fig. 18.5). The two most well recognized of these are the procerus and the corrugator supercilii muscles, which are present in the glabella. The procerus muscles are paired superiorly but fuse into a single muscle belly inferiorly and originate from the nasal bones and cartilages. Superiorly, procerus muscle fibers insert into the midline intervening medial frontalis muscle fibers and

**Fig. 18.5** Forehead depressor muscles are shown in this diagram, including the cut edge of the orbital portion of the orbicularis oculi. The orbital portion of the orbicularis muscle originates partially from the medial canthal tendon and from adjacent bone. The plane of dissection in a sub-periosteal plane must release and proceed through the 1 centimeter “zone of adherence” just above the temporalis fascia laterally



the overlying dermis. The procerus is responsible for depression and frowning in the midline between the eyes that often creates a horizontal crease (bunny line) across the upper portion of the nose.

The corrugator supercilii muscles are depressors that act obliquely across the glabella and produce the classic vertical lines seen during squinting or frowning which can create an “angry” appearance. The corrugator supercilii originates from the frontal bone just above the nasal bones and insert into the dermis of the medial brow. The corrugator has two heads, the oblique and the transverse, which act in unison to pull the medial brow down and together. Collectively, the paired procerus and corrugator muscles are the main depressors of the medial brow and are the muscles most commonly treated with Botox to help alleviate frown lines in the glabella. These two muscles are most frequently transected during an endoscopic brow or forehead lift to achieve a smooth and long-lasting result (Fig. 18.6).

Another depressor muscle of importance is the depressor supercilii muscle, which originates on the frontal process of the maxilla just inferior and superficial to the origin of the corrugator supercilii. It inserts into the medial frontalis fibers and dermis just above the medial brow. The depressor supercilii is important because it is superficial to the corrugator and can be inadvertently treated with Botox causing elevation of medial brow. It is also important to mind that it lies under the corrugator during a brow lift and can be transected via aggressive dissection through the corrugator muscle. Although a few patients with very low medial brow position may occasionally benefit from this maneuver, it more often causes over-elevation of the medial brow and creates the “surprised” look.

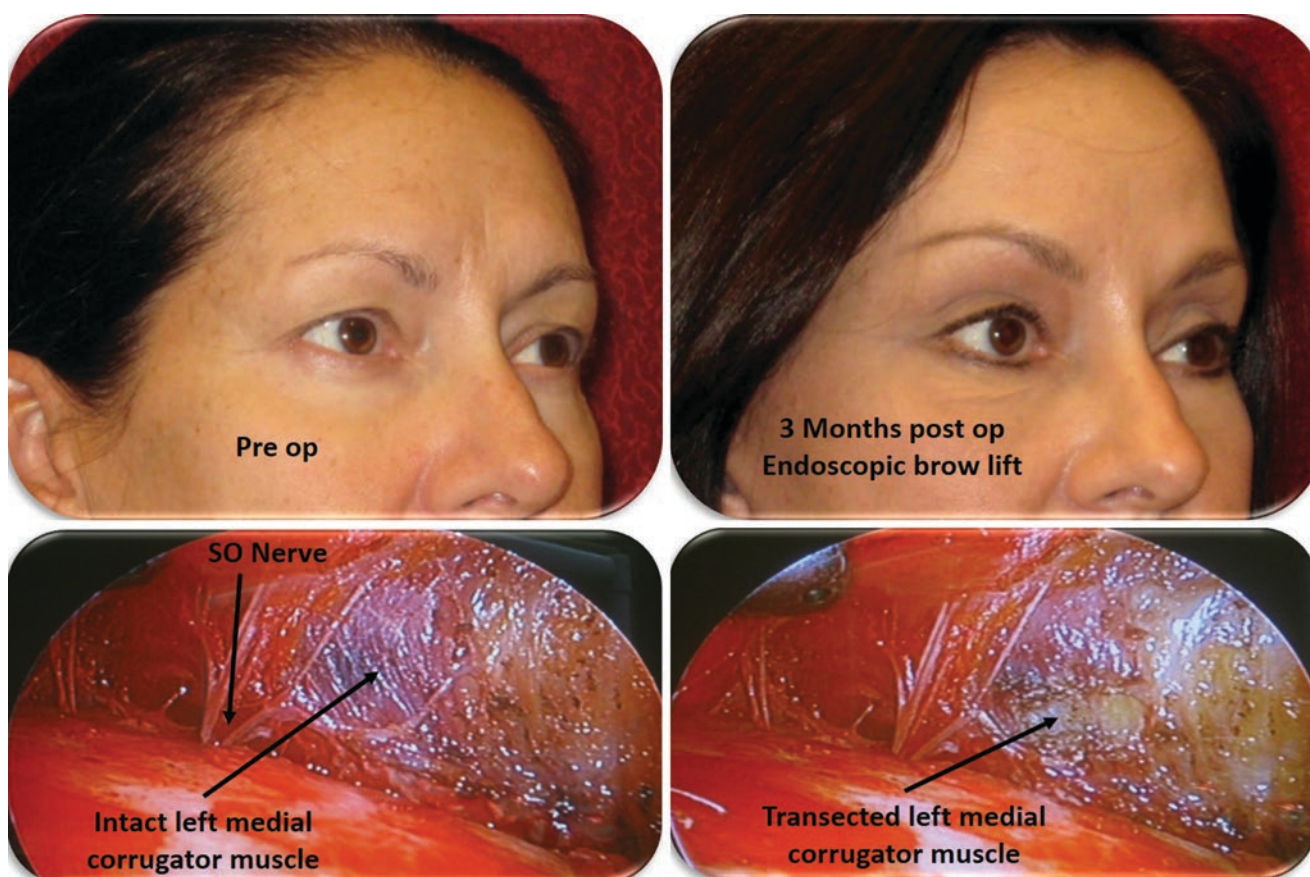Superficial to the depressor supercilii is the orbital portion of the orbicularis oculi, which inserts into portions of the adjacent depressors, the surface of the inferior frontalis, and the dermis below the brow. The orbital portion of the orbicularis muscle originates, in part, from the medial canthal tendon and from the adjacent bone. Deep to all the depressor muscles is the galeal fat pad, which lies directly below the transverse head of the corrugator and helps to identify the locations of muscular landmarks. Clinically, the galeal fat is usually exposed when the periosteum is transected along the orbital rim.

Finally, paired temporalis muscles are located in each temporal fossa, where they originate and then insert onto the coronoid process of the mandible. The importance of these muscles during upper facial rejuvenation is most often related to its overlying temporalis fascia, which can be used to delineate surgical planes and aid in fixation.

The spongy temporoparietal fascia is superficial to the dense and shiny white appearing temporalis fascia which houses the frontal branch of the facial nerve within its deep surface. The temporalis fascia is adherent to the temporalis muscle below and splits into superficial and deep layers in the lower half of the fossa. For consistency, the superficial layer of the deep temporalis fascia describes only that portion of the deep temporalis fascia that is present at the level of the split. The area below is referred to simply as the temporalis fascia, which is the deep, thick fascial layer seen clinically from the temporal crest down to the zygomatic arch.

One method of fixation during brow lifting involves using suture to fixate the temporoparietal fascia from below a skin incision to the adherent temporalis fascia in a





**Fig. 18.6** The patient and endoscopic view demonstrates the power of an endoscopic brow lift to elevate the outer brow, as well as improve dynamic and static glabellar lines. The endoscopic view shows the

medial left corrugator muscle (which produces vertical glabellar lines) before and immediately after transection with needle tip cautery

more superior position to elevate the lateral brow and upper cheek. Some surgeons advocate removing a window of temporalis fascia during this suture fixation procedure and exposing the underlying temporalis muscle in the hope of gaining additional fibrosis and improving fixation longevity.

### Vessel and Nerve Anatomy

Blood supply to the upper face and scalp is abundant and comes from multiple sources. Several major blood vessels of the upper face and scalp originate from the external carotid, including the superficial temporal artery and the facial artery. These vessels give rise to the blood supply in the medial canthal region via the angular artery and in the lateral canthal region via the frontal or anterior branch of the superficial temporal artery. The internal carotid artery branches to the middle meningeal artery and to the ophthalmic artery, which gives rise to the supraorbital and supratrochlear arteries that exit their respective foramina and supply most of the forehead and mid-scalp region. The terminal arterial branches

form multiple and significant anastomoses with adjacent vessels in the upper face.

Venous drainage of the upper face follows the respective arterial supply but can have some variations. However, one particular vein, the *sentinel vein* (medial zygomatico-temporal vein) is relatively consistent in its travels. The sentinel vein runs perpendicular through the temporalis fascia at a location approximately 2 cm lateral or posterior to the lateral canthus or approximately 1 cm lateral or posterior to the zygomatico-frontal suture line. During endoscopic procedures, care must be taken when elevating the tissues inferior to the zygomatico-frontal suture in the subperiosteal plane.

Careless and over dissection laterally in the area can cause tears and injury to the sentinel vein, which can create problems such as bruising and impaired field of visualization.

Nerve supply to some extent parallels the arterial supply. The supratrochlear and supraorbital nerves, which comprise the majority of sensation to the forehead, exit the same foramina or notch as the same named blood vessels. These sensory nerves originate from the first division of the trigeminal nerve. The supraorbital nerve has two divisions after exiting its foramen. The deep (or lateral) division sup-

plies the more lateral and posterior portion of the forehead and scalp. The superficial (or medial) division pierces the frontalis early in its course and runs superficial to the muscle supplying sensation to the lower forehead and the mid-forehead along the mid-pupil line.

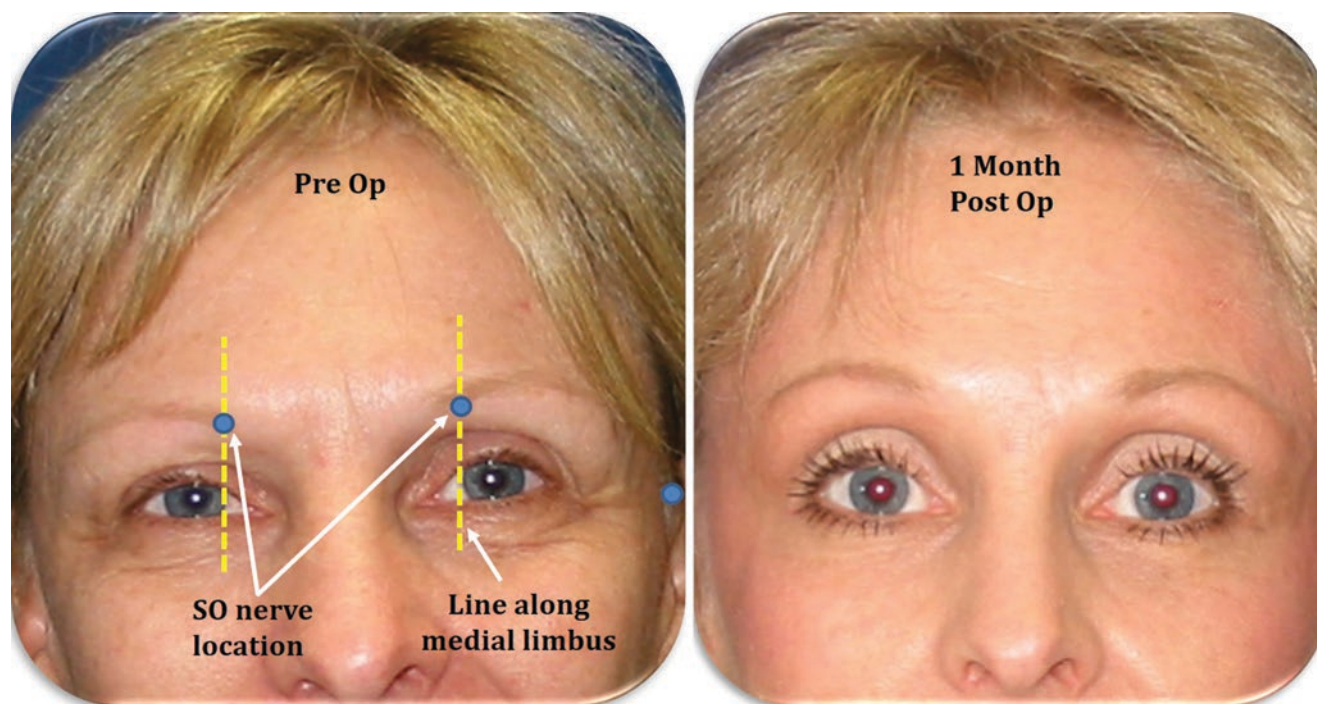
The bony exit point of the supraorbital nerve is relatively consistent. The supraorbital foramen or notch is typically found within 1 mm of a line drawn in a sagittal plane tangential to the medial limbus [7] (Fig. 18.7). This point can be marked on the skin of the brow to give the surgeon a reference point that reveals the exit point of this important structure. The deep division has been known to exit from another foramen as often as 10% of the time and may be as high as 1.5 cm above the orbital rim. Therefore, some surgeons advocate that blind (non-endoscopic) inferior dissection from the scalp above should be performed only to within 2 cm of the orbital rims and that should be followed by endoscopic guidance below this point to decrease the chances of nerve injury [5, 11–16].

The supratrochlear nerves exit near the orbital rim, an average of 9 mm medial to the exit of the supraorbital nerve. The paired nerves supply sensation to the mid-forehead with some overlap from the supraorbital nerves. Infratrochlear nerves which also originate from division one of the trigeminal nerves exit just below the supratrochlear nerves around the medial orbital rim to supply sensation to the upper nose

and the medial orbit. Zygomatico-frontal and zygomatico-temporal nerves originate from the second division of the trigeminal nerve to exit their respective small foramina and supply sensation to the lateral orbit and the temporal regions of the face.

Motor innervation to the forehead and the glabella is supplied by the facial nerve (cranial nerve VII) (Fig. 18.8). The frontal (or temporal) branch of the facial nerve supplies the frontalis muscle, the superior portion of the orbicularis oculi muscle, the superior portion of the procerus muscle, and the transverse head of the corrugator supercilii muscle. The zygomatic branch of the facial nerve supplies the medial head of the orbicularis oculi muscle, the oblique head of the corrugator supercilii muscle, the inferior portion of the procerus muscle, and the depressor supercilii muscle.

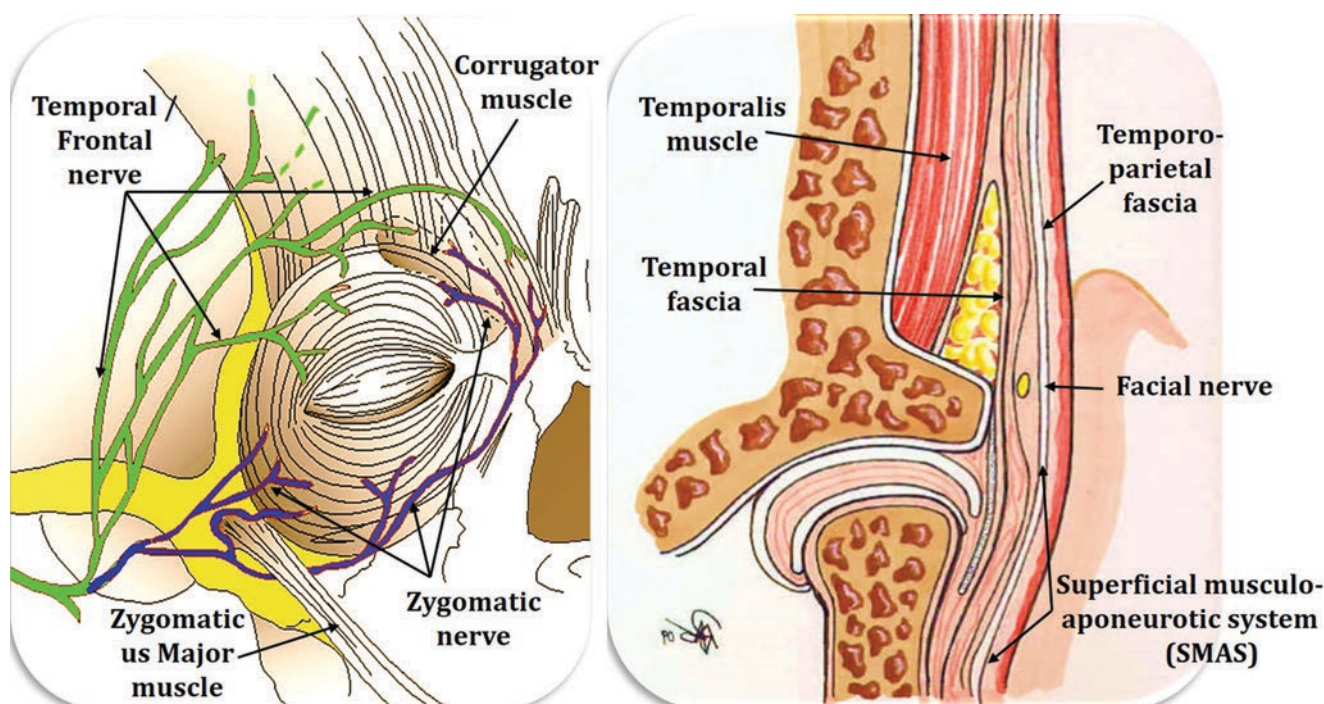
The auriculotemporal nerve originates from the third division of the trigeminal nerve and supplies sensation in front of the ear, to the temporal skin above the zygomatic arch, and to the skin that courses along the superficial temporal artery. Clinically, this nerve may be confused with the frontal branch of the facial nerve during a facelift or temporal dissection during brow-lifting procedures [17–19]. It can be distinguished from the facial motor nerve due to its anatomic location. This sensory nerve runs within 1 cm in front of the tragus of the ear and parallels the superficial temporal artery. In comparison, the much more important frontal branch of



**Fig. 18.7** The figure demonstrates a 53-year-old woman before and 1 month following an isolated endoscopic brow lift. The supraorbital foramen or notch typically is found within 1 mm of a line drawn in a sagittal plane tangential to the medial limbus, as shown here. This point

can be marked on the skin of the brow to give the surgeon an orientation point from which the neurovascular bundle exits its foramen. Plus, adjacent key muscle groups can be identified, such as the corrugator muscle that is found on each side of this nerve and vessels





**Fig. 18.8** The frontal or temporal branch of the facial nerve supplies the frontalis muscle, the superior portion of the orbicularis oculi muscle, the superior portion of the procerus muscle, and the transverse head of the corrugator supercilii muscle. Whereas the zygomatic branch of the facial nerve supplies the oblique head of the corrugator supercilii muscle, the medial head of the orbicularis oculi muscle, the inferior

portion of the procerus muscle, and the depressor supercilii muscle as shown. The temporal nerve is shown in this cross-sectional diagram through the temporomandibular joint and zygomatic arch. The facial nerve runs directly below the temporo-parietal fascia above the arch, which is contiguous with the SMAS fascia below the arch, as well as the platysma in the neck

the facial nerve runs an average of 2 cm in front of the tragus when it crosses the zygomatic arch at a more oblique angle and at a deeper level just below the SMAS at the arch. The motor branch is located just below the temporo-parietal fascia immediately above the arch. The frontal branch of the facial nerve typically has already divided into two rami at the level of the arch and into at least four branches by the time it reaches the level of the eyebrow.

## Endoscopic Anatomy

Initial incision and dissection must be performed to gain adequate space prior to the endoscopic equipment. Early dissection is performed in the posterior scalp, in the mid-forehead and upper forehead, and in temporal regions. Elevation of the deep tissues in this “safe zone” is essentially performed bluntly and blindly through each of the small scalp incisions leaving the endoscopic-guided dissection for the inferior forehead or approximately the last two centimeters above the orbital rim and zygomatic arch. Incisions and specific tissue release and fixation techniques are highly variable among surgeons. It is this author’s preference to dissect in a completely subperiosteal plane medial to the temporal crest and in the plane immediately above the temporalis

fascia below the temporal line on each side. Subperiosteal dissection in the lateral forehead helps to prevent injury to the deep or lateral division of the supraorbital nerve, which runs in the subgaleal plane near the zone of fixation. Others begin their dissection in a subgaleal plane in the posterior scalp [20–35]. Regardless of preference, adequate space must be created in the upper areas of the scalp to allow for placement of an endoscope to aid dissection in the lower forehead near important anatomic structures.

The first anatomic landmark that the surgeon must consider during dissection is the zone of fixation along the superior temporal crest. A less tenacious zone of adherence is present along the entire temporal crest that can be elevated bluntly with the use of finger dissection at the hairline level and a couple centimeters below. However, the inferior edge of the temporal crest found near the superior-lateral orbital rim usually requires endoscopic guidance for maximum release. Complete adherence release is especially important below the orbital ligament intermix of fibers from the periosteum, galea, temporalis, and temporo-parietal fascia interlace and fuse to form a zone of adherence at this part of the upper lateral orbital rim, much in the same way that the layers of tissue planes condense at the level of the zygomatic arch. The temporal nerve has branches within this ligamentous type of structure just above the brow level. During dissec-

tion, care must be taken to remain against the bone and temporalis fascia below to avoid nerve injury. Another fibrous attachment known as the orbicularis-temporal ligament is located in this area and contains small motor nerve fibers. The orbicularis-temporal ligament represents the decussation of fibers from the temporoparietal fascia and the temporal fascia that extends laterally from the orbital ligament.

The zone of adherence becomes most tenacious near the orbital ligament at the orbital rim level. Meticulous dissection is required at this point to avoid nerve injury, as well as injury to the sentinel vein, which is located within the orbicularis-temporal ligament approximately 1 cm lateral and inferior to the zygomatico-frontal suture [36–44]. Careful dissection can expose an intact sentinel vein that can be seen piercing through the temporal fascia at a perpendicular angle to enter the temporoparietal fascia above.

Dissection medial to the lateral orbital rims in the subperiosteal plane will expose the entire superior orbital rim from each zygomatico-frontal suture. The curvature of the rims must be visualized so that transection through the periosteum can be made at rim level (arcus marginalis). The nasofrontal suture may not always be seen but can be felt with the periosteal elevator when used to elevate tissue into the upper nasal region. Subgaleal fat often is encountered immediately during transection through the periosteum across the entire orbital rim except when directly behind the supraorbital nerve at the rim level where the deep (or lateral) division of the nerve is closely adherent to the periosteum. Preoperative marking of a point on the brow at a level tangential with the medial iris (limbus) helps easily identify the location of the supraorbital vessels and nerves. By identifying important structures, dissection through the periosteum in this region is performed slowly and superficially to avoid injury to these structures.

The transverse head of the corrugator supercilii is visualized at the orbital rim level behind a portion of the supraorbital vessels and nerves. The corrugator muscle can be transected or partially excised here, as well as medially. As dissection proceeds medially, the oblique head of the corrugator is encountered and with transection through this portion of this muscle, the supratrochlear nerve and the depressor supercilii muscle may be seen and protected from injury. Medially in the glabella, the procerus muscle is seen and is variable in thickness. Care should be used to avoid over-resection in thin patients to prevent an atrophic defect in the glabella caused by excessive and aggressive muscle resection. Deeper dissection toward the skin level under the brow will lead to the orbicularis oculi but is usually not necessary to gain the desired effect, except in the lateral orbicularis, where limited transection may improve lateral brow elevation. Also, transection through the periosteum can be performed at higher levels in the midline under the frontalis muscle but is only required when deep horizontal lines are

present. It is important to gain complete release of the retaining lateral ligaments, transection of those muscles that are causing glabellar lines, and adequate separation of periosteum along the orbital rim to attain elevation of the brow and forehead tissues for the most pleasing and long-term aesthetic result.

---

## Preoperative Evaluation and Surgical Preparation

A correct diagnosis and appropriate treatment plan is vital to ensure that a patient will not be disappointed. First, the clinician must determine whether that patient would benefit from a brow or forehead lift and then must select the most appropriate surgical procedure. Frequently, the novice surgeon may only notice the horizontal forehead lines as an indication for a brow lift. Unfortunately, this is much less of a problem for most patients than is a low lateral brow position (hooding) or glabellar creasing. As previously discussed, the ideal female eyebrow should be arched and positioned just above the orbital rim with the peak point of the brow between middle and lateral third of the eyebrow. On average, the lateral one third of the brow lies 5–10 mm above the rim. Men require a more straight-up elevation of the entire brow to avoid feminization of their appearance which can be caused by over-elevation of the lateral brow. Some men may benefit from a standard upper blepharoplasty and a local transpalpebral brow lift if brow ptosis is nominal. As with any cosmetic surgery, a risk/benefit decision is made and must conform to the actual patient desires and expectations. Patients must be educated about the risks and about what can *realistically* be achieved. Even with fairly aggressive muscle resection and forehead elevation, new dynamic lines often are formed in the upper face and the glabella following surgery. Lateral crow's feet lines caused by action of the orbicularis oculi while smiling may appear improved following a brow lift achieved by unfolding of the muscle. However, these lines are not completely treated by brow lifting alone. The patient must understand that other treatment modalities such as Botox therapy may be required to manage these particular lines on an ongoing basis.

In addition to brow ptosis and lines in the forehead and glabella, the condition of the patient's skin must be evaluated and addressed. Intrinsic skin damage and collagen changes from the effects of sun, age, and smoking cannot be treated by lifting alone. Topical skin care (e.g., Retin A, microdermabrasion, pulsed light therapy, sun block), along with possible surgical resurfacing, must be considered. In general, the forehead can be treated carefully with simultaneous chemical peels or laser skin resurfacing into the dermal level when brow-lifting procedures are performed, provided that the lifting technique is a subgaleal or subperiosteal technique,



rather than a subcutaneous lift. Finally, bony irregularities or hypertrophic bony orbital rims can be evaluated for treatment by means of a cephalometric radiograph or a computed tomography (CT) scan as required. Bony contouring can be performed on a limited basis endoscopically, but major reduction for significant bone hypertrophy such as frontal bossing is best achieved through an open (coronal) approach. However, bone reduction is limited by pneumatization of the frontal sinus and is best evaluated by CT. Treatment planning for placement of bone tunnels for fixation with brow lifts does not require a preoperative CT scan; however, a standard cephalometric radiograph may reassure the surgeon regarding the thickness of available corticocancellous bone.

As with any surgical procedure, appropriate preoperative labs and other indicated tests must be performed. Pre- and postoperative care should be discussed and written instructions are given including instructions for washing hair with antibacterial soap (Hibiclens®) or other antiseptic type shampoo and avoidance of hairspray or other hair products immediately prior to surgery. The patient should be thoroughly instructed on the critical need to avoid all medications that may cause platelet dysfunction and excessive bleeding (including aspirin, other nonsteroidal anti-inflammatory drugs [NSAIDs], vitamin E, and many over-the-counter herbal medications) for 2 weeks prior to surgery. Endoscopic techniques require a very dry operating field; thus, strict avoidance of these medications is required, as is proper preoperative injection of vasoconstrictive agents.

Prior to administration of anesthesia, five standard photos are taken, and the patient is marked while awake and sitting up. After induction of general anesthesia or IV sedation, the patient is prepped and is injected with local anesthesia with epinephrine. It is the author's preference to lidocaine 1% combined with 1:100,000 epinephrine along the entire superior orbital rim, glabella, and lateral orbital rim. Tumescence anesthesia solution (250 mL normal saline mixed with 1 mL 1:1000 epinephrine and 20 mL 2% lidocaine) then is injected into the remaining upper forehead, temple, and posterior scalp. Careful injection into desired tissue planes helps to prevent hematoma formation during injection and allows for a nearly bloodless procedure. Minor shaving of hair along the marked incision lines can be performed if desired immediately before the final prep and drape, but this usually is not necessary.

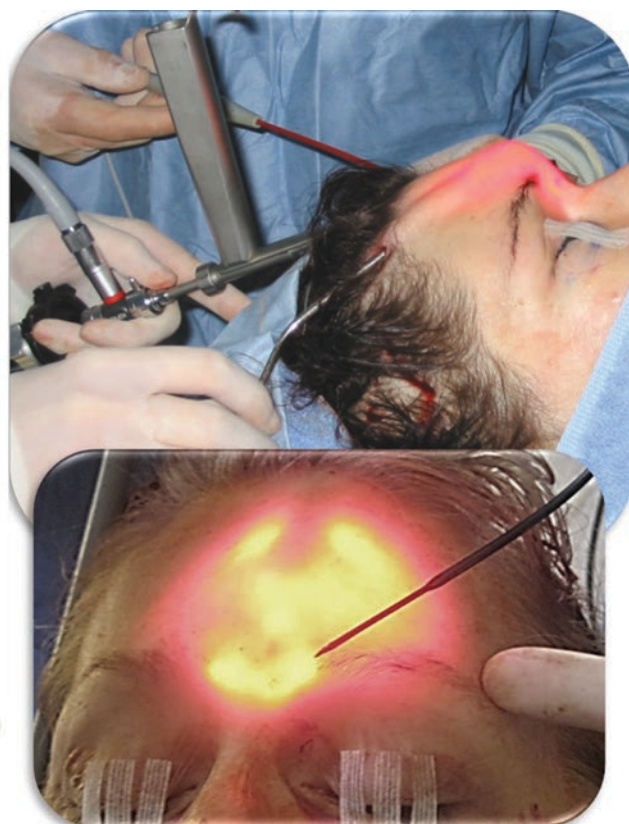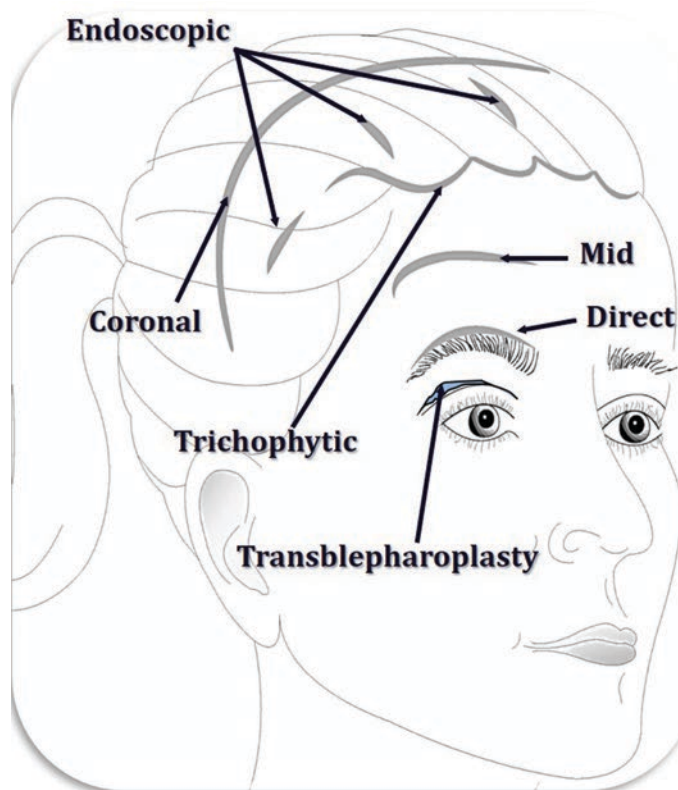
## Endoscopic Forehead and Brow Lift Technique

The first known endoscopic surgery began over a century ago with Nietzsche's description of a crude cystoscope. Nevertheless, modern surgical endoscopy did not gain significant popularity until the 1980s. Endoscopic surgery gained popularity

with upper GI exams, followed by intra-abdominal surgery. However, facial endoscopic cosmetic surgery did not really begin until the early 1990s. Over the past two decades, the endoscopic forehead and brow lift procedure has been considered by many to be the state-of-the-art procedure for upper facial rejuvenation. It is predictable and versatile and can be combined with many other procedures. The most notable benefits of the endoscopic technique include smaller scars hidden in the hairline and selective brow elevation without the need for removal of any skin or hair.

This technique involves strategic placement of several incisions behind the hairline for access for initial blunt dissection, followed by insertion of the endoscope and other surgical instruments. Other incisions can be used as ports for dissecting instruments such as periosteal elevators, electrocautery lasers, tissue graspers, and suction devices. Incision (port) design and placement as well as fixation points varies among surgeons. This author prefers to place five separate 2.5 cm incisions for easy access and for ideal fixation placement. Each of these five incisions begins approximately 1 cm posterior to the hairline. One is placed in the midline of the sagittal plane and two are placed in the parasagittal plane tangential to the lateral third of the brow, where maximum lift is typically desired in females. These parasagittal incisions can be moved slightly more medially for male patients to attain a more even brow elevation. The midline incision plus the two parasagittal incisions are aligned vertically to avoid unnecessary transection of sensory nerves originating from the supraorbital nerves below. The two parasagittal incisions are placed medial to the temporal crest to gain access to skull bone rather than to the temporalis fascia for more secure fixation (Fig. 18.9). The frontal bone in this location of the parasagittal incision is also one of the thickest regions, as well as with a low density of venous lakes helps to prevent accidental intracranial injury during bone tunnel creation or placement of fixation bone screws. Another important factor for placing the incision medial to temporal crest is to allow the clinician to easily gain access to the subperiosteal plane. Accidentally placing the parasagittal incisions too far laterally over the zone of fixation or temporalis muscle will make pocket development difficult and obscure future endoscopic visualization.

Finally, two temporal incisions are made, one on each side of the head, for direct access to the thick temporal fascia. These incisions are placed perpendicular to the desired elevation vector from the lateral canthal region. Coincidentally, the temporal incision parallels the course of the temporal branch of the facial nerve, which is located 2–3 cm inferior to this incision. It also parallels the superficial temporal artery and vein. Sensation and vascular supply to the scalp are less compromised by arranging the three medial incisions on a vertical axis and the two temporal incisions in an oblique position to parallel the nerve and blood supply in each area.



**Fig. 18.9** Multiple forehead and brow lift incisions are possible and shown in the diagram. The two most common are the trichophytic which is great for high hairlines versus the five small incisions of the endoscopic techniques for patients with short or average hairlines.

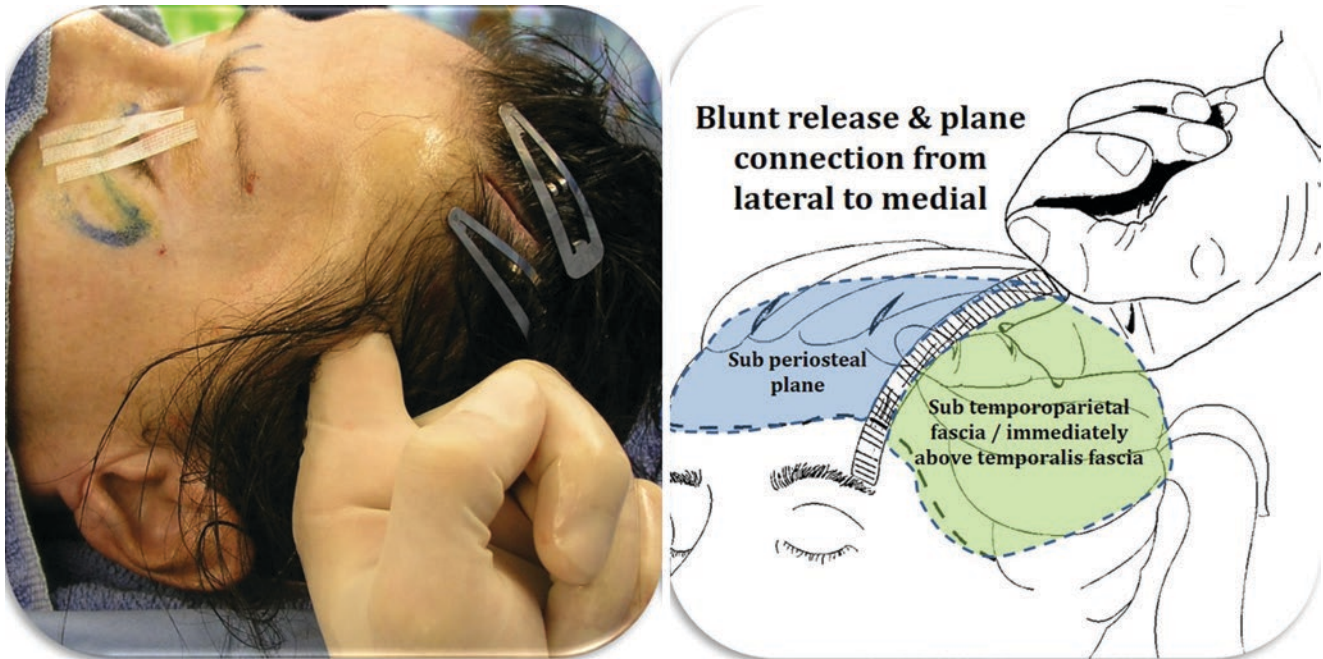
Intraop views of an endoscopic technique demonstrates the classic placement of the scope centrally, the cautery from a sagittal incision, and suction laterally

Dissection is performed through the above incisions, down through the periosteum medial to the temporal crest and down to the temporalis fascia lateral to the crest (some surgeons may elect the subgaleal plane rather than the subperiosteal medially). Many surgeons, including this author, believe that total subperiosteal dissection medial to the temporal lines rather than subgaleal dissection leads to better fixation and long-term stabilization [45–63].

Blunt and blind dissection can be carried out after reaching the subperiosteal and subtemporoparietal planes through the five incisions. Finger dissection and long, curved endoscopic periosteal elevators are used to elevate the tissue anteriorly to a point 2 cm above the orbital rims and the zygomatic arch. Posteriorly, blunt dissection should be used to elevate the temporal tissues to a few centimeters behind the ear, where the temporal fossa becomes self-limiting. Subperiosteal dissection must elevate the scalp at least 10 cm posteriorly but can extend as far as the lambdoid suture. Once these areas have been dissected, a connection can be made from the temporal region to the subperiosteal dissection through the upper portion of the zone of fixation at the temporal crest by finger dissection (Fig. 18.10). Avoid blind release of the

more inferior portion of the temporal line where the facial nerve crosses. Endoscopic-guided dissection here will help prevent nerve injury [64–66]. Finger dissection through the upper zone of fixation should proceed from the temporal incision toward the medial scalp rather than vice versa to prevent creation of a false tunnel in the spongy-appearing temporoparietal fascia. False tunnels along the temporal crest create problems when inserting the endoscope through the parasagittal port to visualize the lateral forehead. This will place the plane of dissection more superficial within the temporoparietal fascia, which greatly increases chance of nerve injury. Therefore, it is critical to stay firmly against the periosteum and the temporalis fascia when initially elevated the scalp and forehead.

Following blunt elevation of the scalp from all incision ports, the endoscope is inserted usually through one of the three medial incisions. Poor initial blunt dissection will make the initial endoscopic insertion feel very tight, and care must be taken not to perforate the skin through excessive retraction. Medial dissection is performed down over the nasofrontal suture and the orbital rims under direct endoscopic vision with a curved and smooth rounded elevator to avoid inadvertent



**Fig. 18.10** Two diagrams shown are of the left temporal-forehead region demonstrating dissection planes initially performed prior to endoscope insertion. The lateral area is taken down to immediately above temporalis fascia while the scalp medial to the zone of adherence

is elevated in the sup periosteal plane via blind periosteal elevator dissection. The two planes are then joined as shown with finger dissection from lateral to medial to avoid a false tunnel that the endoscope could inadvertently enter

tent tearing of the periosteum. The periosteum may be thin in some patients and a straighter elevator may be used to transect the periosteum at the level of the rim (arcus marginalis). However, the entire rolled edge of the orbital rim must be visualized before proceeding with periosteal incision. Typically, the periosteum is more precisely incised with a needle tip cautery or laser on a low power setting. The supra-orbital nerves and vessels as described earlier are at a level tangential with the medial limbus and are immediately behind (superficial to) the periosteum from the internal endoscopic view. Periosteum release can be avoided in the area of these nerves and vessels to avoid major nerve trunk transection or injury to these vital structures. Suction is required to maintain a clear view when cautery or a laser is used. Temporal incisions work well as suction ports during dissection over the rims because the endoscope and cautery take up most of the room through any of the middle three incision sites. At this point, transection can be performed through the corrugator supercilii muscles and the procerus in a clear and near bloodless field. If unwanted bleeding is encountered and cannot be controlled easily with pinpoint accurate cautery, then pressure should be applied externally over the rim until improved visualization allows for control of bleeding without nerve injury.

Vertical rhytids in the glabella created by the corrugators can be improved greatly by transection through the corrugator muscles. Likewise, horizontal glabellar lines are treated by transection of the procerus muscle, which creates these

particular facial wrinkles or “bunny lines.” Some surgeons recommend more aggressive surgical avulsion of these muscles with endoscopic biopsy forceps [67–79]. Aggressive muscle removal may lead to more permanent treatment of glabellar lines compared to isolated transection only, but this approach should be avoided in most cases because of the increased risk of significant postoperative irregularities and abnormal facial expression. As a rule, patients prefer a more natural appearance with some minor return of frown line expression over risking a bizarre facial expression and glabellar depression from atrophic fibrosis.

Once the periosteum has been completely freed across the orbital rims and appropriate muscles have been treated, the cut periosteal edges are separated (periosteal elevators work well for this) by at least 1 cm to facilitate release at the arcus marginalis. Adequate tissue release is critical for significant and long-term brow elevation. Next, the lateral orbital rim must be exposed in the subperiosteal plane after careful release below the zone of fixation and orbital ligament. Dissection along the anterior and inferior aspect of the temporal crest must be performed cautiously to avoid temporal nerve injury. Overzealous retraction of the dense tissue in this area can cause injury to the nerve it contains. Staying tight against the periosteum and the temporalis fascia helps to prevent nerve damage and produces clean and bloodless dissection. Slowly creating a distinct plane of dissection down just past the zygomatico-frontal suture line and avoiding excess retraction help to prevent unwanted bleeding from



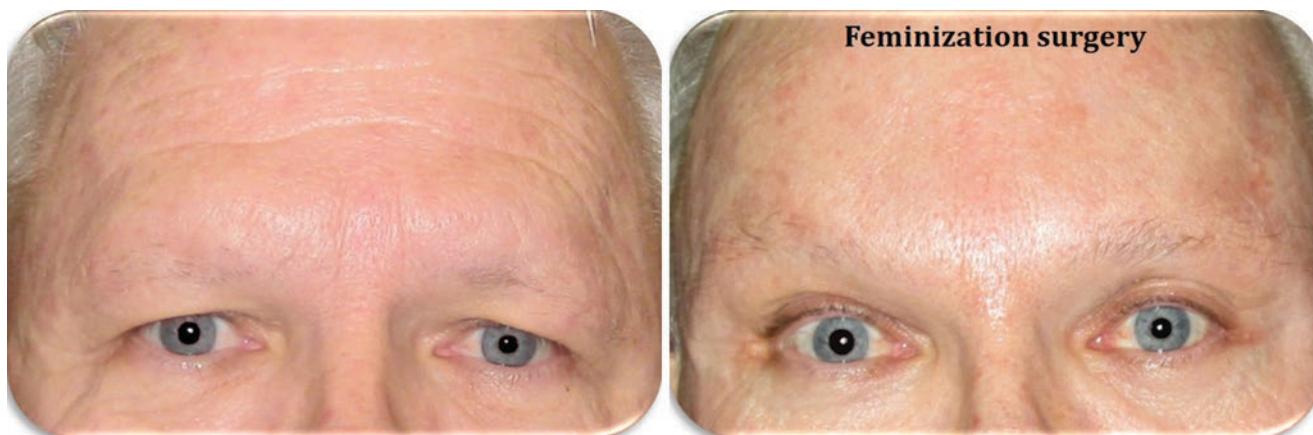the sentinel vein (medial zygomatico-temporal vein). The sentinel vein as previously described in the anatomy discussion need not be sacrificed for a customary endoscopic forehead and brow lift.

Dissection for a standard endoscopic brow lift also need not proceed all the way to the zygomatic arch but can stop approximately 1 cm above this level. If an extended mid-facelift is planned and elevation of tissue over the zygomatic arch is the goal, then dissection must extend to below the superficial layer of the deep temporal fascia above the arch. Abbreviated mid-facelifts performed simultaneously with endoscopic brow lifts may simply be confined to the subperiosteal plane along the lateral orbital rim and are significantly less risky than a full arch release. The beauty of the classic endoscopic brow lift is its versatility and the ease with which simultaneous additional procedures can be combined with this eloquent cosmetic surgery. For instance, the temporal incision of an endoscopic forehead lift can easily be extended inferiorly to blend with the preauricular incision from a standard lower facelift. Also, mid-facelifting (with intraoral dissection) can connect the intraoral subperiosteal dissection over the maxilla and the zygoma to the subperiosteal plane from the endoscopic brow lift through a tunnel near the lateral orbital rim.

After all dissection has been completed, appropriate elevation and fixation are required. Many techniques have been described such as tissue suture only, bone screws and plates, resorbable screws, bone tunnels, local skin excision, temporalis muscle exposure for added scarification, tissue glue, and tight head wraps. Regardless of the any specific fixation technique, successful long-term fixation is most dependent on adequate lower forehead tissue release during endoscopic dissection. Failure to adequately release internal forehead tissues will result in relapse in brow ptosis, even with heavy fixation and the appearance of a “nice” intra op results.

Once complete internal release of the forehead has been attained, specific lifting vectors for the most pleasing esthetic effect are determined. The lateral one-third of the female brow is elevated to the greatest extent, which can be up to 1 cm above the orbital rim (Fig. 18.11). The medial brow should be only slightly above rim level and absolutely below mid and lateral brow levels to avoid a surprised or bewildered expression. Typically, the glabellar region is elevated without the need for midline fixation, which helps to avoid excessive medial elevation. The lateral third of the brow is lifted straight up and can be fixated at the level of the hairline. The galeal tissue is typically secured to bone at this point while the lateral brow is held at the desired height or a few millimeters above the desired level [80–84]. Very little relapse occurs with proper technique and averages only 1–2 mm after 2 weeks [1, 8, 11]. Measurements also can be taken with clear circular templates from pupil to brow to help improve symmetry. Brow position remains very stable following the first few weeks of tissue edema resolution. The time required for complete fixation of the periosteum is not known, but tissue adhesion certainly begins in the first few days after surgery. Various animal studies suggest that a full 12 weeks is required for occurrence of what is called *full histologic periosteal refixation*. An example is the common fixation technique used by many surgeons who place a single transcutaneous bone screw at each parasagittal incision that is removed after only 1 week. The 1-week fixation technique has been used with success for many years. Some suggest that longer bony fixation may provide longer-term retention and less early relapse. The key to long-term fixation appears to be determined most often by proper tissue dissection and release, rather than by a specific fixation technique [1, 8, 11].

Although many fixation techniques are available, this author prefers to fixate the galea and the periosteum near the hairline to a bone tunnel created under the parasagittal inci-



**Fig. 18.11** Sixty-seven-year-old transgender patient shows before and 2 years following a coronal brow lift, blepharoplasties, and bone reduction to decrease frontal bossing. Feminization, changing male features to female, can be very dramatic in the upper facial third since brow

position is so distinctively different between men and women. Obviously, one must be very cautious not to raise the outer third of the brow too high in heterosexual, non-transgender males



sions a few centimeters posterior to the hairline with a single heavy suture such as 0 Vicryl®. Fixation of the lateral tail of the brow is performed at each temporal incision, where an isolated heavy suture plicates the temporoparietal fascia in a posterior and superior vector to the temporalis fascia. Optional creation of a small window of exposed temporalis muscle in this area may facilitate internal scar formation and fixation. The vector of lift at this outer tail of the brow follows a line drawn at an angle from the outer nasal ala that passes just beside the lateral canthus.

Final closure of hair-bearing scalp incisions can be performed with skin staples alone with excellent scar formation, since no skin is excised and no pressure exists at the incision sites. Redundant tissue (forehead skin) created by an average of 1 cm of brow elevation is easily distributed evenly over the posterior 15–20 cm of elevated scalp, which essentially absorbs or redistributes this excess tissue with few to no signs of bunching, provided adequate posterior elevation of the scalp was performed. Because of this occurrence, the endoscopic forehead and brow lift tends to slightly elevate the hairline compared with the open skin-excising coronal technique. No drains typically are required for the endoscopic technique.

It is interesting to note that in a survey performed in 1998 of American Society of Plastic and Reconstructive Surgery members, a total of 6951 brow lifts were performed by 570 members. Of the questionnaire returned that year, 3534 used a coronal incision and 3417 (almost 50%) were performed endoscopically. The most prominent difference was the greater chance for hair loss associated with the coronal incision technique; however, both techniques yielded very low overall complication rates.

## Postoperative Care

Following endoscopic forehead and brow lifting, a compression bandage is applied with a material such as Coban® or Ace type wraps. The pressure helps to limit edema and small hematoma formation while possibly improving fixation. Typically, a drain is not required if a very dry field is maintained, making postoperative care very easy. The patient should be instructed on limited activity, use of cold compresses over the eyes and brow. Head elevation is recommended for the first 48–72 h as tolerated. Preoperative avoidance of anti-platelet drugs, careful surgical technique, and immediate postoperative use of cold compresses, elevation, and limited strenuous activity will significantly decrease postoperative healing time.

The patient may remove postoperative dressing on postoperative day 1 to visually inspect the surgical site for any problems. A less constrictive Velcro-type head wrap then can be used for patient comfort and to allow easy removal for

showering, but a dressing is not absolutely required after the first 24 h. The patient may gently shampoo their hair after 24 h but must be cautioned to avoid water pressure directly over the incision sites. Each incision then is cleaned twice a day with a dilute peroxide solution, and a thin layer of antibiotic ointment is applied for the first week.

Ensuring a short and comfortable recovery is important for the modern cosmetic surgery patient. One hopes an endoscopic technique will yield results with fewer overall problems than are associated with open techniques. Unfortunately, the release of significant scalp and facial deep tissues continues to produce significant pain that requires narcotic relief for most of the first few days.

Staples can be removed at the end of 1 week. Chemical treatment for hair such as a “permanent” should be delayed for at least 2 weeks to avoid the possibility of hair loss caused by the harsh chemicals. Hot curling irons or similar devices must be used with caution because areas of scalp anesthesia that may be present for months can predispose a patient to an accidental self-inflicted burn.

## Complications

Fortunately, major complications are rare with properly performed endoscopic forehead and brow-lifting techniques. Proper patient selection, diligent preoperative planning, meticulous surgical technique, and thorough postoperative care all are required to limit the chances of complications [85–91]. Minor complications can always occur despite a surgeon’s best efforts. However, no matter how minor the problem, the patient must be treated with concern and compassion. The typical cosmetic surgery patient is expecting improvements soon as possible and is not always as tolerant of perioperative complications as a trauma patient. Extensive edema and ecchymosis usually are not considered complications, but they warrant appropriate reassurance and even simple suggestions to hasten recovery when feasible. For example, makeup suggestions from a well-trained staff member may greatly improve a postoperative patient’s frame of mind after he or she is shown how to better camouflage unusual ecchymosis.

The list of true and significant complications includes poor scar appearance, wound dehiscence, hematoma, skin sloughs or perforations, asymmetries, sensory disturbances, facial paralysis, eyelid ptosis, corneal abrasions, dry eye syndrome, hair loss (alopecia), infection, relapse, irregular facial expressions, and contour irregularities. Of all possible problems, permanent facial paralysis or major tissue loss are the most devastating. Fortunately, these particular complications are rare (less than 0.3% and less than that for a standard lower facelift). Regardless, it is critical for the clinician to know the precise anatomy and to avoid improper or exces-

sive retraction, overzealous electrocautery, and excessive thinning of the flaps when transecting depressor muscles. Hematomas must be diagnosed early and treated without delay. Small fluid collections may be aspirated, but larger collections require prompt open surgical intervention.

Some complications such as corneal abrasions can be very concerning to the patient due to the severe pain they produce. These abrasions can be nearly eliminated with proper technique and perioperative attention to detail. For instance, eye lubricant should always be used. Placement of temporary Steri-Strips over the eyelids or a tarsorrhaphy suture should also be considered to prevent inadvertent scratching of the cornea by gauze, tubing, or other materials during the procedure. All severe pain requires immediate evaluation, and suspected abrasion should be treated with suitable ophthalmic drops or bandage contact lens for pain and with patching of the affected eye for 12–24 h. Minor blurred vision for the first 12 h due to chemosis and use of ophthalmic ointments is not unusual. Appropriate ophthalmologic consultation is required for persistent or uncontrollable eye pain, persistent dry eye symptoms, or unusual changes in vision.

Alopecia and sensory disturbances can be very bothersome to the patient and may not be permanent. The problem is our inability to predict whether the numbness a patient has will return partially, not at all, or fully, and just how soon this will happen. With proper technique, endoscopic forehead and brow lift has a high rate of sensory nerve recovery, but full recovery may take several months and may require patient reassurance. Although exact numbers are not known, empiric observation of the last 350 endoscopic brow lifts performed by this author strongly suggests that sensory disturbances may be an occasional early concern but a very unusual complaint after 6–12 months. Careful dissection around the supraorbital nerve is critical if permanent sensory disturbances are to be avoided. Alopecia, on the other hand, is a matter of significant concern, especially if it persists for longer than a few months. Local alopecia may return after an average 4–8 month dormancy period in the hair follicle. A condition known as *telogen effluvium* is the result of stress or a “shock” to the system that can cause up to 70% of hair to fall out. Although it is typically self-limiting, this condition causes great distress, particularly because it may take 6–8 months for the hair to return. Often, the hair follicles in this situation have a club shape and may be found in areas far from the surgical site. On the other hand, excessive tension on the flaps, rough handling of wound margins, or excessive use of cautery near follicles may lead to permanent hair loss that requires treatment.

Proper planning, technique, and postoperative care will help to reduce the incidence of complications. Immediate and appropriate treatment, along with sincere concern for the

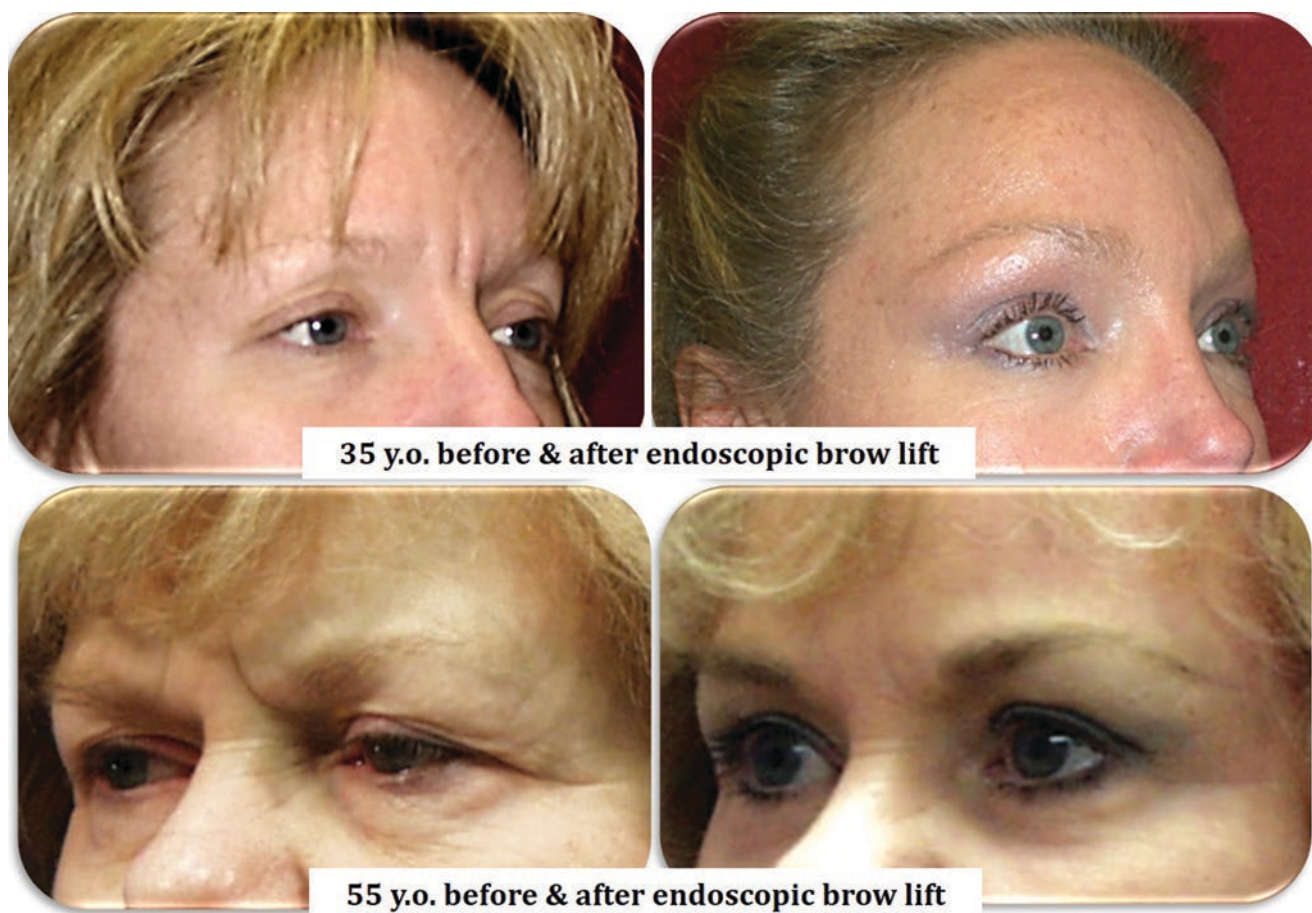patient’s well-being, should minimize escalation of the problems or having unsatisfied patients.

## Summary

Evolution in upper facial rejuvenation techniques over the past decade, led by the use of the endoscope and Botox, has revolutionized the treatment of upper facial aging. Cosmetic surgery for the treatment of the upper facial third is frequently an essential element for complete facial rejuvenation [85, 86]. Procedures are highly variable and can offer improvement in this area of the face to both young and old (Fig. 18.12). Accurate diagnosis with the ideal rejuvenation technique(s) is essential for maximum esthetic benefit. Even the best surgical technique can produce inadequate or even poor results if improper patient selection or diagnoses are made. For this reason, the forehead and brow area must be critically evaluated for a wide range of interlacing diagnoses.

Particular forehead and brow skin problems vary with patient’s age and sex, but gravity remains consistent and nonselective. So, with regard to brow ptosis, the question often is not “Will it occur?” but “When will it occur?” and “How severe will it be?” Wrinkles are also inevitable but may be dynamic or static in nature. With introduction of Botox, the previously difficult treatment of dynamic upper facial lines can be effectively treated with low risk from a simple injection. The other common and consistent finding is brow ptosis, especially in the lateral third of the brow (hooding), may now be selectively treated endoscopically to achieve a more youthful appearance. Society’s definition of beauty at any single moment in time ultimately will guide the patient and surgeon as they choose position and shape of their brow. True or total rejuvenation is complex and involves multiple modalities and often tissue replacement techniques such as fat grafting. Only time and persistence will prove what best restores youth to the upper face. Endoscopic forehead and brow lifting is an elegant surgical adjunct in a wide surgical armamentarium.

Facial cosmetic surgery continues to show an exponential rise in popularity. The aging population wants to feel and look more youthful, nonetheless demands to remain looking natural after low-morbidity procedures. Today’s discernible cosmetic surgery patient is often very knowledgeable on the subject of procedural options and may even insist on a specific technique such as an endoscopic procedure. It is the guidance of a well-trained surgeon and diagnostician that can ultimately produce a happy patient. Also, it is imperative for the surgeon to refuse to provide treatment that is not in the best interest of the patient. Cosmetic surgery is an elective surgery and is considered a luxury. In the end, it is the



**Fig. 18.12** Young and older female patients may significantly benefit from brow lifting as these before and after pictures demonstrate. The key is selecting the appropriate patient who would truly benefit and

desires this surgery regardless of age. As shown, each of these patients is ideal for a brow lift since they both have significant brow ptosis/lateral hooding, as well as glabellar furrows that are nicely improved

surgeon's responsibility to provide the patient with the best and safest techniques available to achieve realistic outcomes, whether they are performed endoscopically or by any other means.

## References

1. Niamtu J. Endoscopic brow and forehead lift: a case for new technology. *J Oral Maxillofac Surg.* 2006;64:1129–32.
2. Ramirez OM. Endoscopic techniques in facial rejuvenation: an overview, part 1. *Aesthet Plast Surg.* 1994;8:141.
3. Isse NG. Endoscopic facial rejuvenation: endoforehead, the functional lift: case reports. *Aesthet Plast Surg.* 1994;18:21–9.
4. Graf RM, Tolazzi ARD, Mansur AEC, Teixeira V. Endoscopic periosteal brow lift: evaluation and follow-up of eyebrow height. *Plast Reconstr Surg.* 2008;121:609.
5. Evans TW. Browlift. *Atlas Oral Maxillofac Surg Clin North Am.* 1998;6:111–33.
6. Knize D. Reassessment of the coronal incision and subgaleal dissection for foreheadplasty. *Plast Reconstr Surg.* 1998;102:478.
7. Cuzalina A. Endoscopic versus other common brow lifting techniques. *Surge-Publication of the American Academy of Cosmetic Surgery*, Winter 2009 ed. p. 28–29.
8. Sullivan PK, Salomon JA, Woo AS, et al. The importance of the retaining ligamentous attachments of the forehead for selective eyebrow reshaping and forehead rejuvenation. *Plast Reconstr Surg.* 2006;117:95.
9. Knize DM. Limited incision foreheadplasty. *Plast Reconstr Surg.* 1999;103:271.
10. Zide BM, Jelks GW. *Surgical anatomy of the orbit.* New York: Raven Press; 1985.
11. Cuzalina LA, Holmes J. A simple and reliable landmark for identification of the supraorbital nerve in surgery of the forehead: an in vivo anatomical study. *J Oral Maxillofac Surg.* 2005;63:25–7.
12. Fagien S. Eyebrow analysis after blepharoplasty in patients with brow ptosis. *Ophthal Plast Reconstr Surg.* 1992;8:210.
13. Powell H, Humphreys B. *Proportions of the aesthetic face.* New York: Thieme-Stratton; 1984.
14. Ricketts RM. Divine proportion of facial aesthetics. *Clin Plast Surg.* 1982;9:401.
15. Ellis DAF, Bakala CD. Anatomy of the motor innervation of the corrugator supercilii muscle: clinical significance and development of a new surgical technique for frowning. *J Otolaryngol.* 1998;27:222–7.
16. Larrabee WF, Mahielski KH. *Surgical anatomy of the face.* New York: Raven Press; 1993.
17. Waite PD, Cuzalina LA. Rhytidectomy. In: Fonseca RJ, editor. *Oral and maxillofacial surgery: cleft/craniofacial/cosmetic surgery*, vol. 6. Philadelphia: Saunders; 1998. p. 365–81.



18. Tobin HA, Cuzalina LA. An opportunistic approach for face lifting. *J Oral Maxillofac Surg.* 2000;58:76–85.
19. Tobin HA, Cuzalina LA. SMAS surgery versus deep-plane rhytidectomy. In: Pensak ML, editor. *Controversies in otolaryngology.* New York: Thieme; 2001. p. 148–55.
20. Bostwick J, Eaves F, Nahai F. *Endoscopic plastic surgery.* St. Louis: Quality Medical Publishers; 1995.
21. Hiatt JL, Gartner LP. In: Gardner J, editor. *Textbook of head and neck anatomy.* 2nd ed. Baltimore: Williams & Wilkins; 1987. p. 373–345.
22. Hamas RS. Reducing the subconscious frown by endoscopic resection of the corrugator muscles. *Aesthet Plast Surg.* 1995;19:21–5.
23. Ellis DAF, Masri H. The effect of facial animation on the aging upper half of the face. *Arch Otolaryngol Head Neck Surg.* 1989;115:710–2.
24. Brennan HG. The forehead lift. *Otolaryngol Clin N Am.* 1980;13:209.
25. Grant JCB, editor. *Grant's atlas of anatomy.* 6th ed. Baltimore: Williams & Wilkins; 1972.
26. Tolhurst DE, Carstens MH, Greco RJ, et al. The surgical anatomy of the scalp. *Plast Reconstr Surg.* 1991;87:603.
27. Tremolada C, Candiani P, Signorini M, et al. The surgical anatomy of the subcutaneous fascial system of the scalp. *Ann Plast Surg.* 1994;32:8.
28. Carstens MH, Greco RJ, Hurwitz DJ, et al. Clinical applications of the subgaleal fascia. *Plast Reconstr Surg.* 1991;87:615.
29. Knize DM. Transpalpebral approach to the corrugator supercilii and procerus muscles. *Plast Reconstr Surg.* 1995;95:52–60.
30. Knize DM. A study of the supraorbital nerve. *Plast Reconstr Surg.* 1997;99:1224.
31. Knize DM. Muscles that act on glabellar skin: a closer look. *Plast Reconstr Surg.* 2000;105:350.
32. Netter FM. *Atlas of human anatomy.* Summit: Ciba-Geigy; 1989.
33. Knize DM. An anatomically based study of the mechanism of eyebrow ptosis. *Plast Reconstr Surg.* 1996;97:1321.
34. Lemke BN, Stasior OG. The anatomy of eyebrow ptosis. *Arch Ophthalmol.* 1982;100:981.
35. Aiache AE, Ramirez OM. The suborbicularis oculi fat pads: an anatomic and clinical study. *Plast Reconstr Surg.* 1995;95:37.
36. Trinei FA, Januszkiewicz J, Nahai F. The sentinel vein: an important reference point for surgery in the temporal region. *Plast Reconstr Surg.* 1998;101:27.
37. Gosain AK, Sewall SR, Yousif NJ. The temporal branch of the temporal nerve: how reliably can we predict its path? *Plast Reconstr Surg.* 1997;99:1224.
38. Ellis E, Zide MF. *Surgical approaches to the facial skeleton.* Baltimore: Williams & Wilkins; 1995. p. 59–169.
39. Liebman E, Webster R, Berger A, et al. The frontalis nerve in the temporal brow lift. *Arch Otolaryngol Head Neck Surg.* 1982;108:232–5.
40. Furnas DW. Landmarks for the trunk and the temporofacial division of the facial nerve. *Br J Surg.* 1965;52:694.
41. Cuzalina LA. Forehead and brow procedures. In: Peterson's principles of oral and maxillofacial surgery. 3rd ed., Vol. 2, Section 8; 2012. p. 1571–96.
42. Isse NG. Endoscopic forehead lift. *Clin Plast Surg.* 1995;22:661.
43. Isse NG. The endoscopic approach to forehead and brow lifting. *Aesthet Plast Surg.* 1998;18:67.
44. Vasconez LO, Core GB, Gamboa-Bobadilla M, et al. Endoscopic techniques in coronal brow lifting. *Plast Reconstr Surg.* 1994;94:788.
45. Morselli PG. Fixation for forehead endoscopic lifting: a simple, easy, no-cost procedure. *Plast Reconstr Surg.* 1996;97:1309.
46. Marchac D, Ascherman J, Arnaud E. Fibrin glue fixation in forehead endoscopy: evaluation of our experience with 206 cases. *Plast Reconstr Surg.* 1997;100:704.
47. Hoeing JF. Rigid anchoring of the forehead to the frontal bone in endoscopic facelifting: a new technique. *Aesthet Plast Surg.* 1996;20:213.
48. De la Fuente A, Santamaria AB. Facial rejuvenation: a combined conventional and endoscopic assisted lift. *Aesthet Plast Surg.* 1996;20:471.
49. Isse NG. Endoscopic forehead lift, evolution and update. *Clin Plast Surg.* 1995;2:661.
50. Adamson PA, Johnson CM, Anderson JR, et al. The forehead lift: a review. *Arch Otolaryngol Head Neck Surg.* 1985;111:325–9.
51. Liang M, Narayanan K. Endoscopic obliteration of the frontalis and corrugator muscles: a clinical study. *Plast Surg Forum.* 1992;XV:54.
52. Su CT, Morgan RF, Manson PN, Hoopes JE. Technique for division and suspension of the orbicularis oculi muscle. *Clin Plast Surg.* 1981;8:673.
53. Byrd HS, Andochick SE. The deep temporal lift: a multiplanar lateral brow, temporal, and upper face-lift. *Plast Reconstr Surg.* 1996;97:928.
54. Kerth JD, Triumi DM. Management of the aging forehead. *Arch Otolaryngol Head Neck Surg.* 1990;116:1137–42.
55. Chierici G, Miller A. Experimental study of muscle reattachment following surgical detachment. *J Oral Maxillofac Surg.* 1984;42:485.
56. Ramirez OM. Endoscopic subperiosteal browlift and facelift. *Clin Plast Surg.* 1995;22:639–60.
57. Tobin HA. The extended subperiosteal coronal lift. *Am J Cosmet Surg.* 1993;10:47–57.
58. Psillakis JM, Rummley TO, Camargos A. Subperiosteal approach in an improved concept for correction of the aging face. *Plast Reconstr Surg.* 1988;82:383–92.
59. Ramirez OM. Endoscopic techniques in facial rejuvenation: an overview. *Aesthet Plast Surg.* 1994;18:141–7.
60. Daniel RK, Ramirez OM. Endoscopic assisted aesthetic surgery. *Aesthet Plast Surg.* 1994;14:18–20.
61. Toledo LS. Facial rejuvenation: technique and rationale. In: Fodor P, Isse N, editors. *Endoscopically assisted aesthetic plastic surgery.* St Louis: Mosby; 1996. p. 91–105.
62. Psillakis JM. Subperiosteal approach for surgical rejuvenation of the upper face. In: Psillakis J, editor. *Deep face-lifting techniques.* New York: Thieme; 1994. p. 51–63.
63. Hinderer UT. The sub SMAS and subperiosteal rhytidectomy of the forehead and middle third of the face: a new approach to the aging face. *Facial Plast Surg Clin North Am.* 1992;8:18–32.
64. Ruess WR, Owsley JQ. The anatomy of the skin and fascial layers of the face in aesthetic surgery. *Clin Plast Surg.* 1987;14:677–82.
65. Abul-Hassan HS, Van Drasek AG, Acland RD. Surgical anatomy and blood supply for the fascial layers of the temporal regions. *Plast Reconstr Surg.* 1986;77:17.
66. Stuzin JM, Wagstrom L, Kawamoto HK, et al. Anatomy of the frontal branch of the facial nerve: the significance of the temporal fat pad. *Plast Reconstr Surg.* 1989;83:265.
67. Savani A. Physiopathology of the aging face. In: Psillakis JM, editor. *Deep face-lifting techniques.* New York: Thieme; 1994. p. 11–23.
68. De la Plaza R, Valiente E, Arroya JM. Supraperiosteal lifting of the upper two thirds of the face. *Br J Plast Surg.* 1991;4:325–32.
69. Wassef M. Superficial fascial and muscular layers in the face and neck: a histologic study. *Aesthet Plast Surg.* 1987;11:171.
70. Tirkanis B, Daniel RK. The biplanar forehead lift. *Aesthet Plast Surg.* 1990;14:111.
71. Ramirez OM, Maillard GF, Musolas A. The extended subperiosteal face lift: a definitive soft-tissue remodeling for facial rejuvenation. *Plast Reconstr Surg.* 1991;88:227–36.
72. Psillakis JM. Embryology and anatomy review of the superficial fascia or SMAS. In: Psillakis JM, editor. *Deep face-lifting techniques.* New York: Saunders; 1994. p. 1–11.



73. Bosse JP, Papillon J. Surgical anatomy of the SMAS at the malar region. In: Transactions of the ninth international congress of plastic and reconstructive surgery. New York: McGraw-Hill; 1987.
74. Owsley JQ. Aesthetic facial surgery. Philadelphia: Saunders; 1994. p. 7–24, 30–31, 117–127.
75. Yousif NJ, Mendelson BC. Anatomy of the mid-face. *Clin Plast Surg*. 1995;22:227–41.
76. Guyuron B, Davies B. Subcutaneous anterior hairline forehead rhytidectomy. *Aesthet Plast Surg*. 1988;12:77.
77. Aiache AE. Endoscopic face-lift. *Aesthet Plast Surg*. 1994;18:275.
78. Ramirez OM. Endoscopic forehead and face-lift: step-by-step. *Open Tech Plast Reconstr Surg*. 1995;2:116–26.
79. Matarasso A, Terino EO. Forehead-brow rhytidoplasty: reassessing the goals. *Plast Reconstr Surg*. 1994;93:1378.
80. Newman JP, LaFerriere KA, Koch RJ, et al. Transcalvarial suture fixation for endoscopic brow and forehead lifts. *Arch Otolaryngol Head Neck Surg*. 1997;123:313.
81. Kim SK. Endoscopic forehead scalp flap fixation with K-wire. *Aesthet Plast Surg*. 1996;20:217.
82. Pakkanen M, Salisbury AV, Ersek RA. Biodegradable positive fixation for endoscopic browlift. *Plast Reconstr Surg*. 1996;98:1087.
83. Knize DM. A study of the supraorbital nerve. *Plast Reconstr Surg*. 1995;96:564.
84. Loomis MG. Endoscopic brow fixation without bolsters or miniscrews. *Plast Reconstr Surg*. 1996;98:373.
85. Keen MS, Khosh MM. The role of botulinum toxin a in facial plastic surgery. In: Willet JM, editor. *Facial plastic surgery*. Upper Saddle: Prentice Hall; 1997. p. 323–9.
86. Frankel AS, Kamer FM. Chemical browlift. *Arch Otolaryngol Head Neck Surg*. 1998;124:321.
87. Beeson WH, McCollough EG. Complications of the forehead lift. *Ear Nose Throat J*. 1985;64:27.
88. Connell BF, Lambros VS, Neurohr GH. The forehead lift: techniques to avoid complications and produce optimal results. *Aesthet Plast Surg*. 1989;13:217.
89. Matarasso A. Endoscopic assisted forehead-brow rhytidoplasty: theory and practice. *Aesthet Plast Surg*. 1995;19:141.
90. Daniel RK, Tirkantis B. Endoscopic forehead lift, aesthetics and analysis. *Clin Plast Surg*. 1995;22:605–18.
91. Mayer TG, Fleming RW. Management of alopecia. In: Cummings CW, Fredrickson JM, Harker LA, et al., editors. *Otolaryngology—head neck surgery*. St Louis: Mosby; 1986. p. 429.

Brian Wong Won, Neel S. Joshi, Walter Jongbloed,  
and Charles L. Castiglione

## Introduction

With age, our skin loses the elasticity and fullness that characterizes a youthful facial appearance. Typically, drooping occurs in anatomically thin areas like the periorbital region, and volume loss manifests as wrinkles. Rhytidectomy, known more commonly as a facelift, refers to the surgical removal of wrinkles. By lifting the upper face and narrowing the lower face, the facelift seeks to restore a heart-shaped, youthful aesthetic [1].

## Anatomy

### Anatomic Layers

There are five crucial anatomical layers to consider when performing the facelift – skin, subcutaneous fat, the superficial musculoaponeurotic system (SMAS) layer, fascia, and the facial nerve (Fig. 19.1). The skin contains the dermal plexus which supplies blood to the flap in the facelift. The subsequent layer is made up of subcutaneous tissue. The third layer is the SMAS layer, which is a fibro-connective tissue of variable constitution throughout the face. First characterized by Mitz and Peyronie in 1976, the SMAS is at its thickest in the buccal area overlying the parotid gland and transitions to an aponeurotic layer as it progresses toward the nasolabial folds. The adiposity of the buccal region is higher

in order to support systematic sliding of the SMAS around somatic muscular contraction [2]. Conversely, the tissue over the nose and face is much more fixed and is more fibrous in quality. The SMAS layer becomes contiguous with the superficial temporal fascia at the temples and with the platysma in the neck. The fourth layer is made up of a loose areolar tissue, and it has various names throughout the face. It is named the subgaleal fascia in the temporal region, the parotid-masseteric fascia in the cheek, and the superior cervical fascia in the neck. The facial nerve and its branches make up the fifth layer.

### Facial Nerve and Muscle Innervation

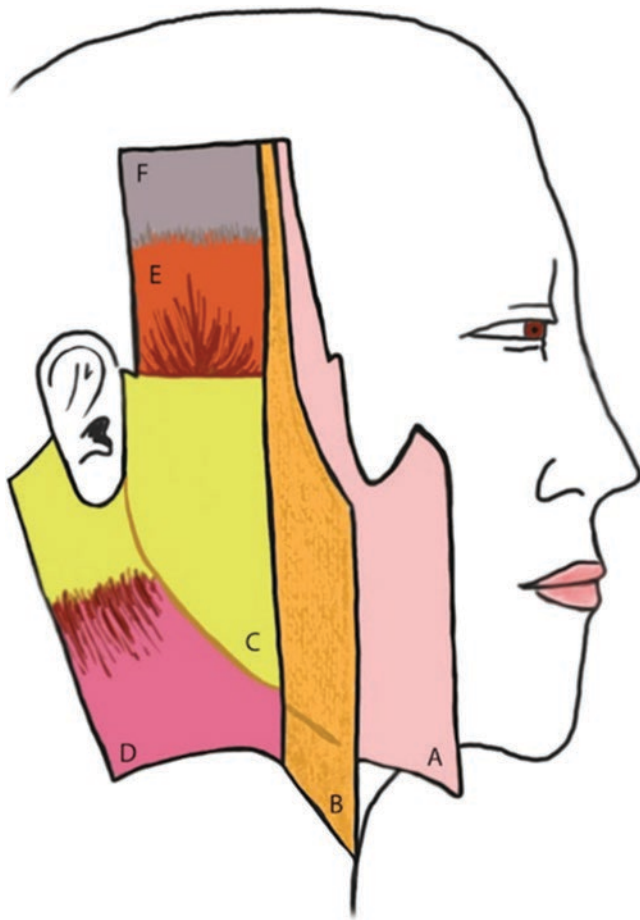
The facial nerve is the seventh cranial nerve, which originates at the brainstem at the pontomedullary junction and ultimately exits the base of the skull at the stylomastoid foramen. The facial nerve then courses anteriorly, almost immediately giving off branches to the stylohyoid, the posterior digastric belly, posterior auricular, and occipitalis muscles of the nuchal region [3]. As it enters the parotid, the nerve can branch into temporofacial and cervicofacial branches [4]. The trunks then subdivide into the parotid plexus, otherwise known as pes anserinus. Classically, five nerves exit the anteromedial parotid surface to supply the facial muscles (Fig. 19.2).

The temporal branch divides into anterior and posterior rami after arising from the parotidomasseteric fascia. There is sometimes a middle ramus that can arise to supply the frontalis muscle. The anterior and posterior rami traverse the zygomatic arch before entering the subgaleal space to give off branches to the lateral part of the auricle, and the anterior and superior auricular muscles. The anterior branches also supply the occipitofrontalis, the corrugator muscles, orbicularis oculi, and branches of the ophthalmic nerve. The temporo-frontal branches are commonly injured, so it is imperative to maintain a dissection plane that is superficial to

B. W. Won · N. S. Joshi  
UCONN Integrated Surgical Residency Program,  
Farmington, CT, USA  
e-mail: [wongwon@uchc.edu](mailto:wongwon@uchc.edu); [nejoshi@uchc.edu](mailto:nejoshi@uchc.edu)

W. Jongbloed  
UCONN School of Medicine, Farmington, CT, USA  
e-mail: [jongbloed@uchc.edu](mailto:jongbloed@uchc.edu)

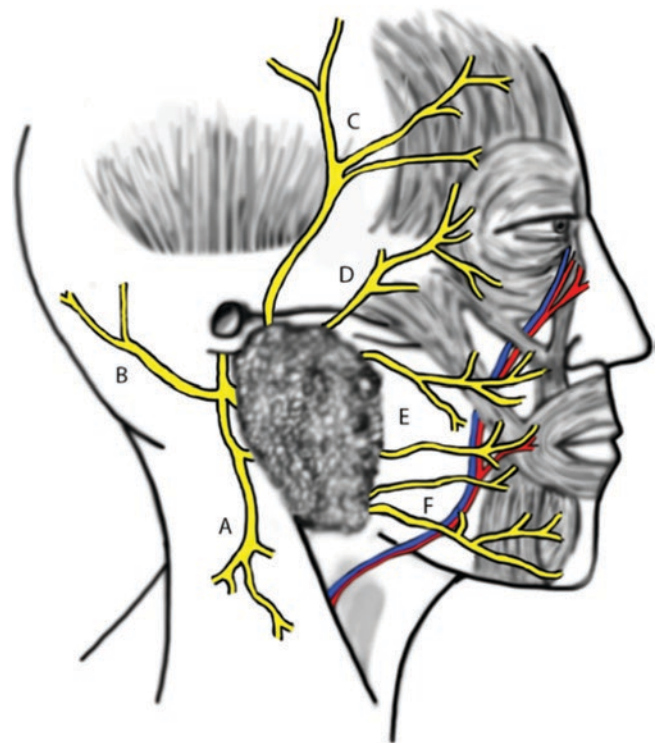
C. L. Castiglione (✉)  
UCONN School of Medicine, Hartford Hospital, Connecticut  
Children's Medical Center, Farmington, CT, USA



**Fig. 19.1** Anatomic layers of the face. (a) Skin, (b) subcutaneous tissue, (c) SMAS, (d) platysma, (e) superficial temporal fascia, (f) galea fascia

the temporoparietal fascia to avoid inadvertent harm [5]. The sentinel vein can often be used as a landmark that conveys proximity to the nerve.

The zygomatic branches are variable but generally traverse the zygomatic bone to the lateral canthus of the eye. They supply the orbicularis oculi, provide innervation to several muscles supplied by the buccal branch, and communicate with the lacrimal nerve and branches of the maxillary nerve. The upper zygomatic branches are deep to the upper one-third of the zygomatic major muscles in the sub-SMAS plane. The inferior zygomatic branches are inferior to the upper part of the masseteric ligament but can become superficial near the inferior margin, so care must be taken to avoid inadvertent transection [3]. The buccal branch is intimately associated with the parotid duct, lying below the duct for roughly 2.5 cm after emerging from the parotid gland. Superficial branches lie below the SMAS system, and deep branches pass to the procerus and communicate to the infratrochlear and nasal nerve. Upper branches supply the zygomaticus major, levator labii, and infraorbital plexus.



**Fig. 19.2** Branches of the facial nerve (VII). (a) Cervical branch, (b) posterior auricular branch, (c) temporal branches, (d) zygomatic branches, (e) buccal branches, (f) mandibular branches

Lower branches supply the orbicularis oris and buccinator. The buccal branches are variable and can have a substantial number of branches. There can also be a vast number of interconnections with zygomatic branches. It is no surprise that these branches are the mostly commonly injured facial nerve branches. In many cases, neurological recovery after injury is mediated by overlapping functions of these many collateral branches. In order to avoid injury, the surgeon must be careful to establish a depth of dissection above the upper zygomatic ligament, and caudad to the upper masseteric ligament [5]. Around the masseteric ligament in particular, branches can reside as shallow as 1 mm deep to the SMAS. The zygomatic eminence provides a relatively safe area of dissection.

There are two marginal mandibular branches. One branch takes a course roughly 2 cm below the mandibular line and turns upward, passing under the depressor anguli oris to supply the risorius, the lower lip, the chin, and communicate to the mental nerve. The cervical branch emerges from the parotid and dives below the platysma and the cervical skin. At the mandibular border, the marginal mandibular nerve can course superficial to the facial artery – as it crosses the facial vessels, it presents a risk for inadvertent injury [5]. The surgeon must take care to stay superficial to the platysma-SMAS in this region because the tissue is particularly thin and can be adherent to the overlying tissue.

## Muscles and Ligaments

The frontalis is responsible for the raising of the eyebrows, while the corrugator muscles enable downward movement of the eyebrow. The orbicularis oculi muscle is essential to closure of the eye. The orbicularis oris and buccinator are involved in mouth closure and cheek muscle function. The mandibular branches supply the muscles of the mentalis, the paired central muscles of the chin that permit wrinkling and pouting. These muscles are innervated by branches of the facial nerve that approach from the deep surface. Therefore, dissection in a plane superficial to the SMAS layer can be performed relatively safely.

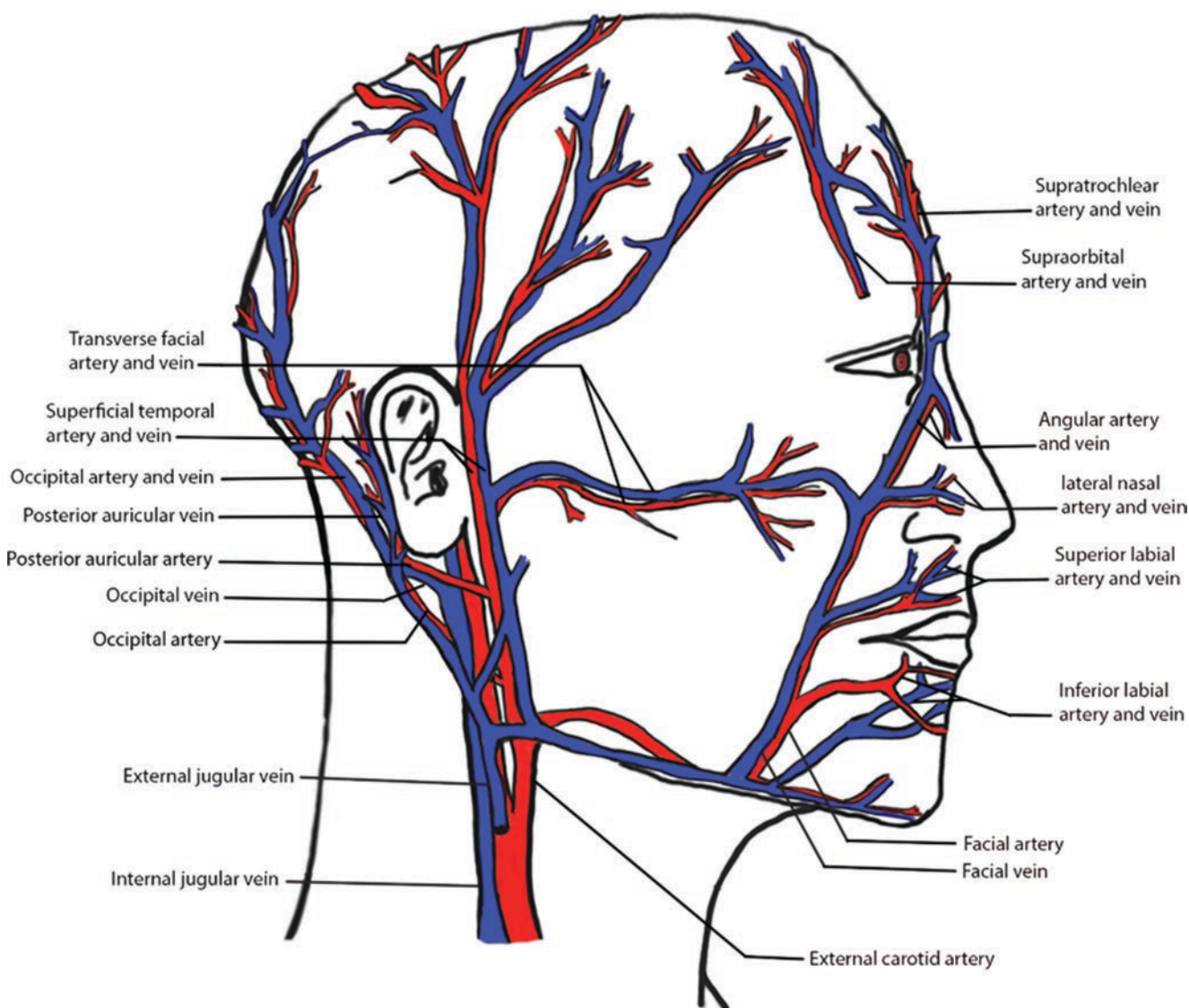
The muscles of mastication are supplied by the mandibular branch of the trigeminal nerve, or cranial nerve V. This is comprised of four muscles: the masseter, the temporalis muscle, and the medial and lateral pterygoids. CN V3 also

innervates the tensor veli palatini, which assists in soft palate movement when swallowing, the mylohyoid muscle that forms the mandibular floor, the anterior belly of the digastric muscle that supports movement of the jaw and elevation of the hyoid bone, and the tensor tympani, which mediates the dampening of sounds.

## Vascular Supply

Four main arteries supply the face – the facial artery, the maxillary artery, the superficial temporal, and the ophthalmic artery.

The facial artery arises from the external carotid artery, passing from the anterior inferior masseteric border on a diagonal course to the medial border of the eye (Fig. 19.3). It transitions from the pre-masseteric artery, gives off the infe-



**Fig. 19.3** Arteries and veins of the face, head, and neck



rior and superior labial arteries, the lateral nasal artery, and ultimately becomes the angular artery.

The maxillary artery is a large terminal branch of the external carotid artery that gives off three main branches. The inferior alveolar artery terminates as the mental artery, supplying the chin and inferior labial region. The buccal branch stems from the second part of the maxillary artery to supply the cheek. The third part of the maxillary artery gives rise to the infraorbital artery that ultimately supplies the upper lip, the lateral nasal area, and the lower eyelid.

The superficial temporal artery is the second terminal branch of the external carotid. It begins from the posterior border of the parotid gland and runs up the scalp before dividing into the frontal and parietal branches. The transverse facial artery, the auricular artery, and zygomatico-orbital artery are all small named branches of the superficial temporal artery.

The ophthalmic artery branches from the internal carotid artery, and it becomes several smaller arteries in the face. The supratrochlear artery supplies the upper eyelid and forehead. The supraorbital artery arises from the supraorbital notch; it gives off superficial and deep branches to the forehead, scalp, and the mucoperiosteum of the frontal bone. The lacrimal artery arises from the lateral part of the orbit and gives off the zygomatic artery that divides into zygomaticofacial and zygomaticotemporal branches. Together, they supply the distribution that encompasses the lateral orbital area and the cheek. The medial palpebral arteries supply the medial area of the eyelids. The dorsal nasal artery supplies the external nose skin and lateral nasal cartilage.

## Venous Drainage

The venous drainage of the face is subject to significant variation, but general relationships are well characterized. The supratrochlear vein drains the forehead and superficial temporal vein branches. It descends the nasal bridge to join branches of the supraorbital vein near the medial canthus of the eye. The supraorbital vein drains the frontal sinus, the superior ophthalmic vein, and traverses the orbicularis oculi. After uniting with the supratrochlear vein, it becomes the facial vein, which travels alongside the nose and passes beneath the cheek muscles before it superficializes at the masseter. It then crosses the mandible to become the internal jugular vein in the neck.

The superficial temporal vein is connected to a rich venous network in the scalp that includes the supratrochlear veins and supraorbital veins. The anterior and posterior branches of the scalp meet at the zygomatic arch to become the superficial temporal vein. The maxillary vein joins the superficial temporal vein, becoming the retromandibular vein behind the parotid gland. The retromandibular vein drains into the external jugular vein.

The retromandibular vein is superficial to the external carotid artery and provides an important anatomic landmark for the facial nerve [6]. In general, the facial nerve can be found lateral to the retromandibular vein and passes superficially. In one described anatomic variant, the facial nerve branch passes through a vascular ring formed by the retromandibular vein. This relationship between the retromandibular vein and the facial nerve must be well defined to avoid inadvertent injury.

## Retaining Ligaments

There are two retaining ligaments in the face where soft tissues are relatively fixed. The zygomatic ligament runs along the cheekbone, above and anterior to the parotid. The mandibular ligament is a fixture at the jawline. These are anatomically significant because they may be released when facial tissue is re-draped (Fig. 19.4).

## Other Important Anatomic Considerations

The greater auricular nerve is a sensory nerve that traverses the sternocleidomastoid roughly 7 cm below the external auditory meatus and lies deep to the external jugular vein. Branches of this nerve become superficial to supply the earlobe. Transection commonly results in hyperesthesia, permanent loss of sensation, and potentially neuroma. This can occur in up to 7% of facelifts [7].

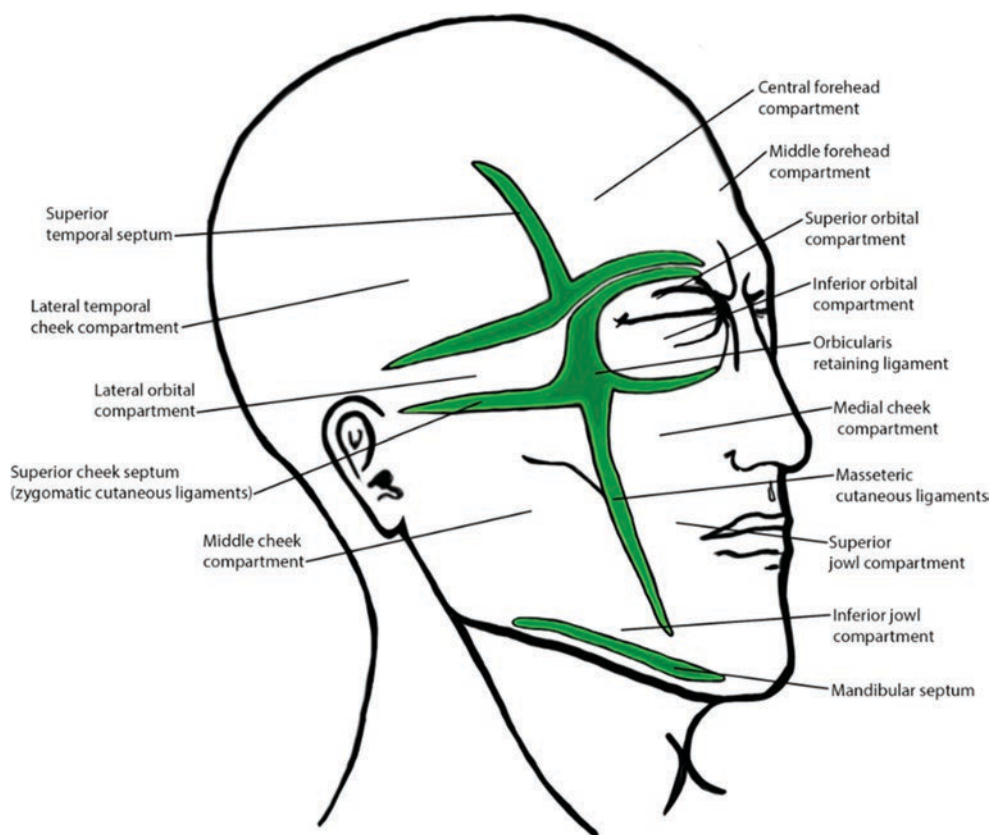
The tear trough is the groove between the medial canthus of the eye and the nose-bridge. In many people, this becomes more pronounced with age. This is of importance because most facelift techniques do not address the teardrop deformity. Rather, it can be addressed with filler techniques or fat micrografting.

The malar fat pad is the fibrofatty tissue that overlies the infraorbital zygomatic muscles. It is superficial to the SMAS layer. With age, drooping of the fat pad leaves a sunken appearance. In the SMAS technique, it is mobilized in continuity with the SMAS layer and lifted to create a fullness in the infraorbital region.

The buccal fat pad is superficial to the buccinator and masseter muscles in the cheek. The buccal branches of the facial nerve run above the plane of the fat pad. The fat pad can be accessed by a sub-SMAS dissector or from a transoral approach through the buccinator muscle. Removal of fat from the buccal fat pad is sometimes performed in patients with fuller faces, but can also create an aged appearance.

The parotid gland is bound by the masseter anteriorly, the zygomatic arc superiorly the external auditory canal posteriorly, and the mandibular ramus inferiorly. The gland lies underneath the SMAS layer and is enveloped by the

**Fig. 19.4** Retaining ligaments of the face and superficial fat compartments



parotidomasseteric fascia. It is most likely to be injured at the inferior portion, near the mandible. While there are roughly 20 cases described in the literature. Injury can result in persistent fistulae, sialoceles, and compromised wound healing [8].

The platysma is the superficial muscular layer of the neck. The two muscles come together at the midline, where it can become more redundant with age. This can be plicated and trimmed in a platysmaplasty.

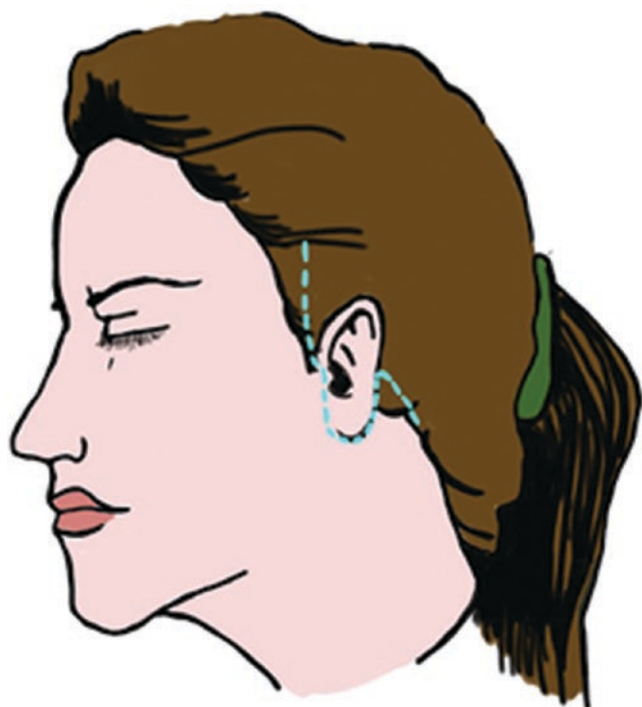The spinal accessory nerve, or cranial nerve XI, exits the jugular foramen with the internal jugular vein and vagus nerve. It courses through the anterior triangle to supply the SCM. There have been case reports describing injuries or neuropraxias that manifest as varying degrees of shoulder pain and dysfunction [9, 10].

## Facelift Techniques

The first rhytidectomy was credited to German surgeon, Eugene Von Hollander in 1901. In a later text entitled "Cosmetic Surgery," Von Hollander describes excising elliptical portions of skin at natural folds along the hairline and periauricular area. Julien Bourguet advanced the procedure with subcutaneous undermining and removal of fat through an incision hidden on the inside of the lower eyelid [11].

Swedish Surgeon, Tord Skoog would later innovate the SMAS facelift that has evolved into the most commonly performed iteration of the rhytidectomy today.

The subcutaneous facelift technique is characterized by undermining in the subcutaneous tissue plane. The goal is to create an inconspicuous incision disguised in the hairline, which can be challenging in patients with prior facelifts due to varying degrees of distortion of the hairline and ear. The incision begins at the hairline, and proceeds along the crus of helix, and continues in either an antetragal or retrotragal fashion [12]. The incision passes then beneath the earlobe, and ascends the retro-auricular sulcus through the hairline into the occipital scalp in an S-shaped or inverted-V-shaped pattern (Fig. 19.5). The extent of undermining and depth can be catered to the unique age-associated changes in the patient. It is best to perform the undermining under direct visualization to avoid permanent nerve injury. Also, providing an excessive amount of countertraction can result in a thinner-than-desired flap. The skin is then re-draped in a posterosuperior direction and is trimmed and inset accordingly. Special care is undertaken at the hairline to avoid distortion adjacent to the ear. For males with inherently longer sideburns, the incision may transect the sideburn to allow aesthetic re-draping of the cheek in a vertical direction. In this scenario, the inferior flap of the sideburn is fixed no higher than the junction of the cheek and ear. The neck is re-

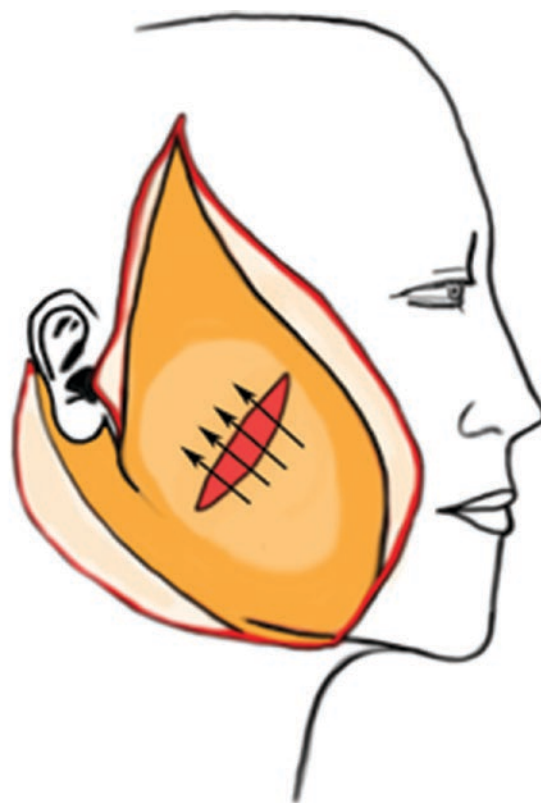


**Fig. 19.5** Facelift incision. The incision is made within the temporal region in the hair but may be placed anterior to the hairline in those with thin hair. The incision continues inferior to the posterior aspect of the tragus, around the lobule and into the retroauricular sulcus to a height high enough to remain invisible in individuals with short hair. The incision terminates in the occipital scalp after extending a short distance along the hairline

draped with traction mostly in the horizontal direction. The skin is incised and trimmed to avoid step-off at the occipital hairline.

The traditional SMAS dissection highlights the mandibular angle. Two incisions are created in the SMAS – one just caudal to the zygomatic arch and one just anterior to the ear that extends past the angle of the mandible to the anterior SCM. The SMAS is mobilized off the parotid fascia until the anterior border of the parotid. The flap is mobilized and trimmed and rotated up and posterior before being transfixed to the original incision. The platysmal portion is lifted and sutured to the mastoid periosteum.

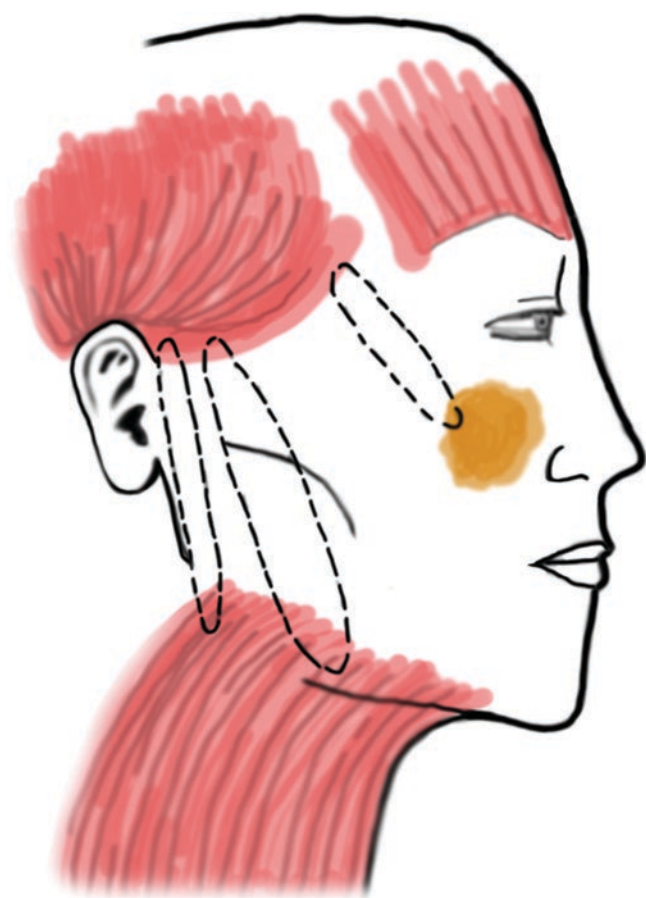The extended SMAS dissection is similar to the aforementioned technique except for a transverse incision that is made above the zygomatic arch. This offers an added benefit of enhancing the malar region.



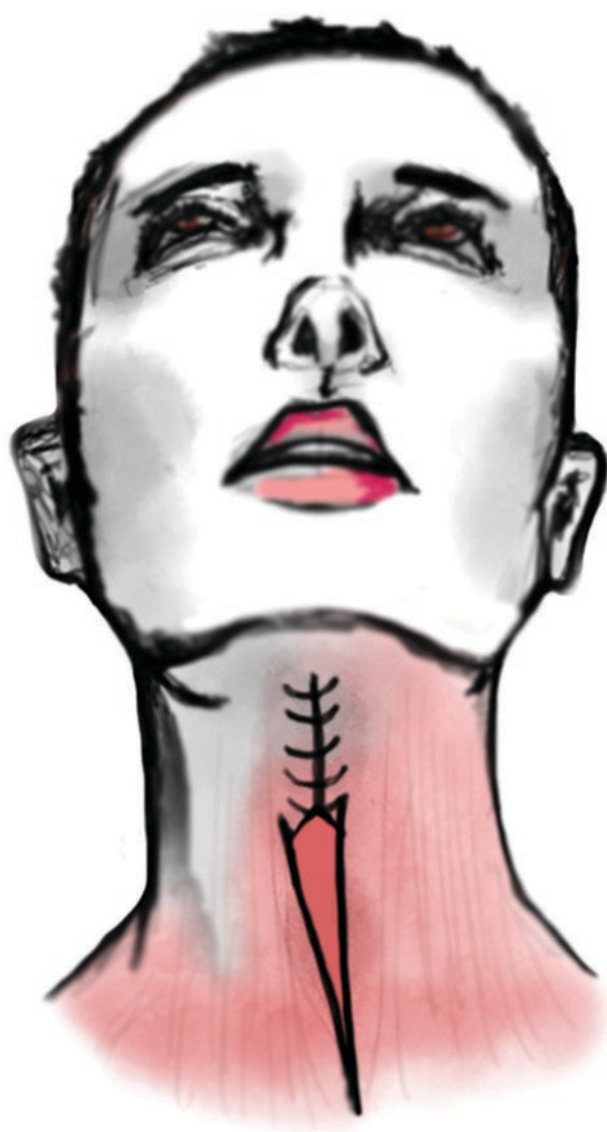
**Fig. 19.6** Lateral SMASectomy. Strip of SMAS removed obliquely along the axis between the lateral canthus of the eye and mandibular angle

The SMASectomy is another variant (Fig. 19.6). A strip of SMAS is removed obliquely along an axis between the lateral canthus of the eye and the mandibular angle. When dissecting, it is crucial to stay superficial to the deep fascia to avoid resection of the parotid parenchyma [13]. In thin patients, plication of the SMAS along this axis may be preferable as it preserves fatty tissue. A surgeon must be cautious to avoid place sutures too deeply that can be injurious to buccal branches of the facial nerve.

The composite rhytidectomy is the most invasive iteration as it dissects the skin and SMAS as a singular flap. While this technique preserves vasculature, it sometimes requires prolonged operative time and recovery time. Conversely, several minimally invasive techniques have been developed – one popular method is the minimal access cranial suspension (MACS) lift, which is performed through a limited



**Fig. 19.7** Extended minimal access cranial suspension (MACS) lift. Platysma and mandibular angle are sutured to the deep temporal fascia under tension while the malar fat pad is raised in a cephaloposterior direction



**Fig. 19.8** Platysmaplasty

preauricular incision (Fig. 19.7). In the simple MACS lift, the platysma and the mandibular angle are sutured to the deep temporal fascia under tension to elevate the jowls. In the extended MACS lift, the malar fat pad is also raised in the cephaloposterior direction to improve sagging in the middle third of the face [14].

A platysmaplasty, commonly performed via a submental incision, may accompany many facelift procedures. An incision is made just below the submental fold and the subcutaneous tissue is undermined to expose the platysma. Redundant tissue can then be excised or plicated at the medial borders of the platysma (Fig. 19.8). Unsightly platysmal bands can be resected. In addition, the platysma can be lifted and tightened in the posterior superior direction and then fixated to the preauricular, peri-mastoid tissue, and

posterior cervical region – this can be accomplished through a lateral neck incision such as the one required to perform the SMASectomy [15].

## Summary

Traditionally, the facelift techniques that involve changes to the deep fascia were presumed to have been more efficacious and more durable than minimally invasive methods, but this



myth has been disproven in multiple studies [16]. A large 2011 systematic review sought to compare facelift methods in terms of efficacy, patient satisfaction, and complication rate. Ultimately, this study was inconclusive due to a lack of objective criteria between studies to demonstrate superiority [17]. To date, there is no gold standard in terms of surgical approach for rhytidectomy. Regardless of the technique employed, a comprehensive understanding of the anatomy of the face is necessary to avoid complications and maximize aesthetic results.

## References

1. Thaller SR. Grabb and Smith's plastic surgery, seventh edition. *Plast Reconstr Surg*. 2014;133(5):1311–2. <https://doi.org/10.1097/PRS.0000000000000337>.
2. Macchi V, Tiengo C, Porzionato A, et al. Histotopographic study of the fibroadipose connective cheek system. *Cells Tissues Organs*. 2010;191(1):47–56.
3. Charafeddine AH, Drake R, McBride J, Zins JE. Facelift: history and anatomy. *Clin Plast Surg*. 2019;46(4):505–13. <https://doi.org/10.1016/j.cps.2019.05.001>.
4. Gray's anatomy. 41st ed. Accessed 24 Mar 2020. <https://www.elsevier.com/books/gray-anatomy/standing/978-0-7020-5230-9>.
5. Roostaeian J, Rohrich R, Stuzin J. Anatomical considerations to prevent facial nerve injury. *Plast Reconstr Surg*. 2015;135(5):1318–27. <https://doi.org/10.1097/PRS.0000000000001244>.
6. Mahore D, Mangalgi AS, Namdev LN, Kapre M. Variations of retromandibular vein and its relation to facial nerve within parotid gland. *Indian J Otolaryngol Head Neck Surg*. 2018;70(3):395–7. <https://doi.org/10.1007/s12070-018-1389-1>.
7. Lefkowitz T, Hazani R, Chowdhry S, Elston J, Yaremchuk MJ, Wilhelmi BJ. Anatomical landmarks to avoid injury to the great auricular nerve during rhytidectomy. *Aesthet Surg J*. 2013;33(1):19–23. <https://doi.org/10.1177/1090820X12469625>.
8. Lawson GA, Kreymerman P, Kreyerman P, Nahai F. An unusual complication following rhytidectomy: iatrogenic parotid injury resulting in parotid fistula/sialocele. *Aesthet Surg J*. 2012;32(7):814–21. <https://doi.org/10.1177/1090820X12455798>.
9. Millett PJ, Romero A, Braun S. Spinal accessory nerve injury after rhytidectomy (face lift): a case report. *J Shoulder Elb Surg*. 2009;18(5):e15–7. <https://doi.org/10.1016/j.jse.2009.01.012>.
10. Chaffoo RAK. Complications in facelift surgery: avoidance and management. *Facial Plast Surg Clin*. 2013;21(4):551–8. <https://doi.org/10.1016/j.fsc.2013.07.007>.
11. Gonzales-Ulloa M. The creation of aesthetic plastic surgery. New York: Springer Science & Business Media; 2013.
12. Pourdanesh F, Esmaeelinejad M, Jafari SM, Facelift NZ. Current concepts, techniques, and principles. *Textb Adv Oral Maxillofac Surg*. 2016;3 <https://doi.org/10.5772/63150>.
13. Chaudhry O, Levine S. Lateral SMASectomy. *Clin Plast Surg*. 2019;46(4):523–32. <https://doi.org/10.1016/j.cps.2019.06.003>.
14. Chopan M, Buchanan PJ, Mast BA. The minimal access cranial suspension lift. *Clin Plast Surg*. 2019;46(4):547–57. <https://doi.org/10.1016/j.cps.2019.06.005>.
15. Miller TR, Eisbach KJ. SMAS facelift techniques to minimize stigmata of surgery. *Facial Plast Surg Clin N Am*. 2005;13(3):421–31. <https://doi.org/10.1016/j.fsc.2005.04.007>.
16. Barrett DM, Gerecci D, Wang TD. Facelift controversies. *Facial Plast Surg Clin N Am*. 2016;24(3):357–66. <https://doi.org/10.1016/j.fsc.2016.03.012>.
17. Chang S, Pusic A, Rohrich RJ. A systematic review of comparison of efficacy and complication rates among face-lift techniques. *Plast Reconstr Surg*. 2011;127(1):423–33. <https://doi.org/10.1097/PRS.0b013e3181f95c08>.

## Introduction

The eyes are arguably the most important facial features when it comes to communication of emotion, age, health, and attitude. The human eye conveys a range of emotions from love to fear and everything in-between. The eyes are one of the first places that we as humans look when we meet someone. Eye contact is very powerful and can play a vital role in our interpretation of other people and how we perceive others' level of engagement. As we age, actinic and degenerative changes of the facial soft tissue lead to loss of elasticity of the skin as well as fat atrophy and appearance of excessive rhytides. When we as humans try to determine someone's age, we consider multiple factors with heavy emphasis on wrinkles and fat redistribution on the face and specifically the periorbital region. The aging changes of the periorbital region convey fatigue, sadness, and just reduce the overall aesthetic appearance. Dermatochalasis (excessive eyelid skin) or steatoblepharon (pseudoherniation of orbital fat) is significant enough to cause a pseudoptosis and reduce the visual fields. Blepharoplasty is a cosmetic procedure to reduce excess eyelid skin and recontour the underlying fat in order to provide a more youthful appear-

ance. Blepharoplasties can be performed alone or in conjunction with other cosmetic procedures. When considering a blepharoplasty for a patient, the provider should consider all aspects of the facial subunits, attempt to determine the patient's overall desires, and formulate a treatment plan to address those needs. The use of minimally invasive cosmetic injectables in combination with a blepharoplasty can provide quite life-changing cosmetic results without the need for very invasive surgery. Among the cosmetic procedures available, blepharoplasty is quite popular due to its relatively short recovery time, ease of operation, and high impact [2, 3].

## Anatomical Consideration

Proper understanding of surgical anatomy is vital to successful outcomes in all surgical procedures. The eye is a very sophisticated area and its unique anatomy often intimidates cosmetic surgeons unfamiliar with this region. The lid complex can be divided into the upper and lower eyelid.

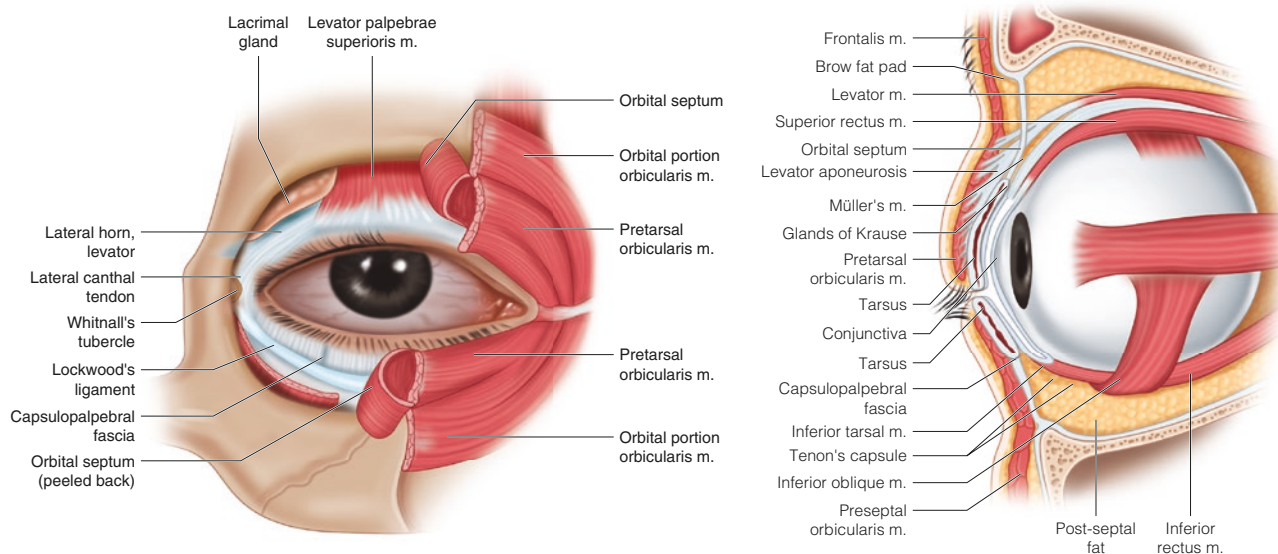
The eyelid skin is one of the thinnest in the body due to its lack of real underlying subcutaneous tissue. The upper eyelid has two segments or subunits. The first is the zone from the lid margin to the lid crease and consists of skin, minimal subcutaneous tissue, orbicularis muscle, levator aponeurosis, tarsus or Muller's muscle superiorly, and conjunctiva. The second subunit is from the crease to the superior orbital rim consisting of the skin, subcutaneous tissue, orbicularis muscle, orbital septum, preaponeurotic fat pads, levator aponeurosis, Muller's muscle, and conjunctiva. The orbicularis muscle is a thin muscle immediately deep to the skin forming concentric circles around the orbit. The orbicularis muscle serves to protract the eyelids and closes the eyelids (see Fig. 20.1). This muscle is innervated by Cranial Nerve VII (the facial nerve). Deep to the orbicularis muscle is the orbital septum that is continuous with the periosteum of the orbit and separates the preseptal and

---

S. Halepas  
NewYork-Presbyterian/Columbia University Medical Center,  
New York, NY, USA  
e-mail: [sh3808@cumc.columbia.edu](mailto:sh3808@cumc.columbia.edu)

X. J. Chen  
Department of Oral and Maxillofacial Surgery, New York  
Presbyterian/Columbia University Medical Center,  
New York, NY, USA  
e-mail: [xc2308@cumc.columbia.edu](mailto:xc2308@cumc.columbia.edu)

M. Banki (✉)  
Clinical Faculty, Department of Surgery, The Warren Alpert  
Medical School of Brown University, Providence, RI, USA  
  
Clinical Faculty, Department of Craniofacial Sciences, Division of  
Oral & Maxillofacial Surgery, University of CT,  
Warwick, RI, USA



**Fig. 20.1** Anatomical illustrations of the periorbital region

postseptal spaces. Posterior to the septum are the fat pads of the eye. The fat pads' main function is to act as a lubricant to allow a smooth continuous movement of the eyes in function. There are three fat pads to the upper eye. The medial and central fat pads compose most of the volume of the upper eyelid. The lateral fat pad contains the lacrimal gland consisting of two lobes and is responsible for tear production to protect the cornea. Deep to the fat pads are the levator aponeurosis and Müller's muscle which act to retract the upper eyelids. The levator is innervated by Cranial Nerve III (the oculomotor nerve), while Müller's muscle is innervated by the sympathetic nervous system. The levator muscle septal fibers extend to the skin and are represented as the lid crease which is typically found about 100 mm above the lid margin, just above the most superior aspect of the tarsal plate. The tarsal plate is the connective tissue support of the eyelid and is about 8–12 mm in the upper eyelid. When the eyelid opens, the lid crease skin is pulled in the superior and posterior directions by the aponeurosis as it retracts under the fat pads.

The lower eyelid is like the upper eyelid. The three fat pads of the lower lid are continuations of the malar fat pad but are separated by the orbital ligaments. The tarsal plate of the lower eyelid is smaller (3–5 mm). The capsulopalpebral fascia is the equivalent to the levator aponeurosis of the upper eyelid. The following seven bones compose the orbit: frontal, zygomatic, maxillary, sphenoid, ethmoid, palatine, and lacrimal. The infraorbital nerve is a continuation of the maxillary nerve after it passes through the pterygopalatine fossa entering the floor of the orbit. About halfway between the apex and the orbital rim, the nerve enters the infraorbital canal running centrally along the floor. The nerve exits the

canal at the foramen about 1 cm below the inferior orbital margin between the levator labii superioris and levator anguli oris muscle.

The periorbital region is very vascular in nature. The supraorbital artery arises from the ophthalmic artery and enters the corrugator muscle at the level of the supraorbital rim and runs in a medial to lateral direction. At the supraorbital notch the vessel branches into superficial vertical and brow branches and deep medial, oblique, and lateral branches. The supratrochlear artery arises from the ophthalmic artery and exits the orbit about 20 mm lateral to the midline. This artery becomes superficial about 15–25 mm above the superior orbital rim but runs medial about 3 mm from the medial canthus. The infraorbital branch of the maxillary artery exits the infraorbital foramen with the nerve and supplies the lower lid and the skin of the midface. The infraorbital artery lies deep to the levator labii superioris muscle and superficial to the levator anguli oris muscle [4]. When performing the blepharoplasty it is unlikely to run into the major branches of the vessel, but rather the numerous small feeding vessels of the skin. The nerves of the periorbital region are also unlikely to be in the surgical field.

## Indications

Blepharoplasty is often performed due to cosmetics concerns. As stated, it can be used to enhance the overall cosmetic appearance of the face as the eyes are an essential component to beauty. Upper and lower eyelid blepharoplasties are often used to remove excess skin and fat to aid in facial rejuvenation.

Aging is a typical cause of dermatochalasis or sagging of the eyelids due to skin redundancy and lid atrophy. The overall prevalence of dermatochalasis among individuals 45 years or older is reported to be 16% and is more frequent in males [6]. Repeated contraction of the orbicularis muscle over time, along with gravity, leads to decreased elasticity of the skin and weakening of the connective tissues in the forehead. Many patients present with cosmetic concerns of drooping eyes, and complain of a tired aged appearance. For some, the eyelid ptosis can be severe enough to cause peripheral visual field reduction. Steatoblepharon, which is anterior prolapsing of the eyelid fat pad due to weakening of the orbital septum, causes a puffy eye appearance. Indications for upper lid blepharoplasty are asymmetry, muscle laxity, excessively high/low lid crease, excessive wrinkling, and skin laxity. The indications for a lower lid blepharoplasty include dermatochalasis and fat herniation [5, 6].

---

## Patient Evaluation

A full medical history and evaluation are necessary before any surgical procedure. It is important to identify any underlying medical conditions, especially those that may have a direct association with the eyes/peri-orbital region. Specific follow-up questions should address thyroid abnormalities, autoimmune disease, dry eyes, chronic blepharitis, ptosis, and previous surgeries such as LASIK (laser in situ keratomileusis) or photorefractive keratectomy (PRK). Blepharoplasty is relatively contraindicated in patients with recent eye surgery such as LASIK within the past 6 months. Patients with persistent dry eye symptoms should also be avoided to an increased risk of worsening symptoms. Autoimmune diseases such as Graves' disease and myasthenia gravis should be properly medically managed and should be free of symptomatic orbitopathy for 1 year before considering a cosmetic blepharoplasty.

A full ophthalmologic evaluation should be performed that includes a visual acuity test, ocular muscle motility, and a basic tear secretion test to ensure adequate tear production. An option is a Schirmer's test which is performed by placing a strip of test paper over the temporal palpebral conjunctiva and measuring the wetting on the strip after 5 minutes. Measurements of less than 10 mm may indicate inadequate production and one may consider avoiding a cosmetic blepharoplasty.

As with any cosmetic patient, it is important to have a good understanding of the patient's motives for the procedure and what goals they are looking for. Much of cosmetic surgery involves managing patient's expectations and good patient selection. Although blepharoplasty can be quite a life-changing procedure, it is important that the patient does not have any unrealistic expectations.

When assessing the cosmetic patient, it is vital to take a holistic approach looking at all areas of the face. Preoperative photographs can be helpful in both treatment planning and for patient records. Determine the overall quality of the patient's skin including any history of hypertrophic scarring/keloids. Observe the level and shape of the hairline as it corresponds to the position of the brows. The eyebrows are important components of facial beauty, and asymmetries in the eyebrows can become more apparent after other cosmetic components are improved. One should assess the relationship of the brow position to the upper eyelid and determine whether and upper lid blepharoplasty is sufficient or whether a brow-lift may be indicated in addition to or in lieu of the blepharoplasty in order for the patient to achieve his/her desired results. Manual manipulation of the brow to the desired position allows the patient and surgeon to determine the role the brow plays in the eyelid position. The presence of excess skin, skin laxity, and fat herniating of the upper eyelid needs to be determined after optimal brow position has been established. Preoperative measurements of the eyelid aperture should be recorded, noting the high point of the upper lid and the shape of the palpebral fissure. The position of the lid crease and fold should also be recorded. The amount of excess skin should be evaluated after the surrounding structures have been corrected mentally. If a brow-lift is also planned, the amount of excess of lid skin requiring removal will be less. Laxity of the canthal tendons is also noted and manually tightened with the finger before considering removal of any skin. The lower lid is assessed in a similar fashion. The lower lid fat pads are more often involved, and the amount of fat removal or repositioning needs to be calculated preoperatively [7–9].

---

## Anesthesia

A topical anesthetic can be used for conjunctival anesthesia if a protective corneal shield is being utilized. Local infiltration is usually enough for blepharoplasties although these procedures can be performed under oral sedation, IV sedation, or under general anesthesia depending on specific patient factors. Most patients will tolerate the procedure with just the use of lidocaine with a vasoconstrictor such as epinephrine. Many providers make a personalized local anesthetic. Utilizing combinations of lidocaine, bupivacaine, epinephrine, bicarbonate, and tranexamic acid can provide great local anesthetic with hemostatic control. 1–2 mL of anesthetic is placed subcutaneously at the surgical site with a 30-gauge needle. The anesthetic is useful in causing hydro-dissection, and can increase ease of the procedure. When fat pads are to be contoured, additional local anesthetic is injected into the fat pads perioperatively as they are often more difficult to fully anesthetize. It is best to inject the local anesthetic after the eyelids are marked to prevent any distortion.

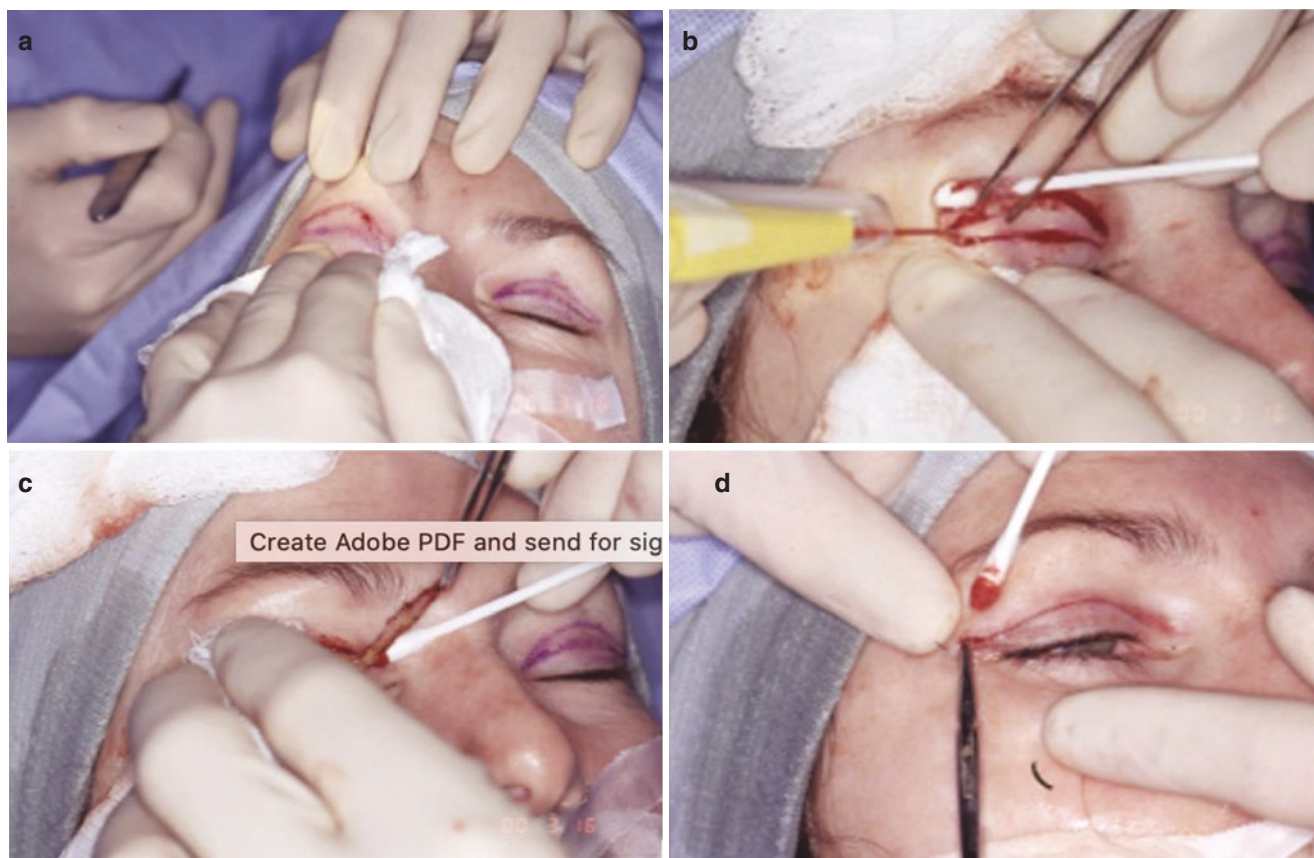


## Upper Lid Blepharoplasty

Marking the patient in the supine position allows for adequate relaxation of the skin and can help to prevent lagophthalmos after the procedure. Markings in the upright position should be in a neutral gaze with brows properly positioned and relaxed. The natural upper eyelid crease is situated above the ciliary margin at approximately 8–9 mm in women and 7–8 mm in men. The lower limit of excision should be along the eyelid crease. Nasally, the incision should be limited by a line drawn upward from the medial commissure, avoiding the deep concavity of the medial canthal region. The lateral extent of the marking should be limited by an imaginary line joining the lateral end of the brow to the lateral canthus. Carrying the incision too far medially may result in scar band formation or medial webbing. Lateral extension of the incision beyond the orbital rim also results in a more prominent and visible scar. To assess the amount of skin to be removed, the surgeon may use the pinch technique. The patient is asked to gently close the eyelids, and smooth forceps are used to grasp the excess skin above the eyelid crease incision just until the eyelashes begin to rotate upward. This is marked as the maximum amount of skin that may be safely removed. A minimum of 20 mm of vertical lid height from the inferior border of the brow to the ciliary

margin should be preserved for normal eye closure. Once the skin has been marked with the patient in an upright position, the surgeon gently presses on the globe to observe protrusion of the fat pockets. The location and amount of protrusive fat is assessed and considered for surgical contouring [10].

The lid is placed under traction and a Bard-Parker #15 blade or monopolar cautery is used to incise the skin to the level of the dermis. Utilization of cautery allows for a relatively bloodless plane and less postoperative swelling. The skin flap is then removed with a blade or Wescott scissors leaving the underlying muscle intact. Excision of fat is only removed if obvious protrusion is noted when the patient was in the upright position to try and prevent a puffy appearance. To access the fat, a small incision (about 2 mm) with cautery is made just below the orbital rim through the orbicularis muscle and septum. Scissors can be utilized to spread and prolapse the fat. Gentle pressure on the globe can facilitate additional fat herniation, and conservative removal is performed. The incision through the orbicularis muscle does not need to be sutured. The lid skin is closed with 5-0 fast-absorbing gut, 6-0 nylon, or prolene sutures depending on the surgeon's preferences and in a simple non-locking running suture. Utilization of some tacking sutures can be useful (see Fig. 20.2).



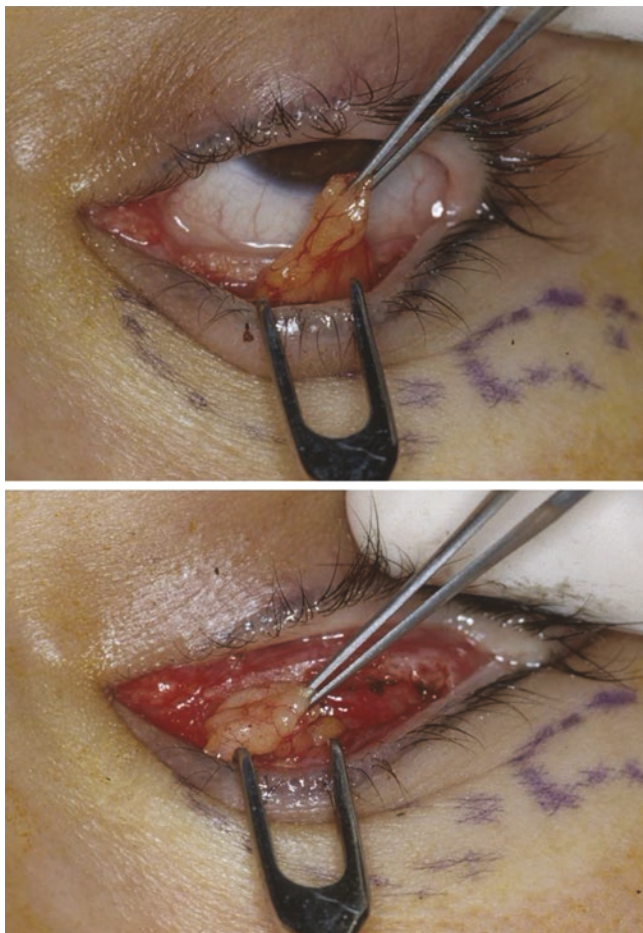
**Fig. 20.2** (a) Incision markings, (b) lid is placed under traction and monopolar cautery is used to incise the skin to the level of the dermis, (c) skin flap is removed, (d) the skin is closed with 5-0 gut suture.

(Photo courtesy of Michael J. Will, MD, DDS, FACS, Will Surgical Arts, 3280 Urbana Pike, Suite 201, Ijamsville, MD 21754)

## Lower Lid Blepharoplasty

Unlike the upper blepharoplasty where the majority of cases involved just skin removal, lower blepharoplasties usually involve fat redistribution.

In the transcutaneous approach, the skin is marked about 3 mm inferior to the lash line from the inferior punctum to the lateral canthal angle. If the skin is to be removed or if the orbicularis muscle is to be tightened, the incision is extended laterally and downward toward the earlobe. The skin is incised with a #15 blade, and scissors are used to dissect into the sub-orbicular plane and along the anterior surface of the orbital septum. The septum can be identified by pushing on the globe gently causing prolapse of the fat beneath the septum. Each of the fat pad capsules is open with scissors. The temporal and central fat pads are separated by vertical bands of fascia between the orbital septum and the capsulopapebral fascia. The fat is then teased out gently to avoid excessive bleeding. The medial fat pad needs extra care as to not harm the inferior oblique muscle as the fat is excised (see Fig. 20.3).



**Fig. 20.3** (Top) central fat pad and (Bottom) medial fat pad. (Photo courtesy of Michael J. Will, MD, DDS, FACS, Will Surgical Arts, 3280 Urbana Pike, Suite 201, Ijamsville, MD 21754)

In the transconjunctival approach, the lid is everted with a Desmarres retractor and the eye is protected with a Yeager lid plate. A CO<sub>2</sub> laser or electrocautery is used to make a 3 cm transverse incision through the conjunctiva about 4 mm behind the infraorbital rim and the lateral fat pad is exposed with the utilization of a buttonhole incision through the conjunctiva laterally about 4 mm from the inferior tarsal plate. The lateral fat pad is easily identified before any bleeding occurs. The incision can then be extended medially to expose the central and medial fat pads which can then be removed with electrocautery, CO<sub>2</sub> laser, and/or fine scissors. Closure of the conjunctiva is completed with a few 6-0 plain catgut sutures. This approach hides any incisions within the inner eyelid and allows for a very pleasing result.

## Postoperative Care

Ophthalmic antibiotic ointment is applied on cutaneous incisions. The patient is instructed to apply cold packs to the surgical site to help reduce swelling. Severe pain is not expected, and usually the utilization of alternating acetaminophen and ibuprofen is adequate management. If non-resorbable sutures are used, they can be removed 5–7 days following the procedure. As with all cosmetic patients, adequate follow up is recommended for both patient satisfaction and early identification of any complications. Systemic antibiotics are unnecessary.

## Complications

### Retrobulbar Hemorrhage

Retrobulbar hemorrhage is a very rare but serious complication following this type of procedure. Acute compartment syndrome can occur due to bleeding into the retrobulbar space leading to ischemic injury to the optic nerve potentially leading to devastating blindness. Strict hemostasis at the time of surgery is very important in preventing this complication. Other factors to minimize bleeding include blood pressure control and discontinuation of antiplatelet/anticoagulant medication that can predispose to postsurgical bleeding. This complication is well known to many in maxillofacial surgery, plastic surgery, otolaryngology, and ophthalmology who manage facial trauma, but may be less familiar to others in the cosmetic field. Retrobulbar hemorrhage is a surgical emergency that can result in permanent vision loss. The patient will present with a sudden onset of a severe and unilateral ocular pain, elevated intraocular pressure, and vision changes. If a retrobulbar hemorrhage is suspected,

the surgical incision should be reopened and explored for bleeding. If a hematoma cannot be identified or controlled, and elevated ocular pressures are persistent, a lateral canthotomy and cantholysis might be indicated for orbital decompression in order to prevent the risk of blindness [11].

## Infection

Postsurgical infections in blepharoplasty are exceedingly rare due to the rich blood supply to the orbit and associated area (around 0.2–0.4%). Post-operative antibiotics are generally unnecessary. Some recommend the use of perioperative antibiotics, however others suggest that this too may also not be indicated. The most important reduction of postsurgical infection is a proper sterile procedure. Mild erythema, swelling, and pain are expected after any surgical procedure. Preseptal cellulitis, which usually presents with mild pain, and drainage can usually be managed with oral fluoroquinolones or third-generation cephalosporins. Severe eye pain, lid erythema, swelling, and decreased visual acuity can be more suspicious for orbital cellulitis. Orbital cellulitis is most frequently due to *Streptococcus*, *Staphylococcus*, and atypical *Mycobacterium* infections. If orbital cellulitis is suspected, computed tomography is indicated to assess for postseptal abscess, and possible cavernous sinus thrombosis. Treatment for orbital cellulitis often requires hospitalization with broad-spectrum antibiotics and surgical drainage when indicated [12].

## Blepharoptosis

This complication occurs due to injury to the levator muscle during the procedure. To prevent this, it is recommended to minimize dissection beyond the preaponeurotic fat compartments. Transient postsurgical ptosis is sometimes observed due to postoperative edema. If ptosis persists longer than 6 months, suspect levator aponeurosis injury that will require surgical repair.

## Lid Malposition

Lid malposition is a relatively common complication following blepharoplasty. Retraction and ectropion are caused by excessive skin resection, edema, or scar contraction.

This can lead to eye dryness, conjunctival irritation, and exposure keratopathy. Entropion is usually caused by posterior lamellar deficiency. Management of lip malposition is a surgical challenge often requiring a very experienced oculoplastic surgeon. Excessive skin removal or inappropriately placed skin incisions can result in both cosmetic and functional failures. While it is a balancing act to ensure proper aesthetic results for the patients in this type of procedure it is best to stay on the conservative side when removing the skin. Excessive skin removal can cause lagophthalmos which can result in a range of complications including stromal scarring and vision loss and, as stated, is very difficult to correct [13].

## Corneal Abrasion

Eyelid surgery poses risk to damage to the underlying corneal epithelium which is usually noted immediately postoperatively. Symptoms present as severe pain, tearing, foreign body sensation, and or photophobia [14].

## Conclusion

Blepharoplasty is an excellent surgical procedure to offer patients seeking facial rejuvenation. The procedure can have quite an impact in restoring the youthfulness of the face. Overall, the procedure has minimal downtime and can easily be performed in the office setting. Successful outcomes are from proper patient selection and proper management of patient expectations.

## References

1. Surgery, T. A. S. f. A. P., Cosmetic (Aesthetic) Surgery National Data Bank. 2018.
2. Ko A, Korn B, Kikkawa D. The aging face. Survey Ophthalmol. 2017;62:190–202.
3. Oliva M, Anikin A. Pupil dilation reflects the time course of emotion recognition in human vocalizations. Sci Rep. 2018;8(1):4871.
4. Ferneini EM, Halepas S, Watras J, Ferneini AM, Weyman D, Fewins J. Surgeon's guide to facial soft tissue filler injections: relevant anatomy and safety considerations. J Oral Maxillofac Surg. 2017;75(12):2667.e1–5.
5. Bhattacharjee K, Misra DK, Deori N. Updates on upper eyelid blepharoplasty. Indian J Ophthalmol. 2017;65(7):551–8.
6. Branham GH. Lower eyelid blepharoplasty. Facial Plast Surg Clin North Am. 2016;24(2):129–38.

7. Jindal K, Sarcia M, Codner MA. Functional considerations in aesthetic eyelid surgery. *Plast Reconstr Surg*. 2014;134(6):1154–70.
8. Zoumalan CI, Roostaeian J. Simplifying blepharoplasty. *Plast Reconstr Surg*. 2016;137(1):196e–213e.
9. Duncan K, Yu J. Blepharoplasty. In: Fonseca R, editor. *Oral and maxillofacial surgery*; 2017.
10. Chen J, Koch A, Banki M. Blepharoplasty. In: Ferneini E, Goupil M, editors. *Office-based maxillofacial surgical procedures*. Cham: Springer; 2019.
11. McBride K. Blepharoplasty. In: *Atlas of oral & maxillofacial surgery*. St. Louis: Elsevier; 2016.
12. Ferneini EM, Halepas S, Aronin SI. Antibiotic prophylaxis in blepharoplasty: review of the current literature. *J Oral Maxillofac Surg*. 2017;75(7):1477–81.
13. Jarecki H, Lucarelli M, Lernke B. Blepharoplasty. In: Miloro M, editor. *Peterson's principles of oral and maxillofacial surgery*. 2nd ed: BC Becker; 2004.
14. Wu C, Wu A, Banki M, Zhu T. Complications of blepharoplasty. In: Ferneini E, Castiglione C, Banki M, editors. *Complications in maxillofacial cosmetic surgery*. Cham: Springer; 2018.



Neel S. Joshi, Brian Wong Won, Walter Jongbloed,  
and Charles L. Castiglione

## Introduction

The external ear is a primarily cartilaginous structure that is unique to mammals and developed to direct sound to the external auditory canal. From a cosmetic standpoint, the shape of the ear can be a distinctive part of a person's visage. As many as 50% of newborns have an auricular deformity [1], but over 80% of these cases improve without intervention by the end of the first year [2]. Prominent ears—present in approximately 5% of the population [1]—are a notable exception, as they tend to increase in severity over the first year of life [2].

It is worth noting that deformities confined to the auricle (i.e., cases without external auditory canal atresia or associated middle/inner ear deformities) do not have a significant impact on hearing capacity [3]. Thus, the majority of otoplasty cases are strictly cosmetic in nature. The most common presentation of a patient for cosmetic otoplasty is *prominauris*, which will be the focus of this chapter, though there are a variety of deformities that may warrant surgical correction, including *microtia*, *cryptotia*, and deformities stemming from oncologic resection. The ear undergoes the majority of its growth in the first few years of life and by age 5 has reached 90–95% of its adult size [4], making otoplasty one of the few cosmetic procedures feasible in the early pediatric population.

Even from a young age, the psychosocial impact of ear deformities can be significant [5]. Studies have shown both

personal dissatisfaction with appearance as well as teasing from peers are strong motivators for patients to undergo otoplasty. In one series, 90% of children and 70% of adults indicated improved self-confidence after undergoing the procedure [6], while in a long-term study of children, statistically significant improvements in anxiety and depression, social problems, and behavioral problems were seen [7].

The first cosmetic otoplasty was described in 1881, involving resection of conchal cartilage and skin [8]. Variations of this technique continued until 1910, when reconstruction of the antihelical fold was attempted [9]. By the 1940s, surgeons were using additional incisions and excisions of cartilage to produce a more natural result [10], while also exploring cartilage sparing techniques that favored shaving over excising tissue. Though many other refinements have been described since, variations of these techniques persist to this day.

## Embryology

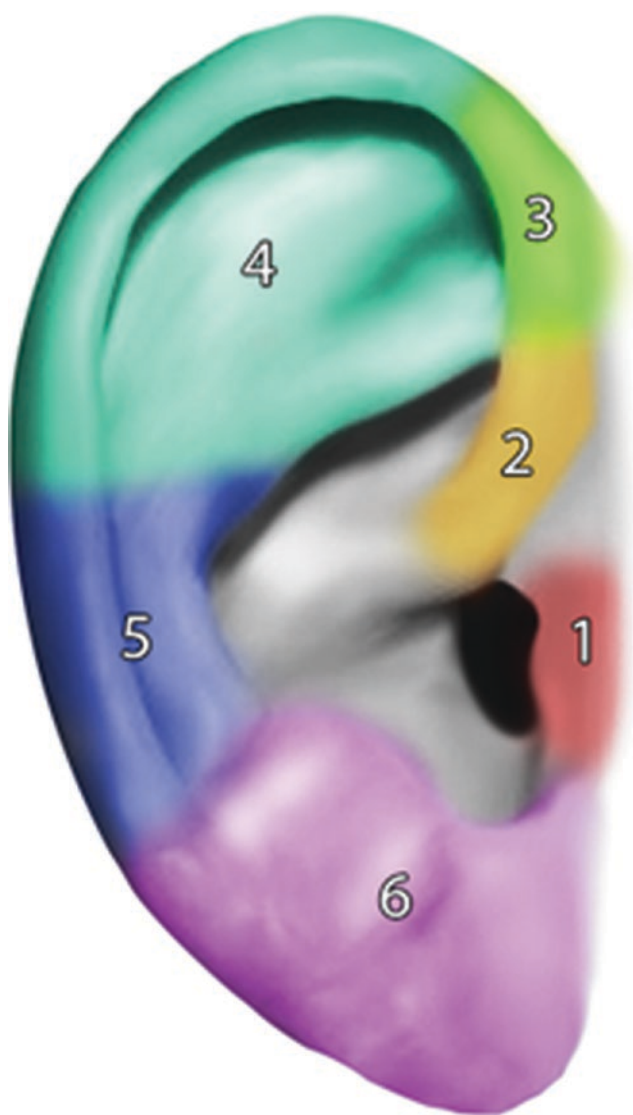
By the end of the second week of development, the embryo has differentiated into its three primary germ layers—the ectoderm, mesoderm, and endoderm—through the process of gastrulation. As the third week begins, the ectoderm gives rise to neurogenic placodes, including the otic placode. Together with the first and second pharyngeal arches, which appear in the fourth week, the otic placode is the precursor of the ear. The auricle specifically is derived from the auricular hillocks, which develop from the aforementioned pharyngeal arches. In total, there are six hillocks, but controversy persists as to what happens from this point forward. The consensus position is that hillocks 1–3 arise from the first arch and 4–6 from the second arch [11]. Accordingly, the tragus and the first portion of the helix (including its root) come from the first pharyngeal arch and the remainder of the ear comes from the second arch (Fig. 21.1). An alternative theory supported by studies of development disorders

---

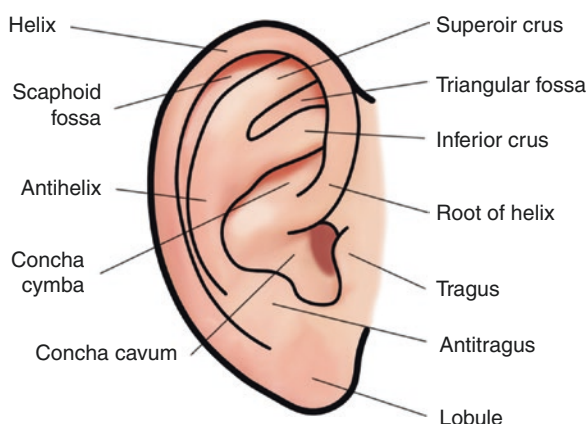
N. S. Joshi · B. W. Won  
UConn Integrated Surgical Residency Program,  
Farmington, CT, USA  
e-mail: [nejoshi@uchc.edu](mailto:nejoshi@uchc.edu); [wongwon@uchc.edu](mailto:wongwon@uchc.edu)

W. Jongbloed  
UConn School of Medicine, Farmington, CT, USA  
e-mail: [jongbloed@uchc.edu](mailto:jongbloed@uchc.edu)

C. L. Castiglione (✉)  
UConn School of Medicine, Hartford Hospital, Connecticut  
Children's Medical Center, Farmington, CT, USA



**Fig. 21.1** The majority of the auricle has its origins traced back to six auricular hillocks, which are derived from the first and second pharyngeal arches. Some controversy remains over the exact portions that arise from each arch



**Fig. 21.2** Anatomic structures of the auricle

suggests that the tragus alone traces its origin to the first arch, while the entire rest of the ear is derived from the second pharyngeal arch [12].

## Anatomy of the Auricle

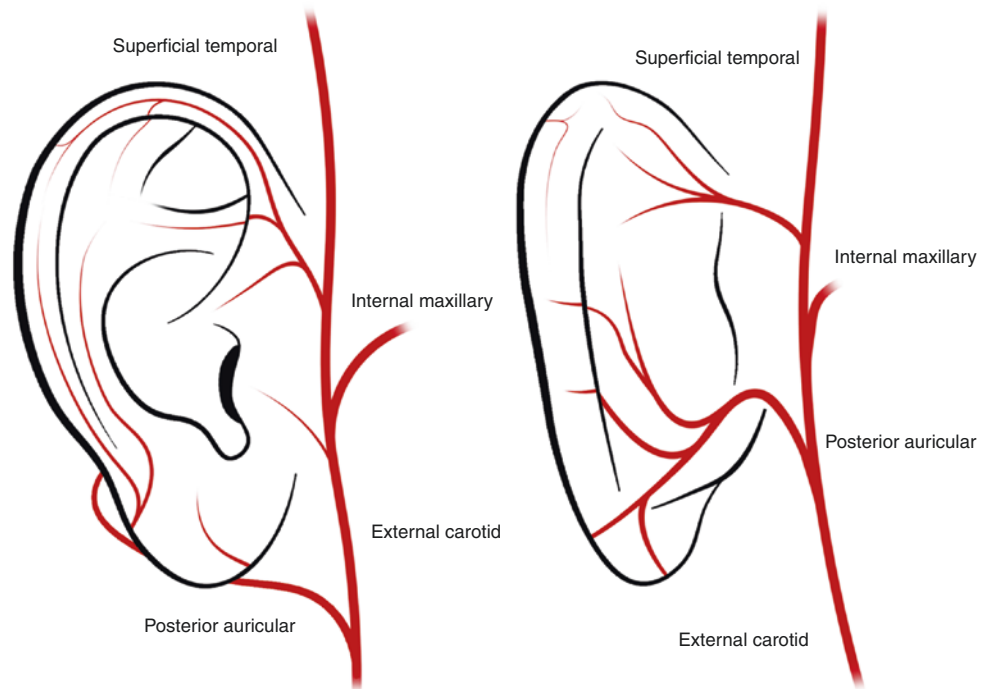
As seen in Fig. 21.2, the external ear is composed of many distinct anatomic elements, each of which contributes to the normal appearance of the ear. The helix defines the outer edge of the ear, as it extends from its root above the tragus and continues around until it meets the lobule at the inferior portion of the auricle. Running alongside the helix is the antihelix, which arises from its crura superiorly and terminates at the antitragus. The concha is a bowl-like depression in the middle of the ear that feeds into the external auditory meatus. Absence or effacement of the antihelix and conchal wall hypertrophy are two of the most common causes of auricular protrusion, and often occur to varying degrees in combination.

A nonanatomic breakdown of the ear into upper, middle, and lower thirds is sometimes favored for the purposes of surgical planning. Rather than strictly defined portions of the ear, these thirds reflect the type of deformity causing prominence. The upper third of the ear roughly extends from the superior aspect of the helix to the point at which the crura of the antihelix meet. Excessive projection of the upper third is typically caused by an inadequately defined antihelix and can be corrected by Mustardé sutures. The middle third spans the concha, and prominence of this region is accordingly due to hypertrophy of the conchal wall. This can be addressed using Furnas sutures for conchal setback with or without cartilage cutting. The lower third of the auricle is the lobule itself, which can be variable in length and degree of projection. Lobule excess typically requires removing a wedge of skin anteriorly and posteriorly.

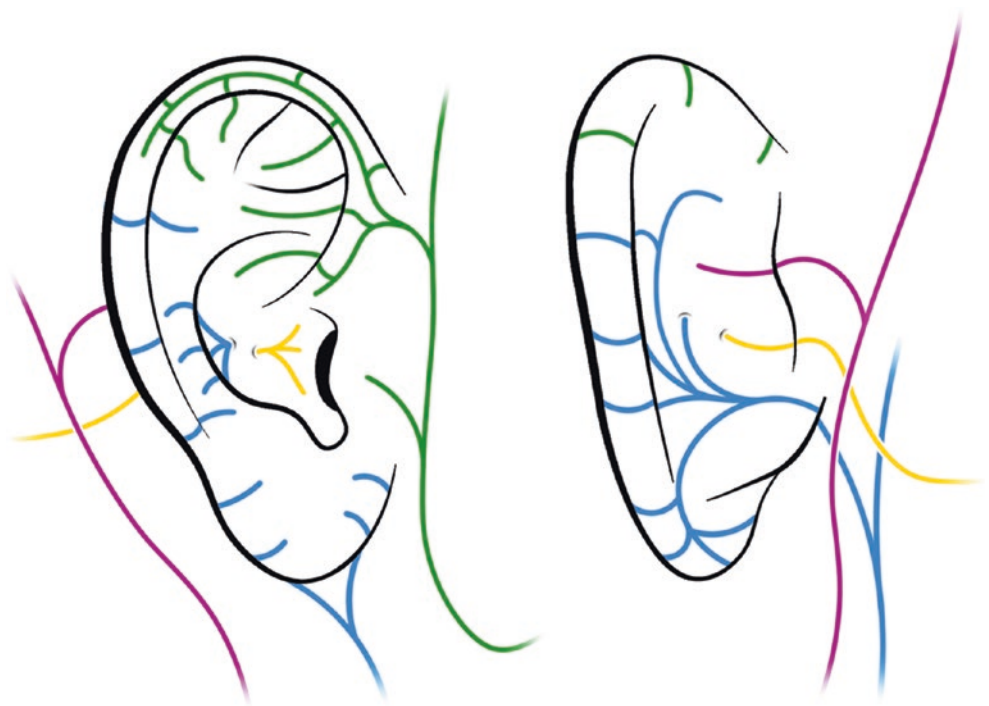The external ear is mostly composed of cartilage and overlying skin, but there are also thin layers of subcutaneous tissue and muscle. Though the intrinsic muscles of the ear are vestigial in nature, the extrinsic muscles serve to hold the ear in its anatomic position, albeit without voluntary action in most cases. The three extrinsic muscles are the auricularis anterior, auricularis superior, and the auricularis posterior. As their names might suggest, these muscles serve to pull the auricle forward, upward, and backward. The auricularis superior is the largest of the three and may be encountered just deep to a subcutaneous advancement flap made for correction of cryptotia.

The blood supply to the auricle arises from branches of the external carotid artery. Superiorly, the ear is fed by the superficial temporal artery, while the inferior and posterior components are supplied by the posterior auricular artery

**Fig. 21.3** The auricle is supplied by branches of the external carotid, namely the superficial temporal and posterior auricular arteries



**Fig. 21.4** Sensory innervation to the external ear is provided primarily by the great auricular nerve (blue), with additional innervation from the auriculotemporal nerve (green), lesser occipital nerve (purple), and Arnold's nerve (yellow)



(Fig. 21.3). Smaller direct branches from the external carotid are also present. The superficial temporal artery gives rise to the anterior auricular branches at the level of the tragus. In just over 20% of cases, these branches instead originate from the parietal branch of the superficial temporal artery [13]. The posterior auricular artery arises deep to the parotid before traveling posteriorly deep to the auricularis posterior muscle and giving off small branches to the ear. Its course brings it in close proximity to the facial nerve near the stylo-

mastoid foramen. A flap supplied by the posterior auricular artery can be fashioned and used for ear reconstruction, among other facial procedures [14].

Sensory innervation to the external ear (Fig. 21.4) comes primarily from the great auricular nerve with additional innervation from the auriculotemporal nerve, the lesser occipital nerve, and the auricular branch of the vagus nerve (Arnold's nerve). Innervation follows embryology, with the tragus, the root of the helix, and a portion of the helix itself derived from the first bran-



chial arch and the remainder of the auricle originating from the second branchial arch. The portions derived from the first branchial arch are supplied by the auriculotemporal nerve, while the great auricular nerve and lesser occipital nerve respectively cover the remainder of the anterior and posterior ear.

Aesthetic Considerations

When evaluating a patient for cosmetic otoplasty, an evaluation of the patient’s ear as compared to normal anatomy is critical. There are a number of characteristics that define normal or ideal anatomy (Table 21.1). The aesthetic ear is between 5.5 and 7 cm in length, with the superior aspect aligned with the lateral eyebrow and inferior portion of the lobule level with the subnasale when viewed in profile (Fig. 21.5). The width of the ear, as measured from the origin

Table 21.1 Characteristics of the aesthetic ear

Height between 5.5 cm and 7 cm
Long axis tilted posteriorly by 15–20°
Ear width 50–60% of height
Auriculocephalic angle of 30°
Superior aspect level with the lateral eyebrow and inferior aspect level with the subnasale
Conchomastoid and conchoscaphalic angles approximately 90°
Helix protrudes between 2 mm and 5 mm further away from the scalp than the antihelix
Helix-to-mastoid distance of 10–12 mm in the upper third, 16–18 mm in the middle third, and 20–22 mm in the lower third
Contour of helical rim is straight when viewed posteriorly

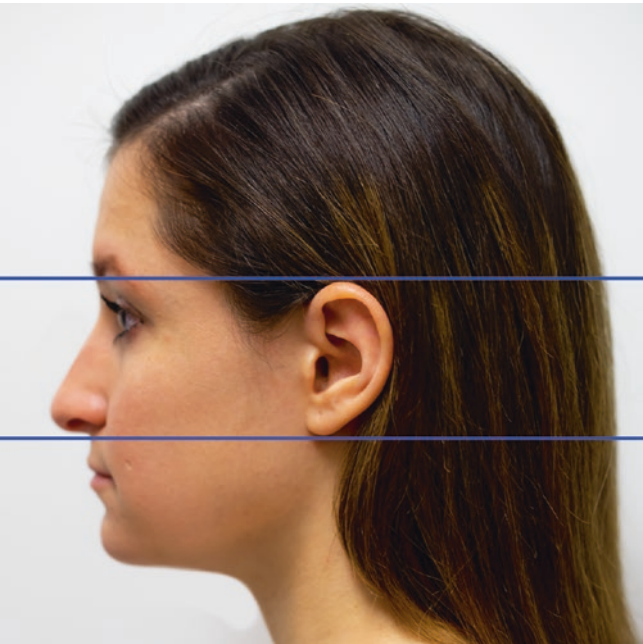


Fig. 21.5 On side view, the superiormost aspect of the auricle aligns roughly with the lateral eyebrow while the inferiormost aspect aligns with the subnasale

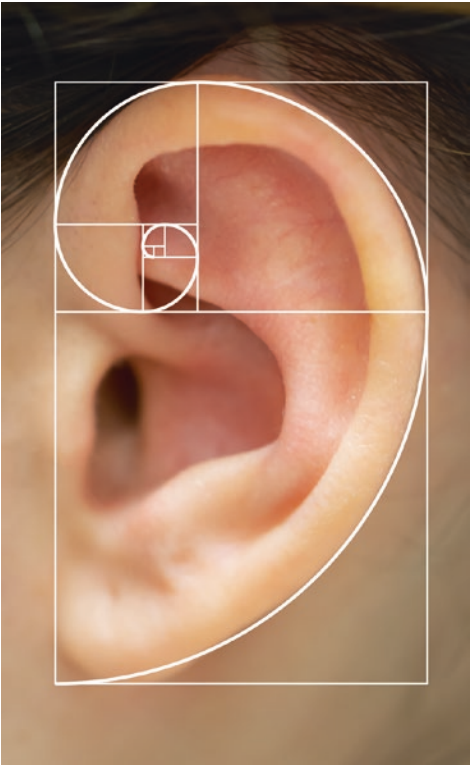


Fig. 21.6 The golden spiral, when mapped over the auricle, closely follows the contour of the helix

of the tragus to the widest portion of the helix, is approximately 55% of the height. The golden ratio ( $\phi \approx 1.618$ ) is a naturally occurring ratio that is often perceived as aesthetically pleasing, and presents itself in many areas of the face. The golden spiral maps fairly well over the helix of the ear (Fig. 21.6), but can overestimate width somewhat.

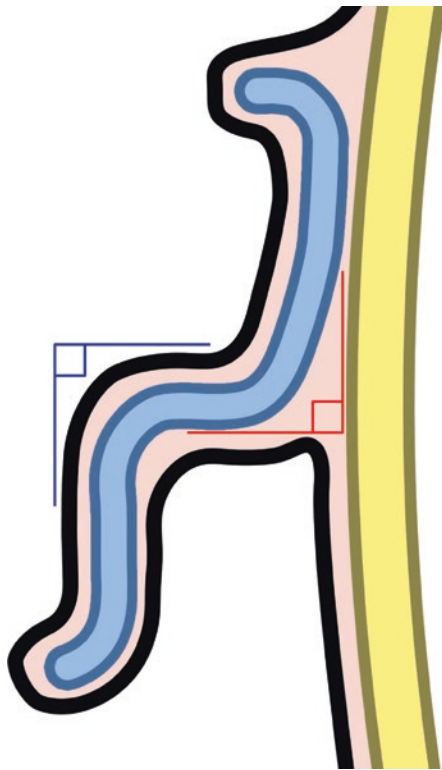
Other notable characteristics of the ear include a 15–20° posterior tilt along the long axis and an auriculocephalic angle around 30°. The auriculocephalic angle is formed by the antero-lateral portion of the helix and the scalp, and is partially determined by variations in the conchomastoid and conchoscaphalic angles, which are typically both around 90° (Fig. 21.7).

As a paired structure, symmetry in the ear is important, but unlike most other symmetrical portions of the human body, much of the ear can only be viewed one side at a time. As such, emphasis should be placed primarily on maintaining evenness on frontal view. It is important to recognize that interaural variance is seen in the normal population [15], and a difference in projection of less than 3 mm can usually be tolerated.

Nonsurgical Otoplasty Techniques

In the early neonatal period, the cartilage of the ear is particularly malleable due to higher levels of circulating estrogen [16]. As previously mentioned, ear deformities are seen frequently in this population, but infrequently require intervention. A subset of these deformities may respond to





**Fig. 21.7** The conchomastoid (red) and conchoscaphoid (blue) angles of the ear are each approximately 90°

nonoperative molding techniques if applied within the first few days of life. A number of studies [17–19] have explored various splinting and molding techniques, the mainstays of which involve fixing the auricle in place against the scalp and using wires/tubing in the scapha or a commercially available system [20] to improve contour for several weeks. Best results were seen in patients with earlier interventions by day 3 of life.

## Surgical Otoplasty Techniques

The ear grows quickly in early development, reaching 85% of adult size by age 3 [21], full adult width at age 6 (girls) or 7 (boys), and full adult length by age 12 (girls) or 13 (boys), with limited variability across ethnicities [22–24]. Surgical correction can therefore be performed early in life without significant risk of constricted growth from scarring or altered morphology from continued growth. Many surgeons consider age 5–7 appropriate timing for otoplasty so as to also minimize the social impact on young patients as they begin to enter schooling and form long-term memories. For patients with mild deformities, it may be more appropriate to encourage patience until the child is old enough to participate in decision-making.

The goals of otoplasty were laid out by McDowell in 1968 [25], and are unsurprisingly reflected in what are now

considered to be the characteristics of the aesthetic ear. Additional technical considerations not already mentioned include correcting all upper third protrusion (though some protrusion in the middle and lower third may be tolerated) and ensuring that the post-auricular sulcus not be markedly distorted or obliterated.

In patients of adolescent age and older, cosmetic otoplasty can be performed under local anesthesia, though general anesthesia is more commonplace. In younger patients unable to cooperate well with positioning, general anesthesia is essentially imperative. Local anesthetic administered anterior to the tragus, posterior to the concha, and inferior to the base of the ear should provide an adequate block of the auriculotemporal, posterior occipital, and great auricular nerves, respectively. Practically, a “ring block” around the base of the ear may help ensure complete coverage [26]. Additional anesthetic can be administered at the surgical area of interest, which can also aid in dissecting planes.

Surgical otoplasty falls into two major categories: cartilage-cutting and cartilage-sparing. Historically, all otoplasty involved cartilage cutting, but over time cartilage-sparing techniques have gained favor as a first-line approach. Minimally invasive otoplasty involving no skin incisions or utilizing endoscopy has also been described, but is outside the scope of this chapter.

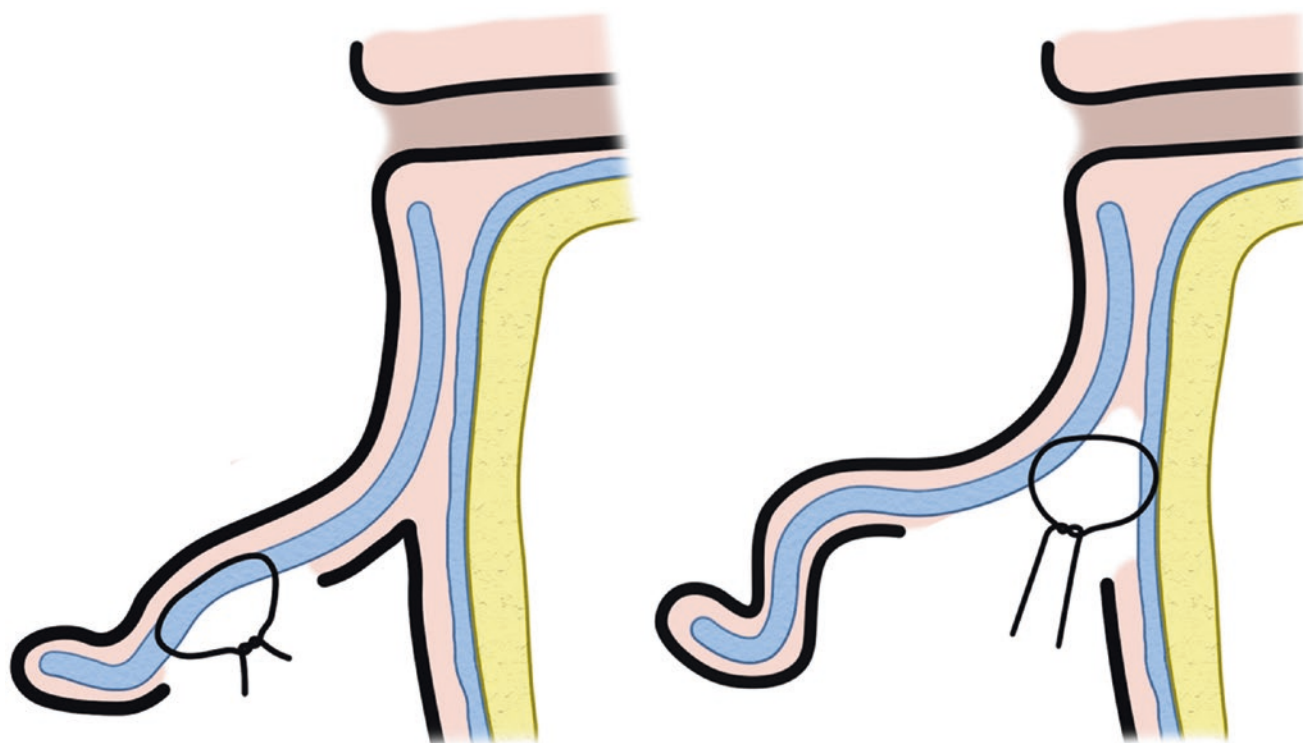
## Cartilage-Sparing Techniques

Mustardé first described [27] the use of mattress sutures alone to recreate the antihelical fold—without the need for cartilage incision or excision—in 1968. Since then, Mustardé sutures have become a mainstay of antihelix reconstruction. Nonabsorbable suture is used, and bites are spaced out approximately 10 mm vertically and 15 mm horizontally, with the degree of antihelical projection determined by how tightly these sutures are tied. As no cartilage is cut, the resultant contour remains smooth.

The Furnas technique [28] for conchomastoid setback addresses conchal excess without excising cartilage. Permanent sutures are placed full-thickness through the conchal cartilage and mastoid fascia, pinning the ear back against the scalp. Care should be taken not to advance anteriorly on the mastoid bites, as this may have the unintended consequence of narrowing the external auditory canal (Fig. 21.8).

## Cartilage-Cutting Techniques

A variety of cartilage-cutting techniques have been described that involve incising, scoring, abrading, or excising auricular cartilage. These can be applied to prominence in the upper and middle thirds of the ear. While these techniques tend to



**Fig. 21.8** Mustardé sutures (left) span the antihelix, causing the cartilage to fold on itself and recreating the antihelical fold. The conchomastoid setback as described by Furnas (right) involves full-thickness sutures through the cartilage, addressing conchal excess without excision

fare better at creating a significant correction, one of the main drawbacks is an unnatural result. Luckett [9] was the first to describe antihelical reconstruction in 1910 by excising a crescent of cartilage via a posterior incision and reapproximating the edges. This cut cartilage had a tendency to produce an abrupt edge rather than a smoother curve when bent, leading to the Converse technique, which involves incising the cartilage on either side of the antihelix without actually excising any tissue [29]. The strip of cartilage between the incisions is instead pushed anteriorly as the cut edges are approximated, and is sometimes filed down to create a more rounded appearance of the antihelix.

One approach for addressing conchal excess is the Davis procedure [30], which involves excision of excess cartilage in the floor of the concha. The typical excision is 8–10 mm of depth, however each patient should be individually evaluated for the amount of necessary correction. The soft tissue in the postauricular area is also removed, including the posterior auricular muscle. The dermal surface of the conchal bowl is thus laid against the mastoid fascia, and secured either with direct sutures or a bolster (Fig. 21.9).

Rather than perform a full excision of cartilage, the surface can be scored and made to bend away from the injury. This property of cartilage was discovered by Gibson and Davis [31] and utilized in the Chongchet [32] and Stenstroem

[33] techniques, which involve scoring the antihelix with a scalpel or blindly using a rasp.

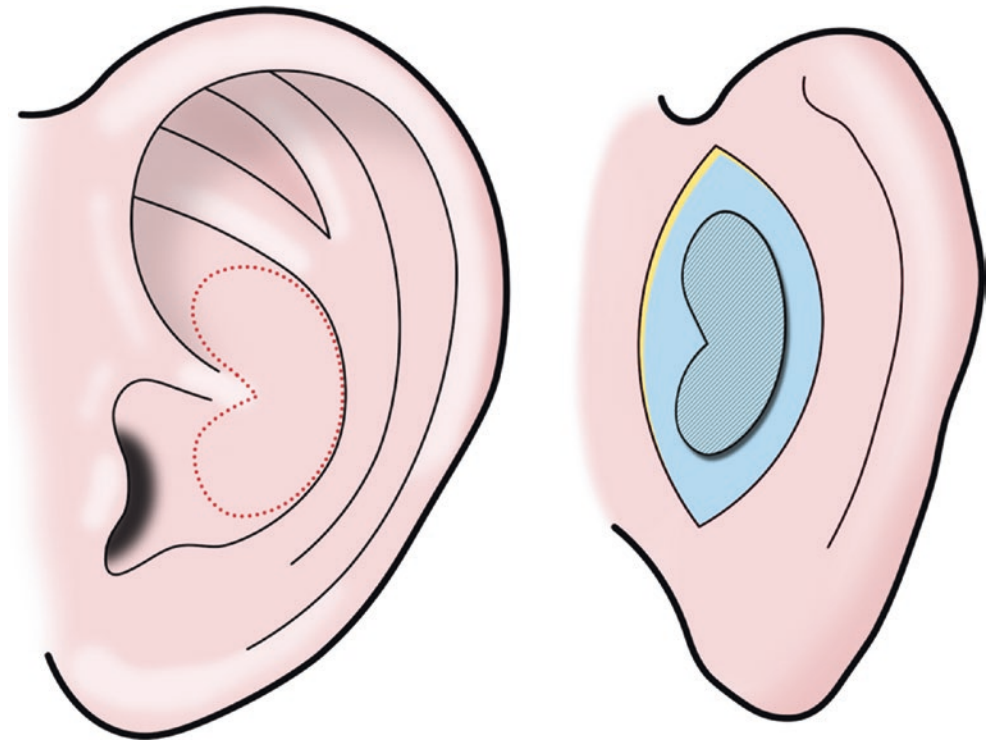
### Combining Techniques

In order to fine-tune a procedure and tailor it to a patient's needs, merging the above techniques may prove useful. For example, though the original Mustardé technique was completely cartilage-sparing, many surgeons now incorporate scoring or incising within the fold to weaken the cartilage and prevent recurrence. Similarly, to facilitate a Furnas conchomastoid setback and mitigate the risk of auditory canal narrowing, a shave excision of the anterior conchal cartilage can be performed [4]. Additionally, a majority of patients will have both an underdeveloped antihelix and hypertrophic concha, thus necessitating a combined approach.

### Correcting the Prominent Lobule

Following correction of upper- and middle-third deformities, consideration must be given to the lobule to ensure it is not abnormally projected relative to the rest of the ear. As the lobule contains no cartilage and is comprised of only skin

**Fig. 21.9** The Davis otoplasty addresses conchal excess by excising a kidney bean-shaped piece of cartilage from the conchal bowl. Tattooing from the anterior side, as seen at left, can help with identifying the margins of resection posteriorly



and subcutaneous tissue, extending the initial surgical incision to include a modified fishtail inferiorly can bring the lobule back into alignment [34].

## Complications

Overall, otoplasty is met with good outcomes, and in the setting of appropriate preoperative counseling and expectation management, the majority of patients are satisfied with their results [35]. Complications can occur, however. Hematoma is an early complication with reported incidence from 2% to 3.5% [36]. Patients present in the first 24 hours with unilateral pain and a tense, bluish swelling. Treatment requires clot evacuation, compression, and antibiotics. A delay in diagnosis can lead to necrosis of the overlying skin or cartilage. Wound infections are another early complication that develop in less than 5% of cases [4]. Presentations involve erythema, swelling, pain, and/or drainage. Washout, followed by antibiotics, is sufficient to manage most cases. The surgeon must remain vigilant for chondritis, however, as this requires surgical debridement [37]. Late complications can include suture extrusion, scarring/keloid formation, loss of correction, and other aesthetic complications.

## Aesthetic Complications

There are a few patterns of postsurgical deformity that are worth noting. The telephone-ear deformity is characterized by excessive projection of the upper and lower thirds of the ear relative to the middle. This may be due to excessive conchal setback or an undercorrected upper and lower third. Treatment involves either redoing the patient's Mustardé sutures to more aggressively recreate the antihelix or relaxing the conchal setback. If appropriate, the lobule can be addressed concurrently. The reverse telephone-ear deformity involves relative prominence of the middle third of the ear, as the name might suggest. Typically, correction involves redoing the conchomastoid sutures.

The vertical post deformity is caused by vertically oriented—rather than oblique—Mustardé sutures, resulting in the superior crus of the antihelix oriented vertically rather than roughly concentrically with the helix. Addressing this would require replacing the incorrectly oriented sutures.

Often, the surgeon is more critical of postoperative aesthetic imperfections than the patient [38]. Therefore, a frank discussion to assess the patient's satisfaction with the procedure should precede any discussion of revisional surgery.

## References

1. Zhao H, Ma L, Qi X, et al. A morphometric study of the newborn ear and an analysis of factors related to congenital auricular deformities. *Plast Reconstr Surg*. 2017;140(1):147–55.
2. Matsuo K, Hayashi R, Kiyono M, et al. Nonsurgical correction of congenital auricular deformities. *Clin Plast Surg*. 1990;17(2):383–95.
3. Greene AK. Otoplasty. In: Chung KC, editor. *Grabb and Smith's plastic surgery*. 8th ed. Philadelphia: Wolters Kluwer; 2020.
4. Banks C, Cheney M. Otoplasty surgical technique. *Open Access Atlas Otolaryngol Head Neck Oper Surg*; 2017.
5. Macgregor F. Ear deformities: social and psychological implications. *Clin Plast Surg*. 1978;5(3):347–50.
6. Horlock N, Vögelin E, Bradbury ET, Grobbelaar AO, Gault DT. Psychosocial outcome of patients after ear reconstruction: a retrospective study of 62 patients. *Ann Plast Surg*. 2005;54(5):517–24.
7. Songu M, Kutlu A. Long-term psychosocial impact of otoplasty performed on children with prominent ears. *J Laryngol Otol*. 2014;128(9):768–71.
8. Ely ET. An operation for prominence of the auricles. *Arch Otol*. 1881;10:97–9.
9. Luckett W. A new operation for prominent ears based on the anatomy of the deformity. *Surg Gynecol Obstet*. 1910;10:635–7.
10. Becker OJ. Surgical correction of the abnormally protruding ear. *Arch Otolaryngol*. 1949;50(5):541.
11. Choo DI, Richter GT. Development of the ear. In: Ballenger JJ, Snow JB, editors. *Ballenger's otorhinolaryngology: head and neck surgery*. USA: PMPH; 2003.
12. Sauter R, Villavicencio E, Schwager K. Doubling of the pinna, a rare branchial arch developmental disorder. *Laryngo-Rhino-Otologie*. 2006;85(9):657–60.
13. Pinar YA, Govsa F. Anatomy of the superficial temporal artery and its branches: its importance for surgery. *Surg Radiol Anat*. 2006;28(3):248–53. <https://doi.org/10.1007/s00276-006-0094-z>.
14. Kolhe PS, Leonard AG. The posterior auricular flap: anatomical studies. *Br J Plast Surg*. 1987;40(6):562–9.
15. Driessen JP, Borgstein JA, Vuyk HD. Defining the protruding ear. *J Craniofac Surg*. 2011;22(6):2102–8.
16. Kenny FM, Angsusingha K, Stinson D, Hotghkiss J. Unconjugated estrogens in the perinatal period. *Pediatr Res*. 1973;7(10):826–31.
17. Matsuo K, Hirose T, Tomono T, et al. Nonsurgical correction of congenital auricular deformities in the early neonate. *Plast Reconstr Surg*. 1984;73(1):38–50.
18. Tan ST, Abramson DL, MacDonald DM, Mulliken JB. Molding therapy for infants with deformational auricular anomalies. *Ann Plast Surg*. 1997;38(3):263–8.
19. Ullmann Y, Blazer S, Ramon Y, Blumenfeld I, Peled JJ. Early nonsurgical correction of congenital auricular deformities. *Plast Reconstr Surg*. 2002;109(3):907–13.
20. Byrd HS, Langevin CJ, Ghidoni LA. Ear molding in newborn infants with auricular deformities. *Plast Reconstr Surg*. 2010;126(4):1191–200.
21. Adamson JE, Horton CE, Crawford HH. The growth pattern of the external ear. *Plast Reconstr Surg*. 1965;36(4):466–70.
22. Farkas LG, Posnick JC, Hreczko TM. Anthropometric growth study of the ear. *Cleft Palate-Craniofacial J*. 1992;29(4):324–9.
23. Zhao S, Li D, Liu Z, et al. Anthropometric growth study of the ear in a Chinese population. *J Plast Reconstr Aesthetic Surg*. 2018;71(4):518–23.
24. Kalcioğlu MT, Miman MC, Toplu Y, Yakinci C, Özturan O. Anthropometric growth study of normal human auricle. *Int J Pediatr Otorhinolaryngol*. 2003;67(11):1169–77.
25. McDowell AJ. Goals in otoplasty for protruding ears. *Plast Reconstr Surg*. 1968;41(1):17–27.
26. Cosmetic otoplasty and related ear conditions. In: Niamtu J, editor. *Cosmetic facial surgery*. Elsevier Health Sciences; 2010.
27. Mustardé JC. The correction of prominent ears using simple mattress sutures. *Br J Plast Surg*. 1963;16:170–6.
28. Furnas DW. Correction of prominent ears by conchamastoid sutures. *Plast Reconstr Surg*. 1968;42(3):189–94.
29. Converse J, Johnson N, Nigro A, Wilson F. A technique for surgical correction of lop ears. *Trans Am Acad Ophthalmol Otolaryngol*. 1956;60(4):551–6.
30. Davis J. *Aesthetic and reconstructive Otoplasty*. New York: Springer New York; 1987.
31. Gibson T, Davis WB. The distortion of autogenous cartilage grafts: its cause and prevention. *Br J Plast Surg*. 1957;10:257–74.
32. Chongchet V. A method of antihelix reconstruction. *Br J Plast Surg*. 1963;16:268–72.
33. Stenstroem SJ. A “natural” technique for correction of congenitally prominent ears. *Plast Reconstr Surg*. 1963;32:509–18.
34. Wood-Smith D. Otoplasty. In: Rees T, editor. *Aesthetic plastic surgery*. Philadelphia: Elsevier Health Sciences; 1980.
35. Schneider AL, Sidle DM. Cosmetic Otoplasty. *Facial Plast Surg Clin North Am*. 2018;26(1):19–29.
36. Owsley TG, Biggerstaff TG. Otoplasty complications. *Oral Maxillofac Surg Clin North Am*. 2009;21(1):105–18.
37. Janis JE, Rohrich RJ, Gutowski KA. Otoplasty. *Plast Reconstr Surg*. 2005;115(4):60e–72e.
38. Richards SD, Jebreel A, Capper R. Otoplasty: a review of the surgical techniques. *Clin Otolaryngol*. 2005;30(1):2–8.



## Introduction

Overall facial symmetry is associated with perceived attractiveness and beauty [1]. Proper facial proportions play a crucial role in subjective attractiveness. Genioplasty comes from the word *genion*, the apex of the mental spine of the mandible and the Greek word *plastós* meaning molded, formed, or shaped. Genioplasty is often used in combination with other esthetic procedures such as rhinoplasty, orthognathic surgery, or rhytidectomy. The chin is the inferior point of the face and its position and morphology are essential components of facial harmony, and a prominent feature when discussing attractiveness. As an example, a broad male chin has been found to be associated with perceived desirability and dominance [2]. Vertical deficiency, or an excess of the chin, results in an imbalanced facial third, while horizontal deficiency or excess results in a poor facial profile. There is also some evidence to support osseous genioplasty as a way of treating obstructive sleep apnea, as it can reposition the genioglossus and potentially increase the airway space. The major treatment options for genioplasty include osseous genioplasty, alloplastic chin augmentation, and augmentation using soft-tissue fillers.

S. Halepas  
NewYork-Presbyterian/Columbia University Medical Center,  
New York, NY, USA  
e-mail: [sh3808@cumc.columbia.edu](mailto:sh3808@cumc.columbia.edu)

A. Koch (✉)  
Department of Oral and Maxillofacial Surgery, NewYork-Presbyterian/Columbia University Medical Center,  
New York, NY, USA  
e-mail: [ak2045@cumc.columbia.edu](mailto:ak2045@cumc.columbia.edu)

E. M. Ferneini  
Beau Visage Med Spa, Greater Waterbury OMS, Cheshire, CT, USA  
Division of Oral and Maxillofacial Surgery, University of Connecticut School of Dental Medicine, Farmington, CT, USA  
Department of Surgery, Frank H Netter MD School of Medicine, Quinnipiac University, Hamden, CT, USA

## Anatomy

The soft tissue borders of the chin are the labial mental fold superiorly, the oral commissures laterally, and the submental crease inferiorly. The bony portions of the chin include the mandibular symphyseal and parasymphyseal region inferior to the root apices. On the anterior surface of the symphysis are the depressor angularis, depressor labii inferioris, and mentalis muscles. The geniohyoid and genioglossus muscles attach to the lingual surface at the genial tubercle. The anterior bellies of the digastric muscles attach to the inferior border in the posterior aspect of the symphysis bilaterally.

There are many muscles of facial expression in this region. The risorius muscle arises from the lateral cheek and pulls the commissure laterally. The orbicularis oris muscle is the sphincteric muscle of the mouth. The depressor anguli oris arises laterally and inserts into the modiolus along with the orbicularis oris, risorius, and the levator anguli oris. The depressor anguli oris serves to depress the commissure and is the melomental folds or “marionette lines.” The depressor labii inferioris is medial to the depressor anguli oris and acts to depress and evert the lower lip. The mentalis muscle is a paired midline muscle deep to the other depressors and acts to elevate and protrude the lower lip. The platysma originates in the neck as a paired muscle that crosses the mandibular border and inserts into the dermis and subcutaneous tissues of the lower lip and chin.

The mental nerve is responsible for the sensory innervation to the skin overlying the chin, the lower lip, and the vestibular oral mucosa. The mental nerve is the terminal branch of the inferior alveolar nerve, as it exits the mental foramen usually between the first and second premolar, and the mental foramen is generally found about 13 mm above the inferior border [3, 4]. As the nerve exits the foramen, it turns superiorly and anterior and sometimes loops back posteriorly. The marginal mandibular branch and cervical branch of the facial nerve are responsible for the motor innervations of the muscles in the soft tissue of the chin.

There is a rich vascular supply to the face and the region of the chin. There are two major arteries to this area. The inferior alveolar artery which is a branch of the maxillary artery and the facial artery which is a branch of the external carotid artery. The inferior alveolar artery becomes the mental branch, as it exits with the nerve in the mental foramen. The mental branch then anastomoses with the submental and inferior labial arteries of the facial artery [5, 6].

## Preoperative Assessment

The chin is the inferior point of the face and is directly involved in providing appropriate facial symmetry; therefore, it is necessary to evaluate the chin in three dimensions to properly plan a genioplasty treatment. The chin and inferior border should be distinct and well demarcated from that of the neck. The chin width should be in harmony with the bizygomatic and bigonial facial widths.

As stated earlier, the vertical dimension of the face is very important for proper facial congruence. The hairline to the glabella should account for the superior third. The glabella to the subnasale should account for the middle third while subnasale to the menton should account for the lower third. The lower third can then be subdivided by the lips. The upper lip length should be about one-third, while the lower lip length should be about two-thirds.

When evaluating the sagittal plane, it is often necessary to incorporate both radiographic imaging and clinical evaluation of the facial profile. A lateral cephalometric radiograph can be useful in judging both the skeletal bony positioning as well as the overlying soft tissue. The Holdaway is used to compare the prominence of the lower incisors with that of the bony chin. Its principle states that the distance from the labial surface of the mandibular incisors to the N-B line (Nasion to B point Supramentale) and distance from the pogonion to the N-B line should be equal. It is useful in identifying the location of the chin prominence [7].

## Anesthesia

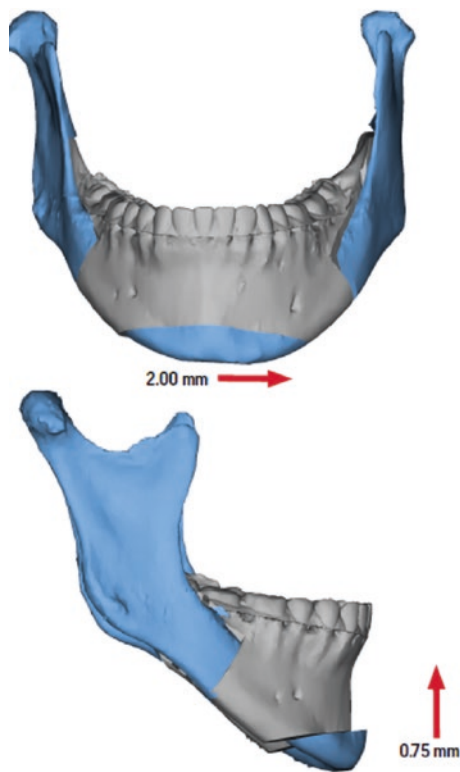
Genioplasty is often done in conjunction with orthognathic surgery or as part of other cosmetic procedures such as rhinoplasty or rhytidectomy [8]. In these circumstances, the patient is often under general anesthesia in an operating room setting. However, both osseous augmentation and alloplastic augmentation can be performed under local anesthesia with or without conscious sedation. Use of local anesthesia with a vasoconstrictor is recommended for anesthesia and hemostasis and to aid in postoperative pain control. Augmentation with soft tissue fillers can often be accomplished with just topical local anesthetics.

## Osseous Augmentation

The intraoral sliding osseous genioplasty was first described by Trauner and Obwegeser in 1957 and then again by Converse and Wood-Smith in 1964 [9, 10]. Originally, the osteotomies were stabilized with wires, but with the development of fixation screws/plates, the stability and predictability of the osseous genioplasty increased. Osseous genioplasty is an excellent surgical option, as it is stable in long term and can provide very pleasing aesthetic results [11].

After local anesthesia is achieved, the patient can be placed in maxillomandibular fixation with arch bars or maxillomandibular fixation screws. The lip is extended outward and the operator's fingers are placed on the cutaneous tissues. This allows the surgeon to feel the bony chin and prevent cutaneous perforation. A #15 blade or electrocautery is used to make an incision from canine to canine about halfway between the depth of the facial vestibule and the wet dry line or about 3–10 mm below the mucogingival junction. After the incision is made through the oral mucosa, it is important to incise the mentalis muscle at an oblique angle ensuring that a portion of the muscle is still attached to the periosteum to allow for proper closure. A #9 periosteal elevator can then be used to reflect the periosteum and dissect the symphysis to the inferior border of the mandible (See Fig. 22.2a). Using the #9 periosteal elevator, the mucosa and muscle superior to the incision that is just under the mucogingival junction ("the cuff") can be release to allow an easier closure. It is important to refrain from excessive dissection along the inferior border to maintain as much vascular supply to the osteotomy site. A well-vascularized pedicle is essential to prevent bony resorption and proper post-surgical healing. The surgeon must also be mindful of the mental nerve exiting the mental foramen on either side, typically at or around the first premolar. The mental nerve is at risk if the incision is extended too laterally, or during dissection along the inferior border. Reviewing imaging for mental nerve position can help reduce the risk of nerve injury. With these aids, the mental nerves should be identified to prevent injury [12].

Often, the chin position has been predicted using virtual surgical planning (see Fig. 22.1). When this technology is utilized, a genioplasty guide can be fabricated (see Fig. 22.2b) [13]. If virtual surgical planning with surgical guide fabrication was not utilized, a fissure bur can be used to mark the midline. The midline mark will allow the surgeon to achieve symmetry upon plating of the genioplasty. A pencil or marking pen can be used to draw the horizontal osteotomy. The osteotomy should be at least 5 mm below the root apices of the mandibular canines and 5–6 mm below the mental foramen if the nerve loops anteriorly or inferiorly to the foramen. In ideal circumstances, the osteotomy should be at least 12 mm from the inferior border, but this may not be possible



**Fig. 22.1** Virtual Surgical planning of a bilateral sagittal split osteotomy and genioplasty

depending the chin morphology, root apices, and mental foramen position.

A small down-turn Obwegeser retractor can be placed in the flap to protect the surrounding soft tissue [14]. The surgeon's non-dominant hand is placed in the submental region. A fissure bur or the reciprocating saw blade can be used to groove the osteotomy at the marked site. The notching can help the surgeon stay on the intended trajectory. The reciprocating saw is then placed at the intended osteotomy site and positioned at the inferior border as if it were extending posteriorly to the mandibular molar apices. This positioning prevents notching in the inferior border. The osteotomy is initiated posteriorly through both cortices of the inferior border, but as the saw is moved medially, the blade should be uprighted to a 90-degree angle at the midline. The surgeon's non-dominant hand should be able to palpate only the tip of the saw extraorally. The same osteotomy is then carried out on the contralateral side connecting at the midline. If the osteotomy is successfully completed, both cortices will have been cut and this will allow easy mobility of the bony segment. Ensuring that only the tip of the blade is beyond the cortex prevents excessive damage to the underlying musculature (See Fig. 22.2c).

With an advancement in sliding osteotomy, the bony segment can be advanced directly forward and good bone-to-bone contact can be achieved. If more complex movements

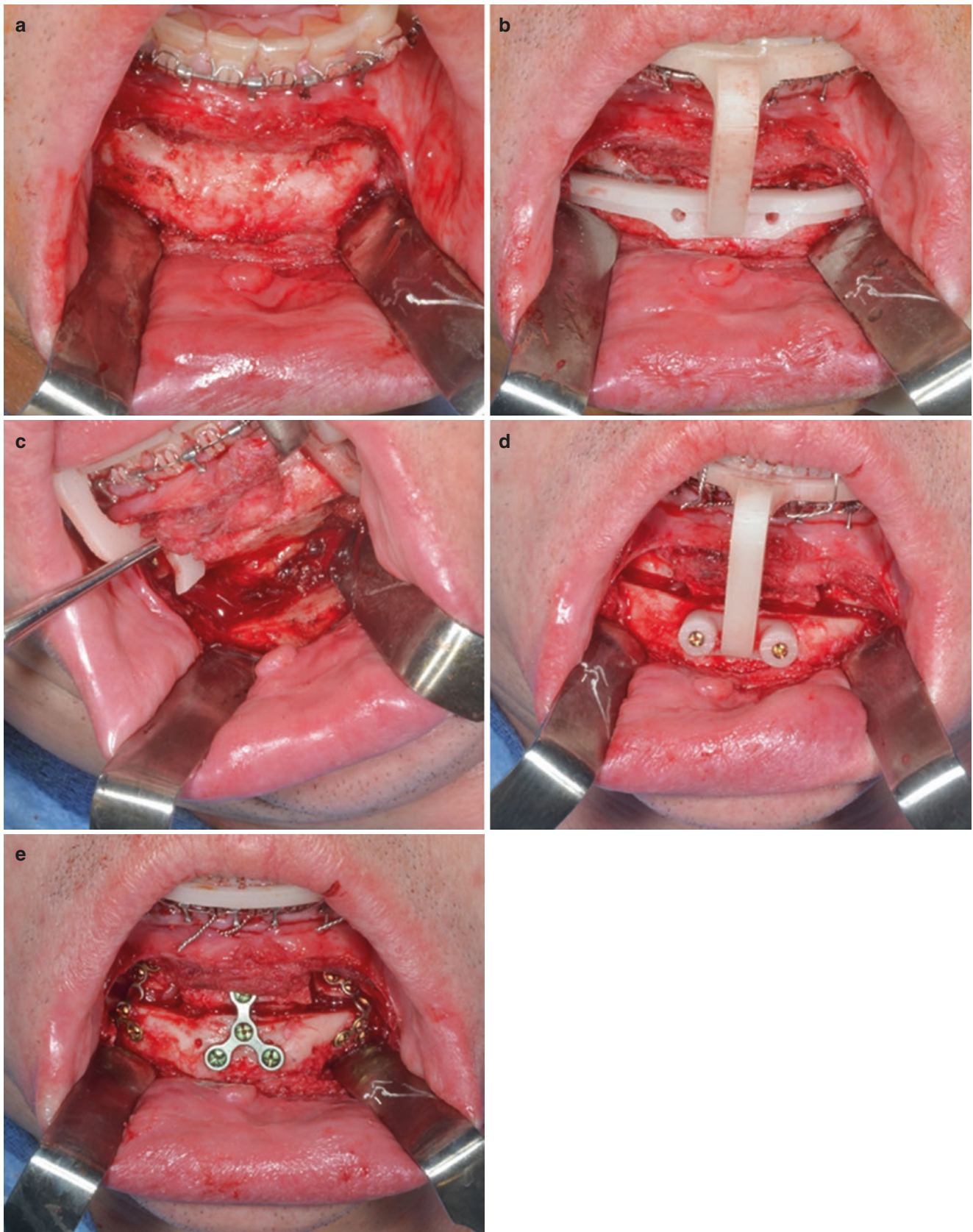
are planned, a surgical positioning guide will be pinned to the free bony segment (see Fig. 22.2d). Fixation plates can then be used to stabilize the free bony segment to the rest of the mandible and one can utilize 2.0 mm bicortical screws. The H-shaped plate is habitually employed at the midline for proper fixation and allow for visibility of the midline mark. Often, surgical positioning guide designs can prevent proper use of these H-plates, so utilization of other plates such as straight, T or L plates can be used with at least two holes on each side of the osteotomy (see Fig. 22.2e).

With the increased use of virtual surgical planning and technology, custom plates can be generated for more complex movements. If excessive gaps are noted, autogenous or allogeneic bone can be used. TruForm™ DBM putty by Stryker works well for these osseous gaps. If the chin is being moved inferiorly to increase vertical dimension, down grafting may be needed and larger gaps can be filled with a block graft. If the chin length is being reduced in a vertical dimension, two osteotomies must be completed. The second osteotomy is created superiorly on the mandible parallel to the original osteotomy but to the level of the desired bony reduction. This segment of bone can be removed, so the genial segment can be fixated to the mandible.

The surgical site should be copiously irrigated, and hemostasis should be achieved. The mentalis muscle is then resuspended using 3-O Polysorb sutures with either multiple single interrupted or horizontal mattress sutures. Failure to properly reapproximate the mentalis can result in chin ptosis and inadequate cosmetic outcomes. The mucosa is then closed with 3-O or 4-O chromic gut sutures often with a continuous running design. A surface pressure dressing is utilized to prevent edema and hematoma formation. The authors utilize 1/2 half inch Pink Hy-Tape placed where one piece is placed as an "A" and then one piece of tape overlapping as a "U". The pressure dressing is left in place for 48 hours [15, 16]. Postoperative films such as a panoramic radiograph can be helpful in evaluating the outcome (see Fig. 22.3).

Complications of osseous genioplasty often involve mild oozing, swelling, and infection or hematoma formation. If a large hematoma is noted in the floor of the mouth, it should be quickly addressed and drained to prevent airway embarrassment. The source of the bleeding must be identified and controlled. If needed, a drain can be placed and close monitoring is warranted. Bleeding can occur from the soft tissue/muscle, sinusoid and cancellous marrow, or from the lingual arteries or deep lingual veins. Floor-of-mouth hematomas are often small and self-limiting. For large expanding floor-of-the-mouth hematomas, the patient's airway must be secured via endotracheal intubation. An unfortunate adverse event is notching at the inferior border due to foreshortening of the osteotomy posteriorly leaving a greater defect in the inferior border. Due to the anatomical positioning risk to the

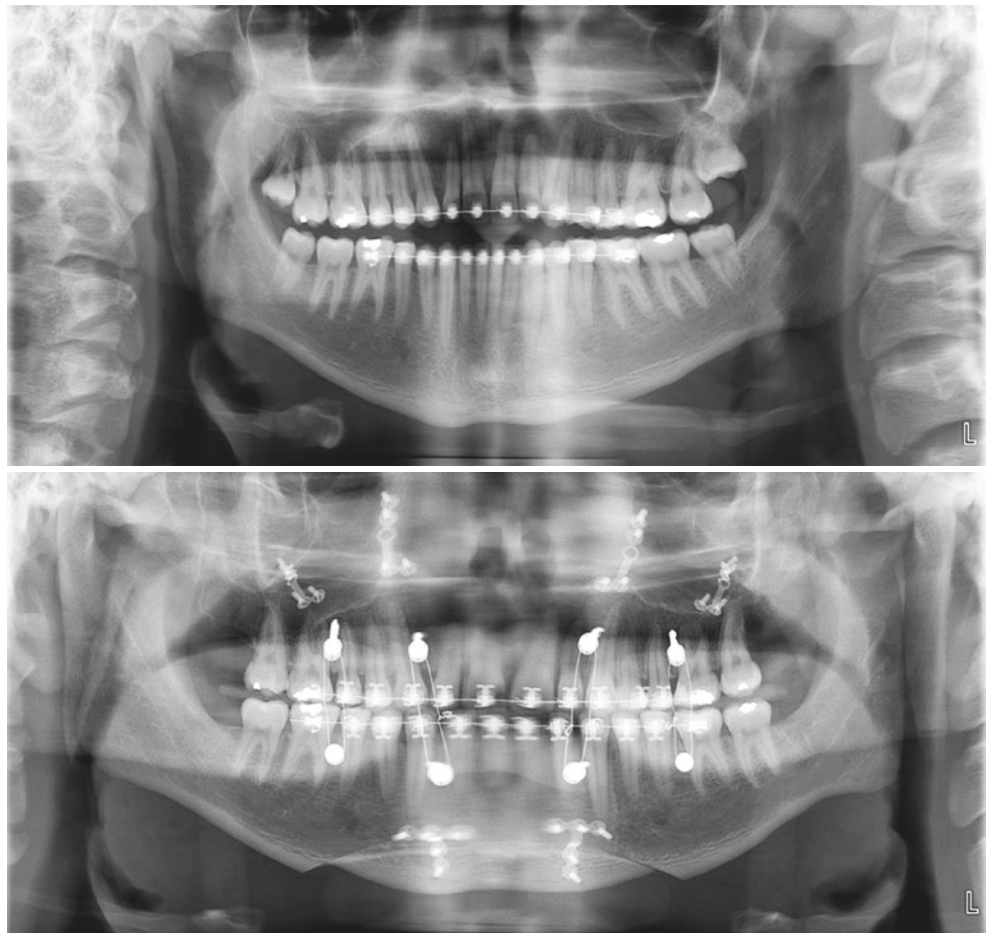




**Fig. 22.2** Intraoral incision with exposure of anterior mandible (a), placement of cutting guide (b), completion of osteotomy with sagittal saw (c), placement of positioning guide (d), final position with bone screws and plates (e)



**Fig. 22.3** Pre-op panoramic radiograph (top) and post-op radiograph following Lefort 1, IVRO and genioplasty (bottom)



mental nerve, altered levels of sensation are other potential complications [17].

### Alloplastic Augmentation

Alloplastic implants have increased in popularity in the last decade. Several biomaterials exist such as silicone, porous polyethylene, polytetrafluoroethylene, and hydroxyapatite. Currently, porous polyethylene marketed by the name of Medpor is one of the most popular biomaterials for facial implants. Alloplastic implants are limited to the correction of vertical or transverse deficiencies. These implants are advantageous because of the ease of placement, decreased surgical time, and their structural stability that allow for excellent facial fullness. Disadvantages occur because of sizing, as the implants generally come as only small, medium, or large. As with any implant, the risk of infection is more worrisome, given that the implants generally need to be removed if an infection develops. The risk of infection in the literature appears to be similar to that of osseous genioplasty. Medpor implants have larger pores in the range of 100–

300  $\mu\text{m}$ , which allow for macrophage infiltration and may aid in a decreased infection rate [18].

If alloplastic implants are completed with rhytidectomy or submental liposuction, an extraoral incision is ideal because it minimizes the risk of infection [19]. The midline of the chin should be marked for correct implant positioning. If an extraoral approach is being utilized without conjunction of other neck cosmetic procedures, a 2 cm incision is marked a few millimeters posterior to the submental crease. Local anesthesia is given at the incision site. A #15 blade is then utilized to make an incision through the skin and subcutaneous tissues. Electrocautery aids in maintaining local hemostasis as well as when incising the periosteum along the inferior border of the symphysis region just anterior to the insertion of the platysma. A #9 periosteal elevator is then used to gain subperiosteal access and reflect tissues along the facial aspect of the symphysis, while always being mindful of the mental nerves in both lateral directions. The dissection needs to be extended enough to allow passive seating of the alloplastic implant. Many brands come with sizers that can be placed to determine which size is most appropriate for the desired cosmetic result. The sizers and the alloplastic implant themselves can be reshaped using scissors to allow a more

pleasing result [20]. Once the appropriate implant has been selected and shaped, it is fixated to the mandible using two or three monocortical screws. Some providers prefer to soak the implant in an antibiotic solution prior to implant placement. Copious irrigation with normal saline or an antibiotic solution should be performed at the surgical site. The periosteum is repositioned with 3-O Polysorb, and a second 3-O Polysorb is then used for deep dermal suturing. A running subcutaneous suture can be utilized with 5-O BioSyn. Dermabond and or Steri-strips can be placed across the incision site. A pressure dressing utilizing tape in the shape of an “A” and overlapping “U” should be placed as described in the osseous augmentation section.

If an intraoral incision was preformed, the dissection is like that described in the osseous genioplasty. A large enough pocket should be created to allow passive seating of the alloplastic implant and closure should be completed as described in the intraoral osseous genioplasty [21].

Complications with alloplastic implants in the chin area can include ptosis or distortion of the soft tissue. There can also be resorption of the underlying bone over time [22]. There are different classifications for bone resorption under chin implants and there is believed to be an association with the implant size and future bone resorption likely due to the soft tissue stretch. The Robinson classification system is divided into three classes. Class I is any resorption up to a third of the added implant dimension or approximately 3 mm. Class II is resorption between a third and a half of the added implant dimension, or approximately 3–5 mm. Class III is more than 50% of the implant dimension or 5 mm [23]. It is believed that with the more diffuse pressure distribution of the extended chin implant design, the bony resorption is less prevalent [24]. Implants have a unique problem compared to that of osseous genioplasty, in that there is risk of implant mobility or migration [25]. Reports have stated infection rates of 5–7% for chin implants [26]. Although the risk of infection is not necessarily greater, it is more worrisome because treatment generally involves removal of the prosthesis.

## Soft Tissue Filler Augmentation

Chin augmentation with facial fillers is a minimally invasive alternative to osseous or alloplastic genioplasty. For chin augmentation with soft tissue fillers, the provider can use Calcium Hydroxyapatite (CaHA, Radiesse®), Poly-L-Lactic Acid (PLLA, Sculptra®), or Hyaluronic Acid (HA, JUVÉDERM®). The injection sites on the skin should be marked first if the provider is to use local anesthetic, as the

infiltration can cause distortion of the soft tissues. The mental foramen must be identified and injections of filler should be at least 1 cm away [27] to avoid nerve damage and potential vascular compression. When using local anesthesia with facial fillers, the authors recommend to avoid the use of vasoconstrictive agents that can mask early signs of avascular necrosis [28]. The provider should use at least a 25-gauge needle to ensure ability to properly aspirate. Whenever possible, a microcannula should be used to prevent excessive bruising and limit potential intravascular injections. Although a rare complication, vascular compromise can be quite devastating. Due to the increased amount of facial filler likely required in chin augmentation, it is vital that the practitioner remains mindful of the anatomy and corresponding vascular supply [29]. A case report of vascular compromise to the tongue has been reported in the literature after chin augmentation with HA [30]. Slow injection speeds with small boluses can decrease postoperative pain and swelling [31–33]. Injecting slowly allows for the soft tissue to stretch and can prevent local tissue damage that results in excessive edema. Small bolus size allows for more homogenous spread of the dermal filler and again allows time for the local tissue to stretch. Small amounts also limit the potential for vascular compression.

The injections should begin in the prejowl sulcus and should extend medially to the mentalis muscle. It is important to do serial puncture injections with small filler deposits. The filler should be placed in the deep submuscular layer using a retrograde filling technique, depositing as the needle is withdrawn. Using small deposits and constant massaging of the area, the provider should be able to facilitate proper distribution and prevent nodular formation.

Calcium hydroxyapatite is an excellent agent to increase the volume of the jawline or augmentation of the prejowl sulcus. In the chin, it is best to use linear threading/cross-hatching technique. Poly-L-Lactic Acid (PLLA) is a biodegradable synthetic polymer that stimulates collagen production and is the principal component in Sculptra®. PLLA can provide long-lasting effects with the duration of Sculptra® reported up to 3 years. PLLA is also a great option for increased jawline definition or correction of dimples.

The technique is slightly different if HA is the filler chosen. It is best to use a layering technique just above the periosteum if the goal is correction of volume loss. If the aim is to correct wrinkles, it should be delivered subcutaneously [27, 34]. Soft tissue projection advances of 3 mm using HA in for genioplasty have been described in the literature [35].

Augmentation with soft tissue fillers can often be done in conjunction with submental liposuction to provide a more

defined jawline. An alternative is the use of deoxycholic acid (Kybella®) to decrease submental fat with a noninvasive approach. Kybella is injected supraplatysmally and aids in the breakdown of fat. Treatment with Kybella injections is typically done at least one month apart, and it usually requires 3–4 treatments to see adequate results [36].

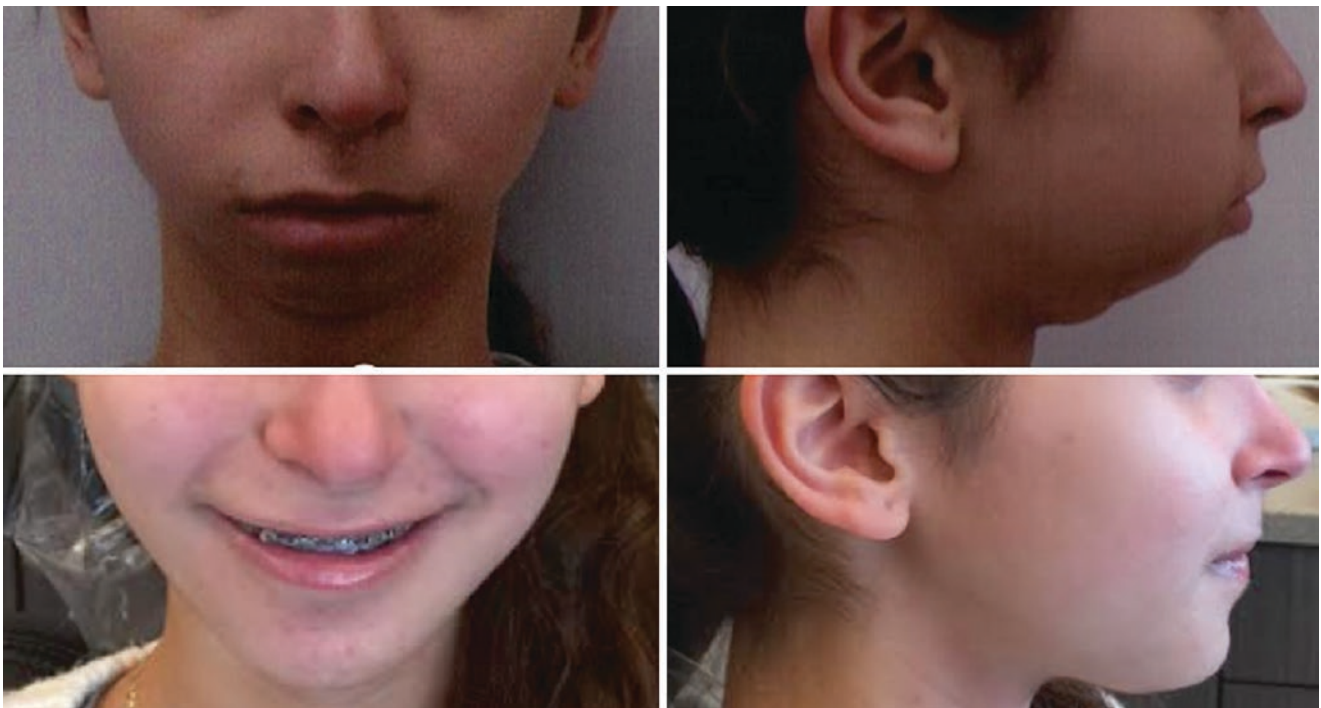### Postoperative Management

Antibiotic prophylaxis may be warranted if bone grafting or alloplastic implants were placed. Typically, with intraoral osseous genioplasty and soft tissue filler augmentation, postoperative antibiotics are not necessary. A single perioperative dose of cefazolin or ampicillin is given for osseous genioplasty. Generally, with osseous and alloplastic augmentation, a course of steroids, either dexamethasone, if the patient is admitted, or a Medrol Dose Pak, if in the outpatient setting is prescribed to decrease postoperative swelling. Postoperative pain medication is generally necessary, and the utilization of scheduled NSAIDs and acetaminophen will

minimize the need for narcotics while maintaining adequate pain control [37]. Continued follow-up with the patient is routine.

### Conclusion

Genioplasty is a safe and effective way to correct facial profile and change the lower third of the face. A genioplasty can substantially improve a patient's overall esthetics and confidence (Fig. 22.4). Genioplasty can be performed through traditional osseous augmentation, alloplastic augmentation, or using soft tissue fillers. Osseous augmentation is the most utilized likely due to its use in combination with orthognathic surgery. Alloplastic augmentation is a smaller surgery with decreased recovery time that can provide exceptional results. Soft tissue filler augmentation, although temporary, can be a minimally invasive and reversible alternative that patients may prefer. With all three methods, knowledge of facial anatomy is the key behind successful cosmetic results.



**Fig. 22.4** Pre- and postoperative clinical photos of an 18-year-old female following a Lefort 1, inverted “L” osteotomy and genioplasty. Take note of the dramatic enhancement of facial harmony utilizing a mandibular and genio advancement



## References

- Rhodes G, Yoshikawa S, Clark A, Lee K, McKay R, Akamatsu S. Attractiveness of facial averageness and symmetry in non-western cultures: in search of biologically based standards of beauty. *Perception*. 2001;30(5):611–25.
- Grammer K, Fink B, Møller AP, Thornhill R. Darwinian aesthetics: sexual selection and the biology of beauty. *Biol Rev Camb Philos Soc*. 2003;78(3):385–407.
- Laher AE, Wells M, Motara F, Kramer E, Moolla M, Mahomed Z. Finding the mental foramen. *Surg Radiol Anat*. 2016;38(4):469–76.
- Sheikhi M, Kheir MK. CBCT assessment of mental foramen position relative to anatomical landmarks. *Int J Dent*. 2016;2016:5821048.
- Lustig JP, London D, Dor BL, Yanko R. Ultrasound identification and quantitative measurement of blood supply to the anterior part of the mandible. *Oral Surg Oral Med Oral Pathol Oral Radiol Endod*. 2003;96(5):625–9.
- Direk F, Uysal II, Kivrak AS, Fazliogullari Z, Unver Dogan N, Karabulut AK. Mental foramen and lingual vascular canals of mandible on MDCT images: anatomical study and review of the literature. *Anat Sci Int*. 2018;93(2):244–53.
- Alfi D, Gateno J. Chapter 5: orthognathic surgery. In: Lam D, Laskin D, editors. *Oral & maxillofacial surgery review*. Hanover Park: Quintessence Publishing Co; 2019.
- Sykes JM, Suárez GA. Chin advancement, augmentation, and reduction as adjuncts to rhinoplasty. *Clin Plast Surg*. 2016;43(1):295–306.
- Trauner R, Obwegeser H. The surgical correction of mandibular prognathism and retrognathia with consideration of genioplasty. I. Surgical procedures to correct mandibular prognathism and reshaping of the chin. *Oral Surg Oral Med Oral Pathol*. 1957;10(7):677–89.
- Converse J, Wood-Smith D. Horizontal osteotomy of the mandible. *Plast Reconstr Surg*. 1964;34:464–71.
- Kumar BL, Raju GK, Kumar ND, Reddy GV, Naik BR, Achary CR. Long term stability following genioplasty: a cephalometric study. *J Int Oral Health*. 2015;7(4):44–50.
- Ferretti C, Reyneke JP. Genioplasty. *Atlas Oral Maxillofac Surg Clin North Am*. 2016;24(1):79–85.
- Li B, Wei H, Zeng F, Li J, Xia JJ, Wang X. Application of a novel three-dimensional printing genioplasty template system and its clinical validation: a control study. *Sci Rep*. 2017;7(1):5431.
- Zhao M, Wu G. The appropriate retractors for Genioplasty. *J Craniofac Surg*. 2017;28(1):252–3.
- Chen X, Koch A. Genioplasty. In: Ferneini E, Goupil M, editors. *Office based maxillofacial surgical procedures – a step-by-step approach*. Cham: Springer; 2019.
- Caloss R. Chapter 29: genioplasty. In: Kademani D, Tiwana P, editors. *Atlas of oral & maxillofacial surgery*. St. Louis: Elsevier; 2016.
- Sood A, Caldemeyer C, Ferneini E. Complications of genioplasty. In: Ferneini E, Castiglioni C, Banki M, editors. *Complication in maxillofacial cosmetic surgery*. Cham: Springer; 2017.
- Ferneini E, Halepas S. Antibiotic prophylaxis in facial implant surgery: review of the current literature. *Conn Med*. 2018;82(10):693–597.
- Schwartz D, Quereshy FA. Combined rhytidectomy and alloplastic facial implants. *Atlas Oral Maxillofac Surg Clin North Am*. 2014;22(1):69–73.
- Lee EI. Aesthetic alteration of the chin. *Semin Plast Surg*. 2013;27(3):155–60.
- Gui L, Huang L, Zhang Z. Genioplasty and chin augmentation with Medpore implants: a report of 650 cases. *Aesthet Plast Surg*. 2008;32(2):220–6.
- Polo M. Bone resorption under chin implants: the orthodontist's role in its diagnosis and management. *Am J Orthod Dentofac Orthop*. 2017;151(1):201–8.
- Robinson M. Bone resorption under plastic chin implants: follow-up of a preliminary report. *Arch Otolaryngol*. 1972;95(1):30–2.
- Reed EH, Smith RG. Genioplasty: a case for alloplastic chin augmentation. *J Oral Maxillofac Surg*. 2000;58(7):788–93.
- Park JY, Kim SG, Baik SM, Kim SY. Comparison of genioplasty using Medpor and osteotomy. *Oral Surg Oral Med Oral Pathol Oral Radiol Endod*. 2010;109(2):e26–30.
- Richard O, Ferrara JJ, Cheynet F, Guyot L, Thiery G, Blanc JL. Complications of genioplasty. *Rev Stomatol Chir Maxillofac*. 2001;102(1):34–9.
- Ferneini E, Jackson T, Ferneini C, Banki M. A review of new facial filler techniques for facial rejuvenation. *Am J Cosmet Surg*. 2014;31(4):166–73.
- Ferneini EM, Halepas S, Watras J, Ferneini AM, Weyman D, Fewins J. Surgeon's guide to facial soft tissue filler injections: relevant anatomy and safety considerations. *J Oral Maxillofac Surg*. 2017;75(12):2667.e2661–5.
- Tansatit T, Phumyoo T, Jitaree B, Sawatwong W, Sahraoui YME. Investigation of the presence and variation of the ascending mental artery: conventional dissections and ultrasonographic study. *J Cosmet Dermatol*. 2019;18(6):1821–9.
- Wang Q, Zhao Y, Li H, Li P, Wang J. Vascular complications after chin augmentation using hyaluronic acid. *Aesthet Plast Surg*. 2018;42(2):553–9.
- Heydenrych I, Kapoor KM, De Boule K, et al. A 10-point plan for avoiding hyaluronic acid dermal filler-related complications during facial aesthetic procedures and algorithms for management. *Clin Cosmet Investig Dermatol*. 2018;11:603–11.
- Ferneini EM, Ferneini AM. An overview of vascular adverse events associated with facial soft tissue fillers: recognition, prevention, and treatment. *J Oral Maxillofac Surg*. 2016;74(8):1630–6.
- Ferneini E, Gady J, Nuveen E. Complications associated with facial soft-tissue fillers. *Am J Cosmet Surg*. 2014;31(4):238–42.
- Boulos M, Halepas S. Chapter 6 facial fillers. In: Ferneini E, Goupil M, editors. *Office based maxillofacial surgical procedures- a step-by-step approach*. 1st ed. Cham: Springer; 2019.
- Bertossi D, Lanaro L, Dell'Acqua I, Albanese M, Malchiodi L, Nocini PF. Injectable profiloplasty: forehead, nose, lips, and chin filler treatment. *J Cosmet Dermatol*. 2019;18(4):976–84.
- Halepas S, Weyman D, Ferneini EM. Complications in minimally invasive facial cosmetic surgery. *J Oral Maxillofac Surg*. 2018;76(10):e44–5.
- Sarkar S, Baliga M, Chakraborty S, Tusharbhay DM. Re: postoperative pain and opioid analgesic requirements after orthognathic surgery. *J Oral Maxillofac Surg*. 2019;77(4):673–4.



## Introduction

The most common reason a patient seeks rejuvenation of the face is the undesirable cosmetic appearance of the neck/jaw-line region. The objective and subjective concerns and findings upon examination indicate the anatomical causes that are underlying the concerns. Fundamental to proper examination, diagnosis, treatment planning, and performance of any surgical intervention is knowledge of the regional anatomy. As cosmetic surgeons of the maxillofacial region, a patient-centered focus of maximizing safety and providing ideal patient satisfaction begins and ends with anatomical awareness.

## Anatomical Considerations

Although arbitrary, we choose to define the anatomical region of the neck with its superior boundary as 1.0 cm above the inferior border of the mandible. The inferior border is demarcated by the clavicles and sternum. The neck region has been further defined into anterior and posterior compartments separated by the sternocleidomastoid muscle. The anterior compartment is bordered by the mandible superiorly, the SCM muscle posteriorly, and the midline anteriorly (Fig. 23.1). The hyoid bone divides the anterior compartment of the neck into the suprahyoid and infrahyoid spaces. The suprahyoid neck is divided into the submental and submandibular spaces by the anterior belly of the digastric muscle and the superior belly of the omohyoid muscle. These muscle groups are defined by anterior and posterior triangles (Fig. 23.2). The innervation and venous supply to the region is remarkable, consistent, and provides predictable knowl-

edge for dissection with minimal aberrancy (Fig. 23.3). The posterior compartment of the neck is divided by the inferior belly of the omohyoid muscle (Fig. 23.4) [1].

The ideal cervicomenal angle has been reported to be 105–120° [5]. The visualized cervicomenal angle is established by the underlying anatomical structures. In patients with an obtuse chin-throat angle (cervicomenal angle), the physical examination will often reveal the origin of the undesirable neck contour and aid in proper surgical treatment planning. During consultation, careful attention during conversation and gesture may reveal adipose location and depth, submandibular ptosis and prominence, digastric triangle visibility, hyoid position, and base of tongue mobility on swallowing and speech. The Dedo Classification system lends objective data to a subjective problem and could be used to stratify patients along a continuum of procedure offerings [6].

The neck region consists of anatomical layers and predictable structures with infrequent aberrancies. The skin layer is of various thicknesses. Variable thickness may be attributable to genetic variation, gender differences, hormonal influence, hair bearing follicular density, adnexal structure density, influence of medications, and cosmeceuticals the patient may be using or have used. Generally, the skin of the submental region is 1.6–5.0 mm [7, 8] in thickness and has a robust collateral random pattern of arterial inflow and venous plexus for pressure-dependent outflow. As a result, the skin of the neck is highly forgiving of traumatic injury and recovers rapidly from elective surgical intervention.

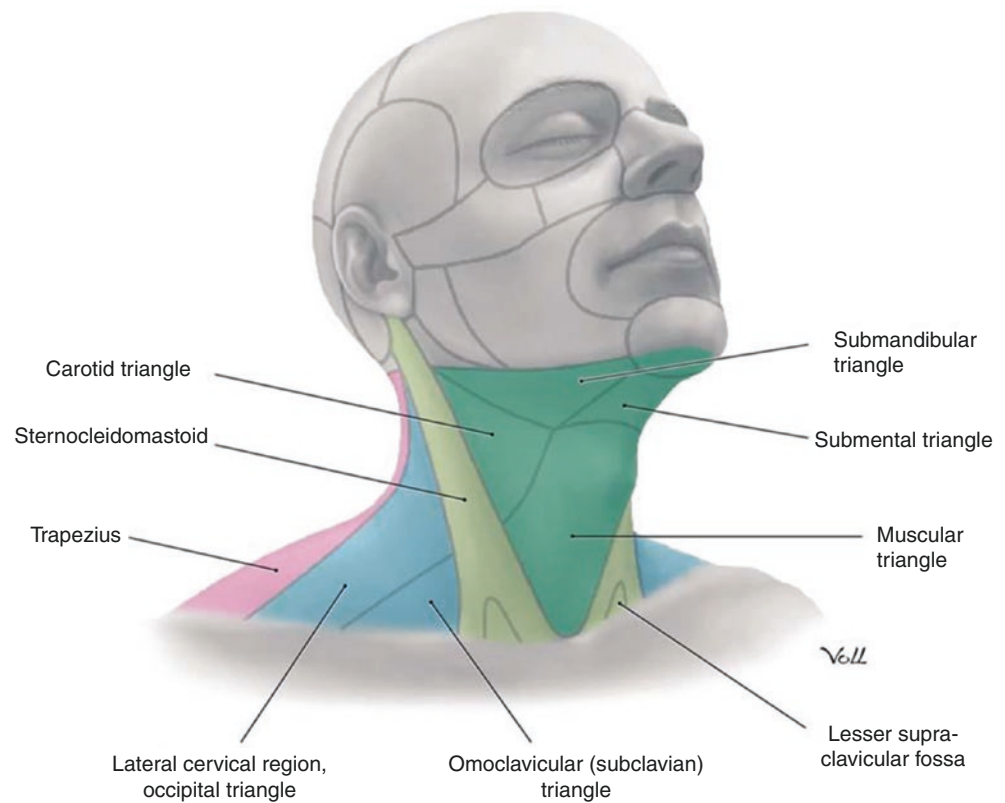
## Treatment Considerations

Planning of surgical exposure of the neck region should involve knowledge of the Relaxed Skin Tension Lines (RSTL) of the region [9]. Planned incisional access should be made either in these lines or parallel to these lines in order

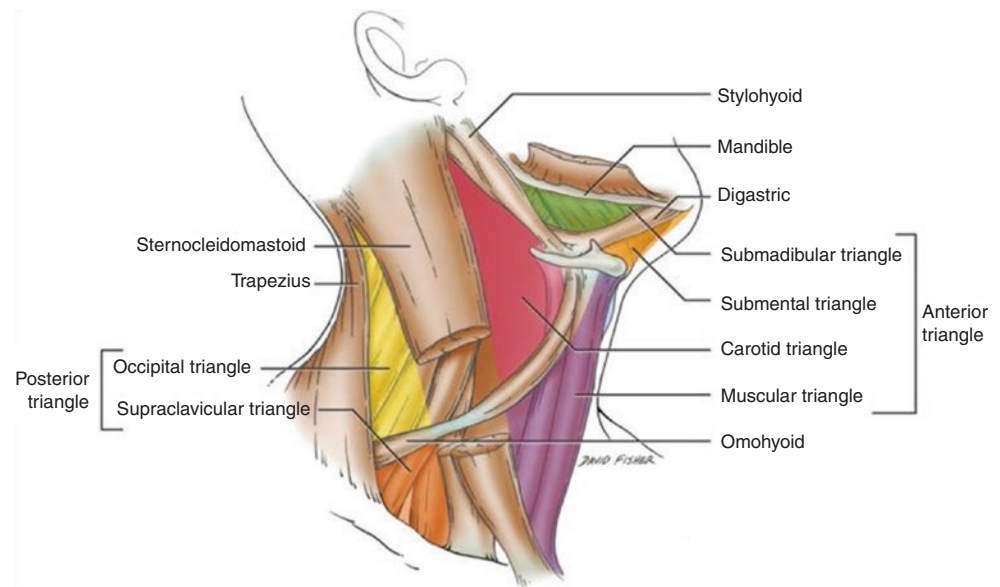
---

E. J. Nuveen (✉)  
Department of Oral and Maxillofacial Surgery, The University of  
Oklahoma Health Science Center, The University of Oklahoma  
College of Dentistry, Cosmetic Surgery Affiliates,  
Oklahoma, OK, USA

**Fig. 23.1** Esthetic units of the neck [1] (Thieme publishing, 2006)



**Fig. 23.2** Schematic drawing of the triangles of the neck [2]



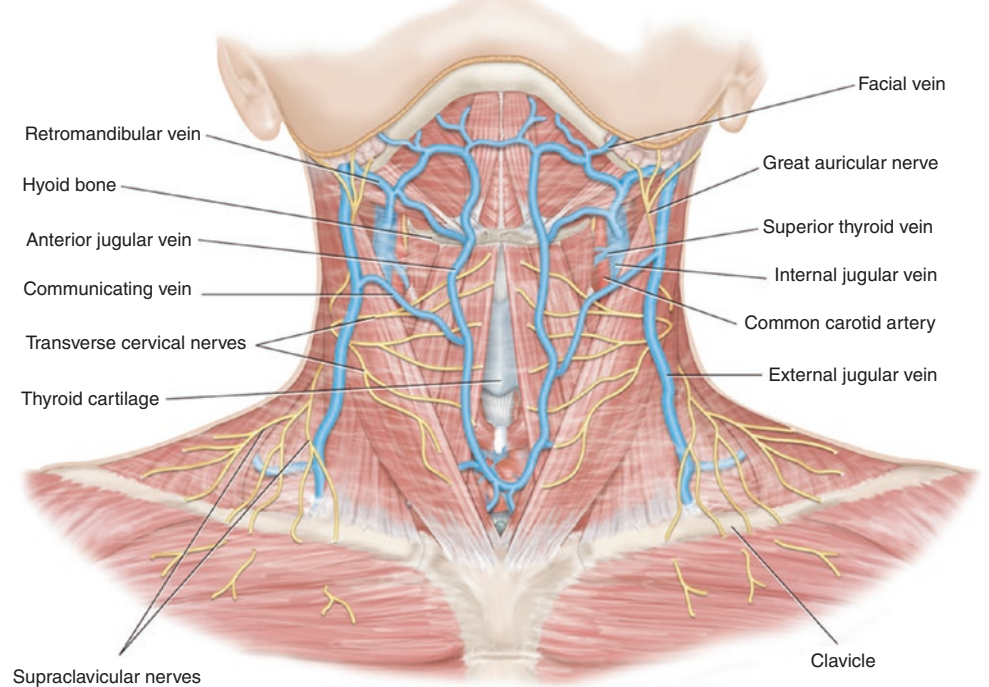
to minimize tension and to aid in visual camouflage of the final scar. In the region of the neck, the most common choice for access to the underlying structures of the neck is either submental or postauricular. Direct access is reasonable in some cases along lines of previous incision or traumatic scars when present. The post-surgical incision lines should reduce risk of contracture, webbing, or hypertrophy when properly planned and executed. Inherent genetic and hor-

monal factors influence the likelihood of hypertrophic or keloid scarring. The probability of occurrence varies widely and should be discussed with all patients choosing to undergo elective surgical incisions.

Skin quality is an extremely important determinant of the proper technique to employ for ideal neck contour. Age, massive weight loss, genetic propensity, extrinsic factors such as exposures or medications may contribute to loss of

**Fig. 23.3** Veins and Nerves of the Neck [3]

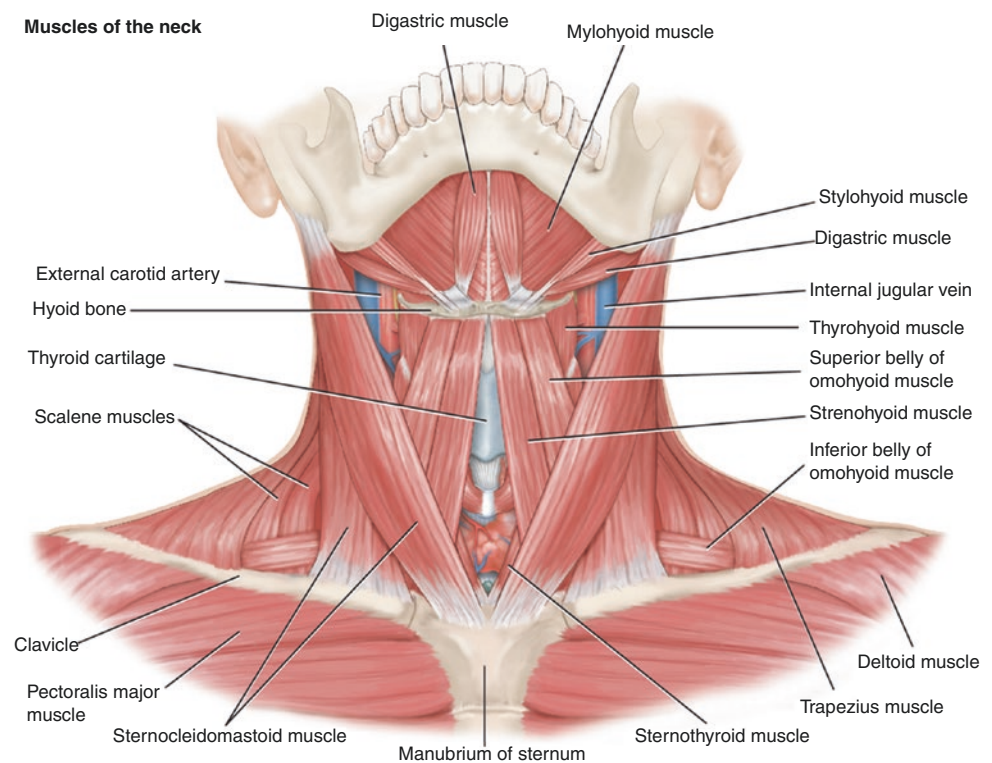
#### Veins and nerves of the neck



© 2010 Encyclopædia Britannica, Inc.

**Fig. 23.4** Muscles of the Neck [4]

#### Muscles of the neck



©2015 Encyclopædia Britannica, Inc.

elasticity of the neck region. As a result, individually customized treatment plans must be made to manage skin excess or laxity after subcutaneous reduction procedures of all types. The post auricular incisions should be initiated in the

post auricular crease and extend from the lobule to the level of the antihelical fold. Complete undermining of the skin from the mastoid region to approximately 1.0 cm above the clavicle will allow mobilization and rotational advancement

sufficient to prevent visible heaping of tissues over the sternocleidomastoid muscle. Meticulous attention to hemostasis is a must with such large potential space and high vascularity. A wide range of hematoma occurrence has been quoted at 0.13–10% with rhytidectomy procedures of the past [10], and this rate may be substantially reduced with epinephrine and tranexamic acid [11].

The next layer of tissue encountered in this region is the subcutaneous fat layer. This layer is less vascular than the subdermal plexus above and is divided into a superficial and deep layer by the superficial fascial system. This fascia is named in various regions of the body but is contiguous throughout and of variable density. On physical examination, when a person makes effort to tighten the platysma muscle below, the fat in this layer is identified as not moving or being compressed by the muscle contracture. This layer is accessible with low risk to nervous and vascular structures immediately below the subdermal plexus. Either direct excision or lipoaspiration of this fatty layer may alone be sufficient to create a satisfied and safe improvement toward a more ideal cosmetic appearance of the submental region. A deep or subplatysmal fat layer may be present, most commonly centrally but may occur laterally as well. This layer can be addressed either direction at the time of platysma elevation from a medial to lateral approach from the midline dissection or with lipoaspiration alone. As the depth of surgical intervention increases, approximation to the marginal mandibular branch of cranial nerve VII increases [12]. In addition, the rate of lymphatic injury also increases. Precision and vigilance must be maintained in deeper surgical management.

Actual volumes of fat available and appropriate for removal are extremely variable. In some cases, 350 cc may be removed. In others, 3.0–10.0cc may be appropriate and effective in achieving the desired outcome of improvement. In larger cases, bulk removal will result in improved contour. In smaller cases, the effect of introducing tumescent solution, traumatic tunneling, and minimal aspiration may result in an outcome of high patient satisfaction as a result of dermal and subdermal contracture alone. In both cases, the surgical removal of tissue will result in increased exposure of the underlying structure. This could result in improved appearance or exposure of underlying anatomical deficiencies or abnormalities, thus the necessity of a complete knowledge of the anatomy of the region and a thorough preoperative examination.

In ideal cases of skin elasticity, a 2.0 mm stab incision with a #11 blade immediately posterior to the submental crease provides sufficient access for supraplatysmal lipoaspiration while minimizing stigma of surgical intervention.

If a patient has a posterior airway and posterior hyoid position, the typical high-yield procedure is platysmaplasty combined with subcutaneous liposculpture. A 2.5–3.0 cm

submental incision is placed with a #15 blade approximately 1.0 mm posterior to the submental crease. Subcutaneous dissection is achieved with facelift scissors. Lipoaspiration is performed with a 5.0 mm spatula open liposuction cannula to the level of the superficial fascia of the platysma muscle. Variable decussations occur in the central region of the neck and may form the basis of the platysmal surgery to correct it [13].

Once the submental fat is fully removed, supra and subplatysma, the medial border of the platysma muscle will be evident from the submental incision with the aid of a sweetheart retractor with headlight. Grasp the medial border of the platysma and dissect with either electrocautery (on low settings) or facelift scissors. This plane of dissection is well established and easy to divide while elevating the muscle. If performing a midline plication, begin at the level of the hyoid bone. Using a 4-0 PDS suture, engage the periosteum of the hyoid bone and ensure medial mobilization of the borders of the platysma without distortion. Typically, this is associated with a 3.0–5.0 cm transaction of the platysma bilaterally at the level of the hyoid, to ease mobilization and more clearly define the cervicomental angle. A running locking suture technique is used to run anteriorly to the mental crease and back again, posteriorly to the hyoid where the suture is tied to the original tail at its origin.

The posterior border of the platysma muscle is plicated with 2-0 PDS suture to the dense tissues found in the mastoid region in one or more locations after subplatysmal dissection with facelift scissors under direct visualization. Care is taken to preserve the greater auricular nerve as it crosses the sternocleidomastoid muscle at Erb's point. Purposeful denervation of the cervical branches of the facial nerve is then performed while incising the cervical retaining ligaments. This improves mobilization and increases longevity of the neck lift procedure [14–16]. The length of the post auricular incision is dependent upon on the laxity of skin and the ability to rotationally advance the skin overlying the advanced platysma. The most common choices are either extension into the hairline or pretrichial. Realignment of the hairline with closure is indicative to all onlookers of attention to detail.

Excluding extreme skin laxity and superficial and deep adiposity, the primary determinants of the ideal neck contour is the mentum and the hyoid position. A supportive mentum or most projected chin prominence adds visual length and grace to the jawline. Insufficient support or projection “weakens” and limits definition of the region. All patients must undergo an evaluation of dental occlusion and basal bony position. This may reveal a class II dental position with mandibular hypoplasia and would be an indication for mandibular advancement surgery. Patients with a Class I occlusion and microgenia may elect for genioplasty or chin implant placement for increased projection towards ideal (See Chap. 21). Genioplasty is preferential when the desired



goal is to modify vertical height and width with length of the mentum, but has an associated longer recovery and increased complications as compared to alloplastic implantation alone.

In patients with massive weight loss and extreme laxity of tissues, my preference is to fully resect the platysma muscle bilaterally. This allows access to the subplatysmal fat and further allows skin redraping to define the cervicomenta angle. A electrocautery is used to incise completely through the platysma muscle 1.0 cm below the inferior mandibular border. Complete resection is mandatory if initiated. Incomplete resection will result in posterior neck banding and will likely increase chances of a requested revision surgery to correct.

Taken as a single element, the hyoid bone and its muscular attachments are the single most important anatomical structures contributing to neck contour. The more superior and posterior the hyoid bone, the more acute and more attractive the neck contour. An obtuse cervicomenta angle is most commonly associated with an inferiorly, anteriorly positioned hyoid. The position of the hyoid is a result of its muscular attachments, the base of the tongue, and the airway position. Selective release of attachments results in unopposed unilateral directional change to the hyoid position. The anterior digastric muscles pulls the hyoid anteriorly. The omohyoid, sternohyoid, and thyrohyoid muscles pull the hyoid inferiorly. The release or removal of these muscles allows unopposed superior and posterior repositioning of the hyoid bone, resulting in the maximum modification in the cervicomenta angle that is possible.

Myotomy or muscle release of the hyoid results in only the trachea and base of tongue as inhibitions to ideal cervicomenta angle and neck contour. In the past this was discussed and the hyoid and its position were identified as limiting factors in the ability of a surgeon to improve neck contour [17]. Reduction neck lift (2016) was introduced in a series of excellent publications in *The Clinics of Plastic Surgery* [18]. This text and its authors ushered in a new era of possible modification of the cervicomenta angle associated with the “difficult or problem neck” [19].

Direct visual inspection of the submandibular glands, lymph nodes and anterior digastric muscle must be performed once the platysma is resected. The digastric muscle is divided into anterior and posterior portions, triangulating the contents of submandibular triangle [2]. This muscle functions to assist in swallowing and elevation and position of the hyoid bone. If this muscle is prominent or removal of the overlying platysma reveals its prominence, the anterior belly of the digastric muscle can be removed without untoward consequences. This results in an unopposed posterior and superior vector of force on the hyoid bone of the remaining posterior belly of the digastric. A more deep and posterior

cervicomenta angle results. Close visual inspection of the superficial lobe of the submandibular gland may reveal its prominence and need for resection. Using a blunt curved or right angle clamp, a blunt dissection is made through the superficial capsule of the gland, immediately posterior to the neurovascular bundle. Electrocautery is used to excise the portion of the gland that herniates with gravity alone. This is a highly vascular structure and requires complete hemostasis prior to closure of the capsule. Due to resection of the platysma and overlying fat, there is an increased rate of sialoceole. Immediate use of chemical paralysis should be considered at this time.

---

## Perioperative Considerations

All patients are evaluated for consideration of pre-operative use of Clonidine (0.2 mg/d transdermal patch) [20]. The synergistic effect of clonidine reduces the need for intraoperative pain and anxiety medications, reduces hypertension, intraoperative bleeding, postoperative hematoma rates, and has very minimal effect on the normotensive or hypotensive patient [21, 22]. This procedure can be performed either under local anesthesia alone, oral sedation, inhalation of nitrous oxide, intravenous sedation, or general anesthesia. Tumescence anesthesia (500 mg Lidocaine, 0.5cc of 1:1000 Epinephrine in 500cc 0.9% Saline solution) volumes of 100–350cc are introduced with a 22-G spinal needle or blunt infusion cannula into the subcutaneous plane and allowed 7–30 minutes for hemostasis and anesthesia prior to performing any surgical intervention. At this same time, if intravenous access is utilized, an infusion of tranexamic acid (1.0 gm TXA in 50cc 0.9% saline intraoperative and 4 hours postoperatively) is performed for 10–20 minutes. This intravenous antifibrinolytic inhibits the conversion of plasminogen to plasmin and results in reductions in ecchymosis, edema, and hematoma rates in facelift patients [23, 24]. High concentration local anesthesia (1:200,000 Epi and 2% lidocaine) of 1–3 cc is used at incision sites to minimize bleeding. Access is created with a #15 surgical blade 1–3.0 mm posterior to the sub mental crease and an infralobular stab incision is created using a #11 blade, through skin to the subcutaneous plane. A 2–3 mm aspiration cannula is then utilized to create tunnels in a fan-like pattern from these points of access. If the cannula is unilateral, the aspiration ports should be directed downward, away from the underlying subdermal plexus. Attention should be made in retaining a 3–5.0 mm layer of fat on the overlying dermis in order to minimize contour irregularities and to minimize excessive and variable fibrosis that occurs with dermal injury.

## References

- Schuenke M, Schulte E, Schumacher U. Consulting editors: MacPherson BR, Stefan C. New York, Stuttgart, Delhi, Rio de Janeiro: Thieme Medical Publishers; 2016. ISBN 978-1-62623-120-7.
- Kikuta S, Iwanaga J, Kusakawa J, Tubbs RS. Triangles of the neck: a review with clinical/surgical applications. *Anat Cell Biol*. 2019;52(2):120–7.
- Augustan A, et al. Anatomy and physiology: neck anatomy. 2010. Retrieved from <http://britannica.com>.
- Rogers K. Anatomy and physiology: neck anatomy. 2015. Retrieved from <http://britannica.com>.
- Michelow B, Guyuron B. The Chin: skeletal and soft-tissue components. *Plast Reconstr Surg*. 1995;95(3):473–8.
- Dedo D. “How I do it”—plastic surgery. Practical suggestions on facial plastic surgery. A preoperative classification of the neck for Cervicofacial Rhytidectomy. *Laryngoscope*. 1980;90(11 Pt 1):1894–6.
- Chopra K, Calva D, Sosin M, Tadisina K, Banda A, De La Cruz C, Chaudhry M, Legesse T, Drachenberg C, Manson P, Christy M. A comprehensive examination of topographic thickness of skin in the human face. *Aesth Surg J*. 2015;35(8):1007–13.
- Ha RY, Nojima K, Adams WP Jr, Brown SA. Analysis of facial skin thickness: defining the relative thickness index. *Plast Reconstr Surg*. 2005;115(6):1769–73.
- Borges AF. Relaxed skin tension lines (RSTL) versus other skin lines. *Plast Reconstr Surg*. 1984;73(1):144–50.
- Gupta V, Winocour J, Shi H, Shack RB, Grotting J, Higdon K. Preoperative risk factors and complication rates in facelift: analysis of 11,300 patients. *Aesthet Surg J*. 2016;36(1):1–13.
- Cohen JC, Glasgold RA, Alloju LM, Glasgold MJ. Effects of intravenous tranexamic acid during rhytidectomy: a randomized, controlled, double-blind pilot study. *Aesthet Surg J*. 2020;
- Batra AP, Mahajan A, Gupta K. Marginal mandibular branch of the facial nerve: an anatomical study. *Indian J Plast Surg*. 2010;43(1):60–4.
- Hwang K, Kim JY, Lim JHB. Anatomy of the platysma muscle. *J Craniofac Surg*. 2017;28(2):539–42.
- Gordon NA, Adam SI. The deep-plane approach to neck rejuvenation. *Facial Plast Surg Clin North Am*. 2014;22(2):269–84.
- Farrior E, Eisler L, Wright HV. Techniques for rejuvenation of the neck platysma. *Facial Plast Surg Clin North Am*. 2014;22(2):243–52.
- Jacono AA, Talei B. Vertical neck lifting. *Facial Plast Surg Clin North Am*. 2014;22(2):285–316.
- Guyuron B. The problem neck, hyoid bone, and submental Myotomy. *Plast Reconstr Surg*. 1992;90(5):830–7; discussion 838–40.
- Bravo FG. Reduction neck lift: the importance of the deep structures of the neck to the successful neck lift. *Clin Plast Surg*. 2018;45(4):485–506.
- Marten T, Elyassnia D. Neck lift: defining anatomic problems and choosing appropriate treatment strategies. *Clin Plast Surg*. 2018;45(4):455–84.
- Beninger F, Pritchard S. Clonidine in the management of blood pressure during rhytidectomy. *Aesthet Surg J*. 1998;18(2):89–94.
- Ramanadham S, Costa C, Narasimhan K, Coleman J, Rohrich R. Refining the anesthesia management of the face-lift patient: lessons learned from 1089 consecutive face lifts. *Plast Reconstr Surg*. 2015;135(3):723–30.
- Baker D, Stefani WA, Chiu E. Reducing the incidence of hematoma requiring surgical evacuation following male rhytidectomy: a 30-year review of 985 cases. *Plast Reconstr Surg*. 2005;116:1973–85.
- Butz D, Geldner P. The use of tranexamic acid in rhytidectomy patients. *Plast Reconstr Surg Glob Open*. 2016;4(5):e716.
- Couto R, Charafeddine A, Sinclair N, Nayak L, Zins J. Local infiltration of tranexamic acid with local anesthetic reduces intraoperative facelift bleeding: a preliminary report. *Aesth Surg J*. 2020;40(6):587–93.

## History of the Procedure

Japanese literature offers the first description of a successful hair restoration procedure, reported by Sasagawa with his hair shaft insertion technique in 1930 [1]. Punch grafts of 2–4 mm were described later in the 1930s by Okuda [2]. The first hair restoration procedures performed in the United States were described by Orentreich in 1952. His technique utilized donor punch grafts much larger than reported in the Japanese literature, taken from the scalp measuring 6–8 mm in diameter [3]. These relatively large grafts were harvested from the posterior and lateral scalp and transplanted into slightly smaller diameter punch sites created in the area of alopecia. The donor sites would typically heal with multiple depressed, hypopigmented scars lacking hair, and would often have a “moth-eaten” appearance. The recipient site was prone to a “pluggy” look, particularly along the frontal hairline. Despite these disadvantages, larger grafts were utilized in the United States for the next 30 years. The concept of “donor-dependence” was also developed by Orentreich during this time and had great clinical relevance for treatment of androgenic alopecia up until present day. Donor dependence referred to the phenomena that grafted hair follicles continued to show the characteristics of the donor site regardless of the recipient site, including the lack of later hair loss in response to androgens in the new location. Thus, stable hair could be maintained in an area of androgenic alopecia indefinitely [3]. Noting that smaller grafts lent to a more natural hairline appearance, the development of “mini-grafts” in the 1980s and “mini-micrografts” in the 1990s, resembling the earlier Japanese technique, was adopted [4, 5]. As understanding of the anatomical follicular unit developed, the concept of placing grafts of this size to achieve a more natural,

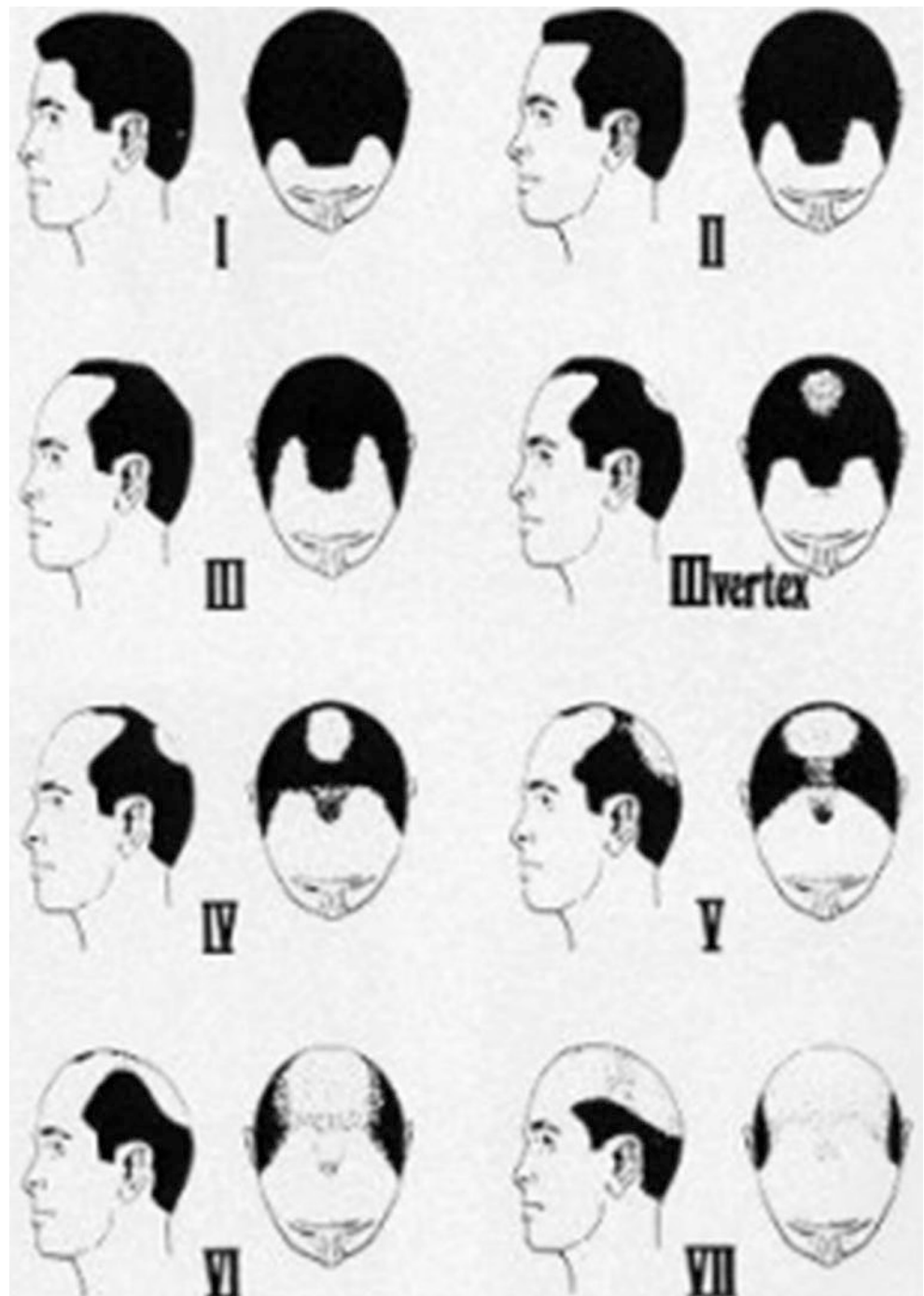
esthetic result was described by Rassman and Bernstein in 1995 and 1997 [6–8]. As follicular unit transplantation (FUT) was initially described, a donor strip (strip technique) was harvested from the posterior-lateral scalp, and under a stereomicroscope dissected into the naturally occurring follicular units. A follicular unit (FU) is typically comprised of 1–4 terminal hairs, one to two vellus hairs, along with the associated sebaceous glands, neurovascular plexus, an erector pili muscle, and the perifolliculum. The surgeon will plan to place the follicular units containing 1–2 terminal hairs to create the anterior hairline, while units containing 3–4 hairs are placed posterior to the first 1–2 cm of the anterior hairline. FUT has continued to be the most common method for hair restoration from that time until the present. In the early 2000s, a modification to the harvesting of the follicular units was described [9]. Called follicular unit extraction (FUE), this technique eliminated the need for harvest of a donor strip of scalp, instead using small punch excisions with or without microdissection to harvest each individual unit separately. The donor site closes by secondary intention. Instead of a long linear donor scar, the patient is left with several hundred/or thousand small hypopigmented indented scars, thus allowing the patient to wear their hair quite short. Shaving of the donor site is a prerequisite, and in general, the donor site is 5 times larger than the amount required for the strip technique. Robotic-aided FUE has also been described. Whether a strip technique or FUE is planned to procure donor hair, FUT is still the preferred method for placement.

## Indications for Hair Restoration Surgery

Hair restoration surgery is indicated most commonly for male pattern hair loss (androgenic alopecia) presenting in the patient over the age of 25. Androgenic alopecia (AA) is typically described by the Norwood classification first published in 1975 [10] (Fig. 24.1). When considering whether a patient is an appropriate candidate, one must consider their current

J. D. Perenack (✉)  
Louisiana State University Oral and Maxillofacial Surgery,  
Williamson Cosmetic Center, and Perenack Aesthetic Surgery,  
Baton Rouge, LA, USA  
e-mail: [drperenack@cosmeticbr.com](mailto:drperenack@cosmeticbr.com)

**Fig. 24.1** Norwood classification [10]



age and Norwood classification, family history of hair loss pattern, patient goals, availability and the quality of donor follicles [11]. A patient who is 50 years of age with a Norwood 4 classification may be an excellent candidate, while a patient who is 25 years old with a Norwood 4 classification and a strong family history of Norwood VII may be a poor candidate. Use of a Rassman densitometer [12] to measure absolute hairs per unit area may be helpful to document donor and recipient sites prior to surgery and determine graft availability. There are numerous conservative hair res-

toration medications and devices that may also be considered. Non-androgenic alopecia causes must also be ruled out. In addition, most males exhibit diffuse patterned alopecia (DPA), which provides for a stable zone of donor hair in the posterior and lateral scalp for grafting. However, some males will exhibit diffuse unpatterned alopecia (DUPA) that is similar to typical female pattern hair loss. These patients exhibit diffuse hair loss and miniaturization throughout the scalp and do not have a stable donor area. These patients are typically not good candidates for hair restoration surgery [7].



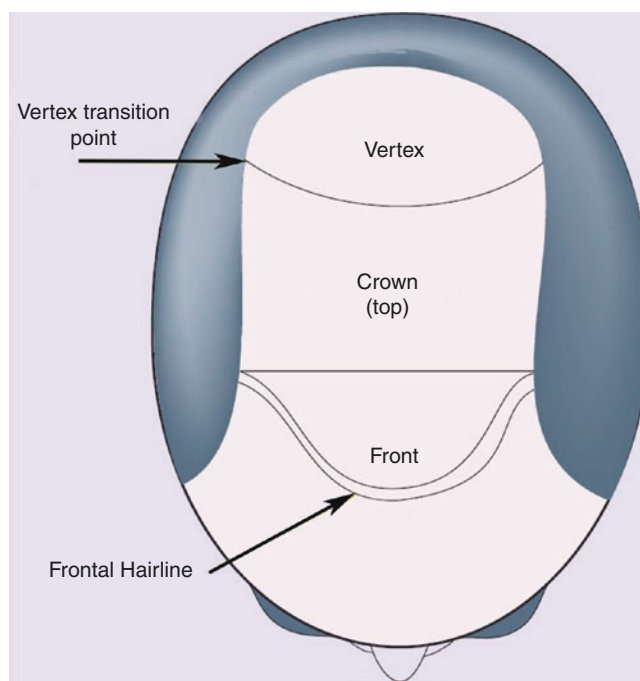
Female patients commonly present with DUPA, but may instead exhibit DPA, or AA patterned hair loss. As mentioned, the DUPA patient is often a poor surgical candidate, and early attention should be given to conservative measures such as PRP therapy, low-energy LED/diode laser light therapy, pharmacologic agents and nutritive supplements to slow advancing hair loss. Female DPA and AA patients can be treated like male patients.

Patients may present with hair loss secondary to a previous surgical procedure. Temporal hair loss may be seen after facelift surgery, and not uncommonly trichophytic browlift scars may become exposed after years of slow anterior hairline recession. Tumor resection or trauma to the hair bearing scalp may also cause permanent hair loss that may be amenable to treatment. Trauma or overplucking of the eyebrow may also present as site for hair restoration.

In a patient presenting with new, rapid hair loss, or hair loss that does not match AA, DPA, or DUPA, one must rule out autoimmune causes. This is typically done by performing multiple 3 mm punch biopsies of hair follicles in and adjacent to the affected area and examination of the histologic sections with immunofluorescence. Autoimmune-mediated hair loss patients are poor candidates for hair restoration surgery.

Once a patient has been determined to be a good surgical candidate, the surgeon needs to plan the pattern of grafting, angulation of graft placement, number of follicles needed for a visually positive outcome, and possible need for secondary surgery. In general, re-creation or lowering of an anterior hairline will require 600, 1–2 hair follicular units. Grafts are typically placed in a staggered pattern along the anterior hairline. A secondary surgery to add density to the area may be considered at 10–12 months and may require an additional 300–500 FU. Stand-alone vertex alopecia may require 600–1000 follicular grafts, and again additional grafting of a similar amount may be required at one year to achieve desired density. A typical Norwood V pattern patient may require two sessions of 2500 FU grafts, grafting from front to vertex. The first grafting session is planned so that results will look natural even if a second session never occurs. If existing hair is present, the surgeon must plan on placing grafts such that further alopecia does not expose an unnatural grafting hair pattern. Recipient sites should be angled to follow existing hair angulation and hair style parts and pattern (Fig. 24.2).

Once the number of grafts and surgeries are determined, the donor site should be assessed for adequacy of donor graft availability. Donor density, scalp laxity and absolute donor size are documented. A typical 1 cm<sup>2</sup> unit of posterior scalp may yield 100 follicular units in the average patient. However, this density may be quite less in some patients due



**Fig. 24.2** Regions of the scalp

to stretching of the scalp from previous surgeries, scarring, the presence of DUPA, and general genetic tendency. Follicle density is generally less on the lateral aspects of the scalp. The density of follicles in African American patients is also typically less. The donor strip must be planned in length and width so that a tension-free closure can be obtained while enough graft is harvested. If a patient lacks sufficient graft material to obtain the planned result, a frank discussion about goals and outcomes must be had with the patient to determine if hair restoration is appropriate for their desires.

## Contraindications for Hair Restoration Surgery

Other than general medical conditions precluding surgery, including keloid formation and auto-immune mediated hair loss, there are no absolute contraindications to hair restoration surgery

### Relative contraindications for treatment of androgenic alopecia

1. Patient age under 25
2. Norwood VII pattern hair loss, or anticipated hair loss
3. DUPA
4. Inadequate donor graft material or site
5. Excessive scarring at recipient site
6. Unrealistic patient expectations

## General Anatomy for Hair Restoration

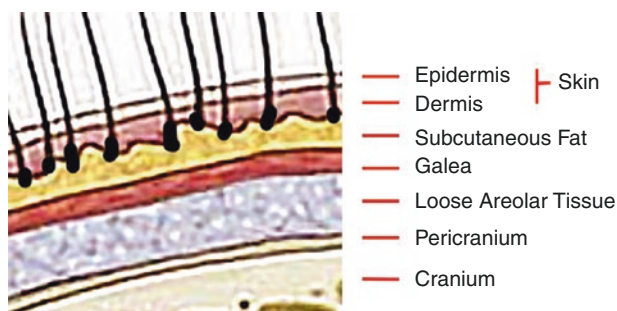
Contemporary hair restoration surgery is almost exclusively limited to the superficial layers of the scalp, specifically, the epidermis and dermis, with their appendages, and the subcutaneous fat layer. However, it is important for the hair restoration surgeon to be aware of adjacent deeper structures so as to be prepared in the instance of technical misadventure.

### The Scalp

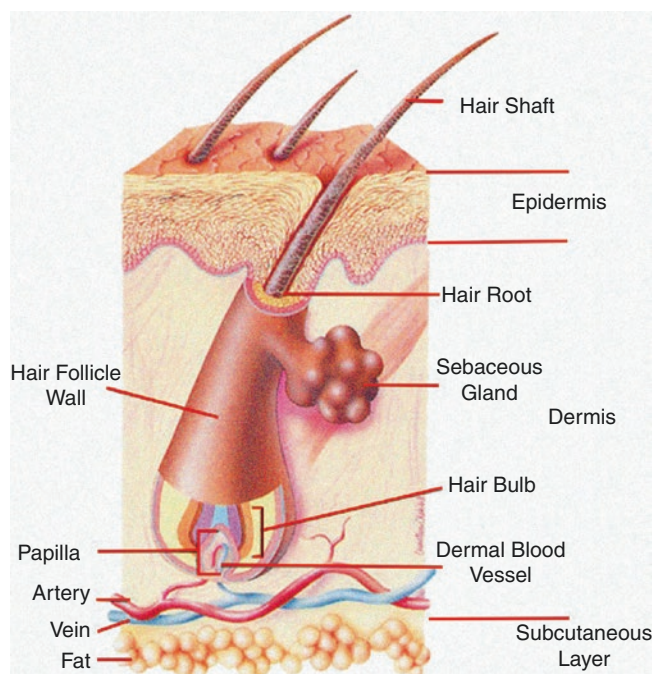
The scalp is composed of five layers from superficial to deep: (1) the skin (epidermis and dermis), (2) the subcutaneous fat layer, (3) the subcutaneous musculoaponeurotic layer – consisting of the frontalis muscle anteriorly, the occipitalis muscle posteriorly and the intervening fascial aponeurosis, (4) loose areolar tissue, (5) Periosteum (Fig. 24.3). Hair restoration surgery, when performed properly, should not violate the anatomic plane deep to the subcuticular layer.

### The Hair Follicle

The follicular pilosebaceous unit consists of the hair follicle itself, an attached sebaceous gland, the associated arrector pili muscle and neurovascular plexus, and the perifolliculum. Most follicular units contain from 1 to 4 terminal hairs along with 1–2 vellus hairs (Fig. 24.4). Vellus hair pilosebaceous units do not penetrate deeper than the reticular dermis, while terminal hairs penetrate into the subcutaneous tissue. When procuring hair follicles for follicular unit transplantation, it is important to maintain the entire pilosebaceous unit. During harvest to the naked eye, or with loupe magnification, typically, only the hair shaft and bulb are visible with adjacent fatty tissue present surrounding the bulb. It is important to leave this fatty tissue intact and not to trim grafts so closely to the bulb to preserve the integrity of the follicular unit. Follicular units containing 3 or 4 terminal hairs are best



**Fig. 24.3** Scalp anatomy



**Fig. 24.4** Follicular unit

suited to grafting areas at least 1–2 cms posterior to the planned anterior hairline. FUs containing 1 or 2 terminal hairs are typically used for recreating the anterior hairline, eyebrows or other sites that present a beginning of a hair-bearing area.

### Vascular and Sensory Supply of the Scalp

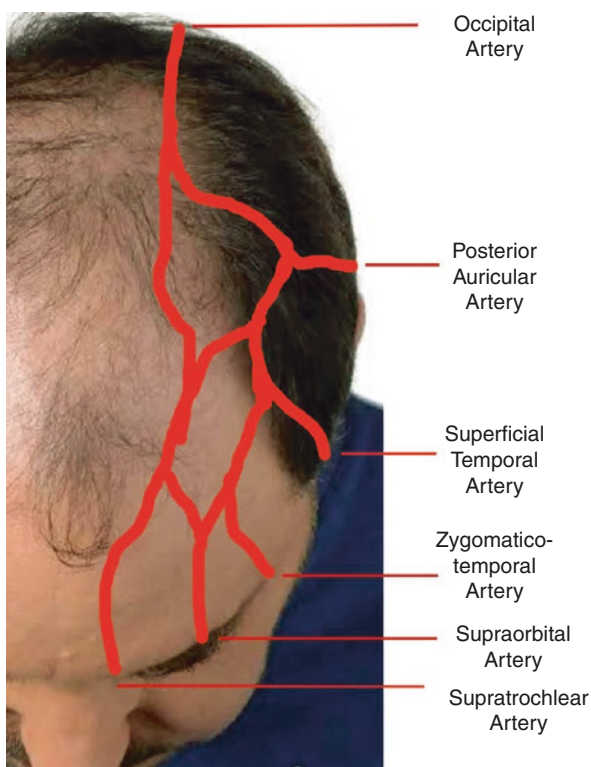
If performed properly, FUE and FUT should not encounter any significant vascular or nervous supply to the scalp. Rarely, a deeper vessel may be encountered. Bleeding associated with vessel transection may be easily accomplished with heat or electrocautery, or vessel tie-off if necessary (Fig. 24.5). Sensory or motor nerves are not encountered.

### Procedure and Anatomical Considerations

The two main phases of hair restoration surgery are (1) graft harvest, and (2) graft placement.

#### Graft Harvest

During the graft harvest phase, attention is turned to toward procurement of follicular units. This may be accomplished either through a strip harvest of the scalp with secondary fol-



**Fig. 24.5** Vascular supply of the scalp

licular dissection, or through individual follicular unit extraction, typically with a small (0.8–1.25 mm) punch device (FUE). As terminal hair bulbs are present slightly below the reticular dermis into the subcutaneous tissue, the surgeon will extract either the strip or individual follicle to slightly below this level, leaving a small amount of soft tissue (perifolliculum and neurovascular plexus) attached below the hair bulb, and subcutaneous fat present deep to the dissection. By staying within the subcuticular plane, the surgeon can avoid any large vascular structures or sensory/motor nerves. There is never a need to violate the deeper fascia or occipitalis muscle.

## Graft Placement

During graft placement, the surgeon makes a small stab incision in the scalp slightly wider than the graft to a depth slightly into the subcutaneous tissue. This may be accomplished with various beaver-type blades, needles, or Nacor type needles. Attention is given to making the graft accepting incisions in such a way as to follow appropriate angulation and pattern that would be expected in the native hair that would normally occur in the area.

## Technique: Strip Technique for Follicular Unit Transplantation

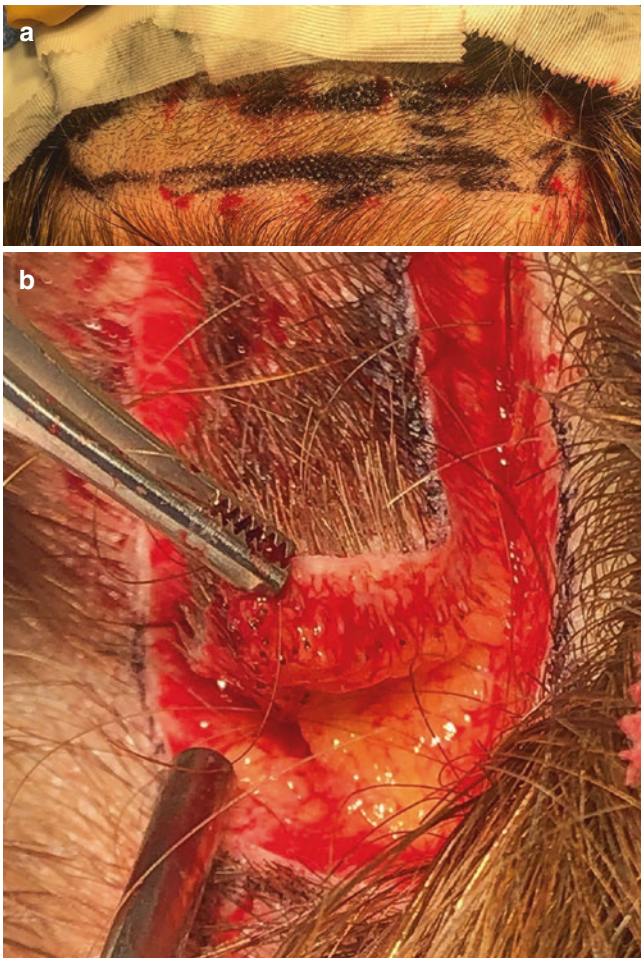
**Step 1. Marking:** With the patient sitting or standing in an upright position, the position of the anterior hairline is marked. A 1–2 centimeter zone is marked where 1–2 hair FU are to be used. The extent laterally and to the vertex where grafting is planned is marked. The direction of hair angulation and vertex pattern are marked. The donor site is marked typically just below the occiput, 1–1.3 cm in height by an appropriate length depending on density, laxity, and the number of grafts needed. The donor site only is trimmed so that hairs are 1–2 mm in length. The planned frontal hairline marking is confirmed with the patient looking in a mirror.

**Step 2. IV sedation and local anesthesia:** The patient is taken to the operating room and laid prone on the table. A dilute Hebiclens solution is used to prep the surgical site and hair. A complete ring block around the scalp is performed with a lidocaine/marcaine mixture. Tumescence fluid is infiltrated in the subcutaneous plane in areas of donor graft harvest and planned recipient sites. For patients anxious about the ring block injection, IV sedation or oral anxiolysis is offered.

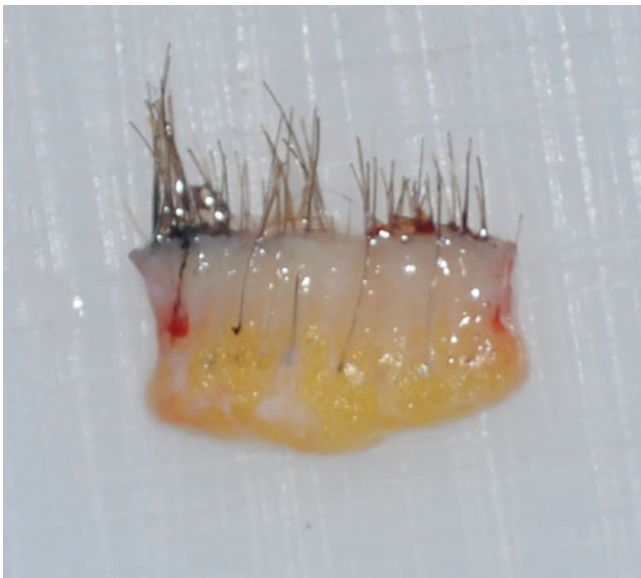**Step 3. Donor site harvest:** The donor site is draped in a semi-sterile fashion. Using a 10 blade angled to parallel the direction of the hair follicles, an incision outlining the proposed graft down to the subcutaneous tissue level is carried out. The graft is harvested with care not to interrupt the inferior aspect of the follicles. It is desirable to maintain 1–2 mm of fatty tissue to protect the follicular bulbs (Fig. 24.6). The graft is placed in a petri dish containing NS or LR and passed to the technicians for FU preparation. The donor defect is closed with interrupted SQ vertical mattress 4-0 polyglycolate sutures. The skin is closed with staples or a running, locked nylon sutures that are removed at 7–10 days. An antibiotic ointment is placed over the donor site.

**Step 4. Graft preparation:** Immediately after the donor strip is harvested, the technicians begin preparation of the FU grafts. This often takes place concurrently while the recipient sites are prepared. The initial step is called “slivering,” where the donor strip is horizontally dissected into slivers roughly 1–2 FU thick (loaf-of-bread slicing) (Fig. 24.7). Visualization of the follicles is accomplished with either a low-power stereoscopic microscope or with high-power surgical loupes. The slivers are then dissected using either a 10 blade or straight razor on a cutting board to isolate the individual FUs. The isolated FUs are then placed in chilled petri dishes containing NS, and are segregated into groups of FUs containing 1, 2, 3, or 4 terminal hairs (Fig. 24.8). This pro-





**Fig. 24.6** (a) Donor strip is marked and area is shaved (b) Donor strip is harvested at the level of the subcutaneous fat



**Fig. 24.7** Slivering of the donor strip



**Fig. 24.8** Final dissected follicular units

cess continues until the entire graft is dissected into FUs. The final graft count is then recorded.

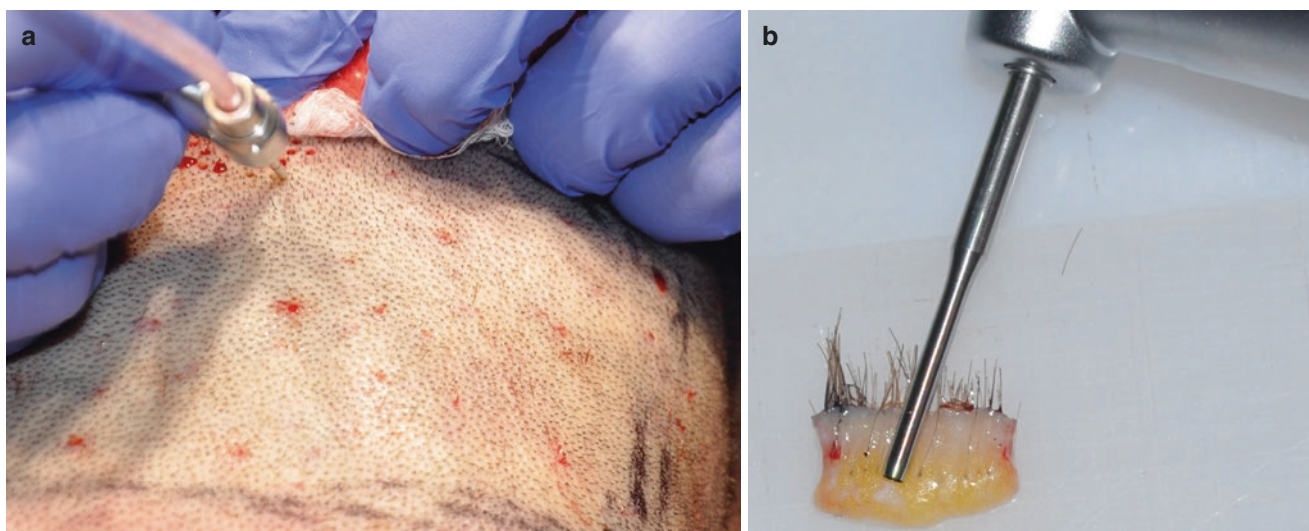
### Technique: Follicular Unit Extraction for Follicular Unit Transplantation

*Step 1. Marking and Harvest Site Preparation:* The sites to be grafted are marked on the patient as would be done with the strip technique. To perform FUE, the donor area must be shaved to about 1 mm in length. If a patient requires only 100–400 grafts, and wears their hair long, horizontal posterior strip areas may be marked that are 1.0–1.5 cm in height and roughly 10–12 cm in length. This strip may then be shaved to allow graft procurement with hair superior to the site allowed to drape over the area for camouflage. Typically, 1 or 2 shaved areas may be created to allow FUE while not requiring complete shaving of the posterior scalp. For patients requiring 500 to 1500 FUs to be extracted by FUE, a large posterior area must be shaved. The area must be roughly 5Xs larger than expected for strip technique with avoidance of harvesting hair from the nape or 2–3 cm from the lateral extent of the hairline.

*Step 2. IV sedation and local anesthesia:* Performed as with strip technique. Tumescence solution is added throughout the entire area to be harvested and may require reapplication during longer cases to decrease bleeding and facilitate graft harvest.

*Step 3. Donor site harvest:* The donor site is draped in a semi-sterile fashion. Appropriate punch size is chosen depending on the thickness of the patient's hair and nature of the hair follicle. Thin to average hair may be harvested with a 1 mm punch. Thicker hair, or African American hair, often requires a 1.25 mm punch. Utilizing the FUE system avail-





**Fig. 24.9** (a) FUE harvest from scalp (b) Angulation of FUE harvest next to scalp sliver for comparison

able, the surgeon angles the punch to match the orientation of the hair follicle (Fig. 24.9). The punch is inserted until the resistance of the dermis is broken and the follicle can be easily removed. Most FUE extraction systems have a suction-based collection system that requires the grafts to be removed and further modified as needed. The grafts are then placed in a petri dish containing NS or LR and passed to the technicians for FU transplantation.

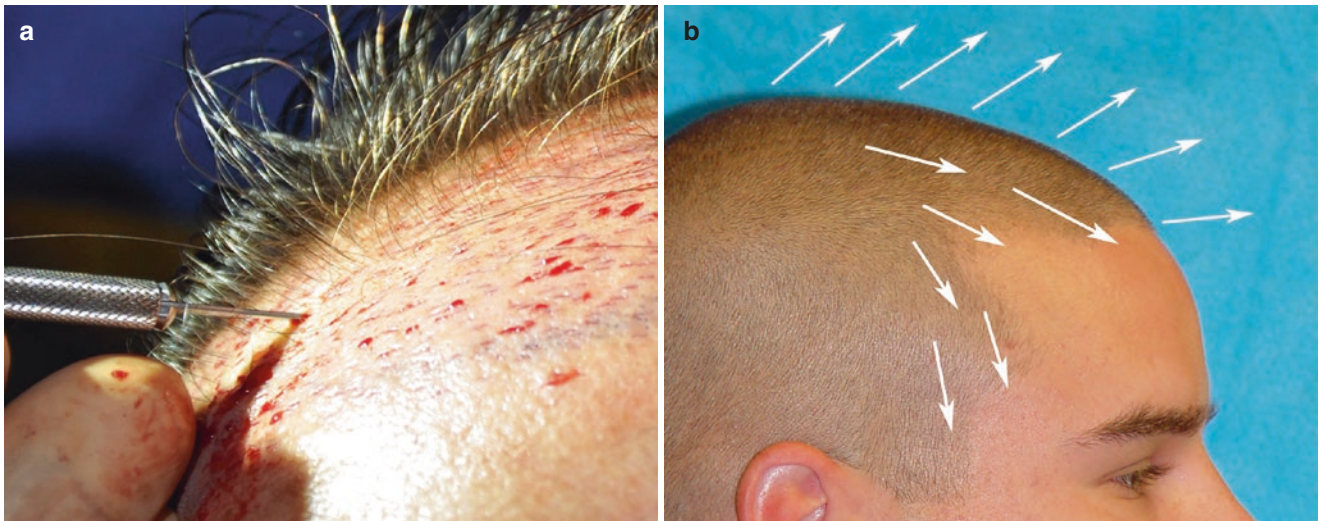
### Technique: Recipient Site Preparation for Follicular Unit Transplantation

*Step 1. Recipient site preparation:* Depending on the size of the grafts to be placed, the surgeon will choose an 89, 90, or 91 rounded beaver blade for site preparation. Nacor needles of varying sizes may also be used. The patient is now seated in an upright to semi-reclined position with soft neck pillows used to incline the head to expose the planned recipient area. An assistant keeps count of the number of recipient sites created. It is preferable to create sites from back to front as occasional bleeding may obscure the more dependent site. Care is made to angulate the blade in the direction the hair should grow, generally forward, often at 45 degrees to the scalp plane along the vertex and crown. This angulation becomes more acute approximating 30 degrees approaching the anterior hairline (Fig. 24.10). If the temporal tuft is grafted, the angulation is quite extreme and directed inferiorly and slightly forward. Once the recipient sites are created, graft placement may begin immediately (Fig. 24.11). One variation of this technique is the “stick and place” method, where the surgeon creates the recipient site and immediately places the graft. While this decreases the time of the graft outside the body and it is often easier for the surgeon to place the graft, it limits the ability of having more

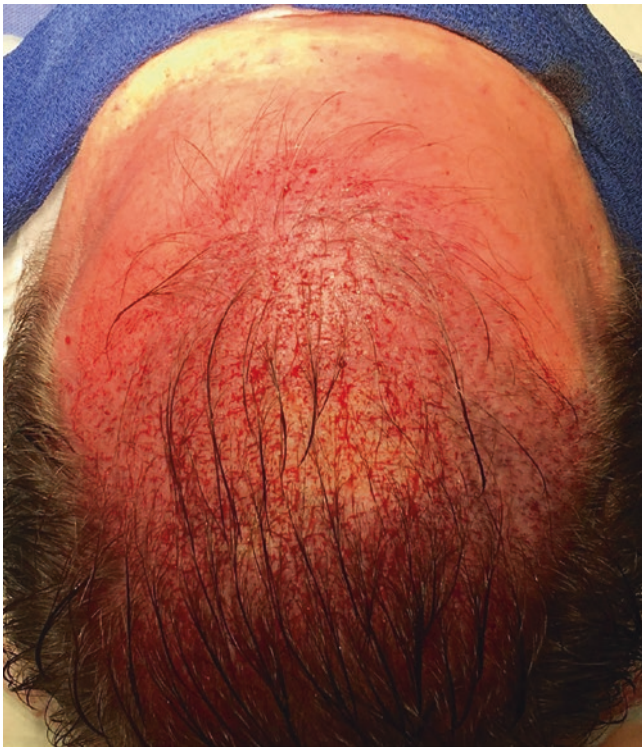than one graft placer. In addition, “stick and place” requires the surgeon’s personal attention throughout the procedure leading to operator fatigue and limiting the number of patients to be treated in one day.

*Step 2. Graft placement:* The grafts are then transferred in a petri dish to the OR. The placing technician places 20–30 grafts on their non-dominant index finger. Using a curved jeweler’s forceps, each graft is grasped gently at the base without crushing the follicular bulb. The graft is inserted into the prepared recipient site in the same angulation as the site was made. Placing continues until all grafts are inserted (Fig. 24.12). The surgical site is constantly sprayed with NS to cleanse any blood and keep the grafts moist. Occasionally, a patient may experience prolonged bleeding from a recipient site resulting in “popping” of the placed grafts. This may be managed by keeping the patient’s head elevated and injection of 2% lidocaine with 1:100,000 epinephrine in the area of bleeding. Once all grafts are placed, a tension headband is placed to compress the donor site. A surgeon’s cap is placed over the head to protect the grafted area.

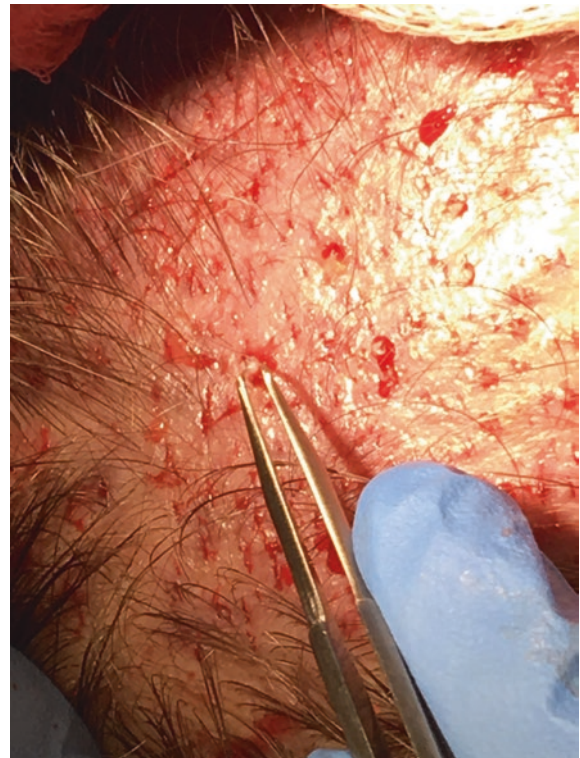
*Step 3. Postoperative course and care:* Most patients report minimal discomfort and have adequate relief with NSAIDs. For the first three days, the patient is given a spray bottle with NS to keep the grafted site moist. Gentle washing of the donor site is allowed on the first postoperative day. The patient is allowed to shampoo gently the entire scalp with baby shampoo on the third day and may wear a cap. Small scabs may be present attached to the grafts that are typically shed by 7–10 days. Most grafted FUs will shed their associated hair shafts within two weeks. Growth returns as early as two months with the majority of grafts appearing within 4–6 months. For most males, a final result will not be seen until 10–12 months depending on the patient’s hair length (Fig. 24.13).



**Fig. 24.10** (a) Site preparation with angulation of blade (b) Arrows denoting general angulation of graft site preparation

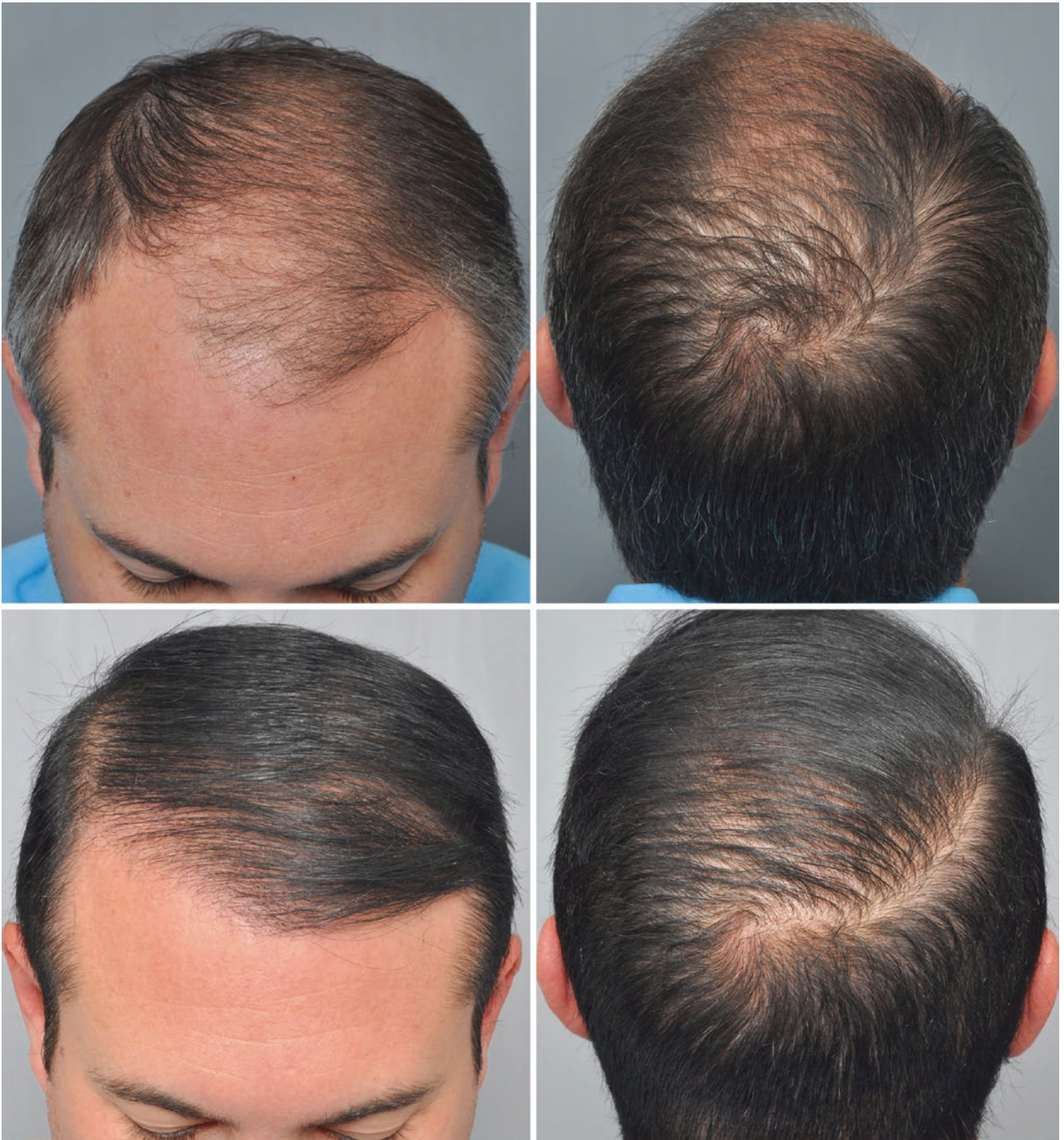

**Fig. 24.11** Recipient sites completed



**Fig. 24.12** Placement of grafts into recipient sites





**Fig. 24.13** Preoperative appearance and 12 months post-op 2200 follicular graft session

## Summary

Hair restoration surgery is a highly predictable procedure that employs a simplified surgical technique that has an acceptable patient experience and limited complications. Anatomical considerations are generally limited to the epidermis, dermis, and subcuticular tissue. The art of hair restoration surgery requires knowledge of normal hair angulation, patterns, and appropriate treatment plan formulation to meet the patient's needs.

## References

1. Sasagawa M. Hair transplantation. *Jpn J Dermatol*. 1930;30:473. (in Japanese).
2. Okuda S. Clinical and experimental studies of transplantation of living hairs. *Jpn J Dermatol Urol*. 1939;46:135–8. (in Japanese).
3. Orentreich N. Autographs in alopecias and other selected dermatologic conditions. *Ann NY Acad Sci*. 1959;83:463–79.
4. Rassman WR, Pomerantz MA. The art and science of minigrafting. *Int J Aesthetic Rest Surg*. 1993;1:27–36.
5. Rassman WR, Carson S. Micrografting in extensive quantities; the ideal hair restoration procedure. *Dermatol Surg*. 1995;21:306–11.
6. Bernstein RM, Rassman WR, Szaniawski W, Halperin A. Follicular transplantation. *Int J Aesthetic Rest Surg*. 1995;3:119–32.
7. Bernstein RM, Rassman WR. Follicular transplantation: patient evaluation and surgical planning. *Dermatol Surg*. 1997;23:771–84.
8. Bernstein RM, Rassman WR. The aesthetics of follicular transplantation. *Dermatol Surg*. 1997;23:785–99.
9. Rassman WR, Bernstein RM, McClellan R, Jones R, et al. Follicular unit extraction: minimally invasive surgery for hair transplantation. *Dermatol Surg*. 2002;28:720–7.
10. Norwood OT. Male pattern baldness: classification and incidence. *Southern Med J*. 1975;68:1359–65.
11. Kuster W, Happle R. The inheritance of common baldness: two B or not two B. *J Am Acad Dermatol*. 1984;11:921–6.
12. Bernstein RM, Rassman WR. Densitometry and video-microscopy. *Hair Transplant Forum Int*. 2007;17(2):1,49–51.



## Appendix 1

### Osteology

The major bones of the external cranium housing the brain include two bilateral bone pairs: the temporal and parietal bones, and bones that cross and center on the midline of the head: the frontal, occipital, and sphenoid bones (Fig. A1.1). The ethmoid bone also crosses the midline and can be observed in the medial wall of the orbit, the space housing the eyeball, extraocular muscles, vessels, nerves, and adipose tissue. Most of these bones are joined by fibrous sutures, many of which are named (Fig. A1.2).

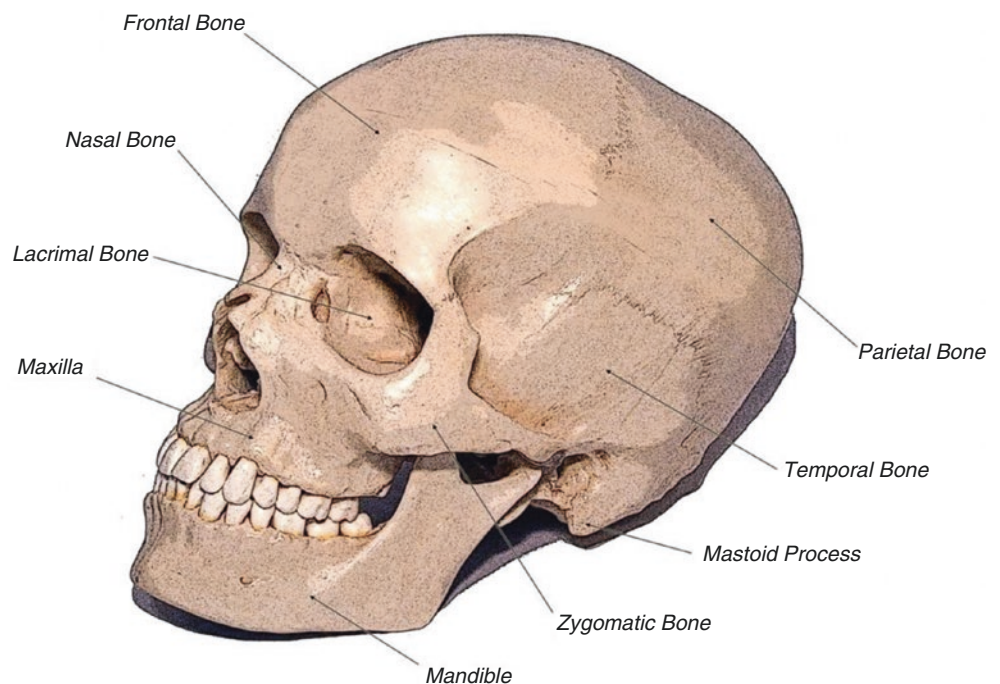
### Anterior Surface of the Skull

The facial skeleton is composed of the frontal and zygomatic bones, nasal and lacrimal bones, maxillae, and mandible. The frontal bone underlies the forehead and makes up the


roof of the orbit and part of the floor of the anterior cranial fossa. It has prominent superciliary arches above the orbit and a sharp ridge at the superior orbital rim that may lacerate the skin when this area is traumatized. The glabella is the smooth depressed area between these arches (Fig. A1.3). At the superior margin of the orbit is the supraorbital notch or foramen. The major sensory termination of the ophthalmic division of the trigeminal nerve (supraorbital nerve) and vessels passes through this foramen or notch onto the forehead.

Within the orbit are the superior orbital fissure and the optic foramen. Veins from the orbital cavity that drain into the cavernous sinus and the ophthalmic division of the trigeminal nerve, oculomotor, abducent, and trochlear nerves pass through the superior orbital fissure. The optic nerve and ophthalmic artery (branch of the internal carotid artery) course through the optic foramen. In the floor of the orbit is the inferior orbital fissure, which opens posteriorly into the infratemporal and pterygopalatine fossae. The infraorbital

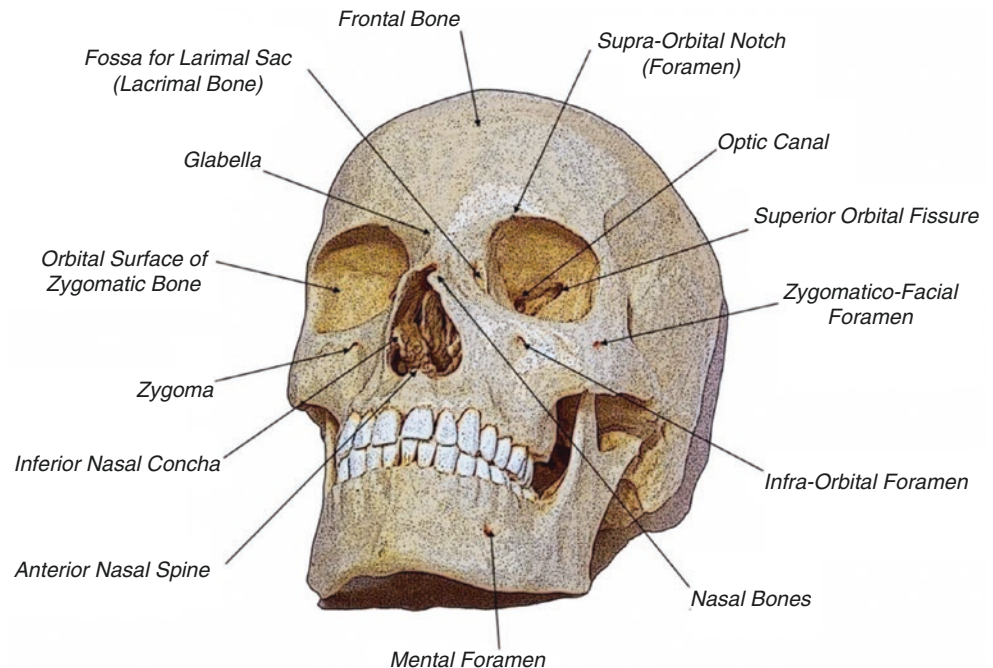
**Fig. A1.1** Lateral view of the skull: major bones and mastoid process of temporal bone are labeled



**Fig. A1.2** Posterior view of the skull: occipital and temporal bones are indicated. Several major sutures are labeled



**Fig. A1.3** Anterior view of the skull



groove and canal extend anteriorly from the fissure, and the canal opens onto the face through the infraorbital foramen. A sensory branch of the maxillary division of the trigeminal nerve, the infraorbital nerve, enters the face through this foramen. From the inferior wall of the infraorbital canal, the middle and anterior superior alveolar nerves descend to supply the anterior and premolar teeth and the tissues surrounding them.

Several bones of the skull are pneumatized and contain sinuses. These are air spaces that increase in size with increasing age. They are present in the maxillary bones, the ethmoid bones, the sphenoid bone, usually the frontal bones, and the mastoid process of the temporal bones.

Inferiorly, the frontal bone articulates with the nasal, lacrimal, and ethmoid bones near the midline, with the sphenoid bone in the posterior orbit, and the zygomatic bone laterally. The thin, paired nasal bones are prominent and subject to fracture during sports or accidents. The lacrimal and ethmoid bones on the medial surfaces of the orbit are extremely thin and may fracture with trauma causing communication between the orbit and underlying sinuses. On the medial wall of the orbit are the anterior and posterior ethmoid foramina. Branches of the nasociliary nerve enter these foramina to supply the ethmoid air cells. The anterior branch also enters the cranial fossa at the lateral margin of the cribriform plate, runs anteriorly for a few millimeters, descends through the

nasociliary slit into the nasal cavity, and emerges onto the face at the lower border of the nasal bone as the external nasal nerve. The nasolacrimal canal lies anteriorly on the medial wall of the orbit. It transmits the tear duct to the inferior nasal meatus.

The zygoma forms the prominence of the cheeks, anterior and lateral to the orbit. On the lateral surface of the zygoma is the zygomaticofacial foramen, and on its posterior surface is the zygomaticotemporal foramen. Sensory nerves from the trigeminal nerve (maxillary division) pass through these foramina to the skin.

Within the nasal cavity is the nasal septum in the midline and, on the lateral surfaces are the bony nasal conchae (superior, middle, and inferior). The hiatus semilunaris is an opening through which the maxillary sinus communicates with the middle meatus of the nasal cavity, just lateral to the middle concha. Note that the connection between the maxillary sinus and the middle meatus is near the roof of the sinus, making natural drainage from the sinus difficult. Projecting anteriorly from the floor of the nasal fossa, the maxilla forms an anterior nasal spine in the midline.

The maxillae make up the majority of the midface, extends into the orbit floor, and support the maxillary teeth (alveolar process). The maxillae extend from the maxillary teeth to the floor of the orbit medially. The infraorbital foramen is located inferior to the orbit. The bone over the root of the canine tooth is elevated to form the canine eminence, and posterior to the eminence is a depression, the canine fossa. Anterior to the canine eminence is a smaller depression, the incisive fossa.

## Interior Base of the Skull

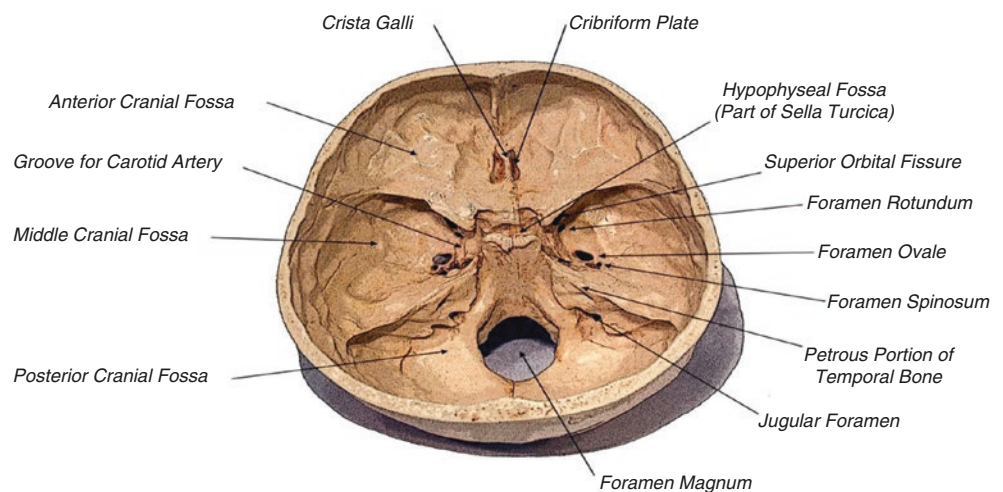
In the anterior cranial fossa, the crista galli is prominent in the midline rising superiorly from the ethmoid. This provides an attachment for the cerebral falx, a reflection of the dura.

The cribriform plate of the ethmoid lies on both sides of the crista galli. The olfactory nerves pass through these foramina to the olfactory bulb. In a traumatic head injury, these nerve fibers can be torn at this point (Fig. A1.4).

In the middle cranial fossa, the hypophyseal fossa is located. The pituitary gland is housed within this fossa, connected to the brain by the infundibulum. What would be the consequence of severing this connection? On the lateral side of the hypophyseal fossa is a groove for the internal carotid artery. The artery is surrounded by the cavernous sinus, a major intracranial venous sinus. Passing through the cavernous sinus in or near its lateral wall, and exiting the cranial cavity through the superior orbital fissure are four nerves: ophthalmic division of the trigeminal (CN V1), oculomotor (CN III), trochlear (CN IV), and abducent (CN VI). Appendix 3 explains the course of the oculomotor nerve. Appendix 4 illustrates the trochlear and abducent nerves. Appendix 5 outlines the trigeminal nerve. Passing through the fissure from the orbit into the skull are veins from the orbital cavity that drain into the cavernous sinus, providing a potential pathway for infections spread from the face to the brain. The superior orbital fissure separates the greater and lesser wings of the sphenoid bone. Inferior to the medial end of the superior orbital fissure lies the foramen rotundum. The maxillary division of the trigeminal nerve passes through this foramen to enter the pterygopalatine fossa. The foramen ovale is about one centimeter posterior to the foramen rotundum. Both motor and sensory components of the mandibular division of the trigeminal nerve pass through the foramen ovale.

An accessory meningeal branch of the maxillary artery also enters the cranial cavity through the foramen. Finally, the lesser superficial petrosal nerve usually leaves the skull through this foramen. (The lesser superficial petrosal nerve is parasympathetic. These fibers leave the brain in the glossopharyngeal nerve but soon leave it and through a complex course ultimately leave the skull through the foramen ovale to synapse in the otic ganglion on the mandibular nerve.

**Fig. A1.4** Interior base of the skull





Postganglionic fibers travel with the auriculotemporal branch of the mandibular nerve, and ultimately supply the parotid gland).

Medial to the foramen ovale is the foramen lacerum. This “foramen” is occupied in life by a plate of cartilage. Nothing but a small meningeal artery actually passes the full distance from the bottom to the top of this cartilage plate. The internal carotid artery leaves the carotid canal in the petrous portion of the temporal bone, crosses the cartilage in the foramen lacerum, and then turns superiorly. The greater superficial petrosal nerve (parasympathetic fibers from the facial nerve) enters the foramen from its intracranial end but exits anteriorly before reaching the bottom of the cartilage plate. The nerve then enters the pterygoid canal with branches (deep petrosal nerve) of the sympathetic plexus surrounding the internal carotid artery. The greater superficial petrosal nerve and the deep petrosal nerve combine in the pterygoid canal to form the nerve of the pterygoid canal. Posterior and lateral to the foramen ovale lies the foramen spinosum, through which the middle meningeal branch of the maxillary artery enters the cranial cavity.

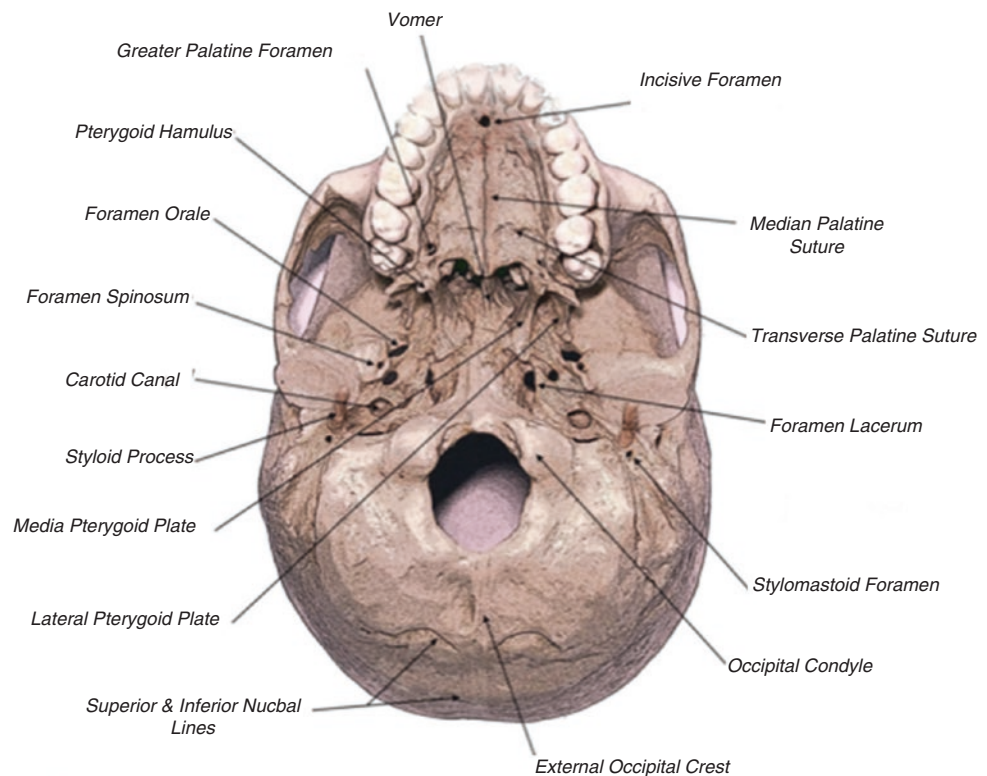
Posterior to the foramina described above is the crest of the petrous portion of temporal bone, separating the middle cranial fossa from the posterior cranial fossa. Near the anterior end of this crest is a depression for the trigeminal nerve and ganglion. On the posterior slope of this crest is the internal acoustic meatus. The vestibulocochlear and facial nerves leave the cranial fossa through this opening.

Below the internal acoustic meatus is the jugular foramen. Through this foramen, the glossopharyngeal (CN IX), accessory (CN XI), and vagus (CN X) nerves leave the cranial cavity accompanying the internal jugular vein. The hypoglossal canal in the occipital bone, through which the hypoglossal nerve leaves the cranial cavity, is below the jugular foramen.

## Exterior Base of Skull

Foramen ovale, jugular foramen, and hypoglossal canal are visible and are openings through which some of the cranial nerves leave the skull as outlined above. Also, foramen spinosum is behind and lateral to the foramen ovale, and the foramen lacerum medial to the foramen spinosum. The major motor component of the facial nerve (CN VII) leaves the skull through the stylomastoid foramen, posterior to the base of the styloid process and anterior to the mastoid process. Behind the stylomastoid foramen are two grooves. The deeper lateral groove is the origin of the posterior belly of the digastric muscle, and the shallower medial groove houses the occipital branch of the external carotid artery. Lateral to the grooves is the mastoid process from which the sternocleidomastoid muscle arises. Extending posteriorly from the mastoid process are the inferior and superior nuchal lines, formed by the attachments of vertebral muscles (Fig. A1.5).

**Fig. A1.5** Exterior base of the skull





The nuchal lines meet in the midline at the external occipital crest formed by the attachment of the ligamentum nuchae. The crest ends anteriorly at the foramen magnum. The lower end of the medulla oblongata and the vertebral arteries pass through the foramen magnum. At the anterior and lateral margin of the foramen, identify the *occipital condyle* that articulates with the atlas (1st cervical vertebra). Superior to the condyle is the hypoglossal canal. A condylar canal is frequently found posterior to the condyle. The condylar canal and similar but unnamed canals and foramina scattered over the skull transmit either diploic veins that join the veins within the marrow spaces of the skull or emissary veins that communicate with the veins of the meninges covering the brain. It is largely because of these venous connections that infections deep to the scalp are particularly dangerous.

About one centimeter behind the foramen spinosum, and separated from the mandibular fossa by the spine of the sphenoid bone, is the inferior opening of the carotid canal. The internal carotid artery enters the canal, bends anteriorly and medially, passing through the petrous portion of the temporal bone, and bends superiorly in the foramen lacerum, subsequently running through the cavernous sinus. If the cavernous sinus fills with arterial blood, what would be the clinical presentation? Which nerves would be affected because they lie in or close to the lateral wall of the cavernous sinus?

Several landmarks can be identified on the bony palate. The intermaxillary suture separates the palatal processes of the maxillae and the horizontal plates of the palatine bones. The hard palate is formed by medial growth of the maxillary bone from each side of the head with suture formation in the midline. What would be the result of a failure of these bones to form a suture? What would be the consequence of premature suture formation? A transverse suture (palatamaxillary suture) separates the palatal bone from the maxilla. At the anterior end of the intermaxillary suture is the *incisive foramen*. The nasopalatine branch of the maxillary division of the trigeminal nerve enters the palate here to supply the soft tissues behind the anterior teeth, and a branch of the greater palatine artery enters this foramen to supply the floor of the nasal cavity. At the side of the palate, near its posterior end, the greater (anterior) palatine foramen can be seen near the roots of the second or third molar. The greater palatine branches of the maxillary nerve and artery emerge through the foramen and run forward to provide sensory innervation to the hard palate and covering gingiva. Behind the greater palatine foramen, identify the lesser (posterior) palatine foramen or foramina within the pyramidal process of the palatine bone. The vessel and nerve emerging through it have the same origins as the greater palatine vessels and nerves and supply the soft palate.

The adult skull normally contains 32 permanent teeth, 16 in the maxilla and 16 in the mandible. A central and a

lateral incisor, a canine tooth, two premolar teeth, and three molars occupy each side of the maxilla and mandible. The third molar teeth are the last teeth to erupt. Frequently, there is inadequate space for these teeth, and they may become impacted behind the second molar. Extraction of third molars is a common procedure. The roots of the teeth are supported by the alveolar processes of the mandible and the maxilla. This alveolar bone resorbs when the teeth are extracted unless a dental implant is placed.

Posterior to the palatine bones are the medial and lateral pterygoid plates of the sphenoid bone. The lateral pterygoid muscle arises from the lateral surface of the lateral pterygoid plate. The medial pterygoid muscle arises from the medial surface of the lateral pterygoid plate. The tensor veli palatini muscle arises from the scaphoid fossa at the base of the medial pterygoid plate, and its belly occupies the pterygoid fossa between the two plates. This muscle descends to, and its tendon runs medially over, the pterygoid hamulus at the inferior end of the medial pterygoid plate. The tendon then inserts into a fibrous sheet within the palate. At the root of the medial pterygoid plate, in the anterior wall of the foramen lacerum, is the opening to the pterygoid canal, which extends to the pterygopalatine fossa. The greater superficial petrosal nerve (parasympathetic fibers from the facial nerve) and deep petrosal nerve (sympathetic fibers from the carotid plexus) join and enter this canal as the nerve of the pterygoid canal.

The mandibular (glenoid, articular) fossa is bounded anteriorly by the articular eminence. The lateral end of this eminence (articular tubercle) is often prominent because of the attachment of the temporomandibular ligament. The articular surface of the fossa (posterior slope of the articular eminence) is bounded posteriorly by a postglenoid lip, the lateral end of which is prominent (postglenoid process). This lip abuts the tympanic portion of the temporal bone. The suture formed by these two components of the temporal bone is the squamotympanic fissure (the superior surface of the fossa is formed by the squamous portion of the temporal bone). A tiny tongue of the petrous portion of the temporal bone intervenes in the fissure in its medial half. The fissure is thereby divided into petrosquamosal and petrotympanic fissures. The chorda tympani nerve, a branch of the facial nerve (CN VII) containing parasympathetic and taste fibers, leaves the skull through the petrotympanic fissure. The spine of the sphenoid bone contributes to the medial wall of the mandibular fossa.

---

## Lateral Surface of the Skull

The superior and inferior temporal lines mark the superior attachments of the temporal fascia and temporalis muscle, respectively. The muscle arises from the medial surface of

the temporal fascia as well as from the temporal fossa. The fascia is attached to the zygomatic arch below. This fascia stabilizes the zygomatic arch in the event of its fracture. The temporal fossa is bounded above by the temporal lines and below by the infratemporal crest. The crest marks the site at which the vertical great wing of the sphenoid and squama of the temporal bone bend horizontally and medially. Pterion is formed by the sutures that unite the frontal, parietal, sphenoid, and temporal bones. It is clinically important because it overlies the anterior branches of the middle meningeal artery (Fig. A1.6).

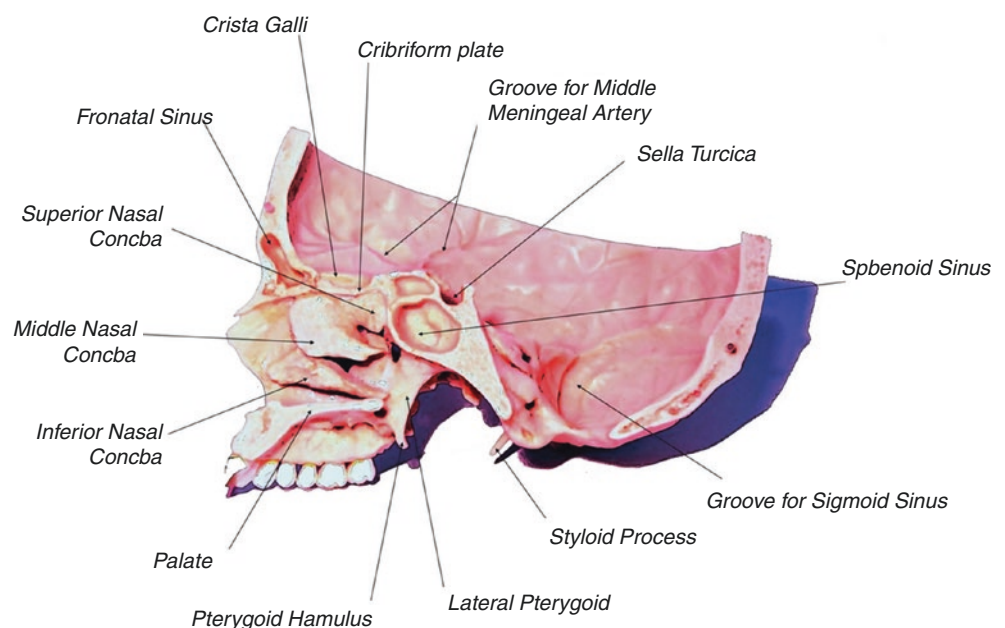
The infratemporal fossa is demarcated above by the infratemporal crest, anteriorly by the infratemporal surface of the maxilla, and behind by the articular eminence and the angular spine of the sphenoid. It is bounded above by the inferior surface of the great wing of the sphenoid and temporal squama. Medially, its floor is formed by the lateral surface of the lateral pterygoid plate, and to a lesser extent by the posterior surface of the maxilla. At its lower end can be seen the pyramidal process of the palatine bone and the pterygoid hamulus.

The infratemporal fossa houses a portion of the insertion of the temporalis muscle, the lateral pterygoid muscle, the mandibular division of the trigeminal nerve, and the maxillary vessels. The foramen ovale and the foramen spinosum open into the posterior part of the fossa. Its anterior surface also contains posterior superior alveolar foramina through which branches of the maxillary nerve and artery supply the maxillary sinus, molar teeth, and surrounding tissues. The inferior orbital fissure opens into its anterior and superior surface. This fissure meets the vertically placed pterygomaxillary fissure.

At the medial end of the pterygomaxillary fissure lies the pterygopalatine fossa. It houses the pterygopalatine (sphenopalatine) ganglion. This ganglion contains the cells with which the preganglionic parasympathetic fibers originating from the facial nerve (greater superficial petrosal, nerve of the pterygoid canal) synapse. Postganglionic fibers supply the lacrimal gland and the minor glands of the nasal, pharyngeal, and palatal mucosa. Accompanying these motor fibers are sensory fibers from the maxillary division of the trigeminal nerve, so these branches are mixed nerves. Many of the terminal branches of the maxillary artery accompany these nerves.

The fossa communicates with the orbit above and anterior through the inferior orbital fissure through which branches of the maxillary nerve and artery enter the orbit. It communicates with the nasal cavity medially through the sphenopalatine foramen, and with the infratemporal fossa through the pterygomaxillary fissure. On the posterior wall of the fossa are the foramen rotundum (through which the trunk of the maxillary nerve enters the fossa), the pterygoid canal, and pharyngeal canals. (Small vessels and nerves pass through the pharyngeal canals to innervate the superior pharynx.) Inferiorly, the fossa communicates with the palate through the greater (anterior, descending) palatine canal, which opens onto the palate through the greater palatine foramen. Parallel to the greater palatine canal, and behind it, is often a smaller canal for the lesser palatine nerve and vessels. Finally, nerves and vessels from the fossa pass inferiorly on the posterior surface of the maxilla to enter the posterior superior alveolar foramina. They subsequently travel in the lateral wall and floor of the maxillary sinus to reach the apices of the molar teeth.

**Fig. A1.6** Near midline medial view of the hemisected skull



Mixed branches of the maxillary nerve, usually accompanied by branches of the maxillary artery and vein, are distributed through these openings. The posterior superior nasal branches pass through the sphenopalatine foramen to supply the nasal cavity. A continuation of this nerve, the nasopalatine branch, descends on the nasal septum after passing across the roof of the nasal cavity and emerges onto the palate through the incisive foramen. A major nerve and artery pass through the inferior orbital fissure and enter the infraorbital canal to emerge on the face as the infraorbital nerve and artery. In the canal, they give off anterior (and often middle) superior alveolar branches that reach the anterior and premolar teeth through canals in the lateral and anterior walls of the maxillary sinus. A zygomatic branch of the maxillary nerve originates in the pterygopalatine fossa, passes into the orbit, and enters the zygoma. This nerve emerges onto the face as zygomaticotemporal and zygomaticofacial branches. (A parasympathetic component that accompanies the infraorbital and zygomatic nerves joins the lacrimal branch of the ophthalmic division of the trigeminal nerve to innervate the lacrimal gland.) Other branches of the maxillary nerve pass posteriorly through the pharyngeal canals to the pharyngeal wall, inferiorly through the greater palatine canals to supply the palate, and into the posterior superior alveolar foramina to supply the molar teeth and the surrounding tissues.

## The Mandible

The mandible consists of a major buttress extending from the condyle to the chin and three processes: alveolar, coronoid, and condylar. It can also be described as a U-shaped body with a vertical ramus on each side. The anterior end of the major buttress is thickened to form the mental protuberance. The protuberance is triangular, with its apex pointing superiorly in the midline, and its base directed toward the lower

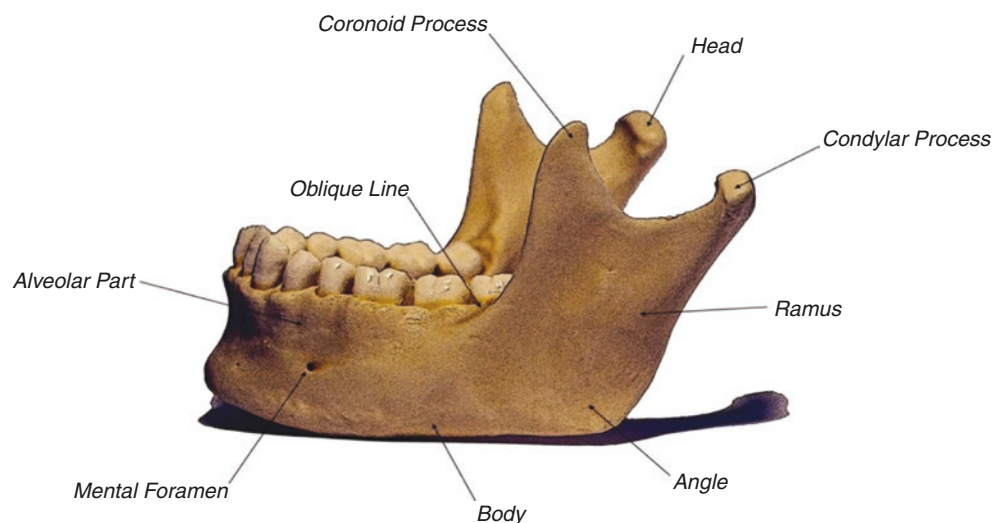
border of the mandible. At its lateral and inferior angles, the protuberance is accentuated to form mental tubercles. The symphysis is the region in which the embryonic halves of the mandible are fused. The articular condyle (the condyle and the neck of the condyle constitute the condylar process) is elongated from medial to lateral ends. The alveolar process of the mandible houses the roots of the mandibular teeth.

The mandibular (sigmoid) notch separates condylar from coronoid processes. The temporal muscle inserts on the medial and lateral aspects of the superior end of the coronoid process, and to its anterior border down to the level of the third molar. The angle of the mandible is the junction between the ramus and the body of the mandible. The is the area most frequently fractured often involving the alveolus of the third molar (Figs. A1.7 and A1.8).

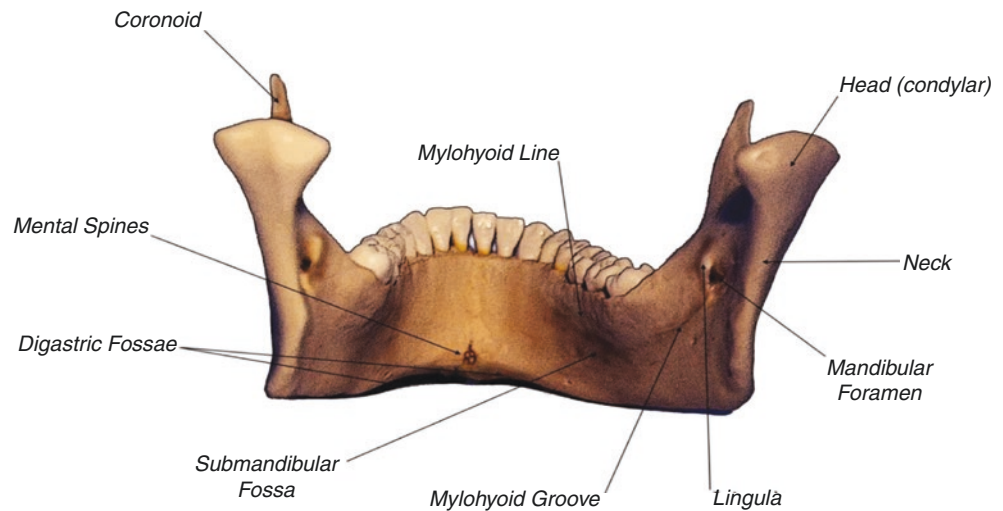
On the lateral surface of the mandible is the external oblique line (the depressor anguli oris is attached to its anterior end, the buccinator to its posterior 3/4) and the mental foramen (through which a sensory branch of the inferior alveolar nerve exits). The depressor labii inferioris and the mentalis muscles attach over the roots of the incisor teeth.

On the medial surface of the ramus, the temporal crest runs downward from the tip of the coronoid process. Behind the second or third molar is the retromolar triangle, a widening of the temporal crest. The mandibular foramen is the entrance into the mandibular canal for the inferior alveolar nerve and vessels, and the lingula, a small process of bone, anterior and superior to the foramen, to which is attached the sphenomandibular ligament. Running inferiorly and anteriorly from the mandibular foramen is the mylohyoid groove for the mylohyoid nerve and vessel. On the body of the mandible is the mylohyoid line for the origin of the mylohyoid muscle. Below it is the submandibular fossa for the submandibular salivary gland. In the midline below the incisor teeth are the mental spines (genial tubercles) for the attachment of the genioglossus and geniohyoid muscles. Below and lateral to these spines

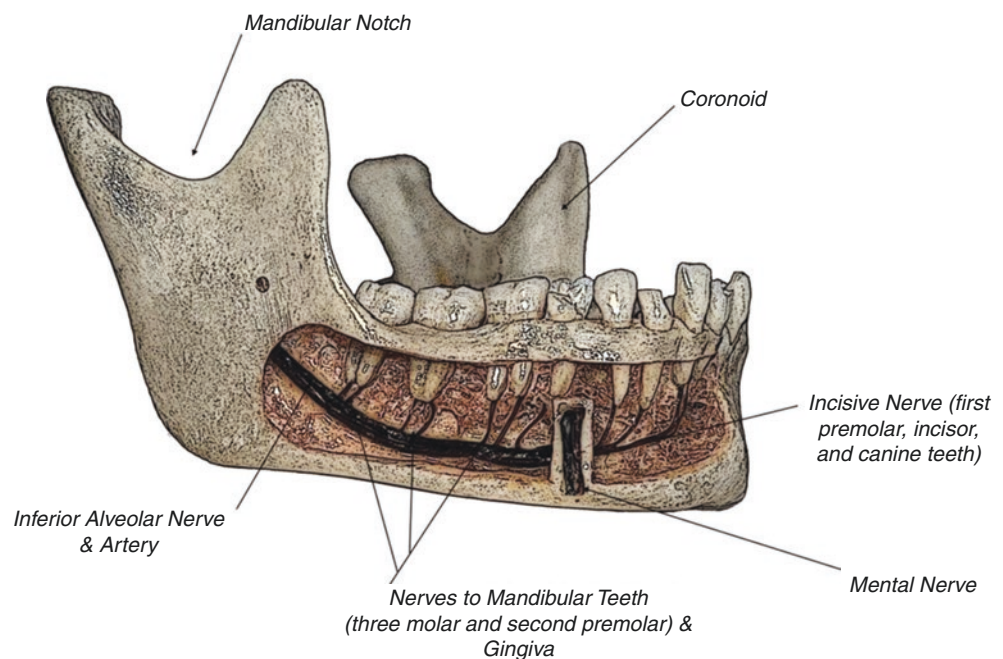
**Fig. A1.7** Mandible: lateral view



**Fig. A1.8** Mandible:  
posterior view



**Fig. A1.9** Mandible with  
outer bone removed to expose  
in inferior alveolar nerve and  
artery in the mandibular canal



is the digastric fossa for the origin of the anterior belly of the digastric muscle. (The mylohyoid muscle separates the digastric from the geniohyoid muscles.) (Fig. A1.9).

## Cervical Vertebrae

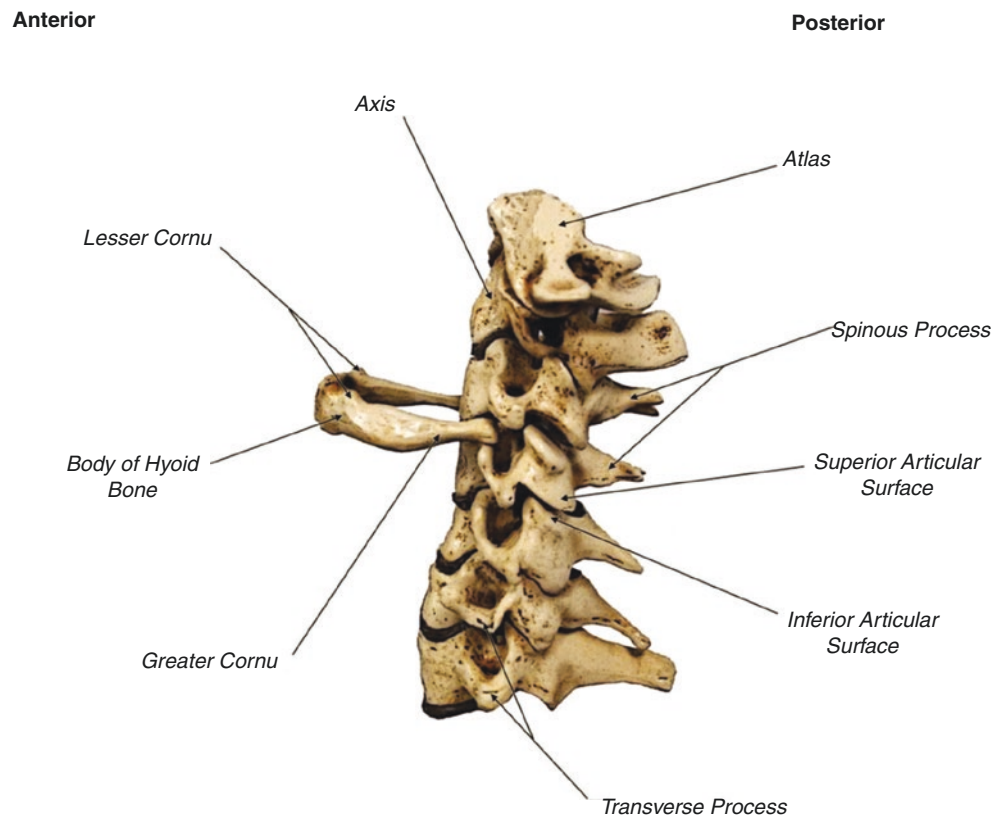
Of the seven cervical vertebrae, the first (atlas) and second (axis) are modified, while C3 through C7 are similar to each other. On each side of the body of C3 through C7, a vertebra displays a pedicle extending laterally and posteriorly. The pedicles are notched above and below to form an intervertebral foramen that transmits a spinal nerve. Projecting laterally from the pedicle and body is a transverse process

perforated by a foramen transversarium for the vertebral artery. The process ends in anterior and posterior tubercles for attachment of the muscles that rotate the neck. The vertebral artery may be torn in these foramina during a “whiplash” type of injury. While the 7th cervical vertebra has a foramen in its transverse process, the vertebral artery does not pass through it. Extending posteriorly and medially from the pedicle is a lamina that joins its mate in the midline and forms the bifid spinous process for the attachment of the ligamentum nuchae and the muscles that extend the neck. The pedicles and laminae form the vertebral arch that houses the spinal cord.

In life, the laminae are joined by ligamentum flavae, and the bodies, with the intervening fibrocartilage intervertebral



**Fig. A1.10** Lateral view:  
cervical vertebrae and hyoid  
bone



discs, are joined by anterior and posterior longitudinal ligaments. At the junction of the pedicle and the lamina are superior and inferior articular processes. Note that the joints formed by these articular surfaces face up and back.

The atlas (C1) consists of an anterior arch (it has no body), two lateral masses, and a posterior arch. Anteriorly, the anterior arch displays a tubercle for the attachment of the anterior longitudinal ligament, posteriorly, an articular facet for the dens of the axis (C2) and two tubercles for attachment of the transverse ligament that retains the dens. The posterior arch has no spine, but it does have a posterior tubercle for the attachment of the ligamentum nuchae. The posterior arch has a broad depression on its superior surface for the vertebral artery and the first cervical nerve. Each lateral mass extends laterally as a prominent transverse process, pierced by a foramen transversarium. This transverse process can be palpated in life between the angle of the mandible and the mastoid process. The superior articular facet of the lateral mass articulates with the occipital condyle; nodding motion occurs at the joint. The inferior articular facet faces medially, meeting the superior articular facet of the axis; rotational motion occurs at this joint.

The axis (C2) possesses a body, pedicles, laminae, a spine, and articular facets. The prominent dens extends upward from the body. The dens has an articular facet anteriorly,

which meets the facet on the anterior arch of the atlas. The dens is constricted for the transverse ligament. The large superior articular facet is anterior to the inferior facet, which is located at the junction of pedicle and lamina. The laminae are particularly thick, and the pedicles are notched to form intervertebral foramina. The transverse processes are small. The bifid spine is large since it is the terminal attachment for the posterior vertebral muscles; because the atlas rotates on the axis, some of these muscles do not extend beyond the axis to the skull (Fig. A1.10).

## The Hyoid Bone

The hyoid bone consists of a body and two processes, the greater and lesser horns (cornu). It is suspended from above by the suprahyoid muscles and anchored below by the infrahyoid muscles. It serves as the insertion for the stylohyoid muscle that forms a sling for the intermediate tendon of the digastric muscle. It is connected with the thyroid cartilage by the thyrohyoid membrane, with the tongue by the hyoglossus muscle, and it is the anterior attachment of the middle constrictor muscle of the pharynx. The stylohyoid ligament is attached to the lesser horn. While nine muscles attach to this bone, none cross it; its lateral and anterior surfaces are subcutaneous.

## Appendix 2

### Major Blood Vessels of the Head and Neck

This appendix describes the distribution of the major blood vessels of the head and neck. More details of the smaller vessels are provided in the specific regional chapters within the book.

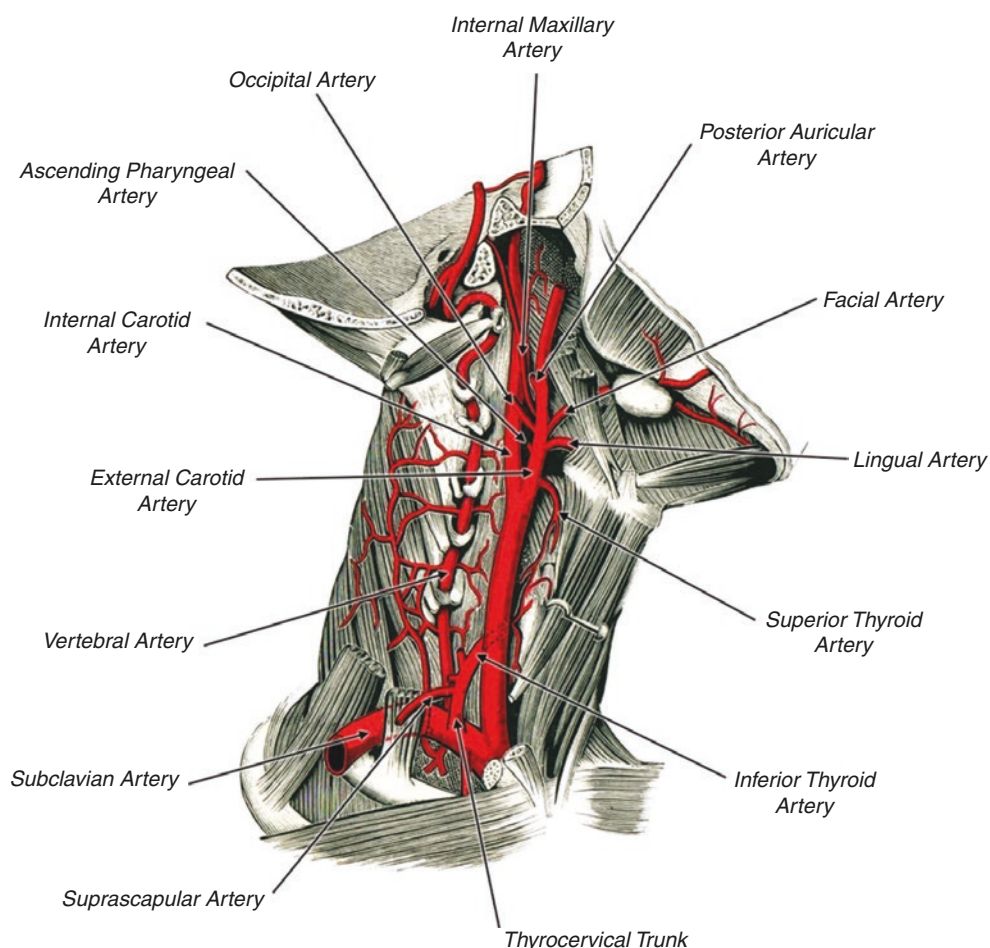
In the upper thorax, the arch of the aorta gives off three major branches. The first is the brachiocephalic (innominate) artery that divides into the right subclavian and the right

common carotid arteries. The left common carotid and the left subclavian are the second and third branches.

### Subclavian Artery

The subclavian artery (Fig. A2.1) is divided arbitrarily into three parts according to its relationship with the scalenus

**Fig. A2.1** Right side view of subclavian artery branches ascending into the neck



anterior muscle. The first part is medial to the scalenus anterior, the second part posterior, and the third part lateral.

The first part of the subclavian artery typically gives off three branches: vertebral, internal thoracic, and thyrocervical trunk. The vertebral artery ascends through the foramina transversari of the cervical vertebrae and passes through the foramen magnum to enter the cranial cavity. It supplies the spinal cord and the brain. The internal thoracic artery descends to supply muscles in the anterior thoracic wall.

The thyrocervical trunk has three branches: inferior thyroid, suprascapular, and superficial cervical. The inferior thyroid supplies the infrahyoid muscles, the thyroid gland, and the lower larynx and pharynx. The suprascapular and superficial cervical arteries supply the muscles of the shoulder.

The second part of the subclavian artery gives off the costocervical trunk that supplies muscles in the upper thoracic wall and back of the neck by way of its supreme intercostal and deep cervical branches.

The third part of the subclavian artery has a descending (dorsal) scapular branch that supplies muscles of the shoulder. This vessel may leave the thyrocervical trunk in a common origin with the superficial cervical artery. The combined vessel is then called the transverse cervical artery.

## Carotid Artery and Branches

The common carotid artery (Fig. A2.1) divides into the internal and external carotids. The internal carotid has no important branches before reaching the cranial cavity. The internal

carotid supplies the cranial contents and, by way of its ophthalmic branch, the orbital contents.

The external carotid artery (Fig. A2.2) supplies the face, most of the neck, and the exterior of the head. From below upward, it has the following major branches: superior thyroid, ascending pharyngeal, lingual, facial, occipital, and posterior auricular. The external carotid ends by dividing into superficial temporal and maxillary arteries.

The superior thyroid artery supplies the thyroid gland and the surrounding muscles. It has a superior laryngeal branch supplying the larynx.

The ascending pharyngeal artery is the smallest branch of the external carotid, and it supplies the wall of the pharynx. It sends minor branches into the tympanic cavity and through foramina in the base of the skull to supply the meninges.

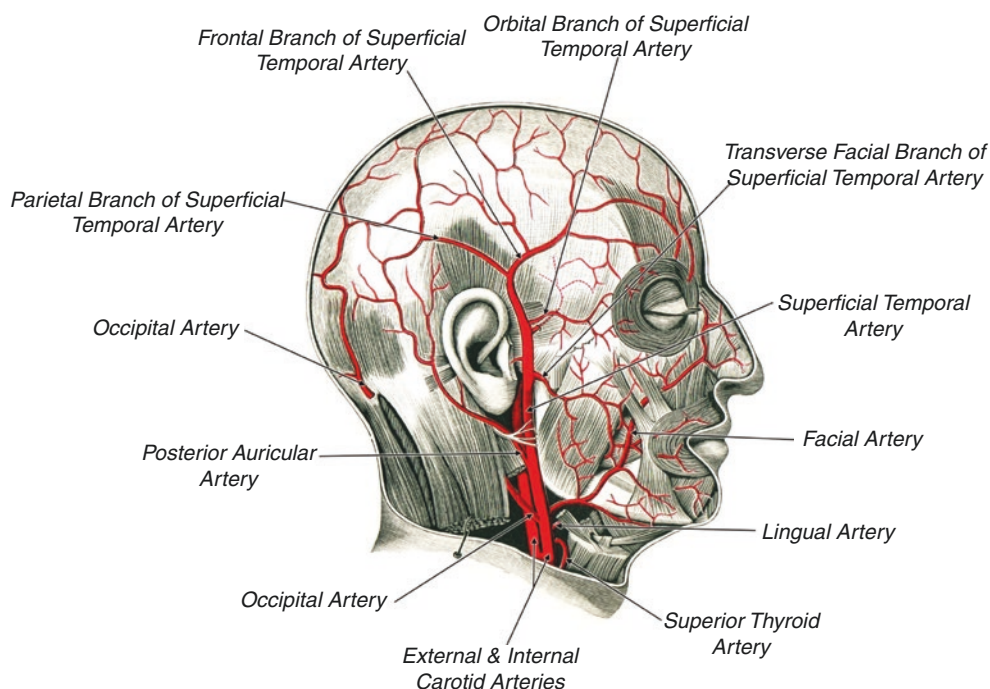
The lingual artery supplies the tongue and the floor of the mouth. It has dorsal lingual branches, which supply the dorsum of the tongue and the adjacent pharynx, a sublingual branch supplying structures in the floor of the mouth, and it ends as the deep lingual.

The facial artery has branches, which supply the wall of the pharynx in the region of the tonsils, a submental branch supplying structures in the floor of the mouth, superior and inferior labial branches to the upper and lower lips, and a number of unnamed branches supplying the muscles of facial expression.

The occipital artery supplies the posterior portion of the scalp and the adjacent muscles and the middle ear.

The posterior auricular artery is small and supplies the parotid gland and the adjacent muscles.

**Fig. A2.2** Lateral view of right side of head illustrating the carotid arteries and the superficial branches of the external carotid artery



The superficial temporal artery supplies the muscles and skin in the temporal region and the more posterior muscles of facial expression.

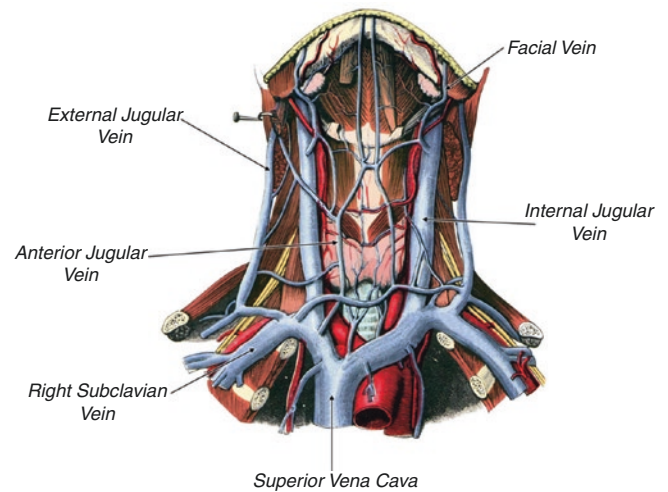
## Maxillary Artery

The maxillary artery has a large number of branches and supplies the deep structures of the face, terminating as the sphenopalatine artery. It sends branches into the middle ear, a large middle meningeal artery to supply the dura, an inferior alveolar branch to supply the lower jaw, teeth and lip, branches to the muscles of mastication, and smaller branches to the upper pharynx and the nasal cavity. The buccal branch of the maxillary artery supplies the cheek, the posterior superior alveolar branch supplies the molar teeth and surrounding structures, the infraorbital artery supplies the middle third of the face, and the greater palatine artery the palate. The infraorbital artery also sends superior alveolar branches to the upper incisor, canine and premolar teeth as well as to the surrounding soft tissues.

## Venous Drainage

The superficial face is drained by the facial vein that communicates with the orbital veins through the supraorbital and infraorbital foramina. The scalp and skin of the temporal region are drained by the superficial temporal vein. The superficial temporal and maxillary veins join to form the retromandibular vein. The retromandibular vein divides below. Its anterior limb joins the facial vein to form a common facial, which drains into the internal jugular. The posterior limb of the retromandibular vein joins the posterior auricular vein to form the external jugular vein.

The internal jugular vein (Fig. A2.3) drains the cranial contents, including the cavernous sinus that communicates



**Fig. A2.3** Anterior view of major veins of the neck

with the veins of the orbit and the veins in the infratemporal fossa. The venous sinuses of the dura also drain into the internal jugular.

For the most part, the branches of the external carotid artery are accompanied by veins with the same names. The veins are less predictable in their positions and courses, and commonly intercommunicate. Those in the infratemporal fossa form the pterygoid plexus surrounding the lateral pterygoid muscle. This plexus drains into the maxillary vein that drains into the retromandibular vein.

The external jugular vein drains into the subclavian. Just before joining the subclavian, it is joined by the anterior jugular, a small vein draining anterior structures in the neck. The internal jugular and the subclavians join to form the brachiocephalic vein. The subclavian vein is a continuation of the axillary vein. The two brachiocephalic veins join to form the superior vena cava.



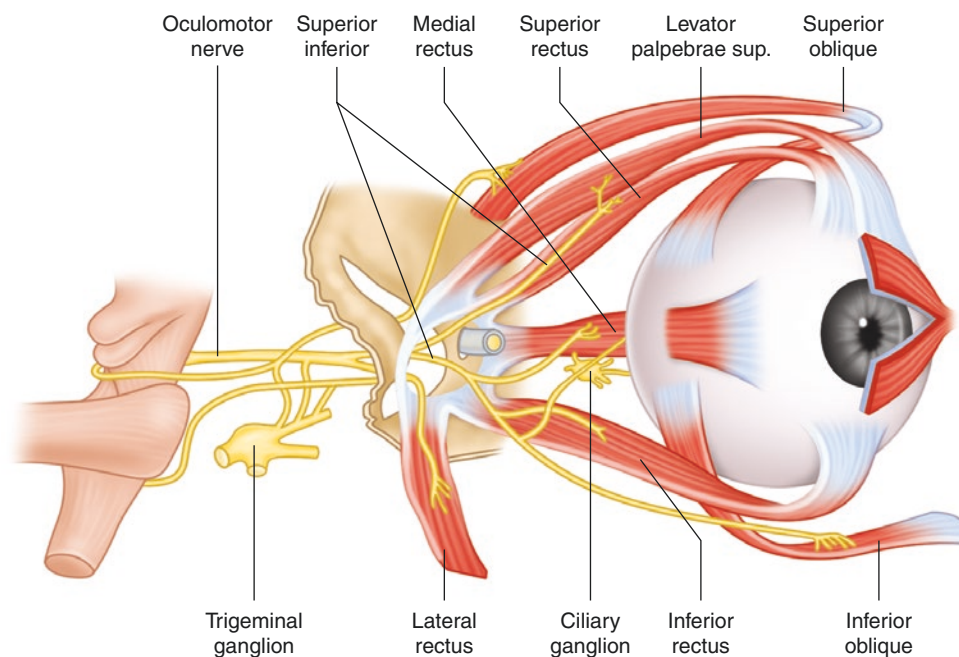
## Appendix 3

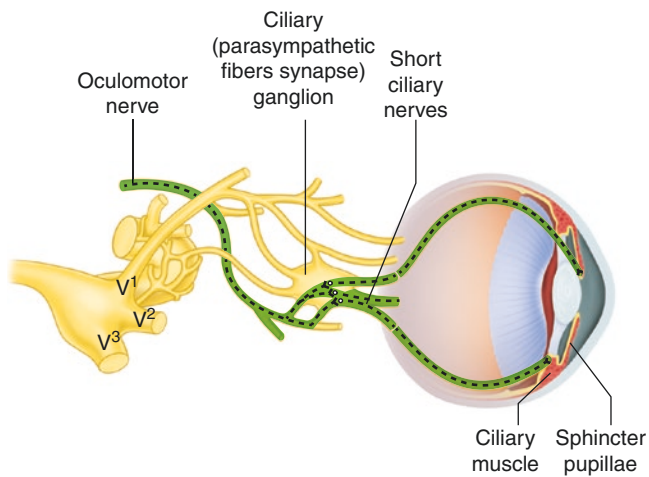
### Oculomotor Nerve (CN III)

Fibers from the oculomotor nucleus (somatic motor) supply all of the extrinsic muscles of the eye except the lateral rectus and the superior oblique (Fig. A3.1). Parasympathetic (visceral motor) fibers from the nucleus of Edinger-Westphal supply the ciliary muscles, those which relax the lens for near vision, and the constrictor muscles of the pupil (sphincter pupillae) as shown in Fig. A3.2. The oculomotor nerve passes through the wall of the cavernous sinus where it is joined by sympathetic fibers from the carotid plexus. Within the orbit, branches supply the extrinsic eye muscles. Sympathetic fibers (Fig. A2.3) continue to the dilator pupillae muscle, and other fibers join the branch to the superior palpebral muscle.

The somatic motor nucleus of CN III is located in the midbrain. The nerve fibers course through the dura mater, over the hypophysis, and through the cavernous sinus. The *oculomotor nerve* emerges from the lateral wall of the cavernous sinus and passes through the superior orbital fissure to enter the orbit. It passes between the two heads of origin of the lateral rectus muscle. It divides into upper and lower divisions. The *upper division* sends branches to the superior rectus and levator palpebrae muscles. The *lower division* sends a branch to the medial rectus muscle, a branch to the inferior rectus muscle, and a branch passing along the lateral border of the inferior rectus muscle to the inferior oblique muscle. The parasympathetic fibers of the oculomotor nerve synapse on cell bodies in the *ciliary ganglion*. The ganglion is above the lateral border of the inferior rectus muscle

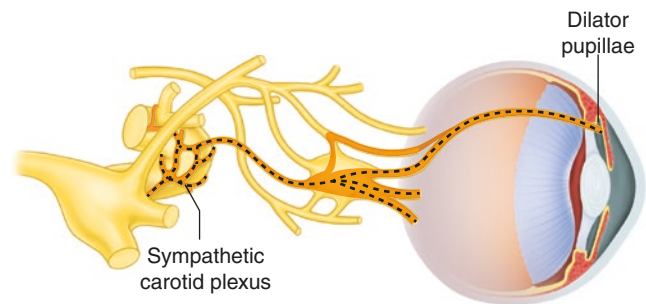
**Fig. A3.1** Lateral view of the orbit illustrating the extrinsic muscles of the eye and the oculomotor nerve





**Fig. A3.2** Pathway of parasympathetic innervation of the eye

between the lateral rectus and the optic nerve, usually on the lateral side of the ophthalmic artery, about 1 centimeter ante-



**Fig. A3.3** Pathway of sympathetic innervation of the eye

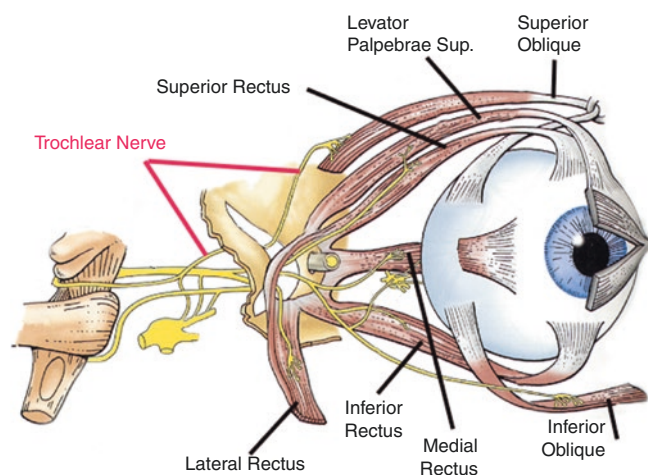
rior to the apex of the orbit. It can sometimes be identified by the presence of the delicate *short ciliary nerves* that attach it firmly to the sclera of the posterior surface of the eye. Postganglionic fibers supply the muscles of the lens and the constrictors of the pupil.

## Appendix 4

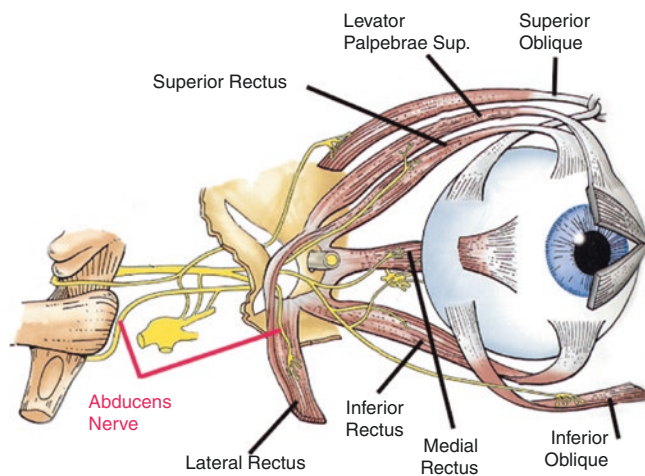
### Trochlear (CN IV) and Abducent (CN VI) Nerves

Aside from their somewhat mysterious proprioceptive components, these nerves are beautifully simple. Their cell bodies are in the trochlear and abducent (somatic motor) nuclei. Those from the trochlear nucleus (in the midbrain) supply the superior oblique muscle (Fig. A4.1). Fibers from the abducent nucleus (in the pons) innervate the lateral rectus muscle (Fig. A4.2). The trochlear nerve is the smallest cranial nerve and the only one attached to the dorsal surface of the brain stem.

The *trochlear nerve* enters the orbit through the superior orbital fissure above the origin of the lateral rectus muscle. It then passes medially above the levator palpebrae to enter the medial surface of the superior oblique muscle in its posterior third. The superior oblique is the only muscle supplied by this nerve.



**Fig. A4.1** Lateral view of the orbit showing the extrinsic muscles of the eye and the trochlear nerve



**Fig. A4.2** Lateral view of the orbit showing the extrinsic muscles of the eye and the abducent nerve

The *abducent nerve* passes through the superior orbital fissure and enters the orbit between the two heads of origin of the lateral rectus muscle. It enters the medial surface of the lateral rectus in its posterior half. The lateral rectus is the only muscle supplied by this nerve.

Muscle spindles are present in the extraocular muscles, but the proprioceptive pathways are not known.

## Appendix 5

### Trigeminal Nerve (CN V)

The trigeminal nerve has a somatic sensory component, which supplies much of the scalp, dura, face, oral and nasal cavities and associated sinuses, upper and lower jaws, teeth, and the anterior two-thirds of the tongue. The first cell bodies for the somatic sensory component are in the trigeminal (semilunar, Meckel's) ganglion, and the second cell bodies are in the main sensory or spinal nucleus of the trigeminal nerve. The trigeminal nerve also distributes special sensory fibers (taste) from the facial nerve (CN VII). In addition, the trigeminal nerve carries postganglionic parasympathetic fibers throughout the head as described below. The nerve consists of three divisions: ophthalmic (V1), maxillary (V2), and mandibular (V3). The sensory distribution of the nerve divisions is shown in Fig. A5.1. The mandibular division also

carries somatic motor fibers to the derivatives of the first pharyngeal (branchial) arch: muscles of mastication (masseter, temporalis, lateral, and medial pterygoids), anterior belly of the digastric, mylohyoid, tensor veli palatini, and tensor tympani. All three divisions have sensory branches from the meninges.

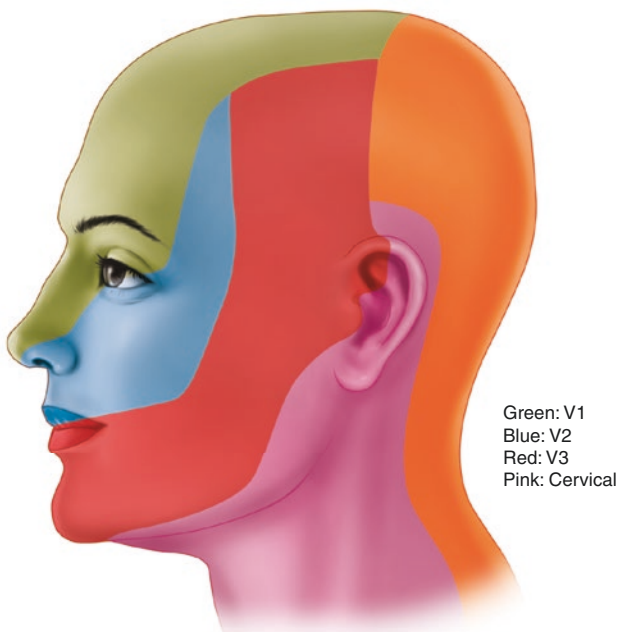
### Ophthalmic Division

The ophthalmic division of the trigeminal nerve (Fig. A5.2) is the smallest and most superior division. After leaving the lateral wall of the cavernous sinus, it divides into three branches, the lacrimal, frontal, and nasociliary nerves and passes through the superior orbital fissure into the orbit. These nerves are sensory, supplying the eyeball, conjunctiva, lacrimal gland, nasal mucosa, part of the external nose, and the skin of the upper eyelid, forehead, frontal sinus, scalp, and meninges.

The lacrimal nerve enters the orbit through the lateral end of the superior orbital fissure. It passes along the upper border of the lateral rectus muscle to the lacrimal gland. Its terminal cutaneous branch ends in the upper lid. This nerve also carries postganglionic parasympathetic fibers from the pterygopalatine ganglion to the lacrimal gland. The preganglionic fibers are from the facial nerve (CN VII) via the greater petrosal nerve.

The frontal nerve passes through the superior orbital fissure and runs anteriorly above the levator palpebrae. About halfway through the orbit, it divides into a small supratrochlear branch and a larger supraorbital branch. The supraorbital branch emerges from the orbit through the supraorbital notch or foramen beneath the frontalis muscle. It supplies the skin of the forehead and much of the scalp, and sends branches to the frontal sinus as well as to the conjunctiva of the eye.

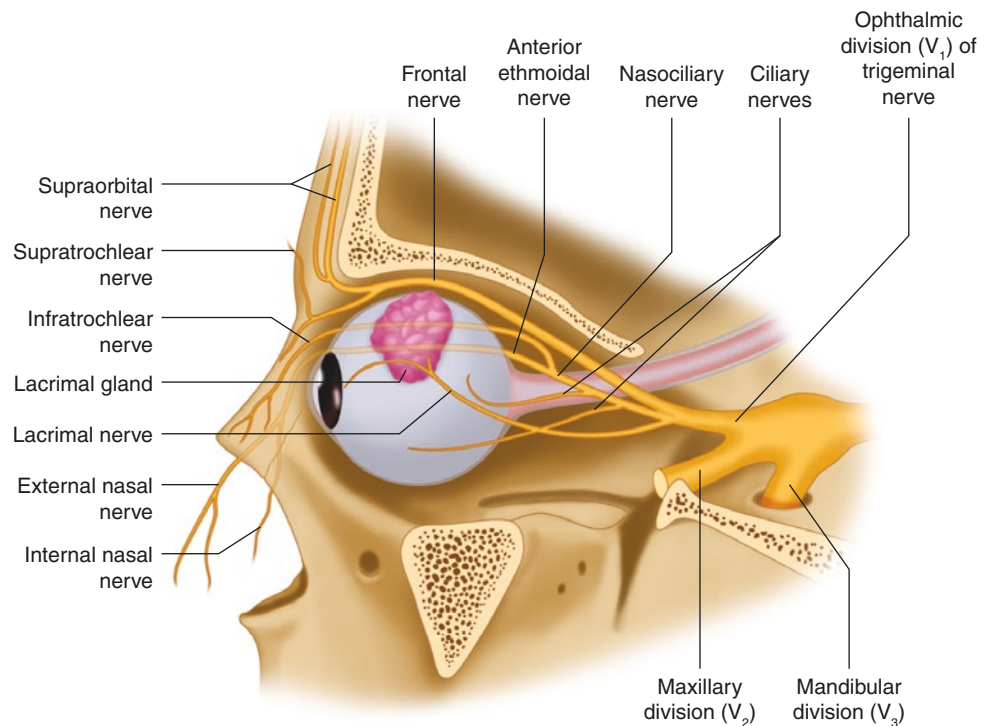
The small supratrochlear branch supplies the skin medial to the eye and sends branches to the upper lid and forehead. It also sends branches to the conjunctiva of the eye. (The superior oblique extra-ocular muscle of the orbit makes a



**Fig. A5.1** Sensory distribution of the divisions of the trigeminal nerve



**Fig. A5.2** The ophthalmic division of the trigeminal nerve (CN V)



bend in the orbit, passing through a connective tissue loop called the trochlea.) This nerve emerges above the attachment of the trochlea to the medial wall of the orbit.

The nasociliary nerve passes through the superior orbital fissure near its center. It crosses above the optic nerve from lateral to medial, and passes to the medial wall of the orbit. It ends as the very small infratrochlear cutaneous nerve. It gives off an anterior ethmoidal branch that enters the anterior ethmoidal foramen. This nerve re-enters the cranial cavity, passes along the cribriform plate, and exits the skull to enter the nasal cavity. It appears ultimately as the external nasal cutaneous branch. The small external nasal termination of the nasociliary branch of the ophthalmic division supplies the skin at the tip of the nose and the vestibule of the nose. It emerges at the lower edge of the nasal bone, between the bone and the cartilage forming the tip of the nose.

A very small posterior ethmoidal branch leaves the trunk of the nasociliary nerve to enter the posterior ethmoidal foramen. The most important branches of this nerve are a number of very fine sensory fibers (ciliary nerves) that pass to the eyeball, especially the cornea, where they are responsible for the initiation of the blink reflex.

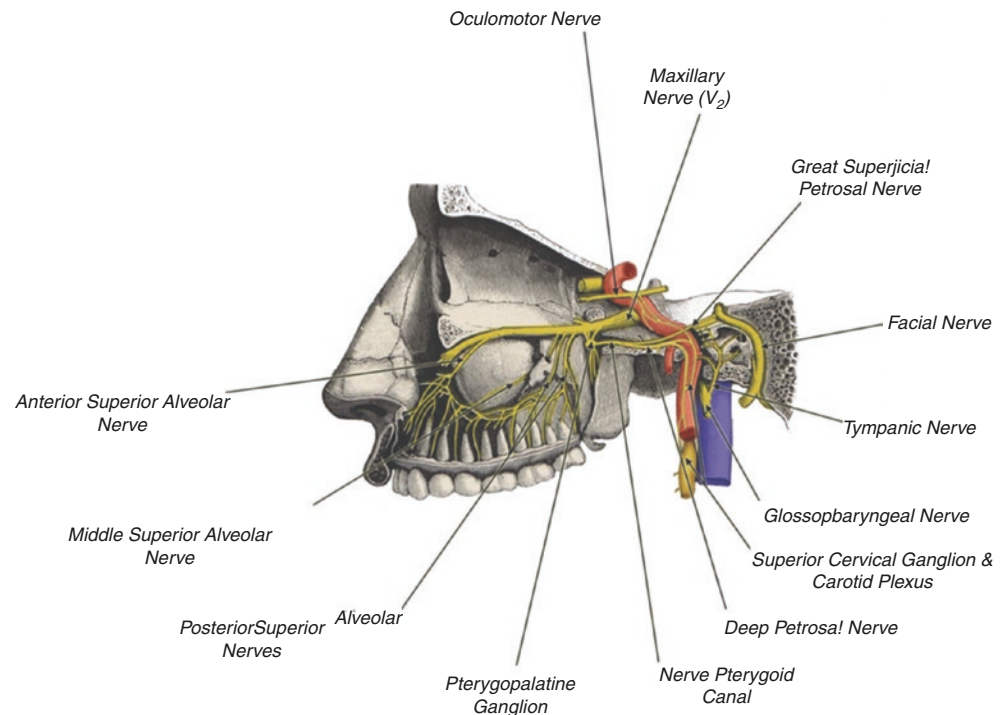
## Maxillary Division

The maxillary division of the trigeminal nerve (Fig. A5.3) supplies sensation to the midface, maxillary teeth, upper lip, maxillary gingiva, mucous membranes of the nasal cavity,

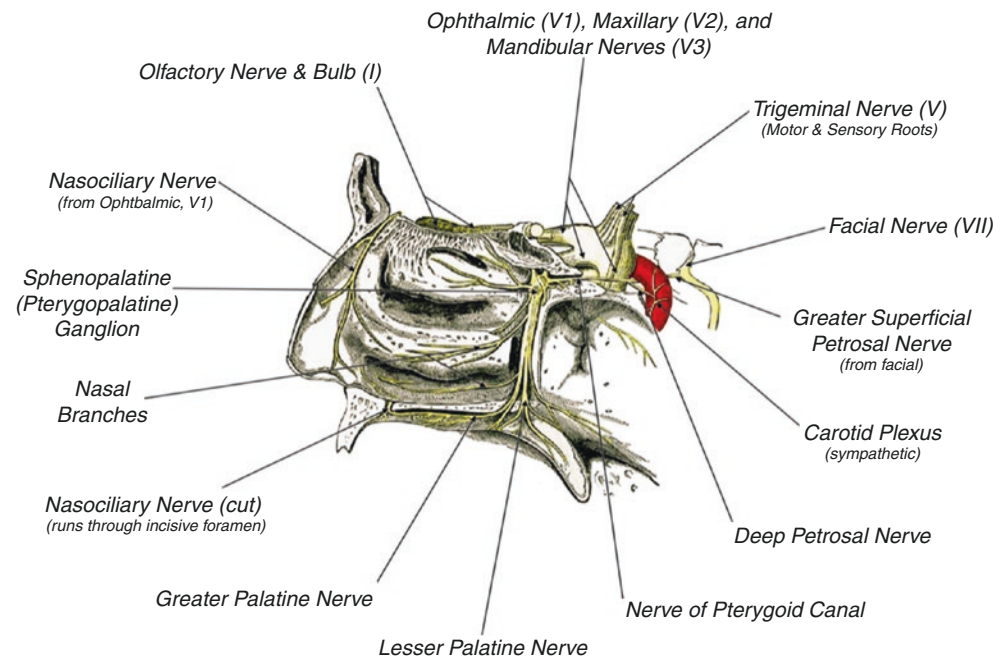
palate and roof of pharynx maxillary and sphenoidal sinuses, and meninges. The maxillary division enters the pterygopalatine fossa through foramen rotundum. The trunk of this nerve passes anteriorly through the inferior orbital fissure and infraorbital groove and canal to become the infraorbital nerve. In the orbit, it gives off the zygomatic branch that supplies the skin over the side of the face via its terminal branches, the zygomaticotemporal and zygomaticofacial nerves. In the infraorbital canal, it also gives off anterior and middle superior alveolar branches that supply the maxillary incisor, canine and premolar teeth, and facial gingival. In the pterygopalatine fossa, the maxillary nerve gives off one or more posterior superior alveolar nerves that enter the tuberosity of the maxilla through small foramina. These nerves supply the maxillary sinus and the maxillary molar teeth and facial gingival. The maxillary nerve also gives off greater and lesser palatine branches to the hard and soft palate and small branches that supply the mucous membrane of the upper pharynx and the posterior portion of the nasal cavity.

Parasympathetic fibers from the facial nerve, the greater superficial petrosal nerve, enter the pterygopalatine fossa through the pterygoid canal to synapse on cell bodies in the pterygopalatine ganglion. Postganglionic fibers from the ganglion are distributed with all the branches of the maxillary nerve to innervate the lacrimal gland and the minor salivary glands of the upper pharynx, nasal fossa, maxillary sinus, palate, upper gingiva, lip, and cheek (Figs. A5.4 and A5.5).

**Fig. A5.3** Maxillary division of the trigeminal nerve (CN V)



**Fig. A5.4** Near midline view of the distribution of the maxillary division of the trigeminal nerve



## Mandibular Division

The mandibular nerve (Fig. A5.6) is motor to the muscles of mastication, to the mylohyoid and anterior digastric muscles, to the tensor tympani in the middle ear, and to the tensor veli palatini in the soft palate. It is sensory to the lower jaw and teeth, the anterior 2/3 of the tongue, and the lower 1/3 of the face including the lower lip. As it leaves the foramen ovale,

it divides into anterior and posterior trunks. The anterior trunk sends a sensory branch to the cheek, the buccal nerve. Its other branches are motor to the masseter, temporal, and medial and lateral pterygoid muscles.

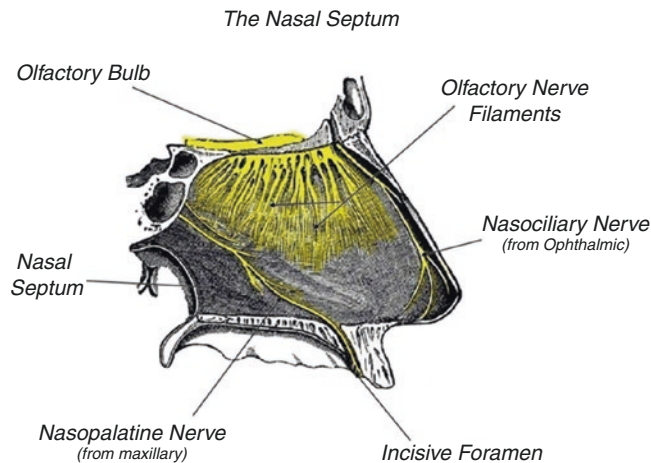
The posterior trunk gives off the auriculotemporal nerve immediately below the foramen ovale. This nerve conveys sensory fibers to the skin over the temple and to the temporomandibular joint, and it conveys parasympathetic fibers from

the otic ganglion to the parotid gland. (The otic ganglion is on the medial surface of the mandibular nerve just below foramen ovale. Parasympathetic fibers reach the otic ganglion from the glossopharyngeal nerve by way of the lesser superficial petrosal nerve.) The auriculotemporal nerve divides to embrace the middle meningeal artery, passes posteriorly medial to the neck of the mandibular condyle, and

then turns laterally and superiorly where it becomes subcutaneous anterior to the ear (Fig. A5.7).

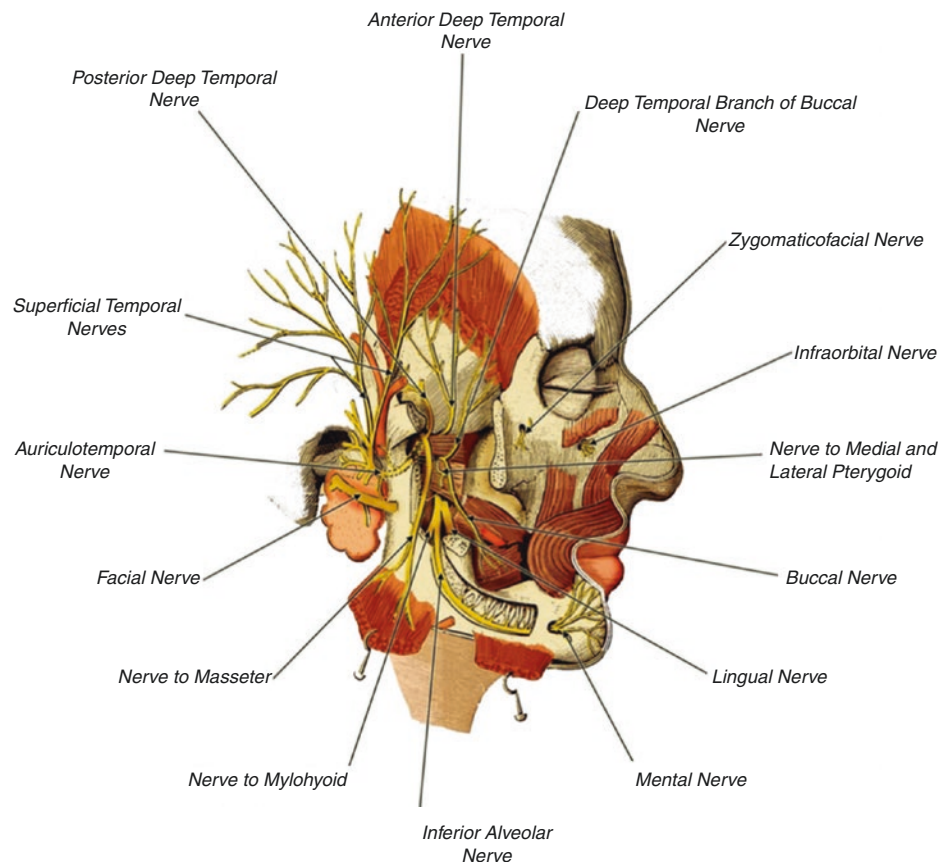
The remainder of the posterior trunk divides into the lingual and inferior alveolar nerves. The inferior alveolar nerve enters the inferior alveolar (mandibular) canal by passing through the mandibular foramen. As it enters the foramen, it gives off the mylohyoid branch. The inferior alveolar nerve continues in the bony canal, providing sensory fibers to the teeth, mandible, and gingiva. It sends a terminal branch through the mental foramen to provide sensation to the lower lip and chin. The mental branch of the mandibular division supplies the skin and oral mucous membrane of the lower lip. It emerges from the mandible through the mental foramen beneath the depressor anguli oris muscle.

The lingual nerve passes anteriorly to enter the tongue where it supplies sensory fibers, including taste, to the anterior 2/3 of the tongue. The lingual nerve is joined from behind by the chorda tympani nerve, a branch of the facial nerve that left the skull through the petrotympanic fissure in the articular fossa of the temporomandibular joint. It contains taste fibers and parasympathetic fibers. The parasympathetic fibers synapse on cell bodies in the submandibular ganglion in the floor of the mouth. Fibers from the ganglion are distributed to the major (submandibular and sublingual) and minor salivary glands of the tongue and floor of the mouth (Fig. A5.8).

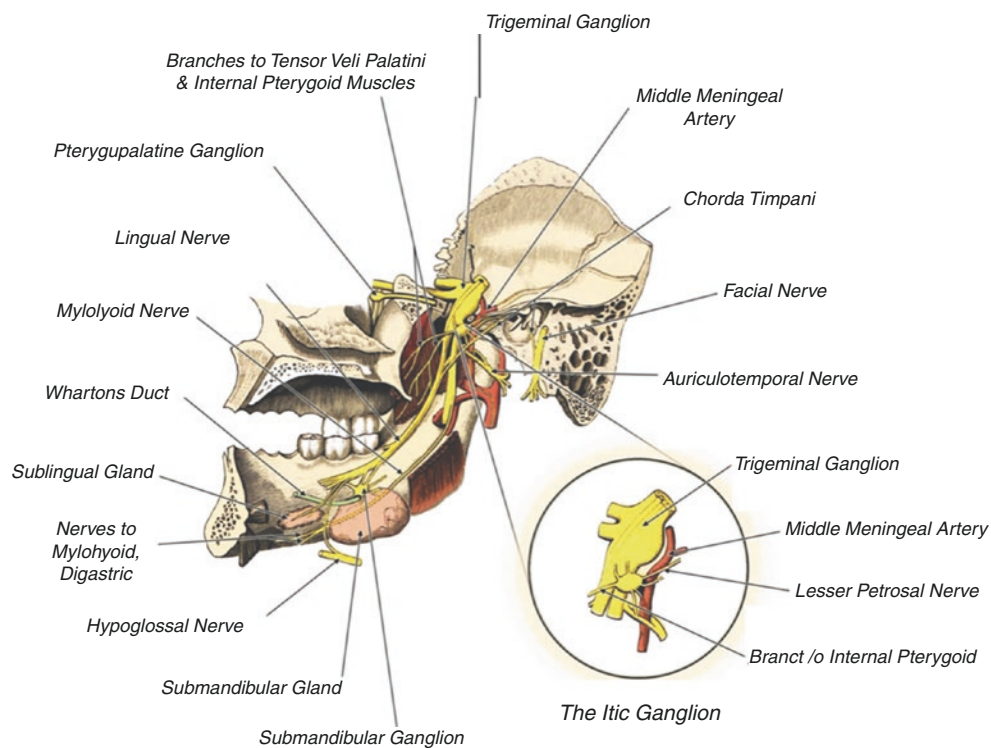


**Fig. A5.5** Midline view of nasal septum and distribution of maxillary nerve branches and the olfactory nerve (CN I)

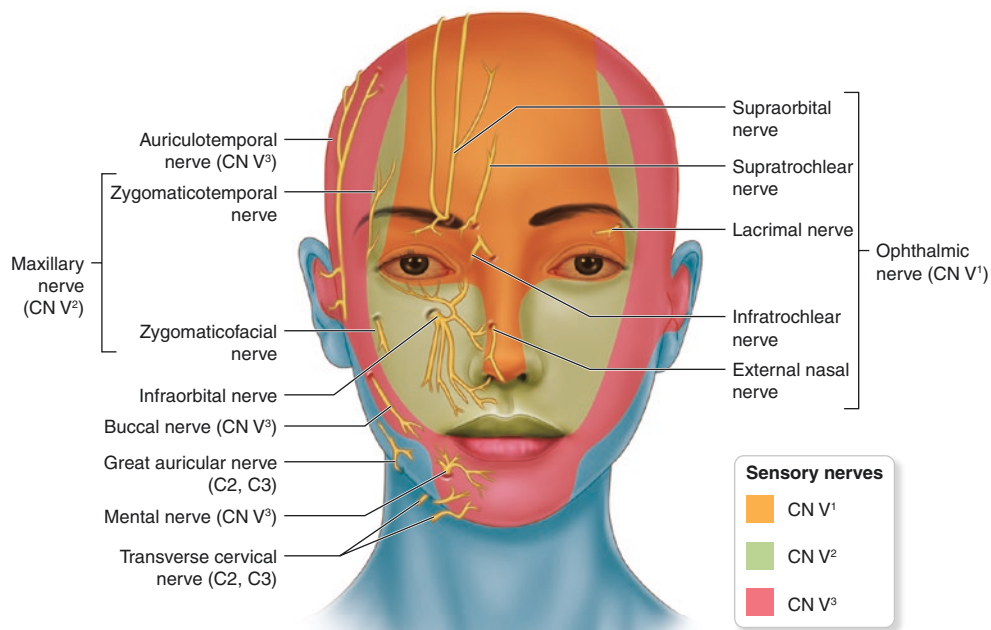
**Fig. A5.6** Lateral view of the mandibular division of the trigeminal nerve (CN V)



**Fig. A5.7** Medial view of the mandibular division of the trigeminal nerve (CN V)



**Fig. A5.8** Terminal branches of sensory nerves of the face





---

## Appendix 6

---

### Facial Nerve (CN VII)

The facial nerve (CN VII) has branchiomotor, general visceral motor (parasympathetic), somatic sensory, special sensory (taste), and proprioceptive components.

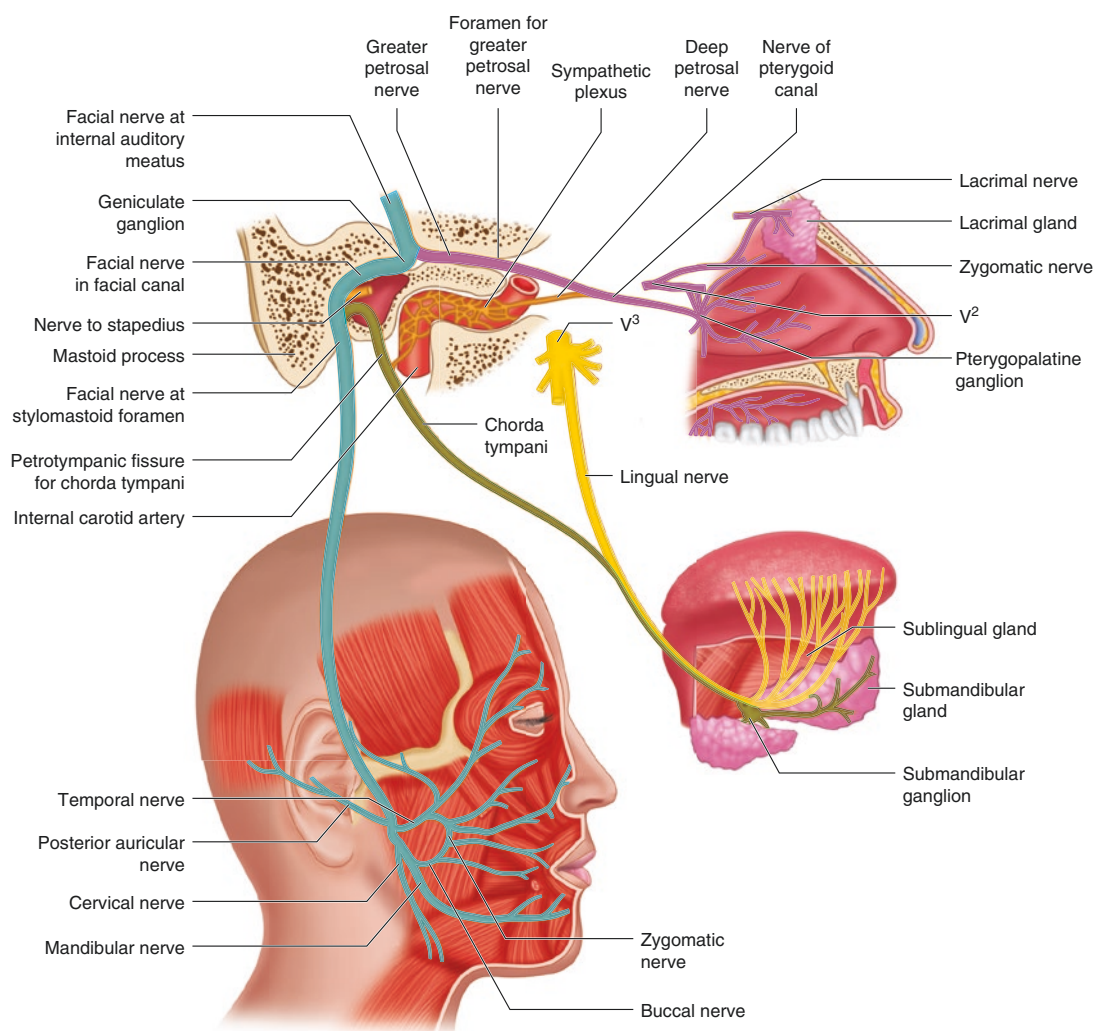
The motor neurons arise from the facial nucleus (in the pons), and supply the muscles of facial expression (including the buccinator), platysma, posterior digastric, stylohyoid, and stapedius (derivatives of the second pharyngeal arch).

The parasympathetic component has its primary neurons in the superior salivatory nucleus. Some of the preganglionic fibers leave the trunk of the facial nerve in the chorda tympani, join the lingual nerve, and synapse on secondary neurons in the submandibular ganglion. Postganglionic fibers supply the submandibular and sublingual salivary glands and the minor glands of the floor of the mouth, lower gingiva and lip, cheek, and anterior two-thirds of the tongue. Other preganglionic parasympathetic fibers leave the facial nerve as the greater superficial petrosal nerve to reach the pterygopalatine ganglion. Postganglionic fibers

are distributed to the lacrimal gland and minor salivary glands of the maxillary region with the maxillary division of the trigeminal nerve.

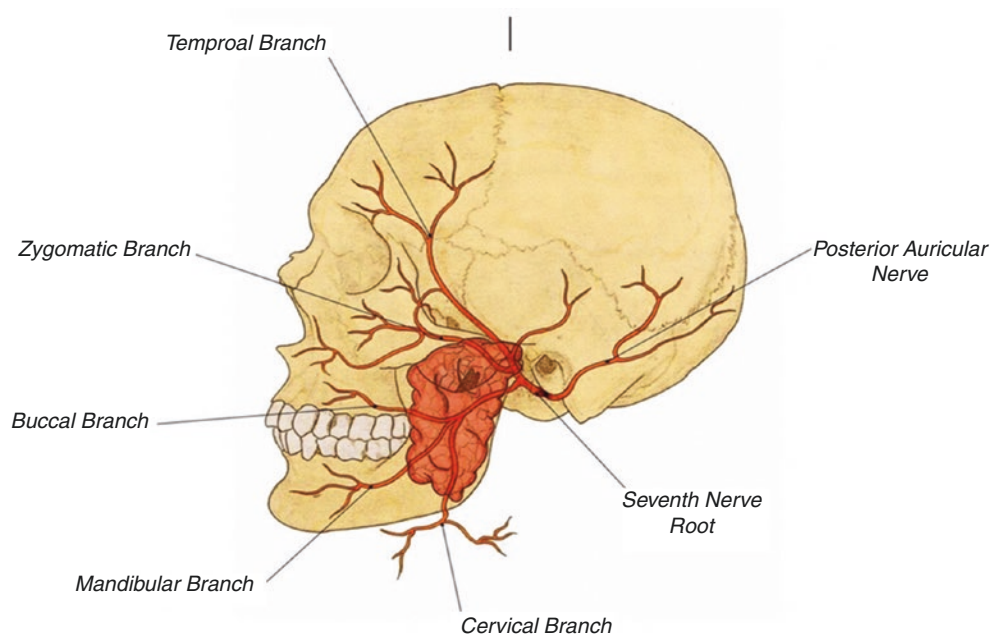
Taste fibers from the anterior two-thirds of the tongue join the lingual nerve and leave it through the chorda tympani. Other taste fibers from the soft palate reach the facial nerve through its greater superficial petrosal branch. The cell bodies are in the geniculate ganglion, and the central fibers synapse in the nucleus solitarius. The facial nerve also carries somatic sensory fibers from the concha of the auricle.

The facial nerve (Fig. A6.1) has a long course through the posterior cranial fossa, into the internal auditory meatus, through the lengthy facial canal within the skull. It leaves the skull through the stylomastoid foramen and courses for approximately 1 cm before penetrating the parotid gland. The nerve trunk (Fig. A6.2) branches into the posterior auricular, temporal, zygomatic, buccal, mandibular, and cervical branches to supply motor function to the muscles of facial expression. The facial nerve also supplies the posterior digastric, stylohyoid, and stapedius muscles.



**Fig. A6.1** Lateral view: Facial nerve distribution

**Fig. A6.2** Terminal motor branches of the facial nerve



## Appendix 7

### Cervical Plexus

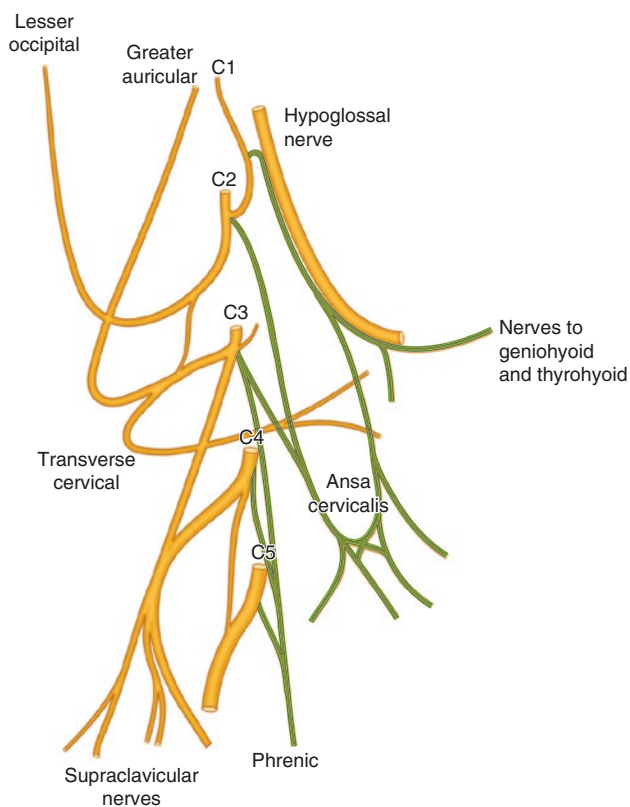
The roots of the cervical plexus are composed of the anterior (ventral) rami of C1-C5. They form a series of loops that give rise to branches that lie anterior to the levator scapulae and middle scalene muscles, covered by prevertebral fascia. Motor and sensory nerves extend from these nerve loops (Fig. A7.1).

The rami arising from C2, C3, and C4 divide into ascending and descending fibers. These combine with

fibers from neighboring rami to create loops. The superficial, posteriorly directed fibers are sensory. The lesser occipital nerve courses superiorly over the posterior border of the sternocleidomastoid muscle and supplies the skin of the posterolateral scalp and the superior portion of the external ear. The great auricular nerve travels superiorly over the sternocleidomastoid muscle behind the external jugular vein and supplies the skin over the parotid gland, over the mastoid process, skin from the mastoid process to the angle of the mandible, and the external ear. The transverse cutaneous nerve courses on top of the sternocleidomastoid muscle, divides into ascending and descending branches, and supplies the skin of the anterior neck from the chin to the sternum. The supraclavicular nerves supply the skin of the back, shoulder, and chest down to the level of the second rib. These nerves emerge from under the sternocleidomastoid muscle near its midpoint (Fig. A7.2).

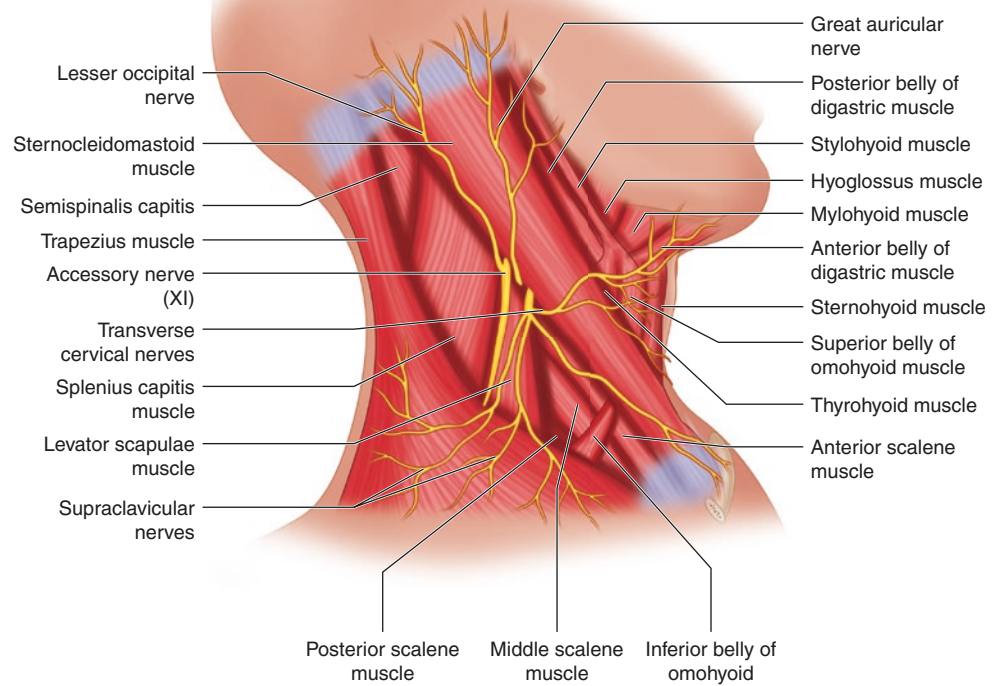
Fibers from the upper cervical spinal nerves accompany the hypoglossal nerve to form the ansa cervicalis. These fibers join the hypoglossal nerve as it leaves the hypoglossal canal, travel with it a short distance, and leave the nerve to form the superior limb of the ansa cervicalis. This limb is joined by other fibers from the upper cervical segments (inferior limb) to form the ansa. The ansa gives rise to motor fibers supplying the infrahyoid muscles (omohyoid, sternohyoid, and sternothyroid). The fibers to the thyrohyoid and geniohyoid muscles leave the hypoglossal nerve as a separate branch rather than joining the fibers to the ansa. Several of the branches from the ansa are illustrated in Fig. A7.1.

The cervical plexus also gives rise to the phrenic nerve with contributions from C3, C4, and C5 that innervates the diaphragm. This nerve is mixed with motor, sensory, and sympathetic fibers. It courses across the top of the anterior scalene muscle deep to the transverse cervical and supraclavicular arteries and beneath the deep cervical fascia. The C5 contribution may arise as a separate accessory phrenic nerve, which joins the phrenic nerve as it descends.



**Fig. A7.1** Lateral view of cervical plexus

**Fig. A7.2** *Lateral neck:*  
lateral muscles and external  
branches of the cervical  
plexus





---

## Appendix 8

---

### Glossopharyngeal Nerve (CN IX)

While the glossopharyngeal nerve has branchiomotor (to stylopharyngeus muscle), general visceral motor (parasympathetic), visceral sensory (from the tongue and pharynx), a minor somatic sensory component (from the tongue and pharynx), and special visceral sensory (taste) components, the only nucleus it can call its own is the inferior salivatory, and even those fibers are ultimately distributed with the trigeminal nerve.

Motor fibers from the nucleus ambiguus (branchial motor) join the glossopharyngeal nerve to supply only the stylopharyngeus muscle.

Preganglionic parasympathetic fibers from primary neurons in the inferior salivatory nucleus join the glossopharyn-

geal nerve, but leave it again as its lesser superficial petrosal branch. These fibers synapse on neurons in the otic ganglion, and postganglionic fibers reach the parotid gland with the auriculotemporal nerve.

Visceral sensory fibers from the posterior third of the tongue and the pharynx are conducted to a ganglion on the glossopharyngeal nerve below the jugular foramen. The central fibers reach the nucleus solitarius. Taste fibers from the posterior third of the tongue also have cell bodies in the ganglion below the jugular foramen, and their central fibers also reach the nucleus solitarius.

The glossopharyngeal nerve also contains a small somatic sensory component from the posterior third of the tongue and the adjacent pharynx with central connections in the spinal nucleus of the trigeminal nerve.

---

## Appendix 9

---

### Vagus Nerve (CN X)

The major component of the vagus nerve consists of visceral motor (parasympathetic) fibers from cell bodies in the dorsal motor nucleus of the vagus nerve. Through pharyngeal, laryngeal, thoracic, and abdominal branches, these fibers supply the glands and involuntary muscles of the respiratory system including the larynx and trachea, the heart, and the digestive system including the pharynx and esophagus. Unnamed parasympathetic ganglia for these pathways are found in the walls of the organs supplied.

The vagus nerve also contains visceral afferent fibers from the same organs, including the pharynx and larynx below the epiglottis and from the carotid body. By way of the recurrent laryngeal nerve, the internal laryngeal branch of the superior laryngeal nerve, and thoracic and abdominal branches, they reach cell bodies located in two ganglia within and just below the jugular foramen and subsequently the nucleus solitarius. The internal laryngeal nerve contains the fibers of general visceral sensation from the region between

the epiglottis and the vocal folds. The recurrent laryngeal nerve contains afferent fibers from the larynx below the vocal folds.

The vagus nerve also contains some special visceral afferent fibers (taste) from the epiglottis (internal laryngeal nerve), and some somatic sensory fibers from the external surface of the tympanic membrane (auricular branch). Sensory fibers from the tympanic membrane are of little significance except that syringing the ear will occasionally cause coughing or vomiting.

Branchial motor fibers supply the constrictor muscles of the pharynx, the muscles of the soft palate, and the intrinsic muscles of the larynx. The fibers leave the brain stem with the accessory nerve, join the vagus, and subsequently become incorporated into 1) the pharyngeal branch of the vagus supplying muscles of the pharynx and soft palate (except for the tensor palatini and the stylopharyngeus); 2) the superior laryngeal nerve, then its external laryngeal branch supplying the cricothyroid muscle; and 3) the recurrent laryngeal nerve supplying the remaining intrinsic muscles of the larynx.

---

## Appendix 10

---

### Hypoglossal Nerve (CN XII)

This nerve has one nucleus and takes a forthright course to its destination. Fibers from the hypoglossal nucleus (somatic motor) innervate the extrinsic and intrinsic muscles of the tongue, except the palatoglossus, which is embryologically a muscle of the palate supplied by the vagus nerve.

The hypoglossal is joined, after it leaves the skull through the hypoglossal canal, by fibers from the ventral rami of the

first and second cervical nerves. These fibers subsequently leave the hypoglossal nerve and descend to form a loop with descending fibers from the ventral rami of the second and third cervical nerves. The loop is the ansa cervicalis, and fibers from it innervate all of the muscles joining the clavicle to thyroid cartilage to hyoid bone to mandible, except the digastric (trigeminal and facial nerves) and mylohyoid (trigeminal nerve). These “strap muscles” are the omohyoid, sternothyroid, sternohyoid, thyrohyoid, and geniohyoid.

---

# Index

## A

Abducent nerve, 231  
Accessory mandibular nerve blocks, 29, 30  
Accessory nerve, 101  
Acidified vasoconstrictor-containing local anesthetics, 9  
Acquired methemoglobinemia, 54, 55  
Acrochordons, 72  
Afferent sensory fibers, 51  
Aging, 71, 177  
Akinosi nerve block, 28, 29  
*Alaëque Nasi*, 111  
Albuterol, 140  
Allergan, 127  
Allergy to local anesthetics, 55  
Alloplastic augmentation, 195, 196  
Alopecia, 163  
Alveolar nerve injection., 58  
Anagen, 68  
Androgenic alopecia, 205, 207  
Angular artery, 76  
Ansacervicalis, 42, 43  
Anterior auricular artery, 87  
Anterior scalene muscle, 97  
Anterior superior alveolar nerve block, 35  
Anterior triangle, 98  
Antibacterial soap, 158  
Antimicrobial peptide dermcidin, 69  
Apocrine sweat glands, 70  
Aponeurosis (Galea), 70  
Arrector pili, 69  
Arterial supply to the external nose, 81  
Articaine solutions, 11  
Articular disc, 119  
Articular fossa, 118–119  
Arytenoid cartilages, 96  
Auricle, 86, 87  
    aligns, 186  
    anatomy of, 184–186  
    extrinsic muscles of, 86  
Auriculocephalic angle, 186  
Auriculotemporal and buccal nerves, 36, 112  
Auriculotemporal nerve, 35, 37, 86, 88, 155

## B

Base-loading dental syringes, 17  
Benign neoplasms, 72  
Benzocaine, 8  
Benzocaine-associated methemoglobinemia, 54  
Bilateral sagittal split osteotomy, 193  
Bilateral superior lateral nasal cartilage, 79

Blepharoplasty, 175  
    anatomical consideration, 175, 177  
    anesthesia, 177  
    complications  
        blepharoptosis, 180  
        infection, 180  
        lid malposition, 180  
        retrobulbar hemorrhage, 179  
    indications, 177  
    lower lid blepharoplasty, 177, 179  
    patient evaluation, 177  
    postoperative care, 179  
    upper lid blepharoplasty, 177, 178  
Blepharoptosis, 180  
Blood supply, perioral region, 94  
Bony junctions, 150  
Botox, 123  
    BTX-A and BTX-B production, 124  
    BTX-A treatment, adverse effects of, 124, 125  
    complications, 129  
    Crow's feet/periorbital rhytids, 127  
    dilution technique, 124  
    glabella, 127, 128  
    indications/contraindications/adverse events, 124  
    injection technique  
        anatomic sites and general dosage ranges, 125, 126  
        dosing, 125  
        longevity of effect, 127  
        posttreatment instructions, 126, 127  
        non-cosmetic indications, 128, 129  
        patient evaluation, 127  
        pharmacology, 123, 124  
Botulinum toxin, 123  
Brachiocephalic vein, 106  
Brow lift, *see* Forehead and eyebrow lift techniques  
Brow ptosis, 149, 150  
Buccal branch, 113, 114  
Buccal fat pad, 170  
Buccal nerve, 35, 93  
Buccinator muscle, 93, 111  
Bulb, 68  
Bunny lines, 126  
Bupivacaine, 12

## C

Calcium hydroxyapatite (CaHA), 134, 196  
Capsulopalpebral fascia, 176  
Carotid artery, 106  
Carotid sheath, 100  
Cartilage-cutting techniques, 187, 188



Cartilage-sparing techniques, 187  
 Catagen, 68  
 Catechol-O-methyltransferase (COMT), 11  
 Cavernous sinus, 76  
 Cell's dendritic processes, 67  
 Cervical branch, 114  
 Cervical nerves, 101  
 Cervical plexus, 41, 42, 101, 241, 242  
 Cervical sympathetic trunk, 103  
 Cervical vertebra transverse processes, 42  
 Cervical vertebrae, 222, 223  
 Cervicomentale angle, 199  
 Chassaignac's tubercle, 43  
 Cheek augmentation, 136  
 Chemical brow lift, 125–126  
 Chin, 138  
 Chin augmentation  
   alloplastic augmentation, 195, 196  
   anatomy, 191, 192  
   anesthesia, 192  
   osseous augmentation, 192–194  
   postoperative management, 197  
   preoperative assessment, 192  
   soft tissue filler augmentation, 196  
 Chondrolaryngoplasty, 50  
 Chongchet and stenstroem techniques, 188  
 Ciliary body muscles, 76  
 Ciliary glands, 73  
 Clear cells, 69  
 CO<sub>2</sub> laser, 179  
 Coban® or Ace type wraps, 162  
 Cocaine, 8  
 Compound melanocytic nevus, 72  
 Compound nevus, 72  
 Concha, 86  
 Conchomastoid, 187  
 Conchoscaphoid, 187  
 Conjunctival sacs, 73  
 Contact dermatitis, 148  
*Corrugator supercili*, 75, 111, 153, 157  
 Cosmetic otoplasty, 183  
 Costocervical trunk, 106  
 Cricoid cartilage, 95  
 Cricothyroidotomy, 95, 96  
 Crow's feet, 127  
 Cystic fibrosis transmembrane regulator (CFTR), 70  
 Cytocrine secretion, 67

## D

Dark cell, 69  
 Dark skin, 67  
 Davis otoplasty, 189  
 Davis procedure, 188  
 Deep cervical fascia, 100  
 Dental cartridges, 17  
 Deoxycholic acid, 197  
 Depressor anguli oris, 111, 126  
 Depressor labii inferioris, 111  
 Depressor supercili, 153  
 Dermal papilla, 67, 68  
 Dermis, 67, 68, 71  
 Descending scapular artery, 106  
 Desmarres retractor, 179  
 Desmosomes, 66  
 Desquamation, 65

Diffuse unpatterned alopecia (DUPA), 206  
 Donor strip, slivering of, 210  
 Dorsal nasal artery, 76  
 Dysport, 123

## E

Ear  
   concept of field block, 37, 38  
   cutaneous innervation, 37  
 Eccrine sweat glands, 69, 70  
   coiled secretory segment, 69  
   duct segment, 69  
 Elastic cartilage, 86  
 Elastomeric infusion pumps, 13  
 Electrocautery, 179  
 Encapsulated sensory receptors, 71  
 Endoscopic forehead and brow lift technique, 150, 158–162  
 Endoscopy, 149, 158, 185  
 Epiboly, 144  
 Epidermal appendages, 68–70  
 Epidermal derivatives (epidermal appendages), 68–70  
 Epidermal ridges/rete pegs, 67  
 Epidermis  
   keratinocytes, 66  
   keratohyalin granules, 66  
   lamellar bodies, 66  
   Langerhans' cells, 67  
   layers, 66  
   melanocytes, 66  
   Merkel's cells, 67  
   stratum basale, 66  
   stratum granulosum, 66  
   stratum spinosum, 66  
 Epiglottis, 96  
 Epinephrine, 11, 140  
   catecholamine neurotransmitter, 10  
   concentrations, 10  
   maximum dosing, 10  
   vasoconstrictive impact, 10  
 Epithelial Na<sup>+</sup>channel (ENaC), 70  
 Er:YAG lasers, 144  
 Ethmoid air cells, 83  
 Ethmoidal infundibulum, 83  
 Eumelanin, 67  
 Eutectic formulations, 8  
 Evolus, 124  
 Exparel®, 13, 14  
 External auditory canal, 86, 88  
 External carotid artery, 115  
 External ear, 86, 183  
   arterial distribution, 87  
   auricle, 86, 87  
   auricle, extrinsic muscles of, 86  
   external auditory canal, 88  
   lateral view, 86  
   sensory nerves of, 87  
   temporal bone, lateral surface of, 88  
   tympanic membrane, 89  
 External jugular, 106  
 External nasal nerve, 31, 112  
 Eyeball, 73  
 Eyebrow lift techniques, *see* Forehead and eyebrow lift techniques  
 Eyelashes, 73  
 Eyelids, 73

**F**

- Facelift, 167
  - anatomy, 109
    - anatomic considerations, 170, 171
    - anatomic layers, 167
    - facial nerve and muscle innervation, 167, 168
    - muscles and ligaments, 169
    - retaining ligaments, 170
    - vascular supply, 169, 170
    - venous drainage, 170
  - techniques, 171–173
- Facial artery, 94, 106, 114, 138, 169
- Facial cosmetic surgeon
  - facial anatomy, 131, 132
  - lower face, 134
  - materials, 134, 135
  - midface, 132, 133
  - techniques, 135
    - cheek, 136
    - chin/jaw, 138
    - complications, 138–140
    - nasolabial fold, 137
    - nose, 136
    - periorbital, 136
  - upper face, 132, 133
- Facial expression, 109–115
- Facial fillers, 134
- Facial nerve, 37, 78, 101–102, 109, 239, 240
  - frontal/temporal branch of, 156
  - and muscle innervation, 167, 168
  - paralysis, 58
- Facial resurfacing
  - pre-procedure considerations, 145, 146
  - procedural technique, 146, 147
  - rehabilitation and recovery, 147, 148
- Facial rhytids, 123
- Facial symmetry, 191
- Facial vein, 76, 94, 106
- Filaggrin, 66
- Follicular bulge, 69
- Follicular unit transplantation (FUT), 205, 208, 209
  - recipient site preparation, 211
  - follicular unit extraction for, 210, 211
- Forehead and eyebrow lift techniques
  - anatomic and esthetic considerations, 150
  - bone anatomy, 150–152
  - complications, 162, 163
  - endoscopic anatomy, 156–158
  - endoscopic forehead and brow lift technique, 158–162
  - endoscopy, 149
  - muscle and fascial anatomy, 152, 153
  - postoperative care, 162
  - rejuvenation of upper third of face, 149
  - vessel and nerve anatomy, 154–156
- Forehead depressor muscles, 153
- Fractional photothermolysis, 143
- Free nerve endings, 70
- Frontal sinuses, 83
- Frontalis muscle, 125, 169
- Frontalis muscle belly of the occipitofrontalis muscle, 75
- Fronto-zygomatic suture line, 151
- Furnas technique, 187

**G**

- Galeal fascia, 152
- Genioplasty, 191–193, 197
- Glabella, vertical rhytids in, 160

- Glabellar region muscles, 75
- Glands of Moll, 70
- Glossopharyngeal nerve, 243
- Gow-Gates mandibular nerve block, 27, 28
- Gow-Gates technique for mandibular anesthesia, 57
- Graft harvest, 208
- Great auricular nerve, 31, 37, 87, 113, 170
- Greater palatine foramen, 20
- Greater palatine nerve, 20, 21

**H**

- Hair follicles, 65, 68, 69
  - hair restoration, 208
  - structure, 68
- Hair restoration
  - follicular unit transplantation, 209
  - follicular unit extraction for, 210, 211
  - recipient site preparation, 211
  - hair follicle, 208
  - history of procedure, 205
  - procedure and anatomical consideration
    - graft harvest, 208
    - graft placement, 209
  - scalp, 208
  - surgery
    - contraindications, 207
    - indications, 205, 207
- Hair restoration surgery, 214
- Helix, 86
- Holocrine mechanism, 70
- Hyaluronic acid (HA), 134
- Hyoid bone, 95, 223
- Hypoglossal nerve, 103–105, 247
- Hypotonic sweat, 70

**I**

- Incisive foramen, 219
- Incisive nerve block, 29, 30
- Infraorbital branch, 112
- Infraorbital nerves, 114
- Inferior labial branches, 114
- Inferior thyroid artery, 104
- Infections, blepharoplasty, 180
- Inferior alveolar nerve block (IANB), 26, 27, 47
- Inferozygomatic approach, 34
- Infracoroid muscles, 98, 99
- Infraorbital nerve block, 19, 20, 33, 35, 93
- Infratemporal fossa, 220
- Infratrochlear branch of nasociliary branch, 112
- Infratrochlear nerve, 31
- Infrazygomatic approach to maxillary nerve blockade, 34, 36
- Injection techniques, 17
- Internal jugular vein, 106
- Internal thoracic artery, 104
- Integumentary system, skin, 65
- Interdigitation of the dermal papillae, 67
- Intraoral maxillary local anesthesia injections, 17
- Intraoral sliding osseous genioplasty, 192
- Intraosseous anesthesia, 30
- Intravascular injection, 26

**J**

- Jaw, 138
- Jeuveau, 123, 124
- Junctional nevus, 72

**K**

Keratinization, 66  
 Keratinocytes, 65  
 Keratohyalin granules, 66  
 Kovanaze™, 14

**L**

Labiomental groove, 92  
 Lacrimal branch, 112  
 Lacrimal apparatus, 74  
 Lacrimal nerve, 31, 78  
 Lacrimal gland, 73  
 Lamellar bodies, 66  
 Langer's lines, 68  
 Langerhans' cells, 67  
 Larynx, anatomy, 50, 51  
 Lasers, 143, 144  
 Lateral nasal artery, 76, 114  
 Lateral pterygoid, 117, 118  
 Left temporal-forehead region, 160  
 Lesser occipital nerve, 185  
 Levator anguli oris, 92, 111  
 Levator aponeurosis, 176  
 Levator labii superioris, 111, 132  
 Levator labii superioris alaeque nasi, 92  
 Levator Palpebrae, 75–76  
 Levator scapulae muscle, 97  
 Levonordefrin, 10, 11  
 Lid malposition, 180  
 Lidocaine, 11  
 Light sedation, 41  
 Lingual artery, 106  
 Lingual nerve, 47  
 Lip injections, 139  
 Liposomal encapsulation of local anesthetics, 13  
 Liposomal-encapsulated bupivacaine, 13, 14  
 Lips, 91, 92  
 Lobule, 86  
 Local anesthesia  
   amide local anesthetics, 7  
   anesthetic failure, 56  
   articaine molecule, 7  
   etiology, 57  
   history of, 3  
   indications, 3  
   intraoperative and postoperative pain control, 3  
   local complications  
     anesthetic failure, 56  
     hematoma formation, 57  
     inadvertent injection, 57  
     inferior alveolar nerve, 57  
     intravascular injection, 57  
     nerve injury, 58, 59  
     topical pre-injection local anesthesia, 57  
     unintended nerve involvement in a non-surgical region, 58  
   loss of sensation, 3  
   management, 54  
   medical and dental procedures, 4  
   metabolism of, 7  
   needle breakage, 60  
   ocular complications, 59  
   pain management, 3  
   pain perception, 57

## pharmacology

  degree of vasodilation, 6  
   duration of action, 6  
   hydrophilic terminal amine, 5  
   intermediate ester or amide linkage, 5  
   lipophilic aromatic ring, 5  
   neuronal conduction, 4  
   onset and duration, 6  
   onset time, 5, 6  
   potency of, 5  
   repolarization phase, 4  
   sensitivity, 4  
   sodium channels, 4  
   somatosensory pathways, 4  
   structural components, 5  
   time to onset, 5  
   tissue inflammation, 6  
   use-dependent or frequency-dependent conduction block, 4  
   vasodilation, 6  
 properties of, 7  
 sedative anesthetic plan, 3  
 self-inflicted trauma to soft tissue, 59  
 side effects and complications, 4  
 soft tissue injury, 60  
 systemic complications  
   acquired methemoglobinemia, 54, 55  
   allergy, 55  
   cutaneous flushing, 53  
   emergency medical services, 54  
   manufacturer's maximum recommended dosages, 54  
   physiological alterations, 53  
   psychogenic episode, 53  
   severity and magnitude, 54  
   supportive measures, 54  
 topical pre-injection local anesthesia, 57  
 toxicity, 53  
 trismus, 61  
 use of, 3  
 vasoconstrictor additives related complications, 55, 56  
 vasoconstrictors, adverse drug interactions, 56  
 Local anesthetic infusion pump, 13  
 Local infiltration, 17  
 Localized tissue injury, 60  
 Long buccal nerve block (supplemental to IANB), 27  
 Lower eyelid, 176  
 Lower face, 134  
 Lower lid blepharoplasty, 177, 179  
 Lower lip, depressors of, 93

**M**

Major blood vessels, head and neck  
   carotid artery and branches, 226  
   maxillary artery, 227  
   oculomotor nerve (CN III), 229, 230  
   subclavian artery, 225, 226  
   venous drainage, 227  
 Malar fat pad, 170  
 Mandible, 221, 222  
 Mandibular block techniques, 26–28  
 Mandibular branch, 114, 168  
 Mandibular division, 235–237  
 Mandibular nerve block, 35, 36  
 Masseter, 117, 118

Mastication muscles, 169  
     lateral pterygoid, 117, 118  
     medial pterygoid, 117  
 Mastoid process, 43, 45  
 Matrix, 68  
 Maxillary artery, 133, 227  
 Maxillary division, 18, 234–236  
 Maxillary nerve block, 18, 22, 33–35  
 Maxillary second division nerve block, 22  
 Maxillary sinuses, 84  
 Meckel's cave, 18  
 Medial palpebral arteries, 170  
 Medial pterygoid, 117  
 MedtronicAxiEM navigation system, 60  
 Meissner's Corpuscle, 70  
 Melanin, 67  
 Melanocytes, 66  
 Melanocyte stimulating hormone(MSH), 67  
 Melanocytic nevi, 72  
 Melanosomes, 67  
 Mental branch, 113  
 Mental nerve block, 35–37, 48, 93, 191, 192  
 Mentalis, 111, 126  
 Mepivacaine, 12  
 Merkel's cells, 67, 70  
 Merocrine mechanism, 69  
 Methemoglobinemia, 54, 55  
 Methylparaben, 9  
 Middle meningeal nerve, 18  
 Middle scalene muscle, 97  
 Midface, 132, 133  
 Midline nasal septum, 79  
 Midline septum of nose, 81  
 Modiolus, 93  
 Monoamine oxidase (MAO), 11  
 Monoamine oxidase inhibitors (MAOIs), 11  
 Motor innervation, 93  
 Motor Nerves, 78  
 Mouth, 91  
 Muller's muscle, 176  
 Multivesicular liposomes, 13  
 Muscles of facial expression, 92  
 Musculature, 92  
 Mustardé sutures, 187, 188  
 Mustardé technique, 188  
 Mylohyoid block, 30  
 Myobloc, 124

## N

Nails, 65  
 Nasal cavity, 79, 80  
 Nasal crests of the palatine bone and maxilla, 79  
 Nasal muscles, 79  
 Nasion, 79  
 Nasociliary nerve, 78  
 Nasofrontal suture line, 151  
 Nasolabial fold, 137  
 Nasopalatine nerve block, 21, 22  
 Neck  
     anterior scalene muscle, 97  
     anterior triangle, 98  
     arteries, 104  
         carotid artery, 106  
         subclavian artery, 104–106

        emergency airway access, cricothyroidotomy, 95, 96  
     esthetic units of, 200  
     fascia of, 99–101  
     infrahyoid muscles, 98, 99  
     levator scapulae muscle, 97  
     middle scalene muscle, 97  
     muscles, 97, 201  
     nerves of  
         accessory nerve, 101  
         cervical nerves, 101, 102  
         cervical sympathetic trunk, 103  
         facial nerve, 101  
         glossopharyngeal nerve, 102, 103  
         hypoglossal, 103–105  
         vagus, 102, 103  
     posterior scalene muscle, 97  
     posterior triangle, 97  
     sensory nerves, 42  
     sternocleidomastoid muscle, 97  
     superficial anatomy, 95  
     suprahyoid muscles, 98, 99  
     trapezius muscle, 97  
     veins and nerves, 201  
     veins of, 106, 107  
     visceral structures  
         parathyroid glands, 96  
         submandibular gland, 97  
         thyroid gland, 96  
 Neck lift  
     anatomical considerations, 199, 200  
     muscles, 199, 201  
     perioperative considerations, 203  
     treatment considerations, 199, 202, 203  
     veins and nerves, 201  
 Needle breakage, 60  
 Nerve injury, local anesthetic injection, 58, 59  
 Nerves, neck  
     accessory nerve, 101  
     cervical nerves, 101, 102  
     cervical sympathetic trunk, 103  
     facial nerve, 101  
     glossopharyngeal nerve, 102, 103  
     hypoglossal, 103–105  
     vagus, 102, 103  
 Neuromodulators, 123  
     BTX-A and BTX-B production, 124  
     BTX-A treatment, adverse effects of, 124, 125  
     complications, 129  
     Crow's feet/periorbital rhytids, 127  
     dilution technique, 124  
     glabella, 127, 128  
     indications/contraindications/adverse events, 124  
     injection technique  
         anatomic sites and general dosage ranges, 125, 126  
         dosing, 125  
         longevity of effect, 127  
         posttreatment instructions, 126, 127  
     non-cosmetic indications, 128, 129  
     patient evaluation, 127  
     pharmacology, 123, 124  
 Neval cells, 72  
 Nonablative fractionated lasers, 143  
 Nonsurgical otoplasty techniques, 186  
 Norwood classification, 206



## Nose

- anterior ethmoidal artery, 82
- bony framework, 79
- cartilages, 81
- concept of field block, 37, 38
- external, blood supply, 81, 82
- infraorbital artery, 82
- infratrochlear artery, 82
- internal, blood supply, 82
- mucosa, 80
- respiratory system, 79
- sensation to the lateral surface, 80

**O**

- Occipital artery, 106
- Occipital condyle, 219
- Occipital triangle, 98
- Occipitofrontalis muscle, 75, 111
- Oculomotor nerve (CN III), 78, 229, 230
- Olfactory nerves (CN I), 80
- Omohyoid muscle, 98, 199
- Ophthalmic artery branches, 76, 132, 170
- Ophthalmic artery occlusion (blindness), 77
- Ophthalmic division, 233, 234
- Ophthalmic nerve (V<sub>1</sub>) block, 31
- Ophthalmic veins, 76
- Ophthalmologic complications, local anesthesia, 59
- Optic nerve (CNII), 78
- Orbicularis oculi muscle, 74, 111, 127, 132, 153
- Orbit
  - muscles, 75
  - superficial anatomy, 74
- Orbital septum, 175
- Osseous augmentation, 192–194
- Osteology, 215
- Osteology of the orbit, 73, 74
- Otoplasty
  - auricle, anatomy of, 184–186
  - cartilage-cutting techniques, 187, 188
  - cartilage-sparing techniques, 187
  - combining techniques, 188
  - complications, 189
  - embryology, 183
  - nonsurgical otoplasty techniques, 186
  - prominent lobule, correcting, 188
  - surgical otoplasty techniques, 187

**P**

- Pacinian Corpuscle, 70
- Paired temporalis muscles, 153
- Palatine canal and pterygopalatine fossa, 23
- Papillary dermis, 67, 68
- Paranasal sinuses, 83, 84
- Parathyroid glands, 96
- Paresthesia and palsy, 58
- Parotid gland, 114, 115, 170
- Perioral region, 91
  - blood supply, 94
  - buccinator muscle, 93
  - lips, 91, 92
  - lower lip, depressors of, 93
  - modiolus, 93
  - motor innervation, 93
  - musculature, 92

- sensory innervation, 93, 94
  - upper lip, elevators of, 92, 93
  - venous drainage, 94
- Periorbital area, 77, 136, 176
- Periorbital rhytids, 127
- Phentolaminemesylate (OraVerse), 60
- Pheomelanin, 67
- Pilosebaceous canal, 70
- Platysmal bands, 126
- Platysma muscle, 97, 111, 171, 202
- Platysmaplasty, 173
- Poly-L-lactic acid (PLLA), 134, 196
- Polymethylmethacrylate, 135
- Pontomedullary junction, 167
- Posterior auricular artery, 87
- Posterior auricular branch, 106, 113
- Posterior auricular vein, 106
- Posterior scalene muscle, 97
- Posterior superior alveolar nerve block, 18, 19
- Posterior triangle, 97
- Post-glenoid lip, 118
- Preproopiomelanocortin (POMC), 67
- Preseptal cellulitis, 180
- Pretracheal layer of the deep cervical fascia, 100
- Prevertebral layer, 100
- Prickle cells, 66
- Prilocaine, 12
- Procerus muscle, 75, 151
- Prominauris, 183
- Psychogenic reactions, local anesthesia, 53
- Pterygoid venous plexus, 76
- Pterygopalatine fossa, 22

**R**

- Real-time navigation, 60
- Relaxed skin tension lines (RSTL), 199
- Reticular dermis, 67, 68
- Retrobulbar hemorrhage, 179
- Retromandibular vein, 106, 170
- Retropharyngeal space, 100
- Rhytidectomy, 171
- Right eyelid ptosis, 128
- Risorius muscle, 93, 191

**S**

- Salivary glands, 114
- Scalp
  - aponeurosis, 70
  - connective tissue, 70
  - hair restoration, 208
  - layers, 70
  - loose connective tissue, 71
  - periosteum, 71
  - regions of, 207
  - skin, 70
  - vascular and sensory supply of, 208
- SCALP, 152
- Scarring, 148
- Sebaceous glands, 65, 69, 70
- Sebum, 70
- Selective norepinephrine reuptake inhibitors (sNRIs), 11
- Selective serotonin reuptake inhibitors (SSRIs), 11
- Sensory innervation, 78, 93, 94, 185
- Sensory modality, 70

- Sensory nerves, 111–113
  - Sentinel vein, 154
  - Serotonin-norepinephrine reuptake inhibitors (SNRIs), 11
  - Side loading dental syringes, 17
  - Silicone, 135
  - Skin, 65
    - aging, 71
    - aging, wrinkles in, 111
    - barrier, 65
    - dermis, 65
    - endocrine, 65
    - epidermis, 65
    - excretion, 65
    - homeostasis, 65
    - hypodermis, 65
    - immunity, 65
    - papillary dermis, 65
    - reticular dermis, 65
    - sensory, 65
  - Skin innervation, 70
  - Skin laxity, 202
  - Skin lesions including cutaneous cancers, 71
  - Skin tags, 72
  - Skull
    - anterior surface of, 215–217
    - bones, 80
    - exterior surface of, 218, 219
    - interior surface of, 217, 218
    - lateral surface of, 219–221
  - Small down-turn obwegeser retractor, 193
  - SMAS (superficial musculoaponeurotic system), 152, 172
  - Soft tissue filler augmentation, 196
  - Soft tissue filler emergency kit, 140
  - Sonography, 13
  - Sphenoid sinus, 83
  - Spinal accessory nerve, 42, 171
  - Spongy temporoparietal fascia, 153
  - Steatoblepharon, 177
  - Sternocleidomastoid muscle, 96, 97
  - Sternothyroid muscle, 99
  - Strap muscles, 104
  - Stratum basale, 66
  - Stratum corneum, 66
  - Stratum granulosum, 66
  - Stratum lucidum, 65, 66
  - Stratum spinosum, 66
  - Subclavian artery, 104–106
  - Subclavian vein, 106
  - Subcutaneous facelift technique, 171
  - Sublingual salivary glands, 116
  - Submandibular gland, 97, 116
  - Submental branch, 114
  - Subplatysmal fat, 203
  - Superficial (cutaneous) branches of the cervical plexus, 42
  - Superficial cervical artery, 105
  - Superficial cervical (C2, C3) block, 41–43
  - Superficial cervical fascia, 99
  - Superficial cervical plexus, 45
  - Superficial face, 109
    - facial expression muscle, 113–115
    - facial expression, muscles of, 109–112
    - major salivary glands, 114
    - parotid gland, 114, 115
    - sensory nerves, 111–113
    - sublingual glands, 116
    - submandibular gland, 116
    - superficial vessels of face, 114
  - Superficial musculoaponeurotic system (SMAS) layer, 131, 167
  - Superficial neck, 95
  - Superficial temporal and maxillary arteries, 106
  - Superficial temporal artery, 76, 87, 114, 170
  - Superficial temporal vein, 170
  - Superior thyroid artery, 106
  - Superior vena cava, 106
  - Superficial vessels of face, 114
  - Suprahyoid muscles, 98, 99
  - Suprahyoid neck, 199
  - Supraclavicular triangle, 98
  - Supraorbital branch, 111
  - Supraorbital nerves, 114
  - Supraorbital and supratrochlear nerve blocks, 31–33
  - Suprascapular artery, 105
  - Supraorbital artery, 176
  - Supraorbital nerve, 31, 32
  - Supraorbital vein, 76
  - Supraperiosteal injection, 18
  - Supratrochlear artery, 76
  - Supratrochlear branch, 111
  - Supratrochlear nerve, 31, 155
  - Suprazygomatic and infrazygomatic approach, 34
  - Suprazygomatic approach to maxillary nerve blockade, 34
  - Supreme intercostal artery, 106
  - Surgical otoplasty techniques, 187
  - Sweat glands, 65
  - Sympathomimetic drugs, 9
- T**
- Thyroid cartilage, 95
  - Tracheal rings, 95
  - Transverse facial branch, 114
  - Tarsalglands(of Meibom), 73
  - TCA peel, 147
  - Telogen, 68
  - Temporal bone, 88, 89
  - Temporal branch, 113, 167
  - Temporalis muscles, 117, 118
  - Temporal nerve, 156
  - Temporomandibular joint, 118–119
  - Tenacious zone of adherence, 152
  - Thermoregulatory sweating, 70
  - Thick skin, 65
  - Thin skin, 65, 66
  - 3D surgical navigation, 60
  - Thyrocerivical trunk, 104
  - Thyrohyoid muscle, 99
  - Thyroid cartilage reduction, 50
  - Thyroid gland, 96
  - Tissue necrosis, 138
  - Tracheal rings, 95
  - Tragus, 86
  - Transcutaneous approach, 48, 49
  - Transient facial blanching, 57
  - Transoral approach, 49
  - Transverse cervical artery, 106
  - Transverse cervical nerve, 42
  - Transverse facial branch, 114
  - Transverse processes of cervical vertebrae, 95
  - Trapezius muscle, 97
  - Triangles of neck, 100

Trichloroacetic acid (TCA), 145  
 Trichohyalin, 66  
 Tricyclic antidepressants, 11  
 Trigeminal nerve, 31, 32, 233  
   anatomy, 44, 46–48  
   maxillary division (V2), 18  
   supraorbital branch, 111  
   supratrochlear branch of frontal branch, 111  
 Trismus, 60  
 Trochlear nerve, 231  
 Trochlear nerve (CN IV), 78  
 TruForm™ DBM, 193  
 Tympanic membrane, 89

## U

Unintended nerve involvement in a non-surgical region, 58  
 Unintended paralysis of the facial nerve (seventh cranial nerve), 58  
 Upper face, 132, 133  
 Upper lid blepharoplasty, 177, 178  
 Upper lip/Perioral rhytids, 92, 93, 126  
 Upper lip, elevators of, 92, 93

## V

Vagus nerve, 102–104, 245  
 Vascular injury, 57, 58  
 Vasoconstrictive effects, 9  
 Vasoconstrictor additives  
   adverse drug interactions, 56  
   epinephrine and nonselective  $\beta$ -blockers, 56  
   epinephrine and phenothiazine and  $\alpha$ -blockers, 56  
   epinephrine and tricyclic antidepressants, 56  
   epinephrine with monoamine oxidase inhibitors, 56  
   complications, 55, 56

Vasoconstrictors  
   agents and preparation, 9  
   concentrations, 9  
   pharmacology  
     anesthetic blockade, 9  
     cardiovascular comorbidities, 9  
     duration of anesthetic activity, 9  
     local anesthetic agents, 9  
     mepivacaine, 8  
     prilocaine, 8  
     rate of absorption into systemic circulation, 8  
     surgical bleeding, 9  
     sympathomimetic, 9  
 Vazirani-Akinosi nerve block, 28, 29  
 Veins, of neck, 106, 107  
 Venous drainage  
   facelift, 170  
   perioral region, 94  
 Vermillion zone, 91  
 Vertebral artery, 104  
 Vertical deficiency, 191  
 Vertical post deformity, 189  
 Vessel injury, 57

## X

Xeomin, 123

## Z

Zygomatic branch, 112, 113, 168  
 Zygomatic nerve, 18, 33  
 Zygomaticofacial nerve, 33  
 Zygomaticotemporal branches, 112  
 Zygomaticotemporal nerve, 34  
 Zygomaticus major and minor, 93, 111